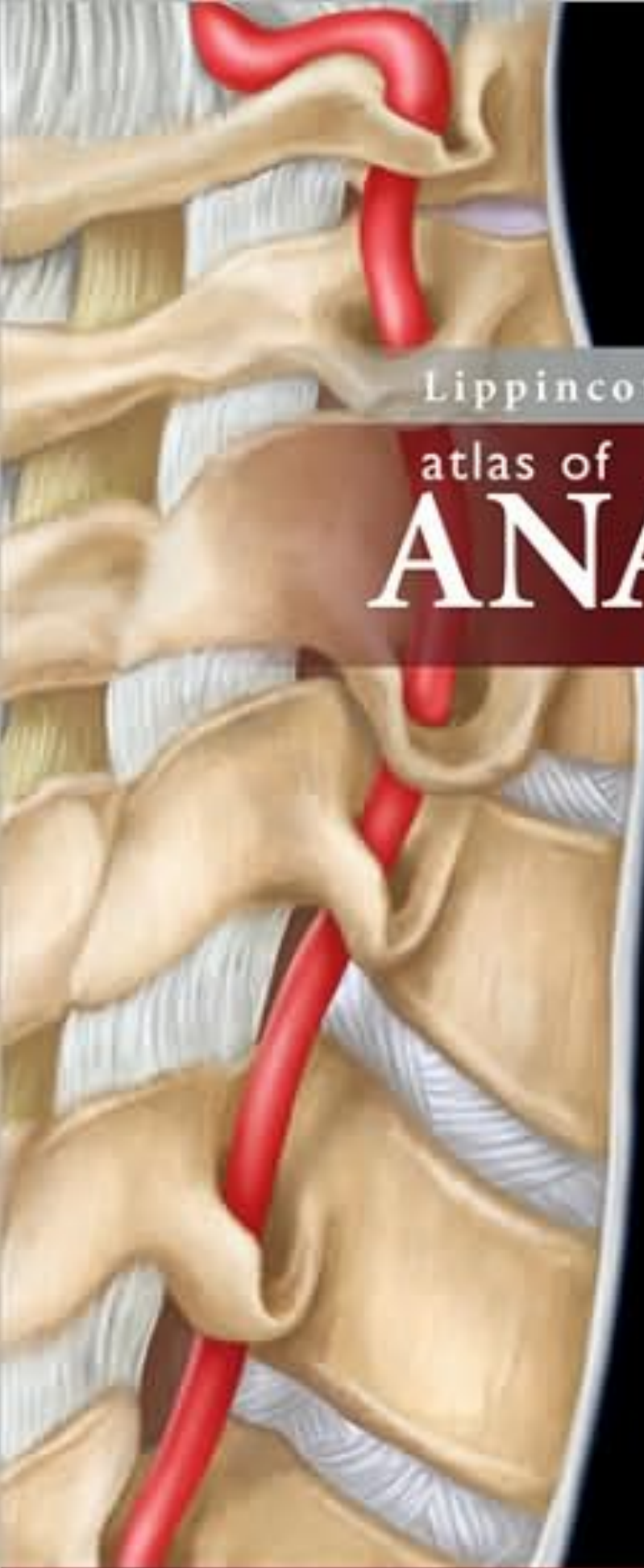

Lippincott Williams & Wilkins

atlas of
ANATOMY

Patrick W. Tank | Thomas R. Gest



Wolters Kluwer | Lippincott Williams & Wilkins

Authors: Tank, Patrick W.; Gest, Thomas R.

Title: *Lippincott Williams & Wilkins Atlas of Anatomy, 1st Edition*

Copyright ©2009 Lippincott Williams & Wilkins

> Front of Book > Authors

Authors

Patrick W. Tank PhD

Director

Division of Anatomical Education, Department of Neurobiology & Developmental Sciences, University of Arkansas for Medical Sciences, Little Rock, Arkansas

Thomas R. Gest PhD

Division of Anatomical Sciences, Office of Medical Education, University of Michigan Medical School, Ann Arbor, Michigan

Contributing Author

William Burkel PhD

Professor Emeritus

Division of Anatomical Sciences, University of Michigan Medical School, Ann Arbor, Michigan

Authors: Tank, Patrick W.; Gest, Thomas R.

Title: *Lippincott Williams & Wilkins Atlas of Anatomy, 1st Edition*

Copyright ©2009 Lippincott Williams & Wilkins

> Front of Book > Dedication

Dedication

Dedicated to the memory of Russell T. Woodburne, PhD whose descriptions of anatomy are as valid and accurate today as they were when first written over 50 years ago.

Authors: Tank, Patrick W.; Gest, Thomas R.

Title: *Lippincott Williams & Wilkins Atlas of Anatomy, 1st Edition*

Copyright ©2009 Lippincott Williams & Wilkins

> Front of Book > Preface

Preface

The opportunity to create a new anatomical atlas could not be described as even a once-in-a-lifetime opportunity. Original atlases simply are not produced often enough to make that statement accurate. As anatomical educators of medical students with nearly 60 years of classroom experience between us, we are familiar with all of the anatomical atlases that are currently on the market, and it is a very esteemed group. Our experience with these existing atlases has helped us formulate strong ideas of how to present anatomical images more concisely and in a more logical sequence. The intent of this new atlas is to make images easier and faster for the student to use. Speed and ease of use have become critical needs in the era of compressed anatomical curricula.

The development of this atlas required the combined efforts of a large group of people and the good fortune to have all of these resources available simultaneously. First, we had the complete support of Lippincott Williams & Wilkins (LWW). This support came in many forms, from editorial and production assistance and project funding to art direction and expert market analysis as well as many words of encouragement.

Second, we had the exceptional talents of the creative team at the Anatomical Chart Company (ACC). ACC produces the thousands of anatomical and diagnostic charts that are displayed in clinics and doctors' offices all over the world. The ACC creative team recruited a small army of the best medical illustrators in the country, kept this army organized, and guided them throughout the project. The ACC design team created a truly inspired design and oversaw the construction of pages. Working with the LWW production team, ACC also guided this complex atlas through the production phase.

Third, the authors have been friends and colleagues for many years. The result of our combined efforts to develop educational material has always been greater than the sum of our individual efforts. To this project we have brought the ability and desire to work as a team.

Using these resources to the maximum extent, we have developed an atlas that stands out among contemporary atlases in several areas.

Teaching Perspective

The *LWW Atlas of Anatomy* is organized regionally. However, the atlas is not simply a series of flat anatomical drawings with every structure labeled. Every aspect of the atlas, from the selection and organization of the plates, to the coloring, style, and labeling of the individual images is grounded in a teaching perspective. The organization follows a teacher's logic, in that it begins with surface anatomy and superficial features, then proceeds into deeper structures with plate groupings that support regional dissection sequences. The labels are carefully selected and placed to tell a story and direct the attention of the viewer to important relationships.

A New Art Style

A new art style was created for the *LWW Atlas of Anatomy*. The illustrations use a vibrant palette, new surface textures, effective use of shading to add depth, and a clean, uncluttered labeling approach. The main illustrations are designed to depict the most common anatomical features (i.e., "average" anatomy) that a student is likely to encounter in dissections or clinical practice. Common important anatomical variations are also depicted in supporting illustrations.

Careful Selection of Images

There are fewer illustrations in the *LWW Atlas of Anatomy* than in other atlases. In today's shrinking anatomy curriculum, more is not necessarily better. We carefully considered the number of illustrations necessary to get the job done, with no superfluous figures or concepts. Illustrations are placed in logical dissection order, followed by summary illustrations (systemically organized illustrations of vessels and nerves) that help the student assemble the parts into a whole.

Consistent Perspective

To aid the novice, the images in the *LWW Atlas of Anatomy* use consistent viewpoints: Directly anterior, directly posterior, directly lateral, or directly medial. The specimen is always placed in the anatomical position. Oblique views and quartering views are not used. Positioning of the limbs or the head in other than the anatomical position has been strictly avoided.

Effective Use of Color

Images in the *LWW Atlas of Anatomy* use color to draw the viewer's attention to the important part of the figure. Many figures have highly detailed peripheral anatomy rendered in gray to provide context for the illustration without distracting the viewer from the central theme. Summary illustrations use this color technique to particular advantage to show systemic anatomy of body regions.

Ghosted Structures

Many illustrations in the *LWW Atlas of Anatomy* employ a ghosting technique to allow the viewer to look into the illustration in greater depth. In some illustrations, the viewer looks through ghosted structures to see important anatomical relationships. In other illustrations, a solid object is rendered as a ghost where it passes behind another solid object. By use of these ghosting techniques, we are able to illustrate the relationships of deep structures to more superficial structures and allow students to see connections and associations that previously they had to imagine.

Limited Labeling

We have intentionally limited the number of labels per illustration in the *LWW Atlas of Anatomy*. We deliberately selected only those structures most likely to be taught in modern curricula and to provide labels for those structures. We did not label everything in each illustration. Many additional structures could have been labeled, but at a loss of the didactic impact of the image.

Effective Label Placement

We have juxtaposed labels to increase the pedagogical impact of the illustration. These label placements encourage the student to notice important relationships. We also have used lists of labels to reinforce the relationship of parts of structures to the whole. The arrangement of labels, combined with the use of color, leaves little doubt as to the intent of the illustration.

No Captions

The *LWW Atlas of Anatomy* has no captions or text to explain the figures. Market analysis indicates that students and faculty are sharply divided on whether or not this type of material is useful. It is our feeling that an atlas is a supplement to a textbook. We feel that students consult an atlas for visual identification, not description, and that lengthy discussion of the illustrations is not necessary if the illustrations are designed and organized properly and used in the context of text materials.

Complete Product Package

We are also offering with the text a set of supporting products designed to help students learn anatomy. All of the images are available electronically in an interactive atlas that can be accessed on thePoint (Lippincott Williams & Wilkins's website). The interactive atlas has several useful features, including a search function and zoom and compare features. Students can also test their knowledge of anatomy with a unique drag-and-drop labeling exercise available for each image. Instructors also receive an image bank that

provides each image in a file suitable for multimedia presentations and an extensive repository of anatomy-oriented test questions

The *LWW Atlas of Anatomy* has taken many years to complete, and its creation took full advantage of electronic communication and imaging. It has not been an easy feat, as the artists, editors, authors, and publisher are spread all over the country. Approximately 7500 versions of the illustrations were reviewed and critiqued during the course of the project. We all suffered moments of fatigue but the result is well worth the time invested. The experience has been both exhausting and exhilarating.

We hope that you enjoy the outcome.

P T

T G

Authors: Tank, Patrick W.; Gest, Thomas R.

Title: *Lippincott Williams & Wilkins Atlas of Anatomy, 1st Edition*

Copyright ©2009 Lippincott Williams & Wilkins

> Front of Book > Illustration Team

Illustration Team

Lik Kwong, MFA

Medical Illustration

University of Michigan

Ann Arbor, Michigan

Dawn Scheuerman, MAMS

Biomedical Visualization

University of Illinois at Chicago

Chicago, Illinois

Karen Bucher, MA

Medical and Biological Illustration

Johns Hopkins University School of Medicine

Baltimore, Maryland

Anne D. Rains, MS

Medical Illustration

Medical College of Georgia

Augusta, Georgia

Jonathan Dimes, MFA

Medical Illustration

University of Michigan

Ann Arbor, Michigan

Megan E. Bluhm Foldenauer, MA

Medical and Biological Illustration

Johns Hopkins University School of Medicine

Baltimore, Maryland

Liana Bauman, MAMS

Biomedical Visualization

University of Illinois at Chicago

Chicago, Illinois

Christopher Rufo, MA
Medical Illustration
Johns Hopkins University School of Medicine
Baltimore, Maryland

William Scavone, MA, CMI
Medical and Biological Illustration
Johns Hopkins University School of Medicine
Baltimore, Maryland

Alison E. Burke, MA
Medical Illustration
Johns Hopkins University School of Medicine
Baltimore, Maryland

Denise Wurl, MS
Biomedical Visualization
University of Illinois at Chicago
Chicago, Illinois

Jennifer C. Darcy, MS
Medical Illustration
Medical College of Georgia
Augusta, Georgia

Jaye Schlesinger, MFA
Medical Illustration
University of Michigan
Ann Arbor, Michigan

Authors: Tank, Patrick W.; Gest, Thomas R.

Title: *Lippincott Williams & Wilkins Atlas of Anatomy, 1st Edition*

Copyright ©2009 Lippincott Williams & Wilkins

> Front of Book > Acknowledgments

Acknowledgments

The authors and publisher would like to gratefully acknowledge the following individuals who reviewed illustrations and provided critical feedback during the development of this atlas:

Marc Abel, PhD
Rosalind Franklin University of Medicine and Science
Chicago, Illinois

Androniki Abelidis
Hull York Medical School
Hull and York, England

Diana Alagna
Branford Hall Career Institute at Southington
Southington, Connecticut

Maryanne Arienmughare
Jefferson Medical College
Philadelphia, Pennsylvania

Fredric Bassett, PhD
Rose State College
Midwest City, Oklahoma

Sonny Batra
Stanford University
Stanford, California

Paulette Bernd, PhD
SUNY Brooklyn College of Medicine
Brooklyn, NY

Neil Boaz, MD, PhD
Ross University
Edison, New Jersey

Anna Brassington
Hull York Medical School
Hull and York, England

Eric Brinton
University of Utah School of Medicine
Salt Lake City, Utah

Ashlee Brown
University of Missouri School of Medicine
Columbia, Missouri

David Brown
University of California at Irvine
Irvine, California

Craig Canby, PhD
Des Moines University Osteopathic Medical Center
Des Moines, Iowa

Walter Castelli, DDS
University of Michigan Medical School
Ann Arbor, Michigan

Silvia Chiang
Case Western Reserve University
Cleveland, Ohio

Matthew Comstock
Oklahoma State University College of Osteopathic Medicine
Tulsa, Oklahoma

Gerald Cortright, PhD
University of Michigan Medical School
Ann Arbor, Michigan

Eugene Daniels, MSc, PhD
McGill University
Montreal, Quebec, Canada

David L. Davies, PhD
University of Arkansas for Medical Sciences
Little Rock, Arkansas

Megan Duffy
Catholic Healthcare West
San Francisco, California

Norm Eizenberg, MB
University of Melbourne
Victoria, Australia

Matt Gardiner
University College London
London, England

Niggy Gouldsborough, BSc, PhD
University of Manchester
Manchester, England

Lauren Graham
Johns Hopkins School of Medicine
Baltimore, Maryland

Santina Grant
University of Illinois at Chicago College of Medicine
Chicago, Illinois

Bill Gross
Medical College of Wisconsin
Milwaukee, Wisconsin

Robert Hage, MD, PhD
St. Georges University
Grenada, West Indies

Felicia Hawkins-Troupe
Loyola University Medical School
Chicago, Illinois

Keels Hillebart de Jong, PhD
Academic Medical Center of the University of Amsterdam
Amsterdam, The Netherlands

Alireza Jalali, MD, LMCC
University of Ottawa
Ottawa, Ontario, Canada

Jennifer Jenkins
Brown University
Providence, Rhode Island

Subramaniam Krisnan
University of Malaya
Kuala Lumpur, Malaysia

Randy Kulesza, PhD
Lake Erie College of Osteopathic Medicine
Erie, Pennsylvania

Anton Kurtz
University of Vermont
Burlington, Vermont

Scherly Leon
State University of New York at Stony Brook
Stony Brook, New York

Jing Xi Li
University of Ottawaâ€™Downtown
Ottawa, Ontario, Canada

Ryan Light
Eastern Virginia Medical School
Norfolk, Virginia

Darren Mack
Medical College of Georgia
Augusta, Georgia

Linda McLoon, PhD
University of Minnesota at Minneapolis
Minneapolis, Minnesota

Jodi McQuillen
University of Vermont College of Medicine
Burlington, Vermont

Nonna Morozova
Asa Institute of Business and Computer Technology
Brooklyn, New York

Karuna Munjal
Baylor College of Medicine
Houston, Texas

Barbara Murphy, PhD
University of Nebraska at Omaha
Omaha, Nebraska

Bruce W. Newton, PhD
University of Arkansas for Medical Sciences
Little Rock, Arkansas

Lily Ning
University of Medicine and Dentistry of New Jersey
Newark, New Jersey

Gezzer Ortega
Howard University College of Medicine
Washington, D.C.

Steve Palazzo, DC
University of Bridgeport
Bridgeport, Connecticut

Lynn Palmeri
Georgetown University School of Medicine
Washington, D.C.

Jilma Patrick
Meharry Medical College
Nashville, Tennessee

Kevin D. Phelan, PhD
University of Arkansas for Medical Sciences
Little Rock, Arkansas

John Polk, PhD
University of Illinois at Urbana
Urbana, Illinois

Omid Rahimi, PhD
University of Texas Health Science Center
San Antonio, Texas

Christopher Rodrique
Louisiana State University
Baton Rouge, Louisiana

Dario Roque
University of Florida
Gainesville, Florida

Heiko Schoenfuss, MS, PhD
St. Cloud State University
St. Cloud, Minnesota

Simant Shah
University of Medicine and Dentistry of New Jersey

Newark, New Jersey

Shahin Sheibani-Rad
Rosalind Franklin University of Medicine and Science
Chicago, Illinois

Parikshat Sirpal
Nova Southeastern University College of Medicine
Fort Lauderdale, Florida

Jan Smit
Queen's University Belfast
Belfast, Northern Ireland

Maria Sosa, PhD
University of Puerto Rico
San Juan, Puerto Rico

Rayapati Sreenathan, MSC, PhD
St. Matthews University Medical School
Grand Cayman, British West Indies

Lisal Stevens
Loma Linda University
Loma Linda, California

Rob Stoeckart, PhD
Erasmus University Rotterdam
Rotterdam, The Netherlands

Stuart Sumida, MA, PhD
California State University at San Bernardino
San Bernardino, California

Frans Thors, PhD
Akademisch Ziekenhuis Maastricht
Maastricht, The Netherlands

Grace Tsuei
University of Texas Southwestern Medical School
Dallas, Texas

Linda Walters, PhD
Midwestern University Arizona College of Osteopathic Medicine
Glendale, Arizona

Daniel Weber
Michigan State University College of Osteopathic Medicine

East Lansing, Michigan

Benjamin Weeks
University of Arkansas
Fayetteville, Arkansas

William Woo
Drexel University College of Medicine
Philadelphia, Pennsylvania

Floris Wouterlood, PhD
Vu Medisch Centrum
Amsterdam, The Netherlands

Jill Zackrisson
Virginia Commonwealth University School of Medicine
Medical College of Virginia Campus
Richmond, Virginia

Michael Zumpano, PhD
New York Chiropractic College
Seneca Falls, New York

Authors: Tank, Patrick W.; Gest, Thomas R.

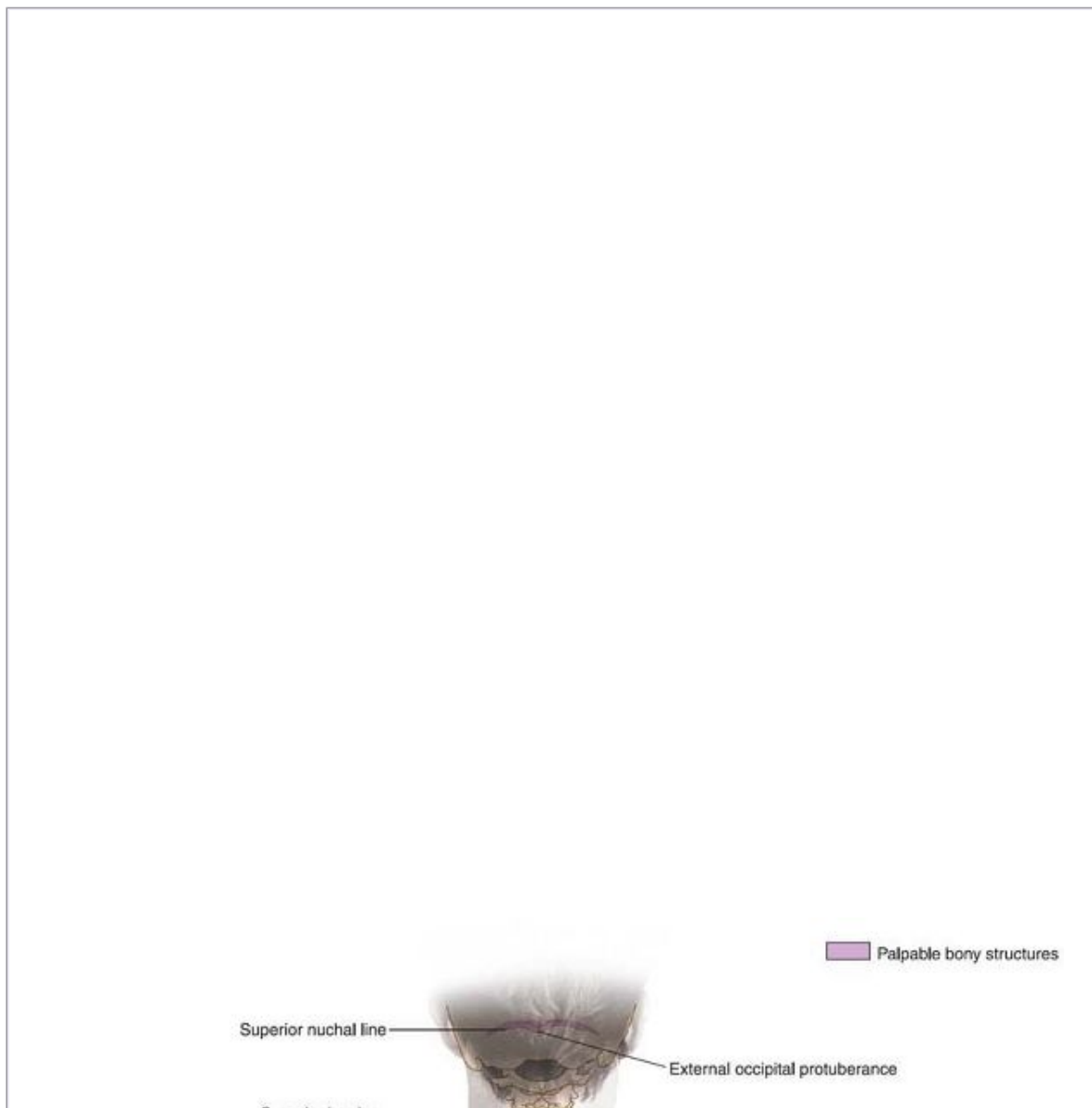
Title: *Lippincott Williams & Wilkins Atlas of Anatomy, 1st Edition*

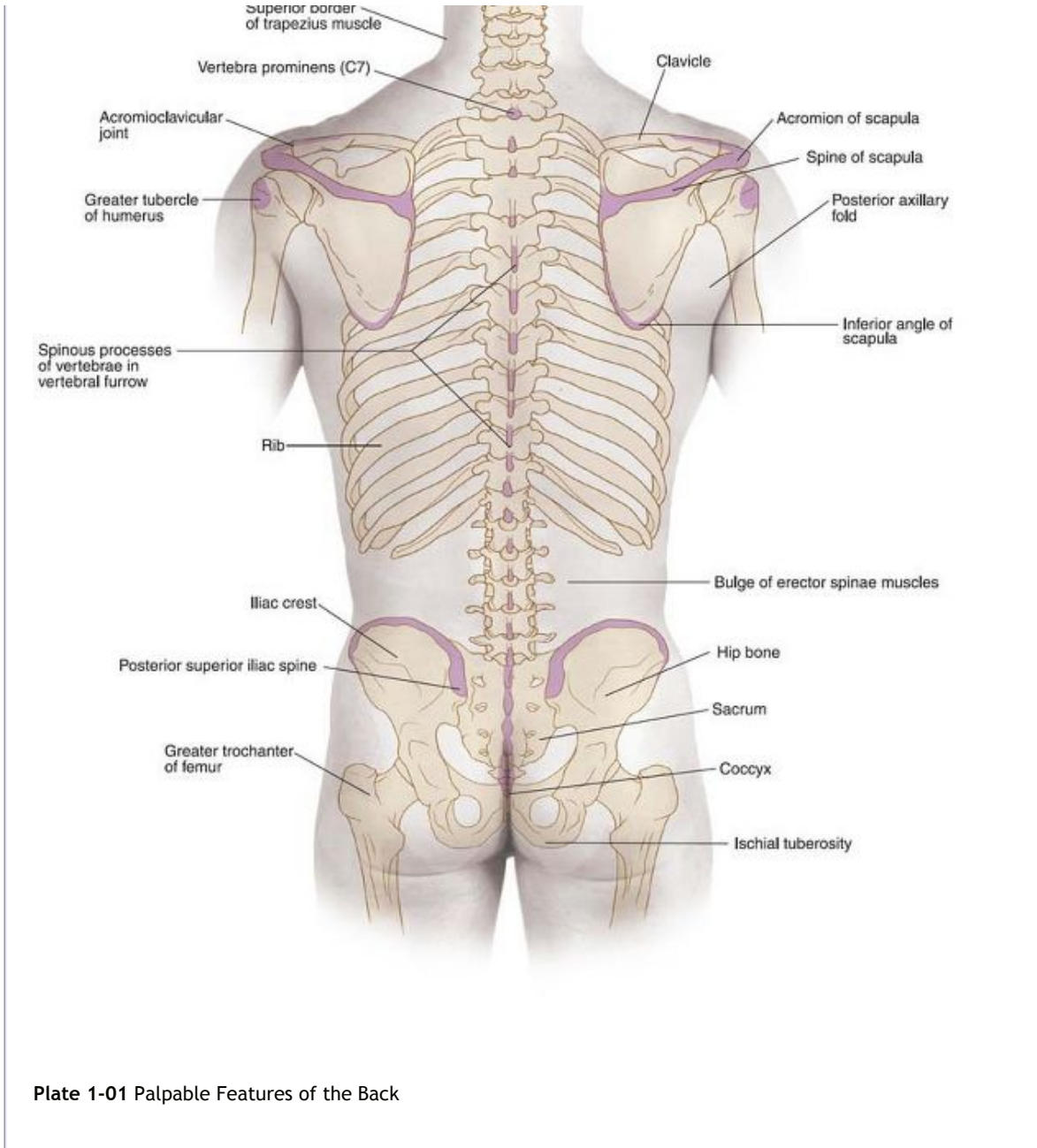
Copyright ©2009 Lippincott Williams & Wilkins

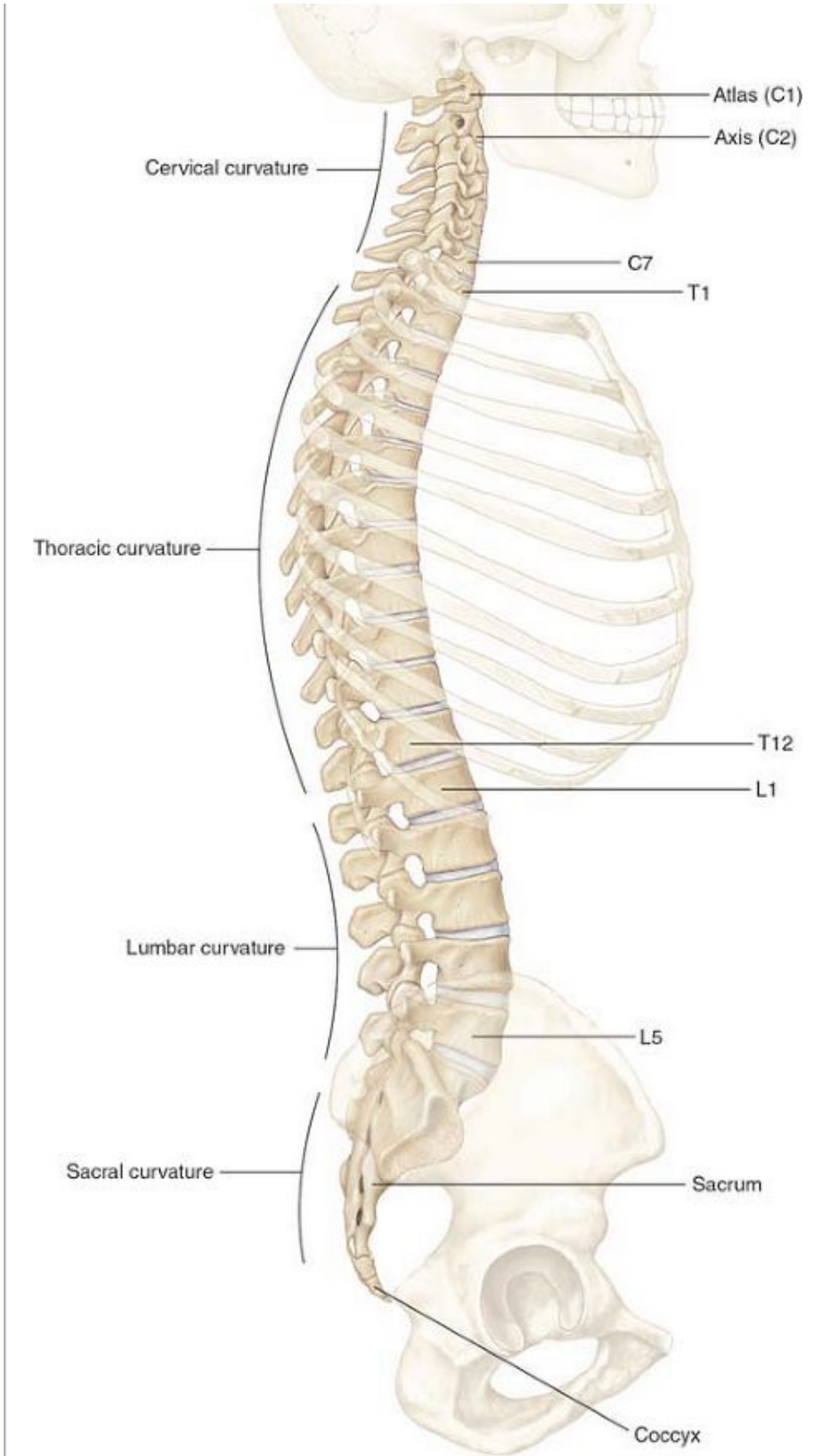
> Table of Contents > Chapter 1 - The Back

Chapter 1

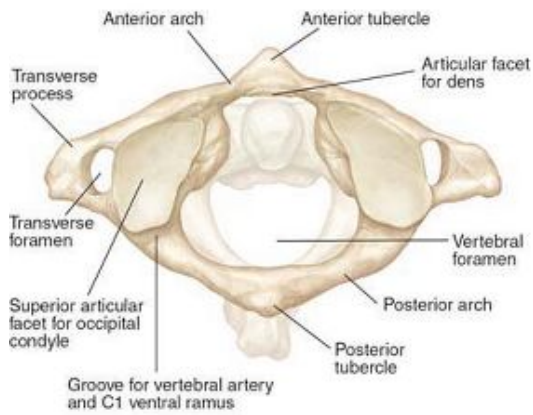
The Back



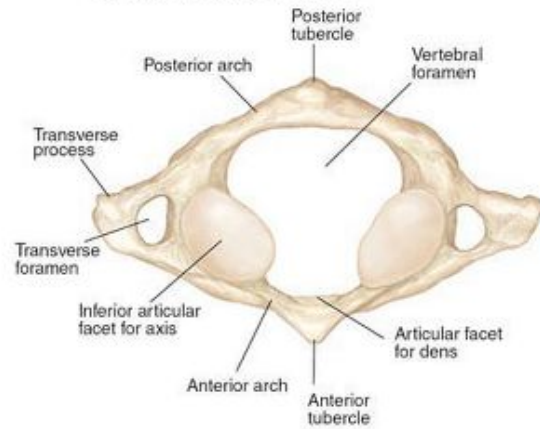




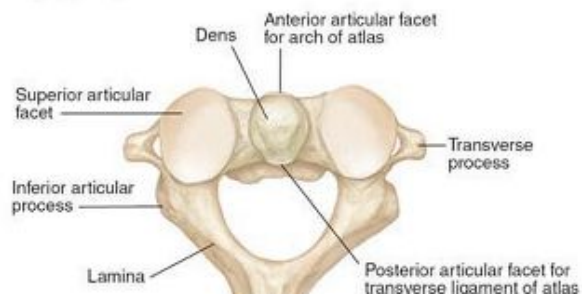
A. Atlas (C1), superior view




B. Atlas (C1), inferior view

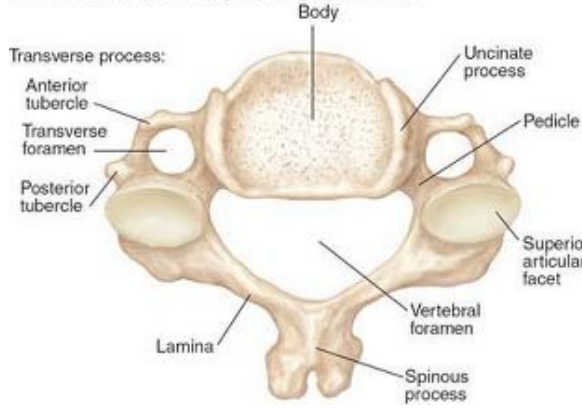


C. Axis (C2), superior view





D. Cervical vertebra (C4), superior view



E. Cervical vertebra (C4), lateral view

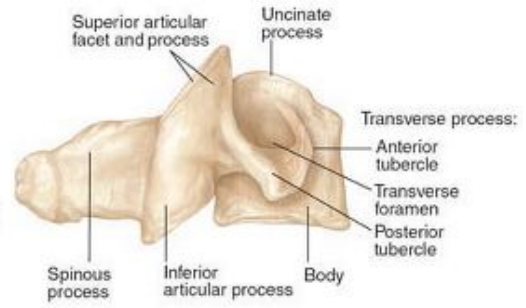
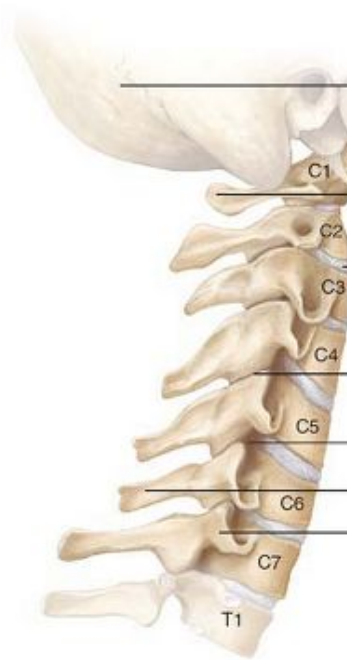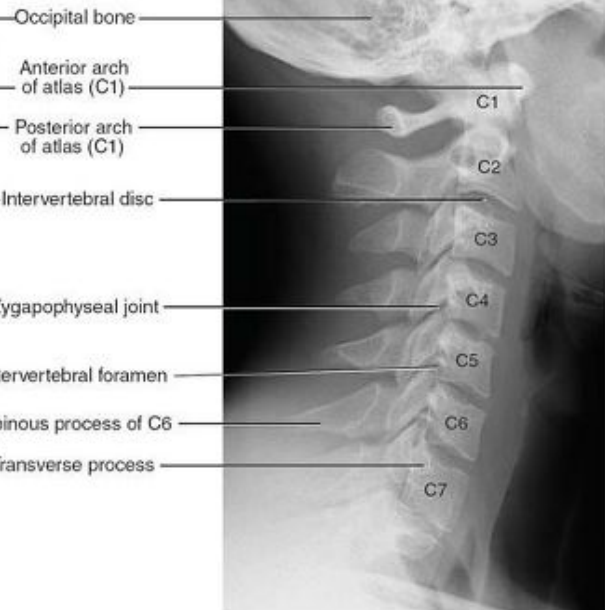


Plate 1-03 Cervical Vertebrae

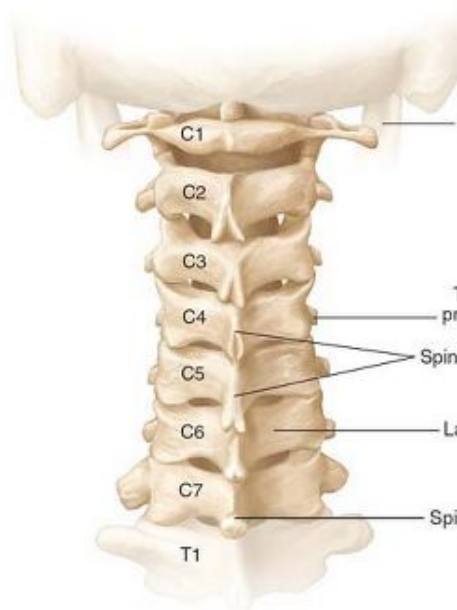A. Lateral view



B. Radiograph of cervical vertebrae, lateral view



C. Posterior view



D. Radiograph of cervical vertebrae, posterior view

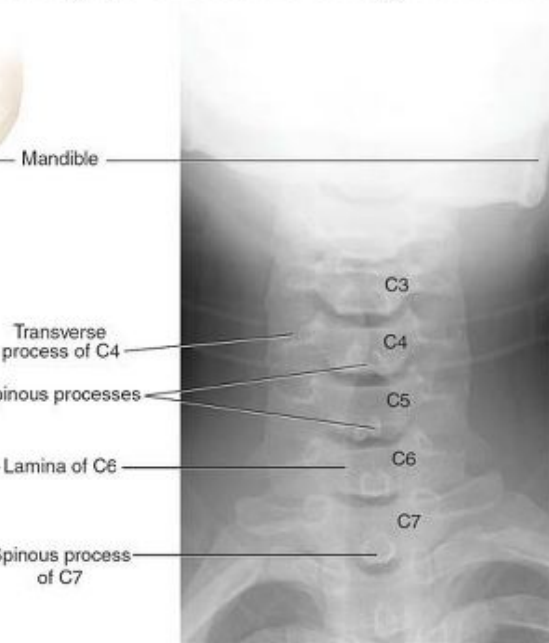
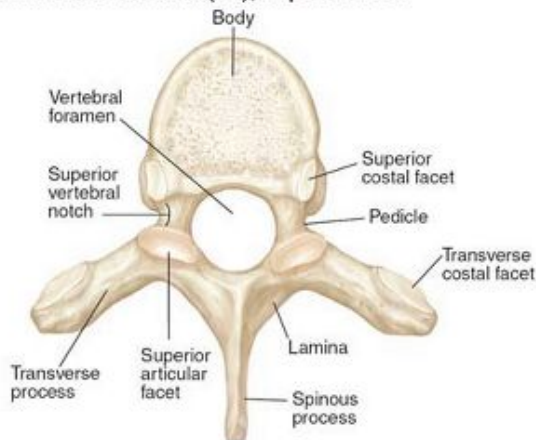
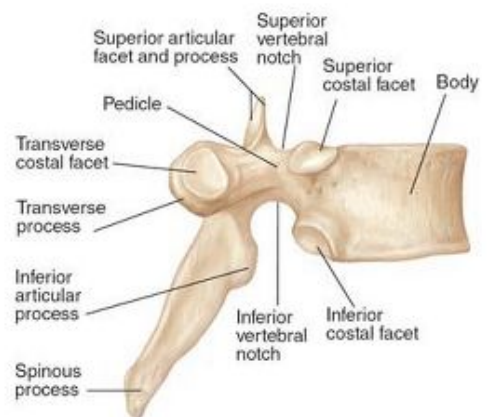


Plate 1-04 Articulated Cervical Vertebrae

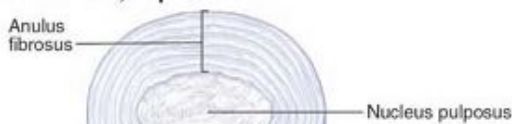A. Thoracic vertebra (T6), superior view

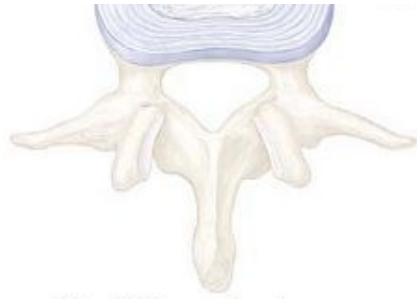

B. Thoracic vertebra (T6), lateral view

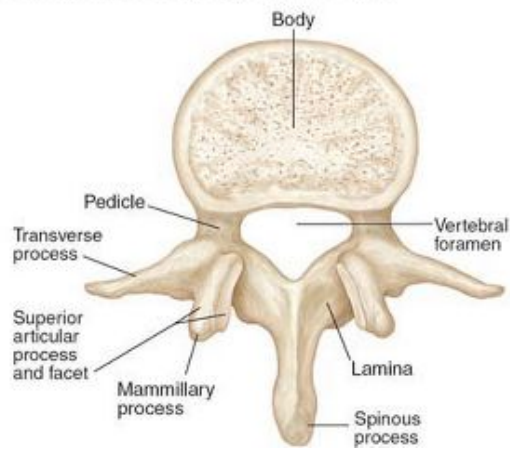


C. Intervertebral disc, superior view





D. Lumbar vertebra (L3), superior view



E. Lumbar vertebra (L3), lateral view

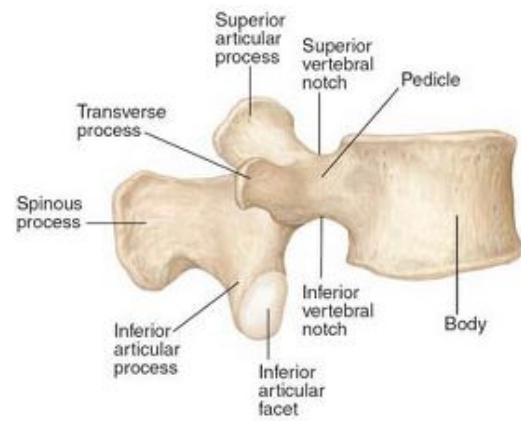
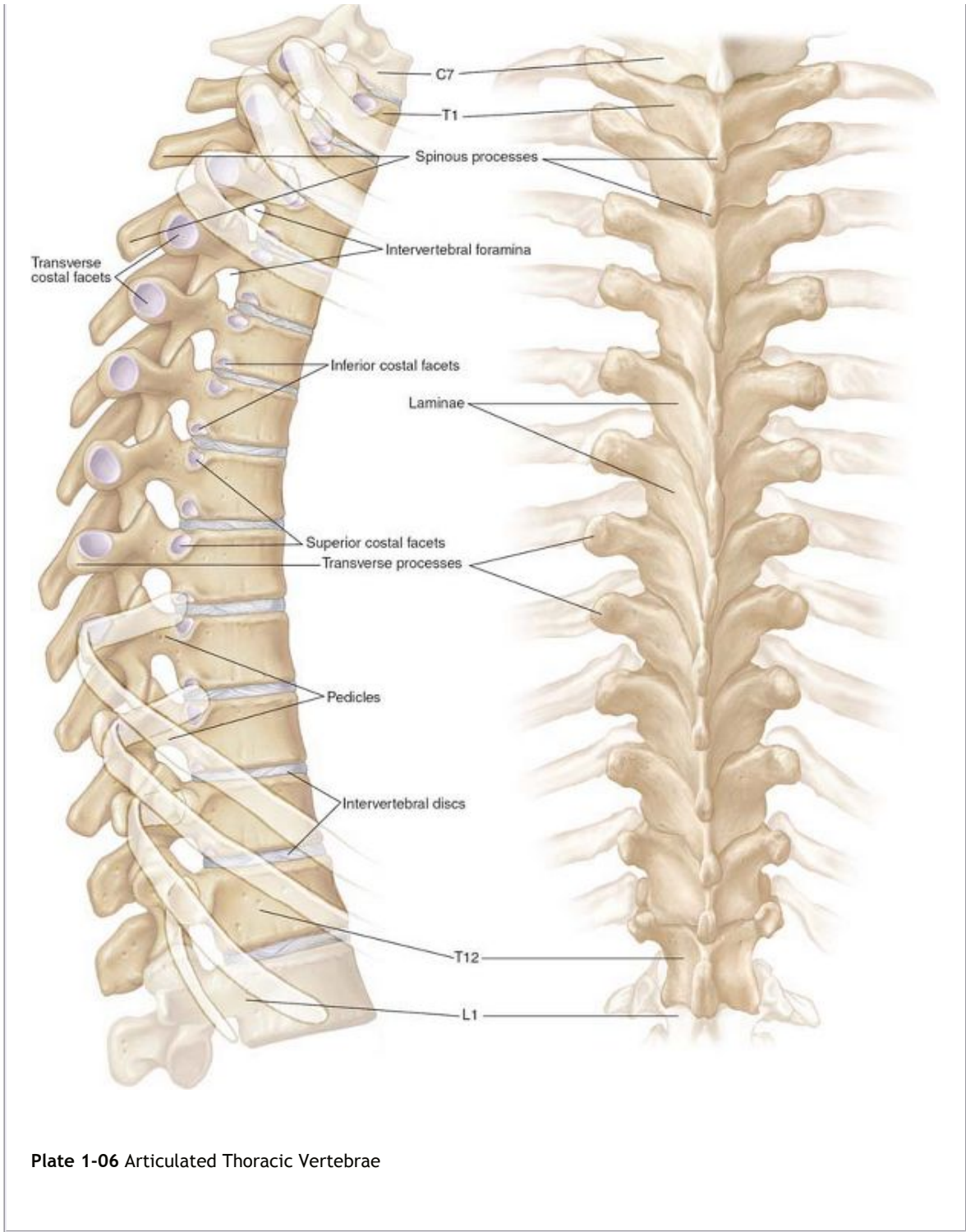


Plate 1-05 Thoracic and Lumbar Vertebrae

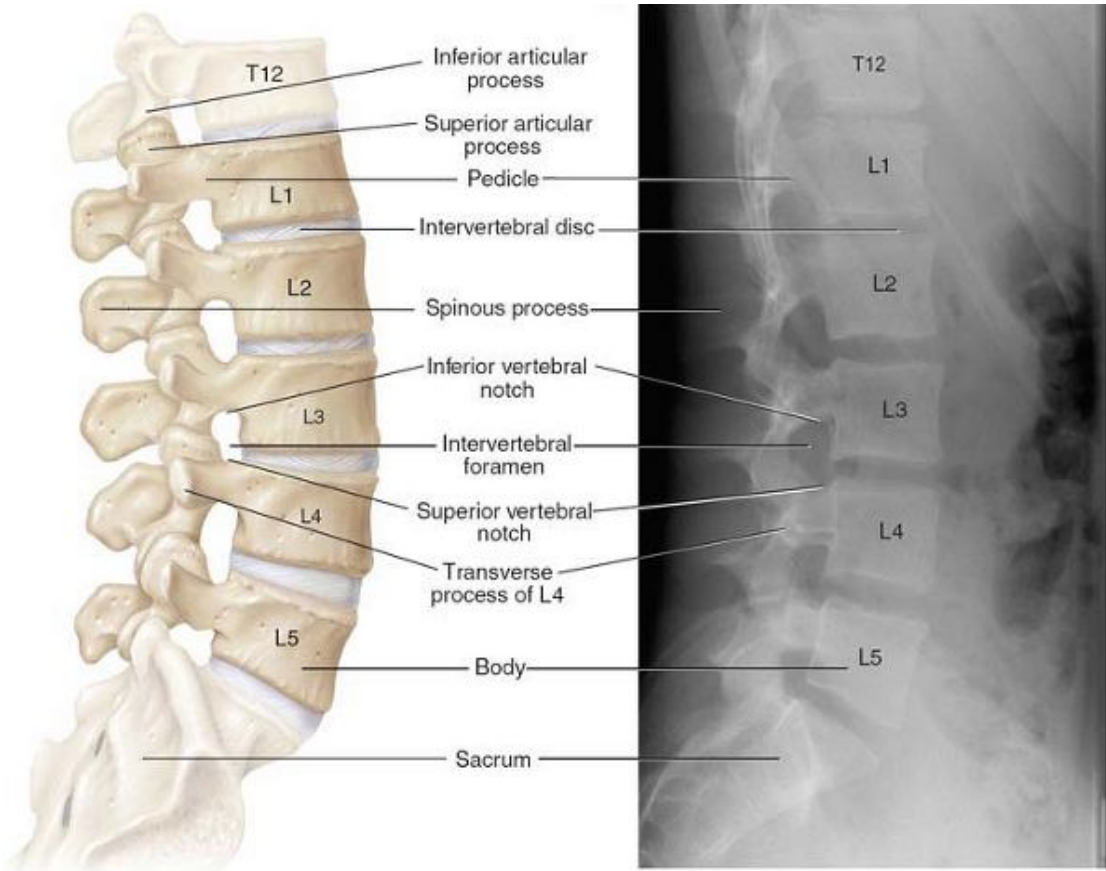
A. Lateral view

B. Posterior view



A. Lateral view

B. Radiograph of lumbar vertebrae, lateral view



C. Posterior view

D. Radiograph of lumbar vertebrae, posterior view

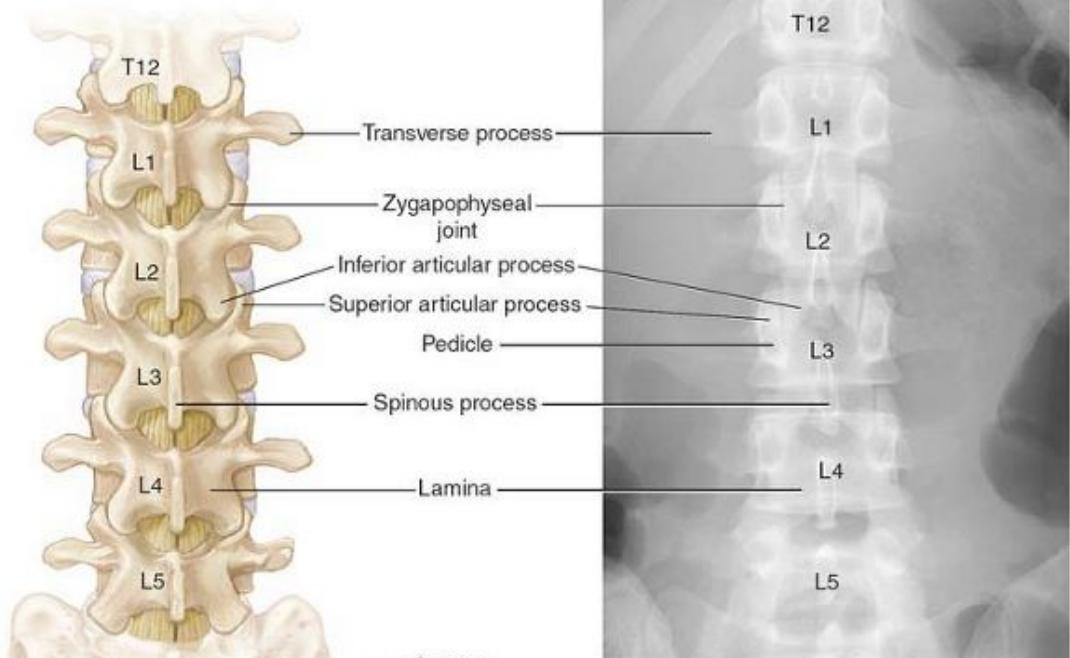
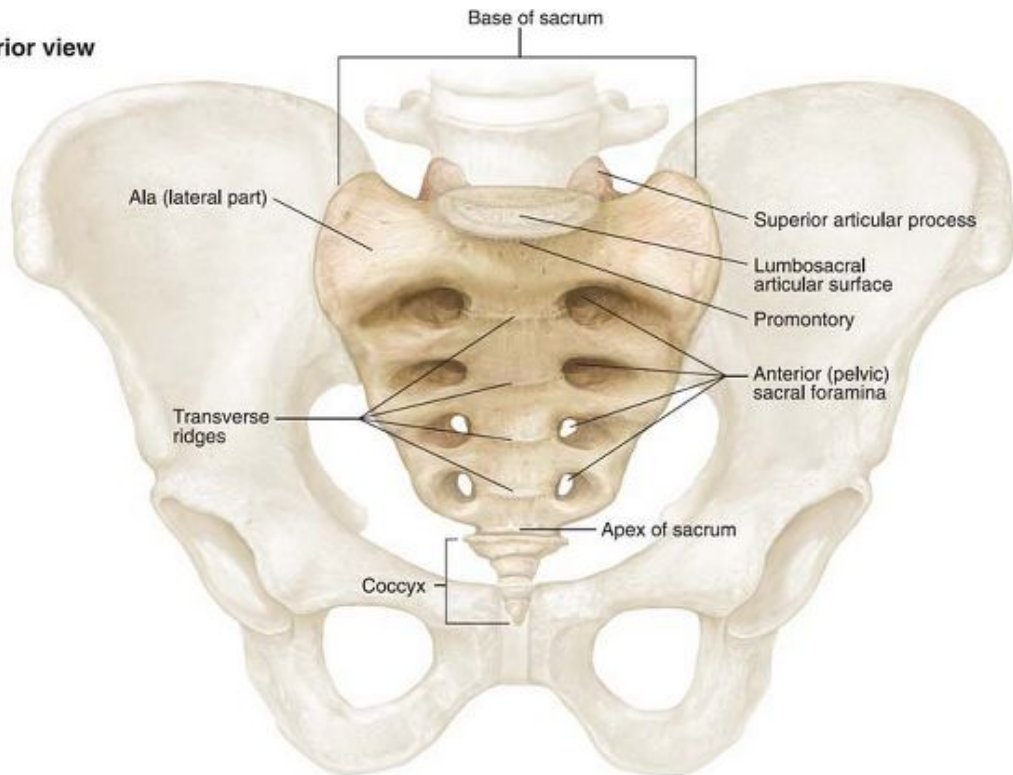


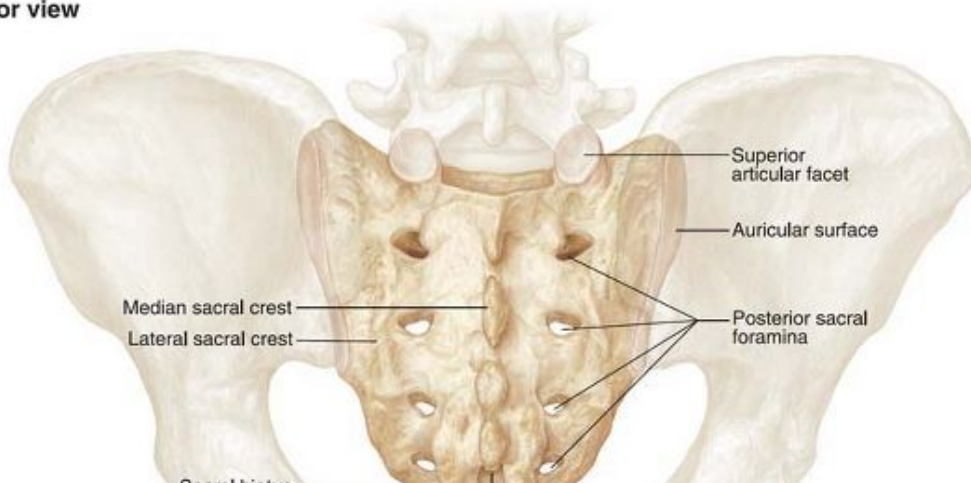


Plate 1-07 Articulated Lumbar Vertebrae

A. Anterior view



B. Posterior view



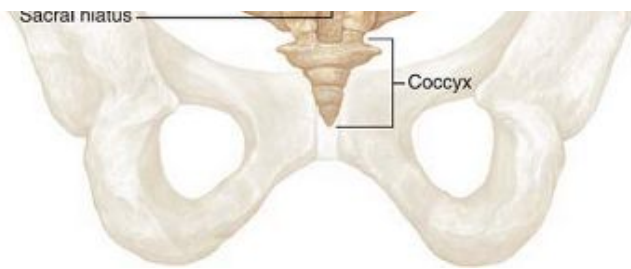
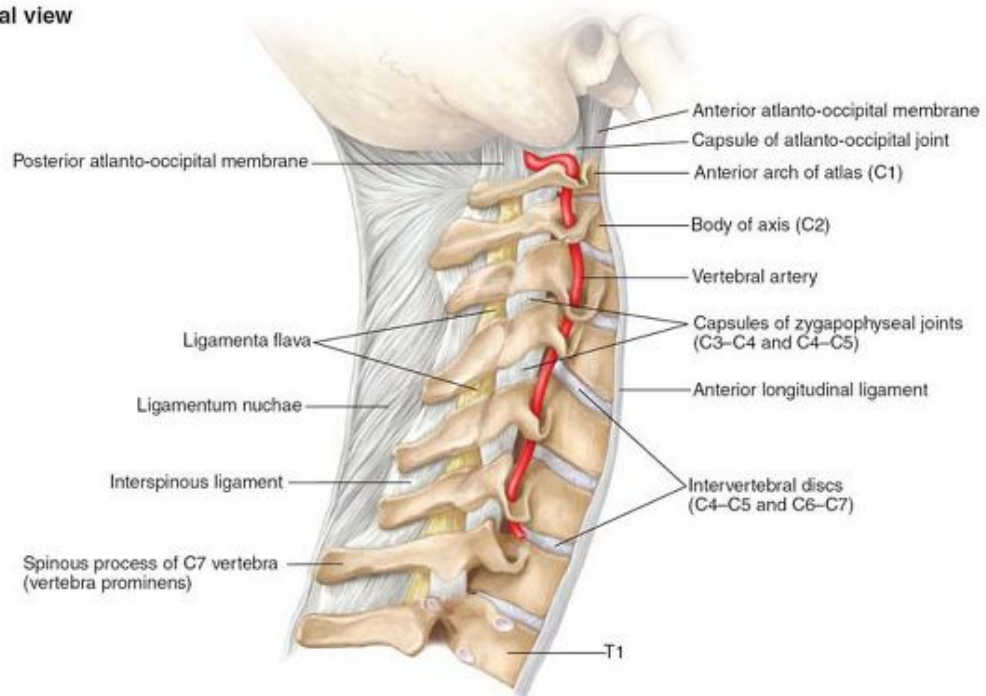
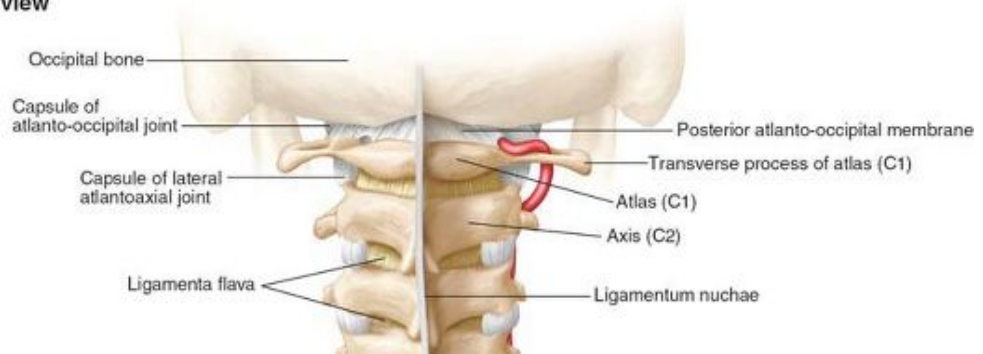

Plate 1-08 Sacrum and Coccyx

A. Lateral view

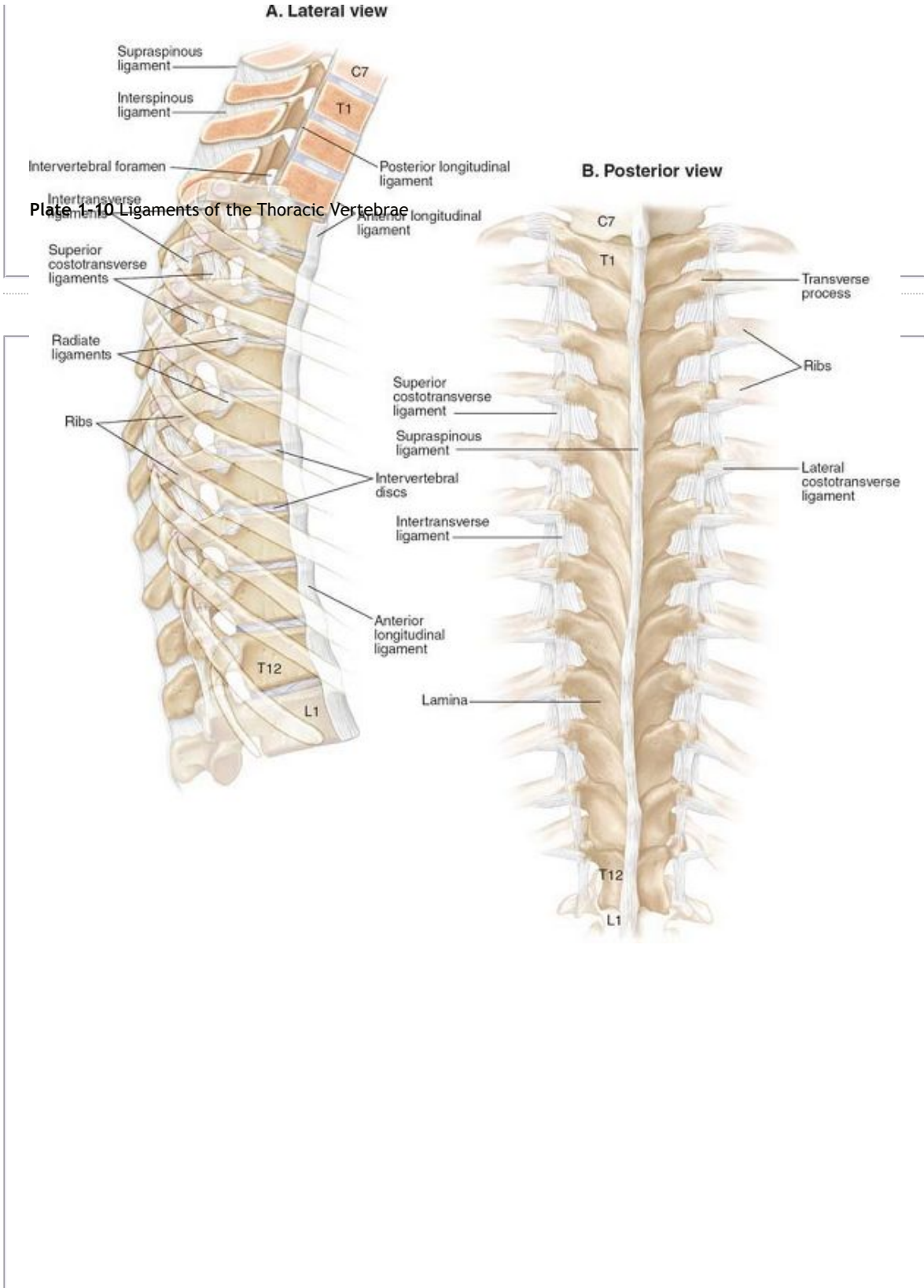


B. Posterior view

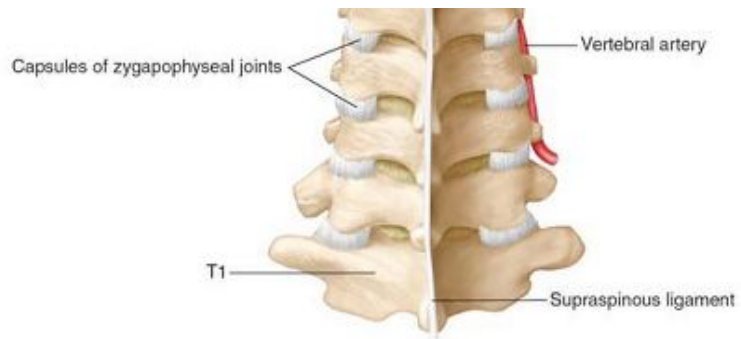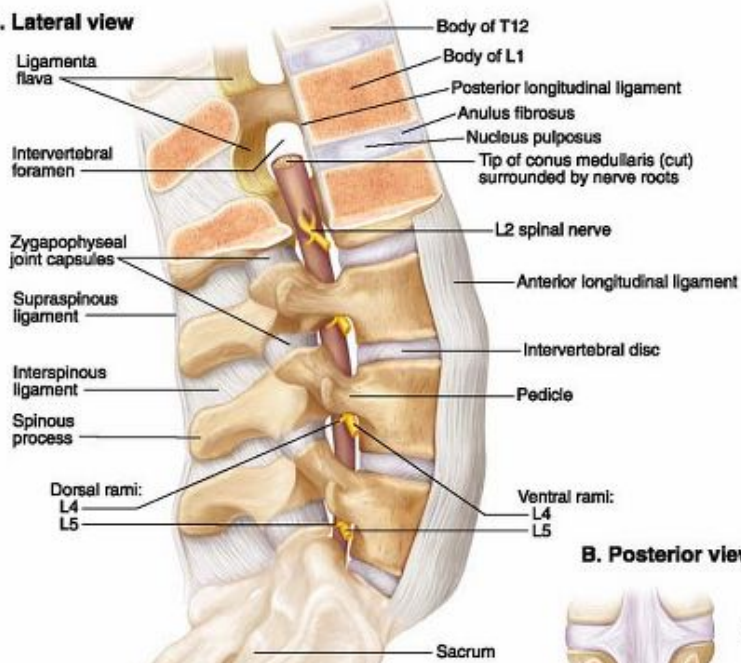




Plate 1-09 Ligaments of the Cervical Vertebrae



A. Lateral view



B. Posterior view

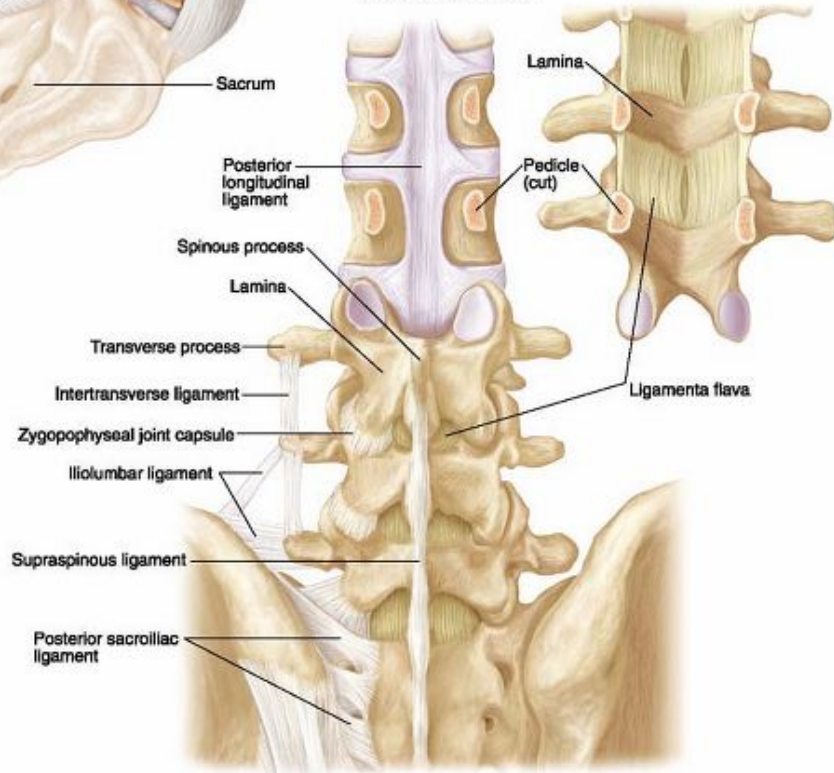


Plate 1-11 Ligaments of the Lumbar Vertebrae and Sacrum

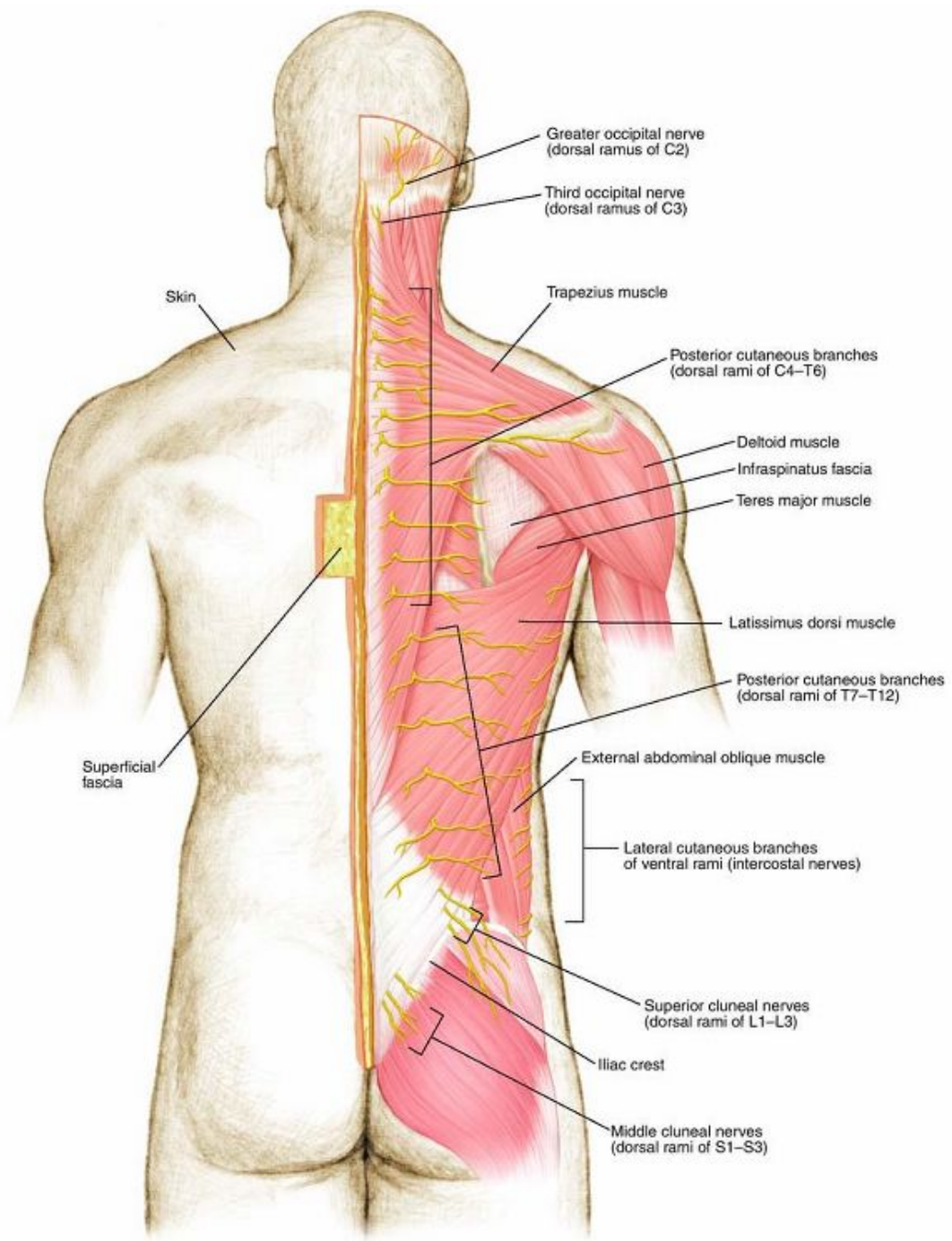


Plate 1-12 Cutaneous Innervation of the Back

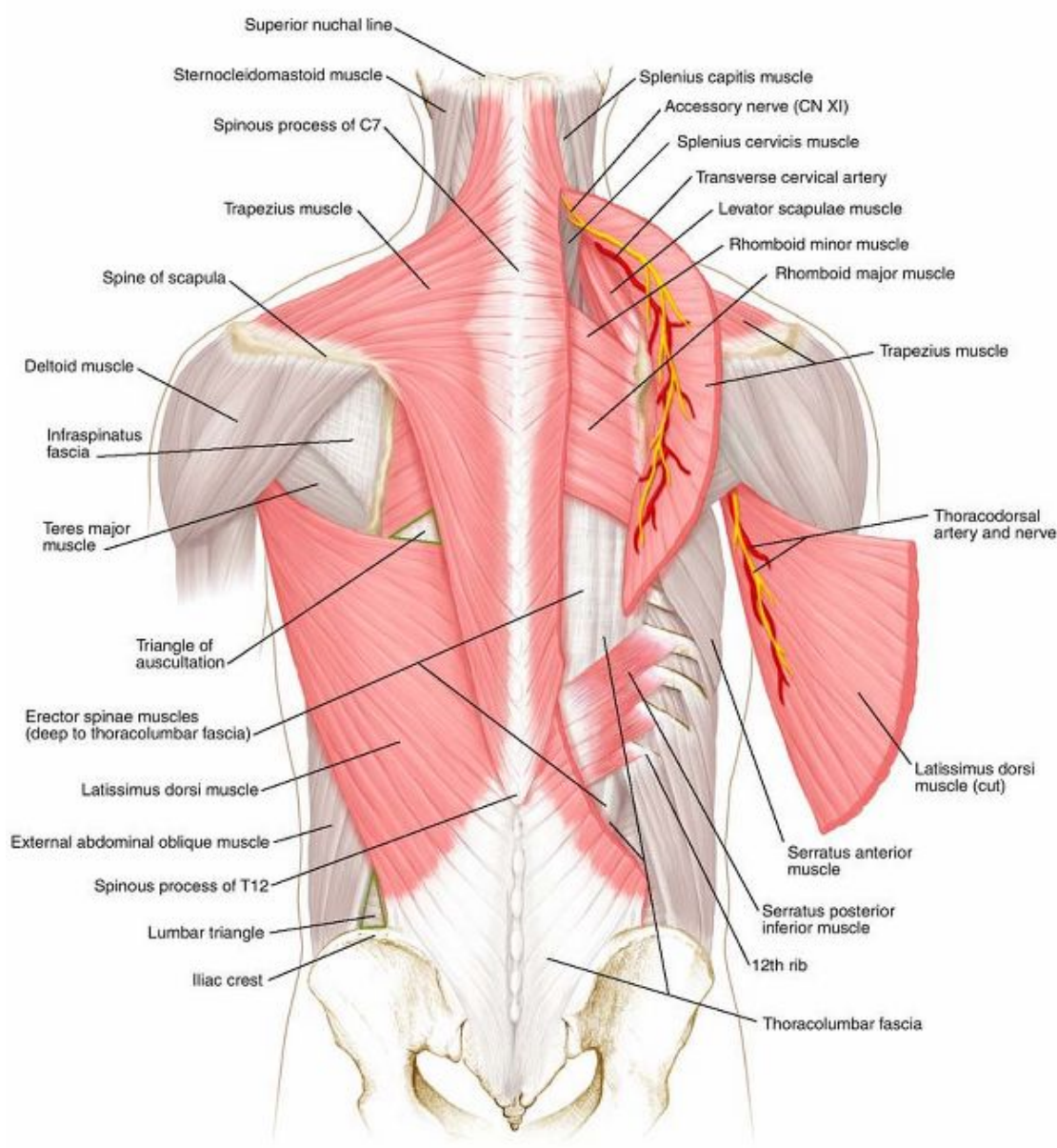
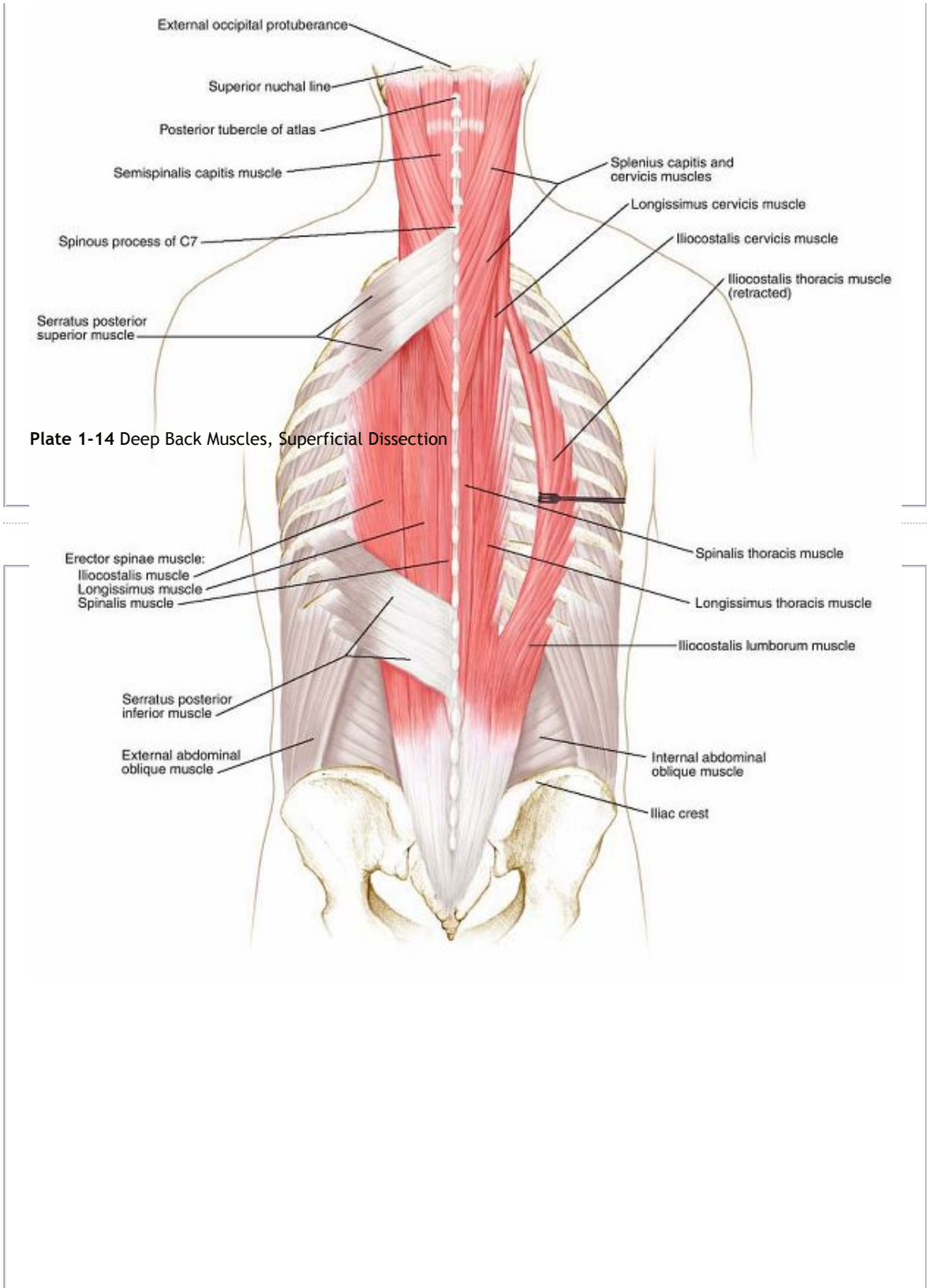


Plate 1-13 Superficial Muscles of the Back



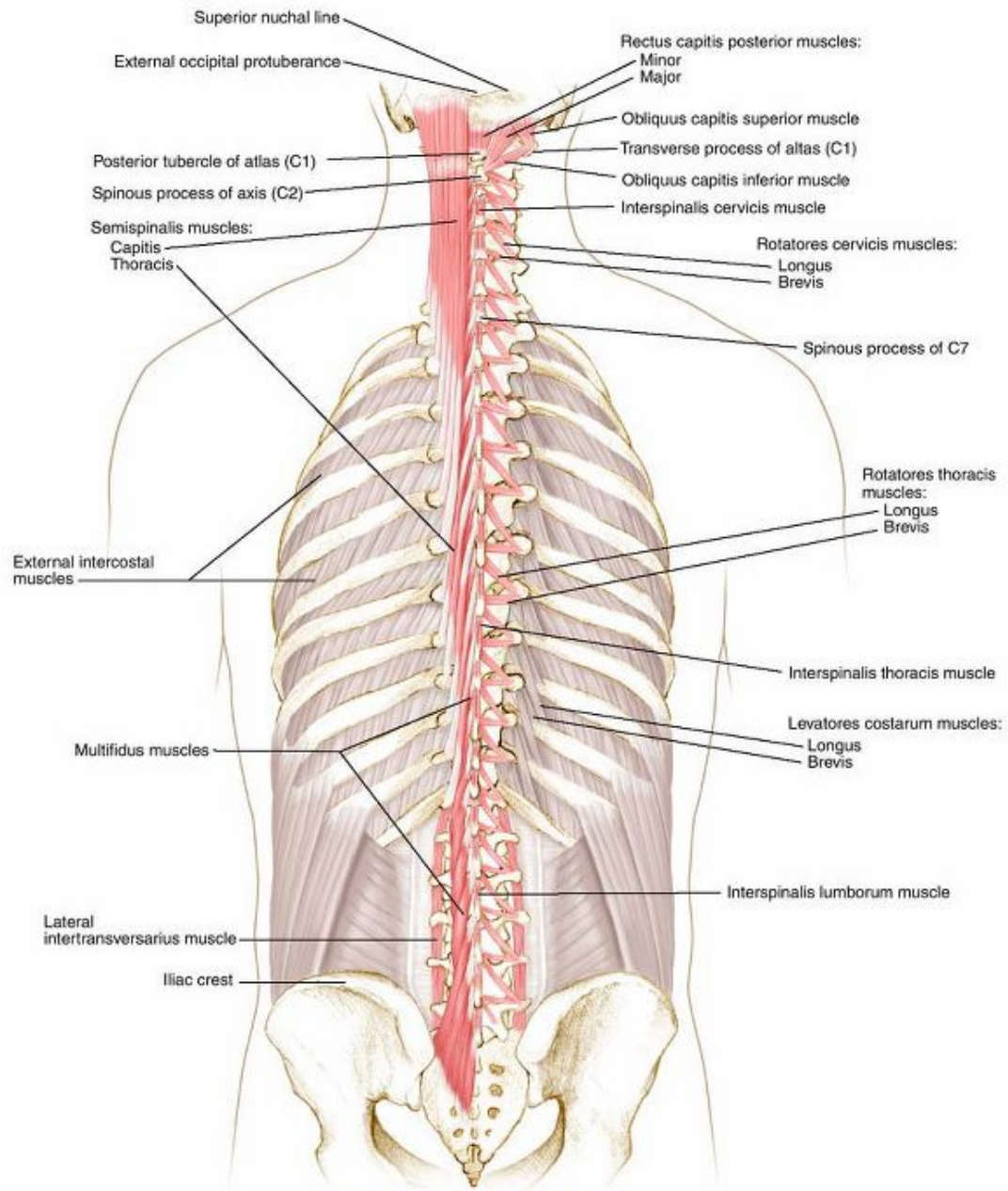


Plate 1-15 Deep Back Muscles, Deeper Dissection

P.20

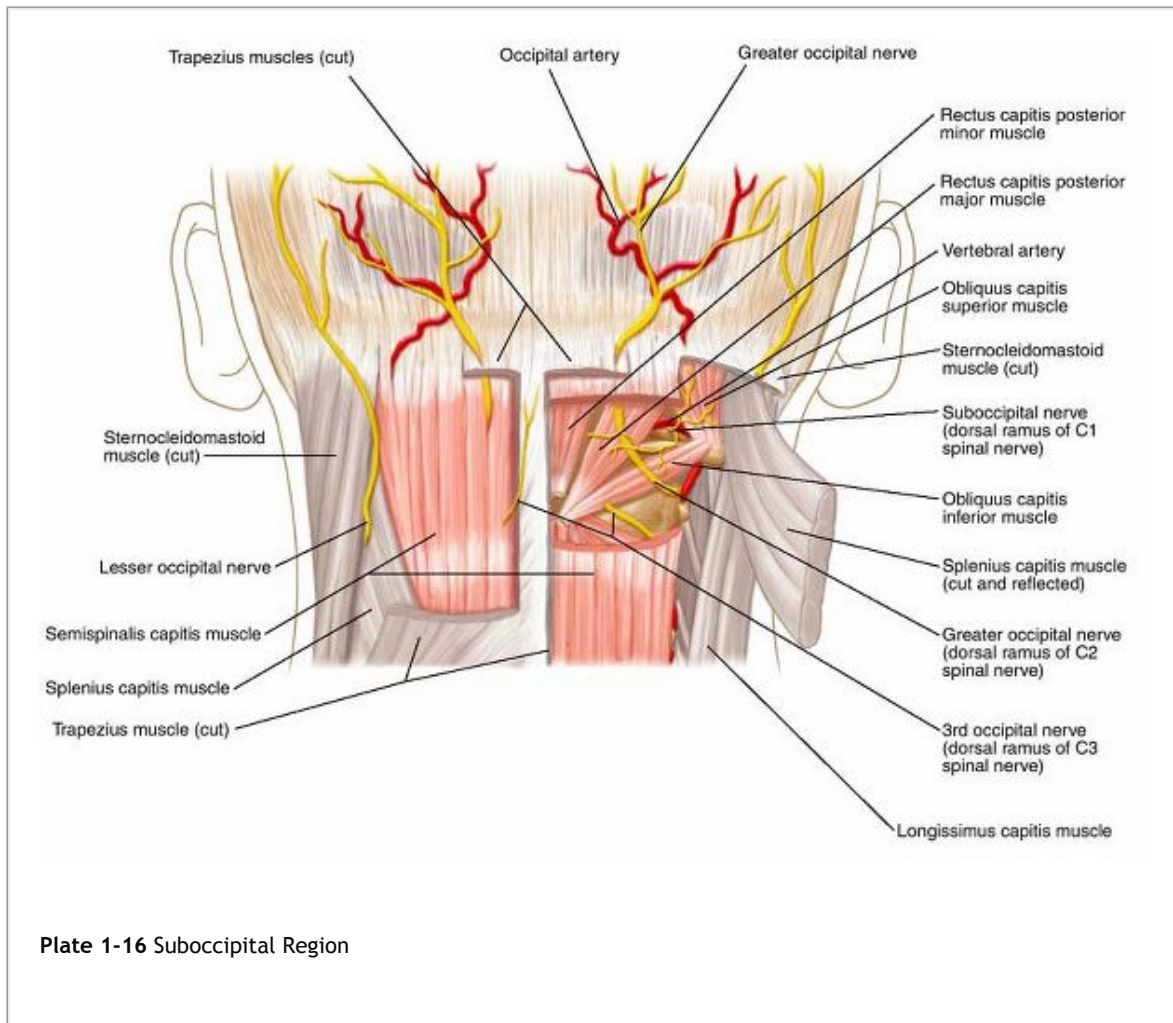
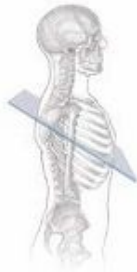

Plate 1-16 Suboccipital Region

P.21

A. Orientation



B. Oblique section

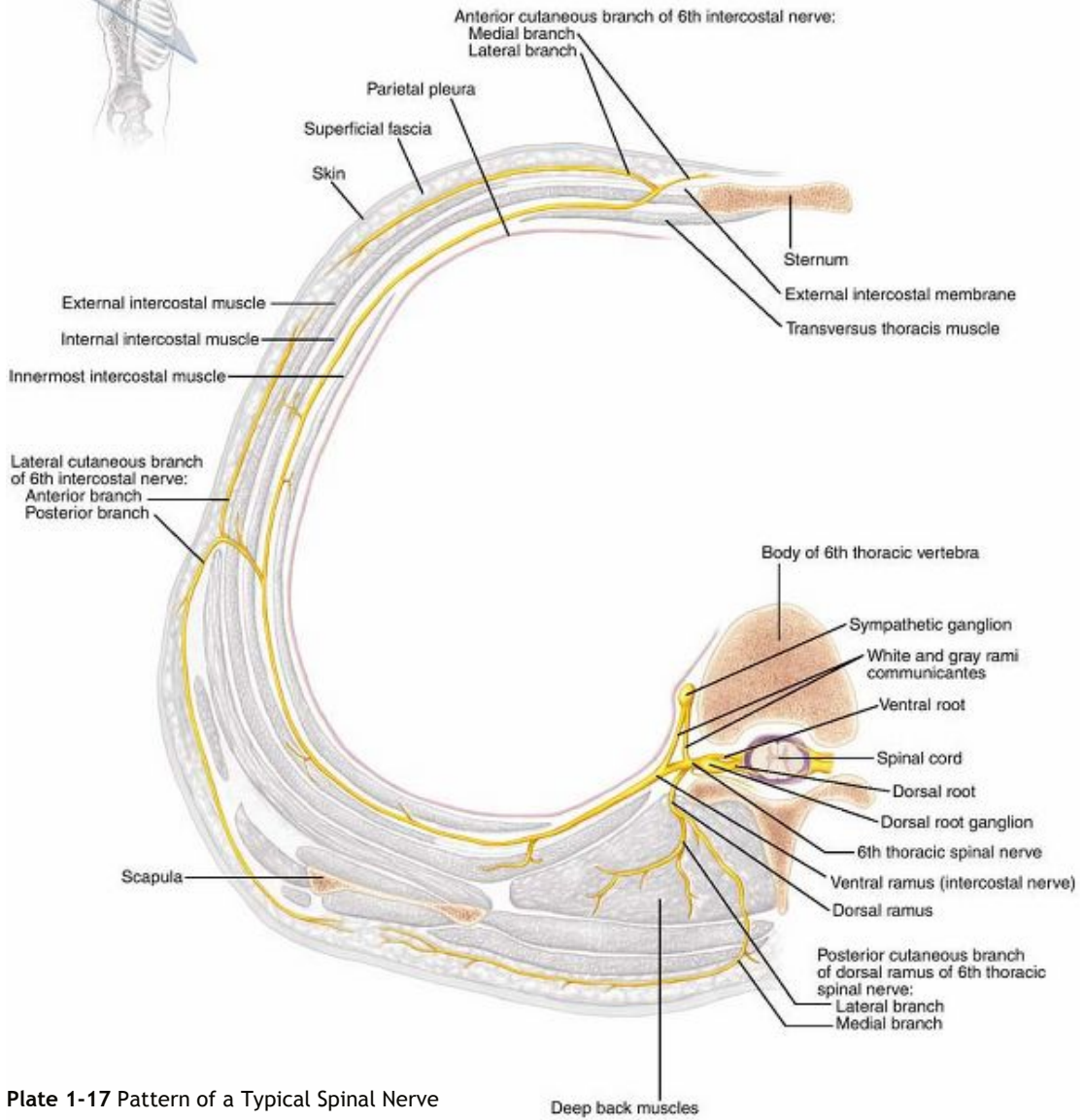


Plate 1-17 Pattern of a Typical Spinal Nerve

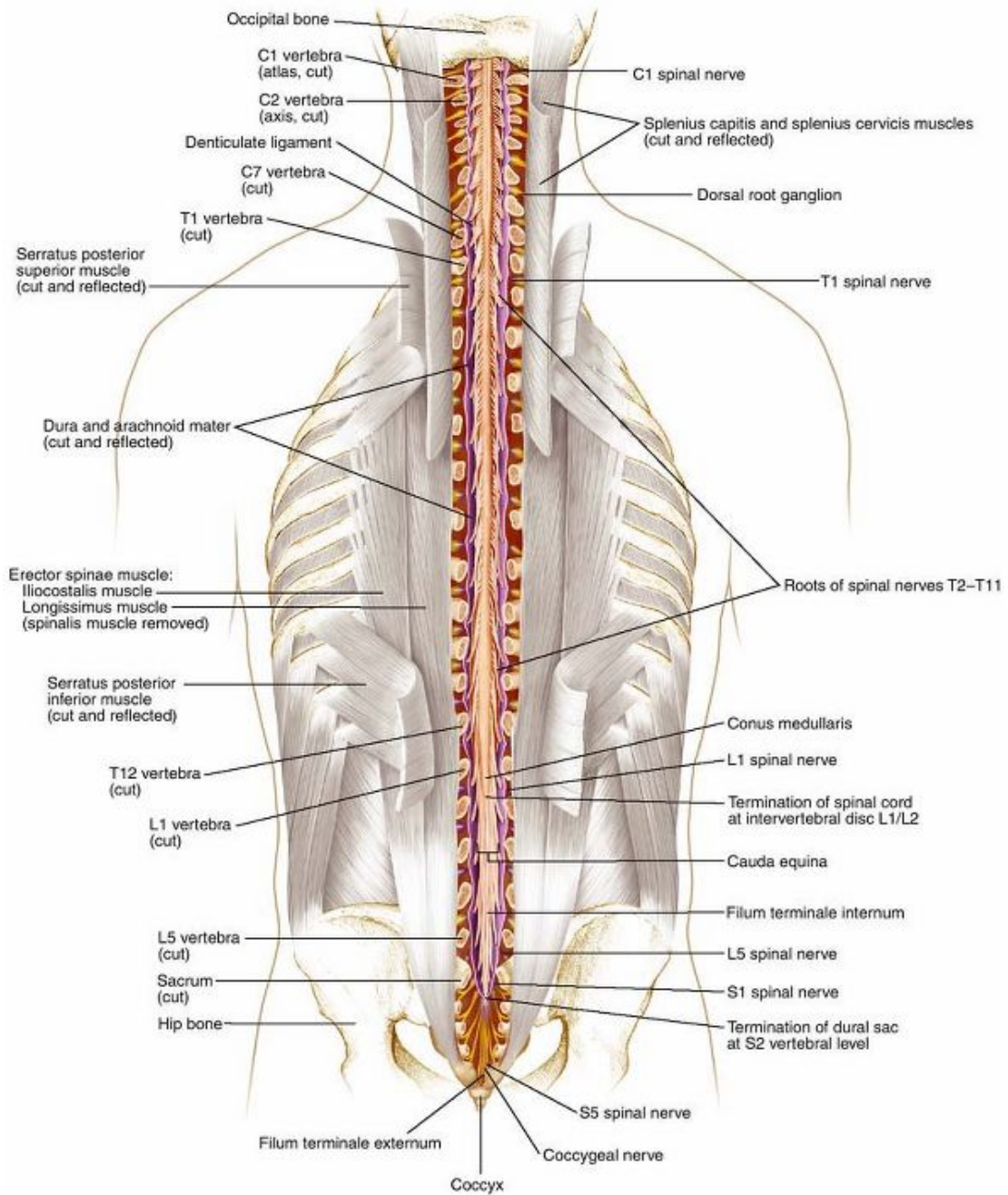
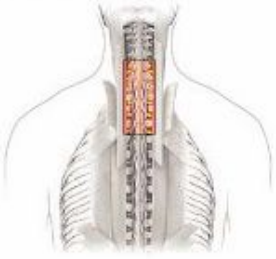


Plate 1-18 Spinal Cord, Posterior View

A. Orientation



B. Dissection

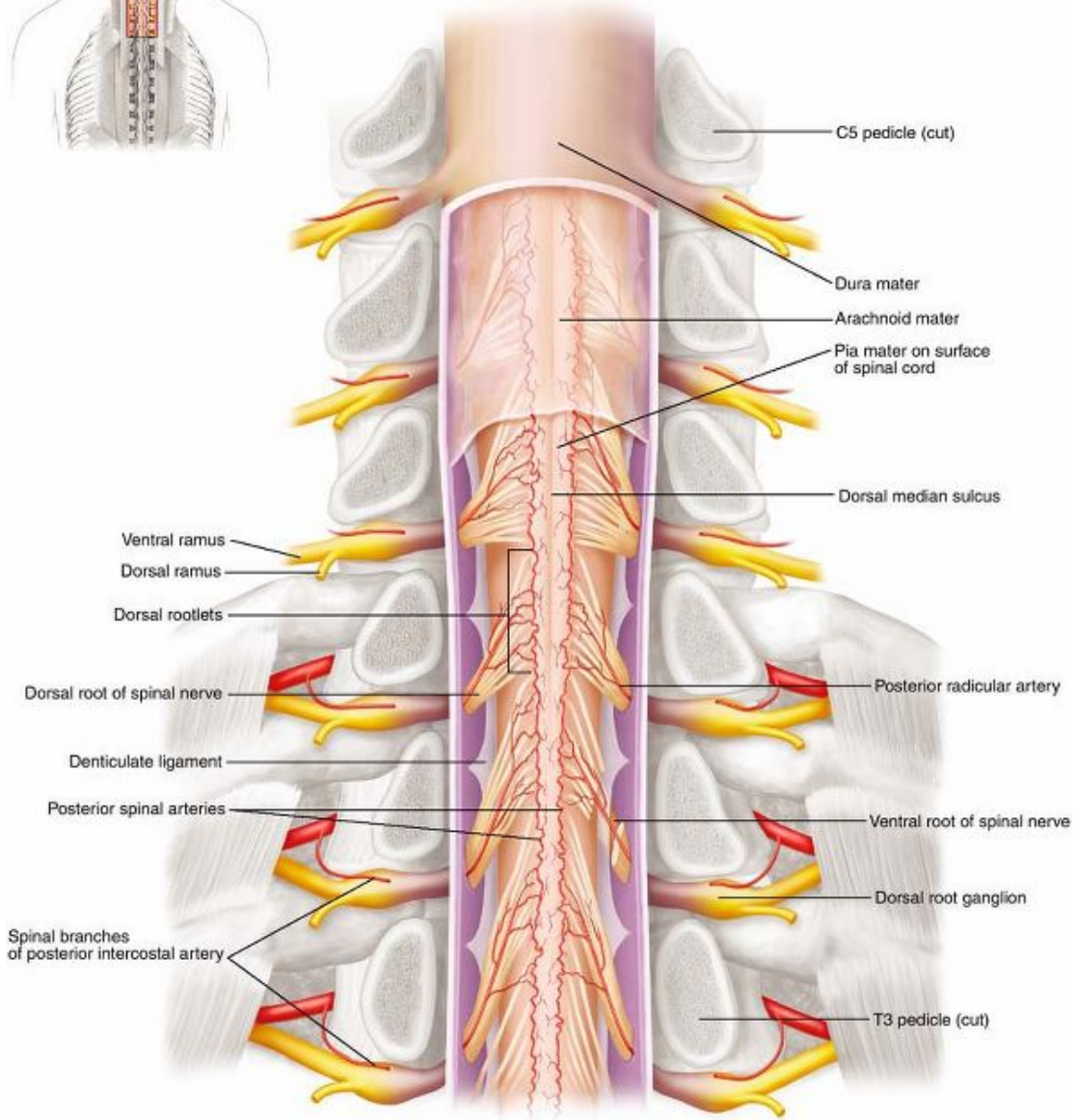
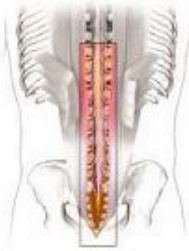

Plate 1-19 Superior Portion of the Spinal Cord

A. Orientation



B. Dissection

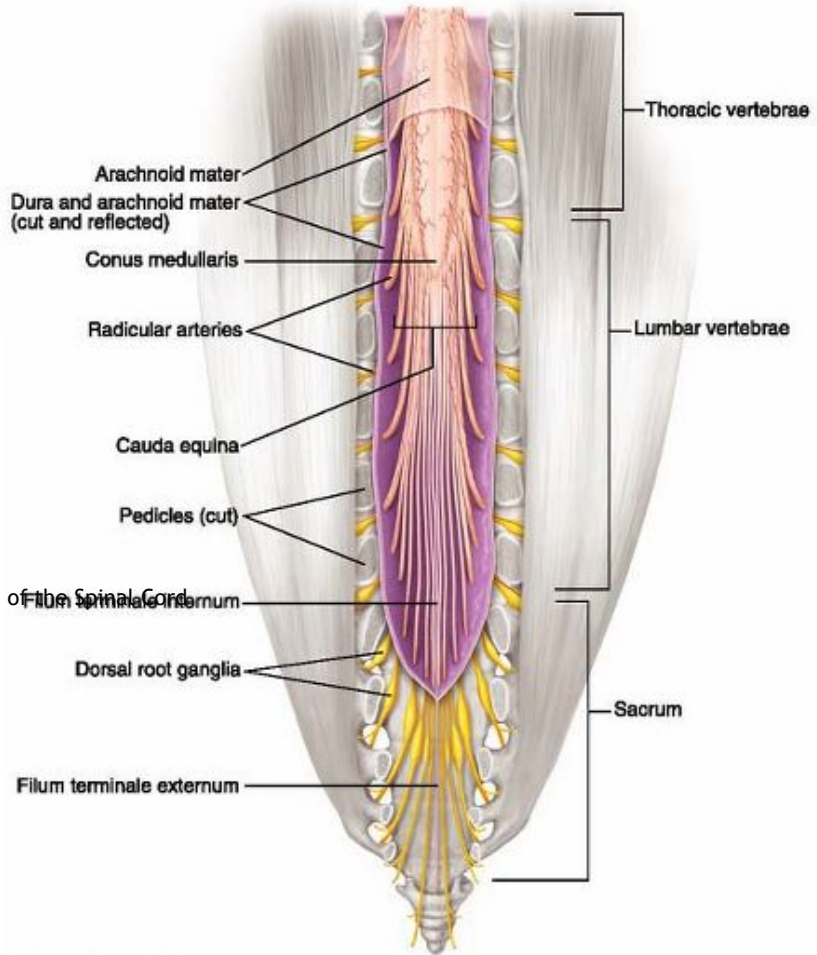
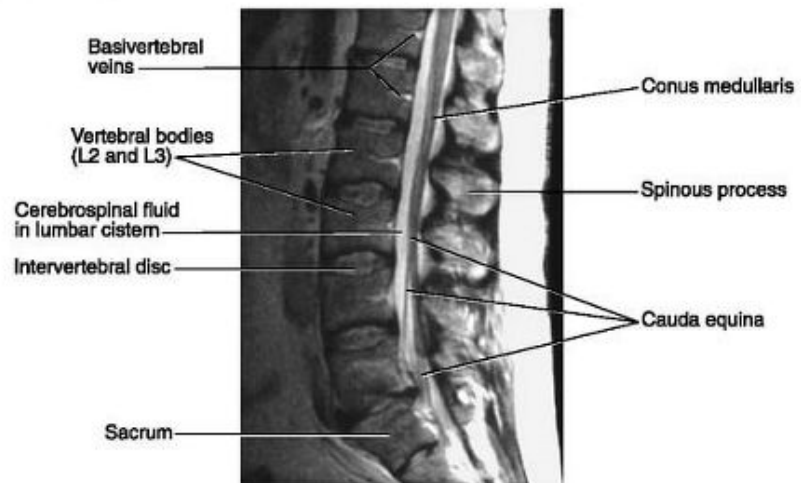


Plate 1-20 Inferior Portion of the Spinal Cord

C. MRI (T2 weighted), sagittal view



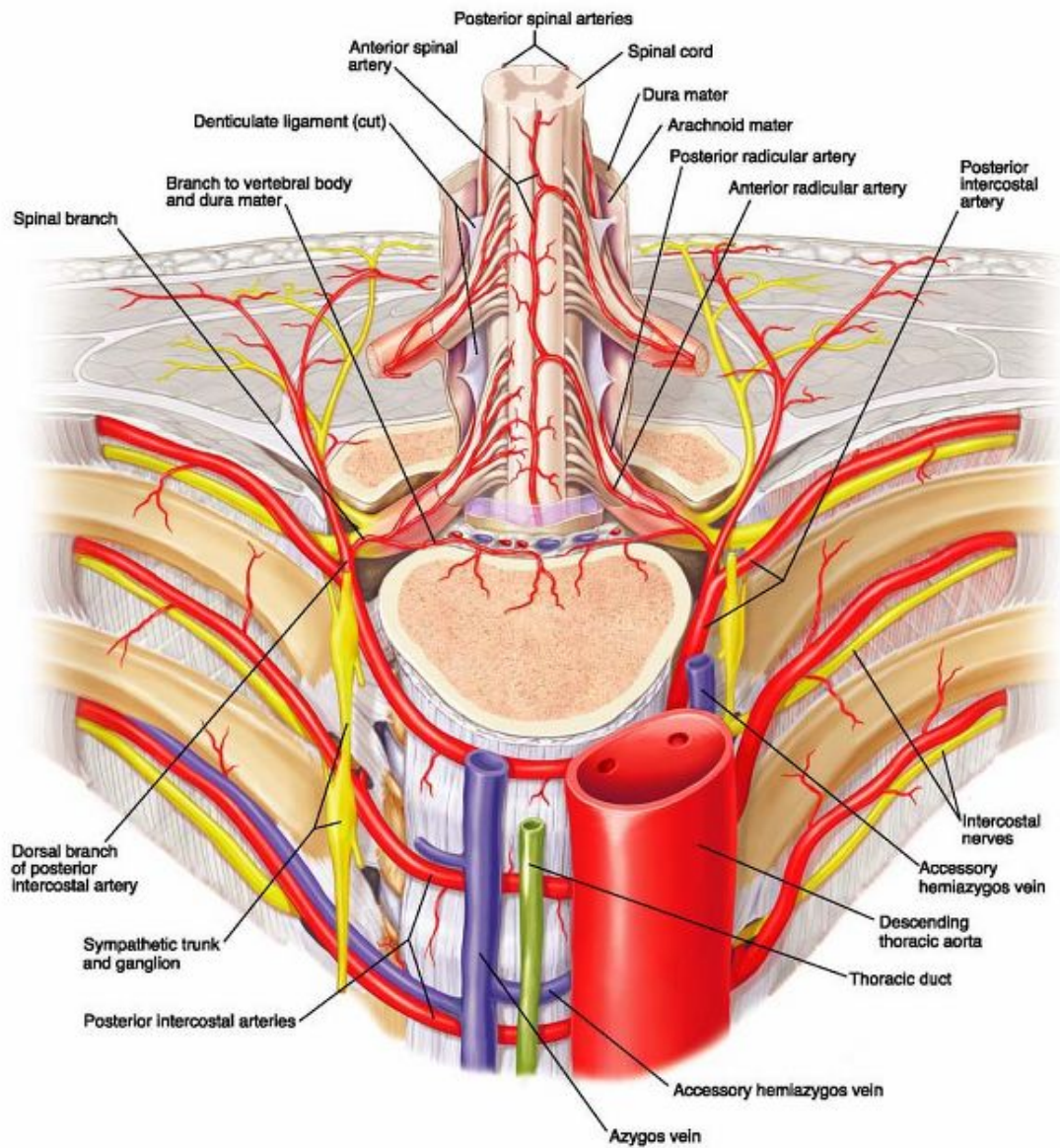
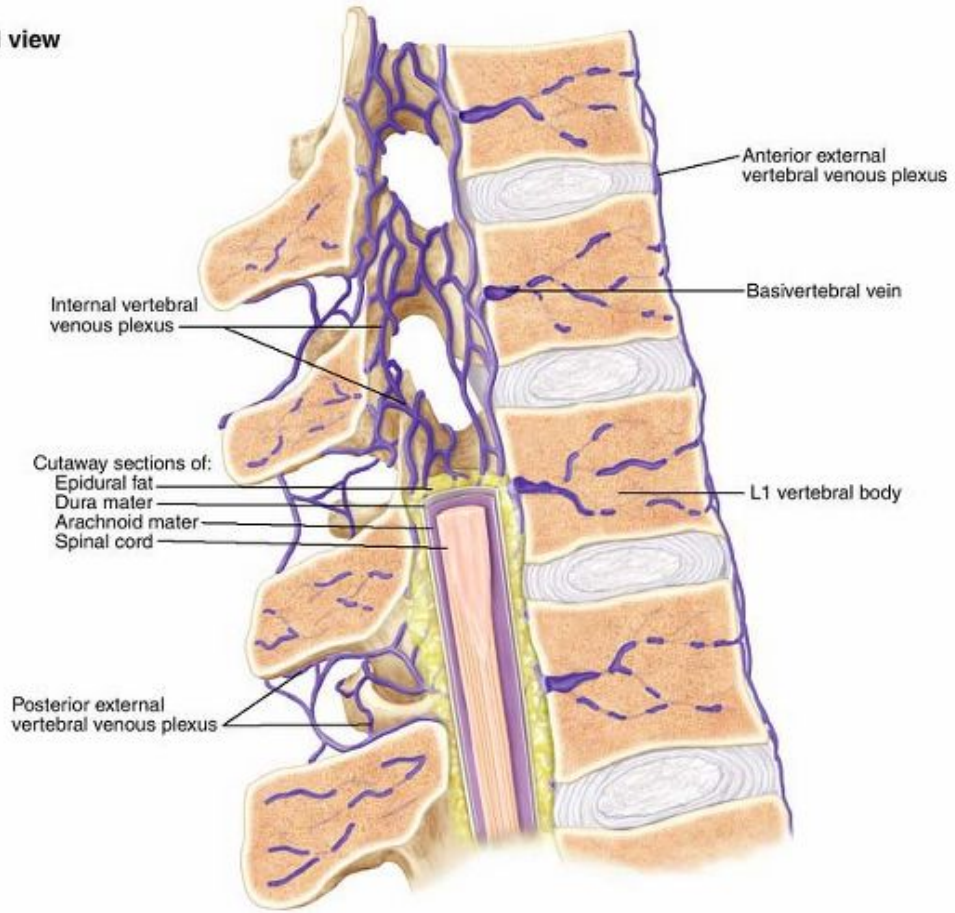


Plate 1-21 Blood Supply of the Spinal Cord, Anterior View

A. Sagittal view



B. Superior view

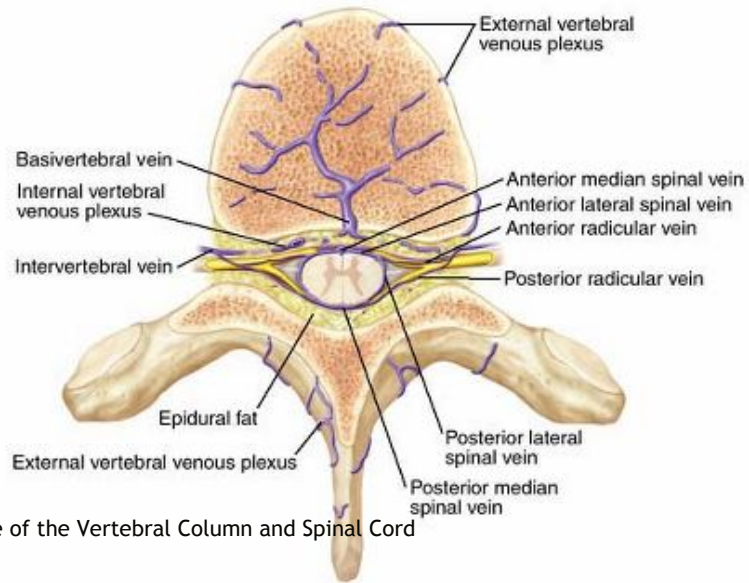


Plate 1-22 Venous Drainage of the Vertebral Column and Spinal Cord

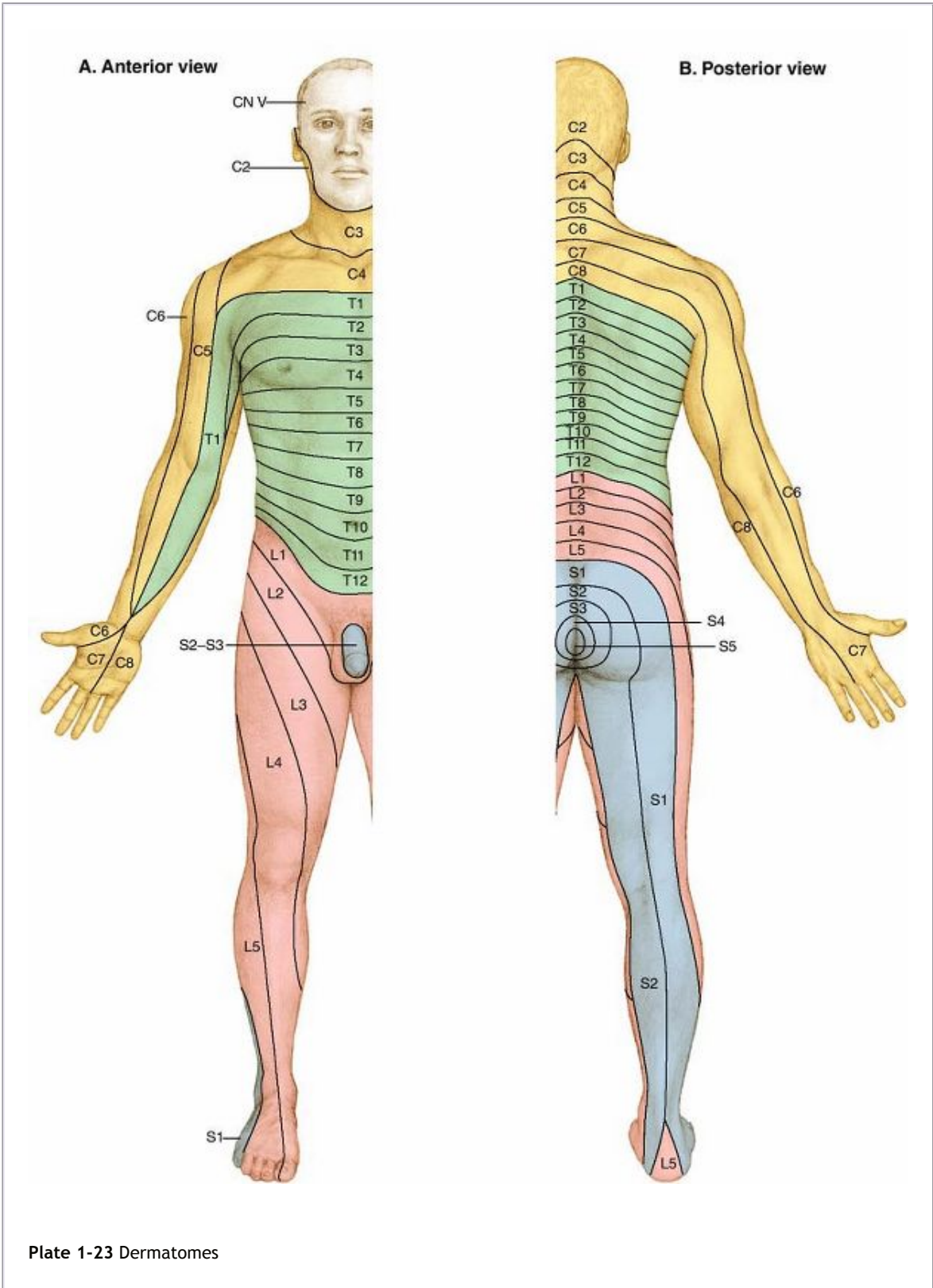


Plate 1-23 Dermatomes

Authors: Tank, Patrick W.; Gest, Thomas R.

Title: *Lippincott Williams & Wilkins Atlas of Anatomy, 1st Edition*

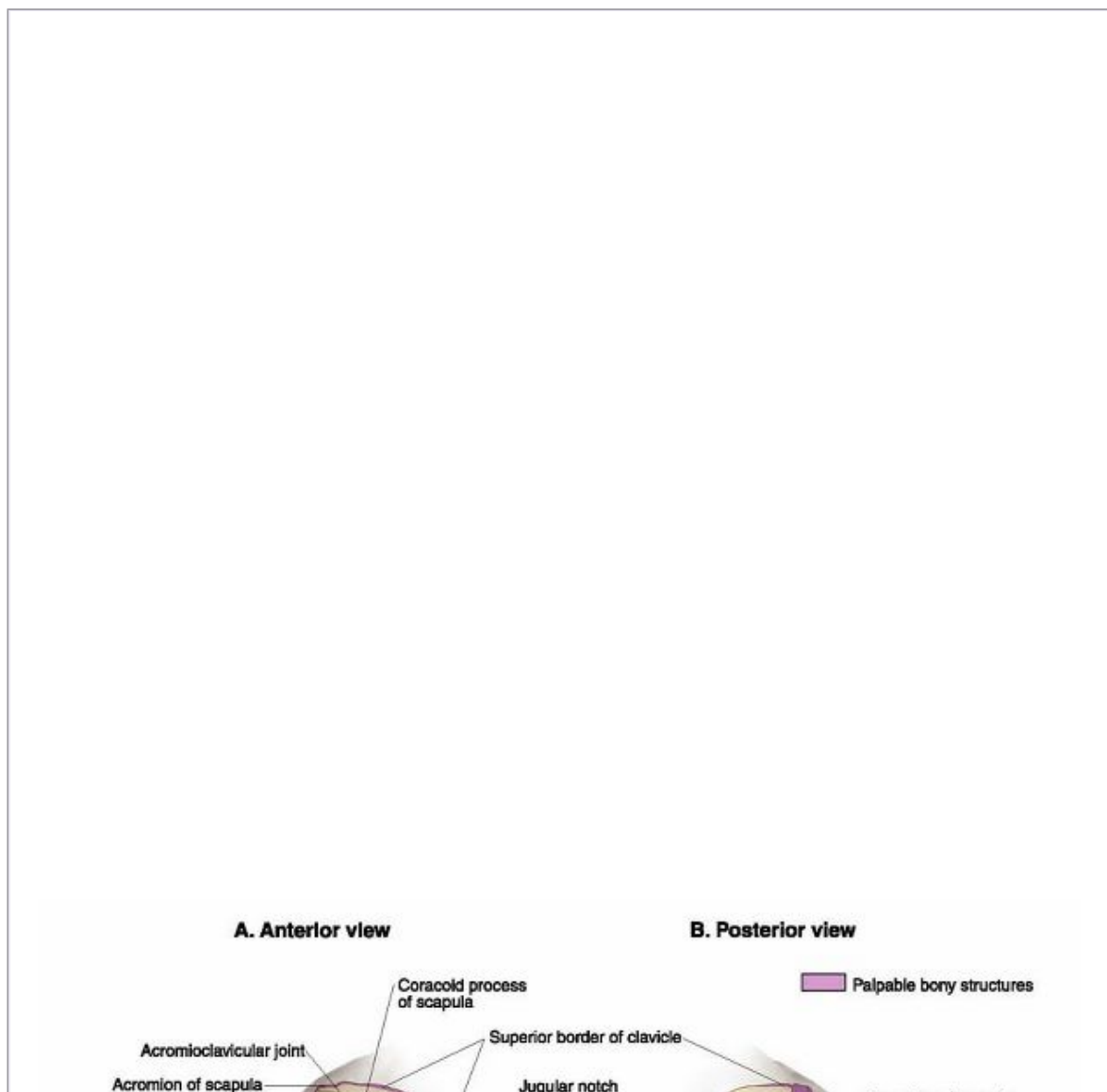
Copyright ©2009 Lippincott Williams & Wilkins

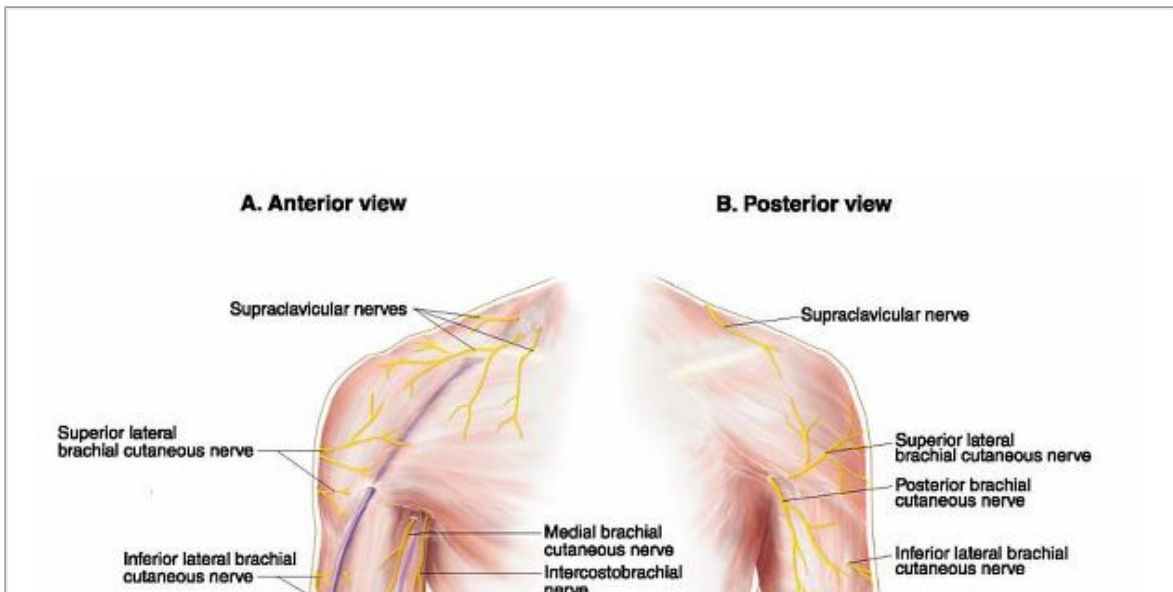
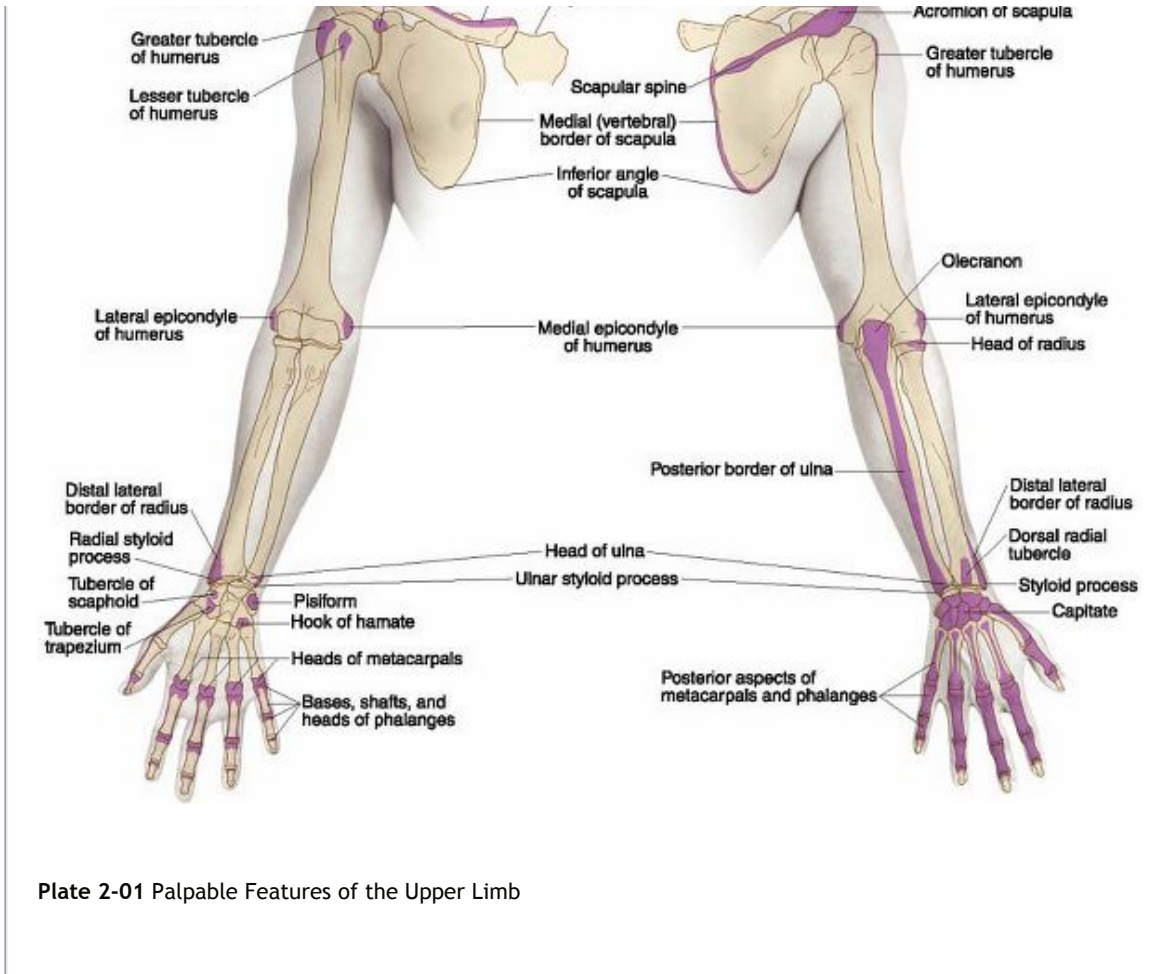
> Table of Contents > Chapter 2 - The Upper Limb

Chapter 2

The Upper Limb

P.30





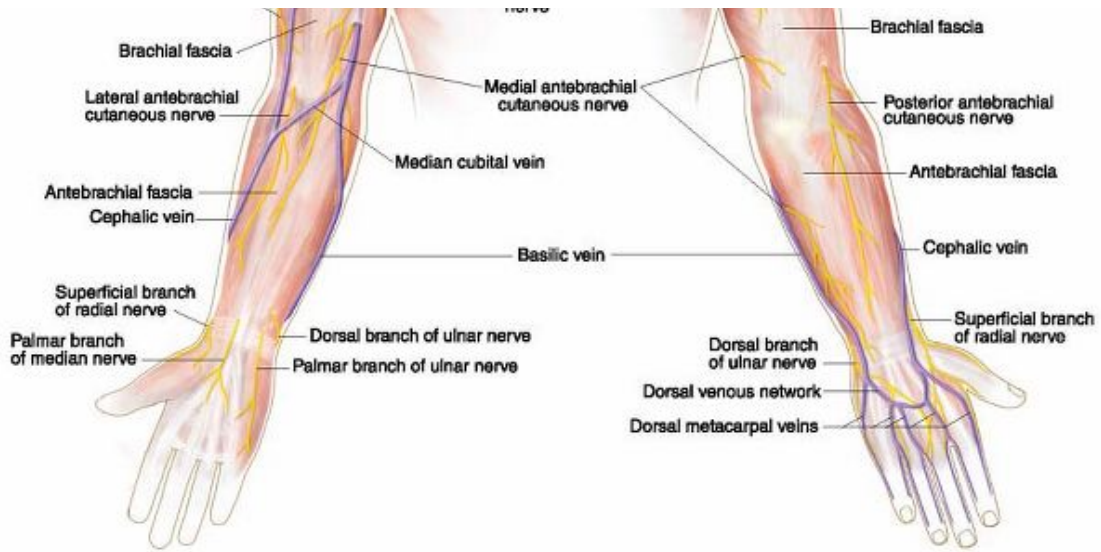
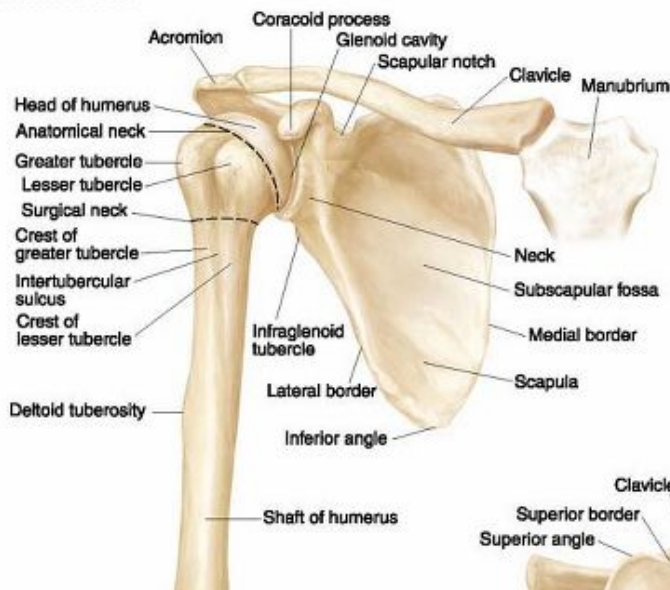
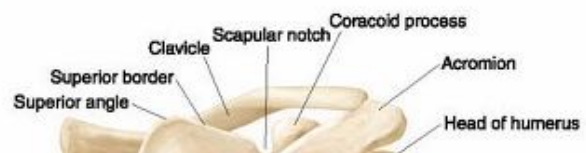


Plate 2-02 Cutaneous Nerves and Superficial Veins of the Upper Limb

A. Anterior view



B. Posterior view



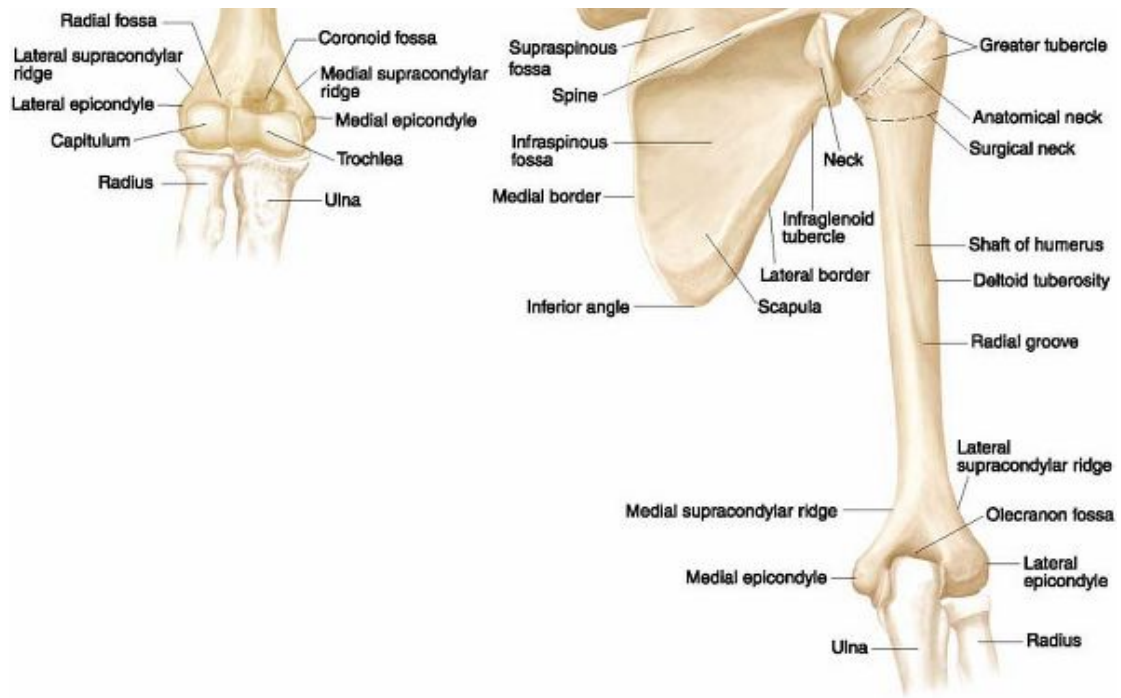
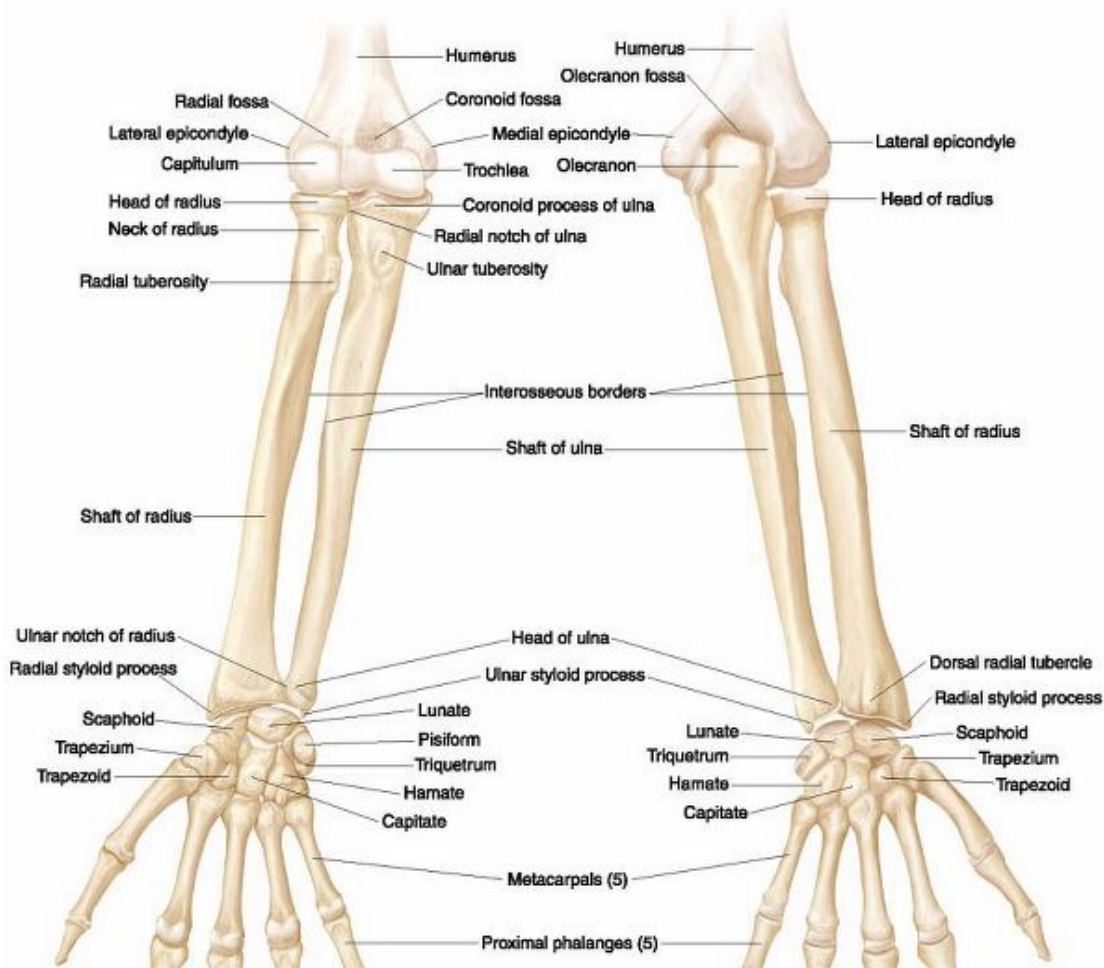


Plate 2-03 Skeleton of the Proximal Upper Limb

A. Anterior view

B. Posterior view



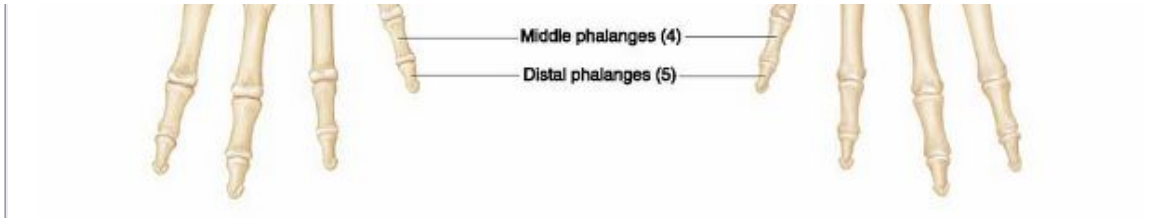
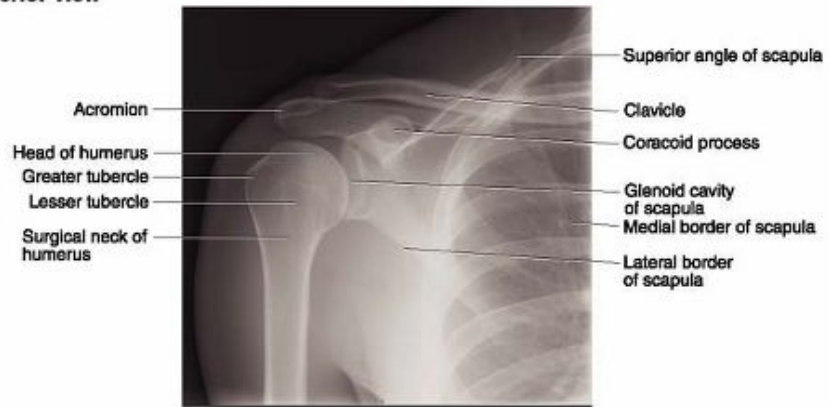
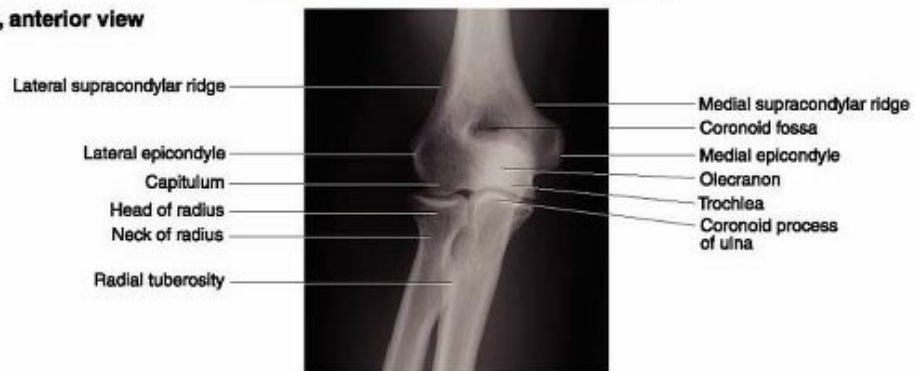
Plate 2-04 Skeleton of the Distal Upper Limb

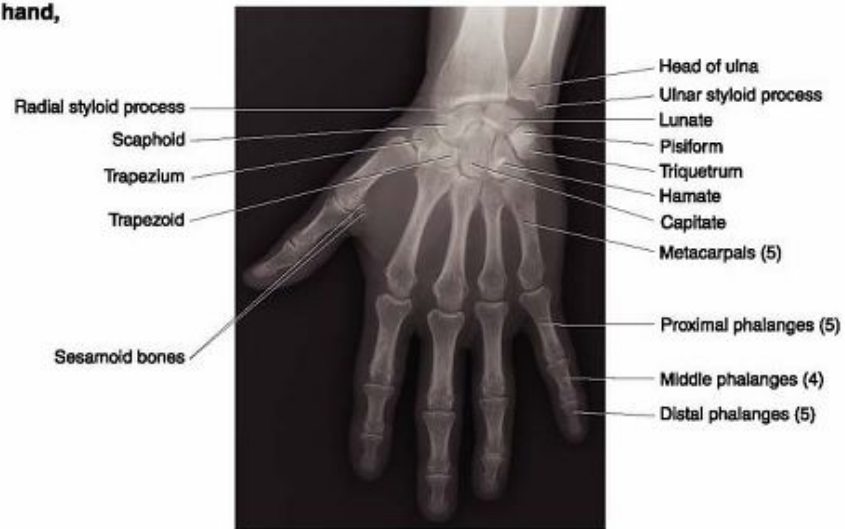
A. Right shoulder, anterior view



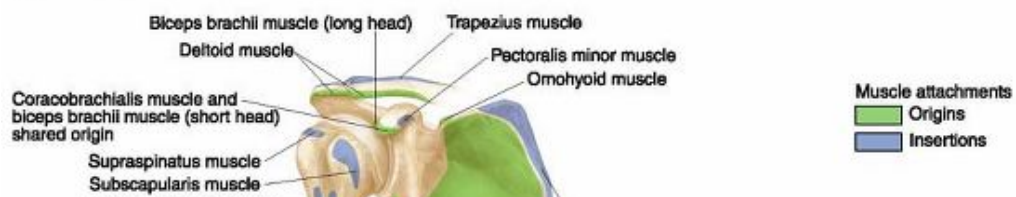B. Right elbow, anterior view



C. Right wrist and hand, anterior view



A. Anterior view



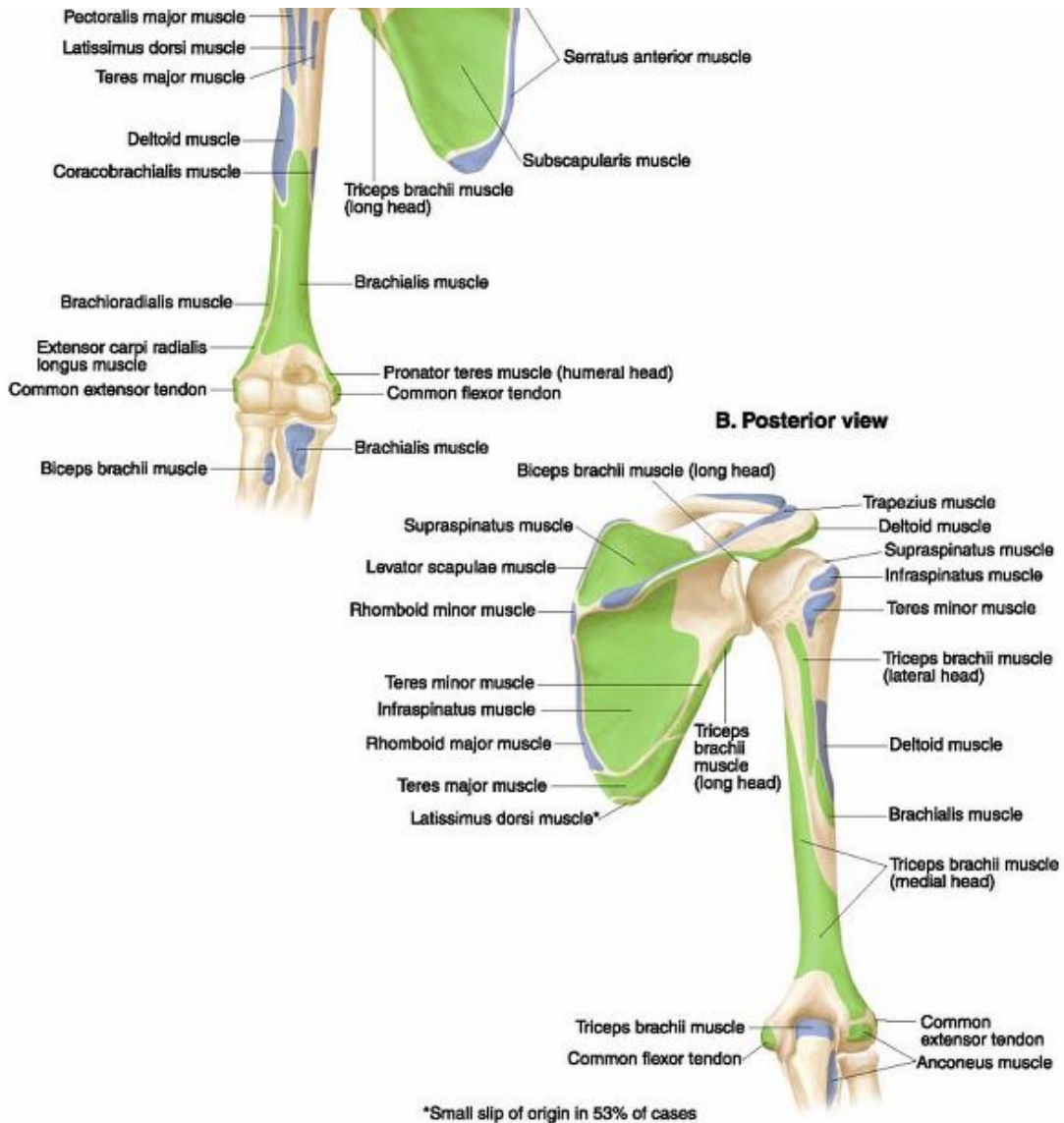
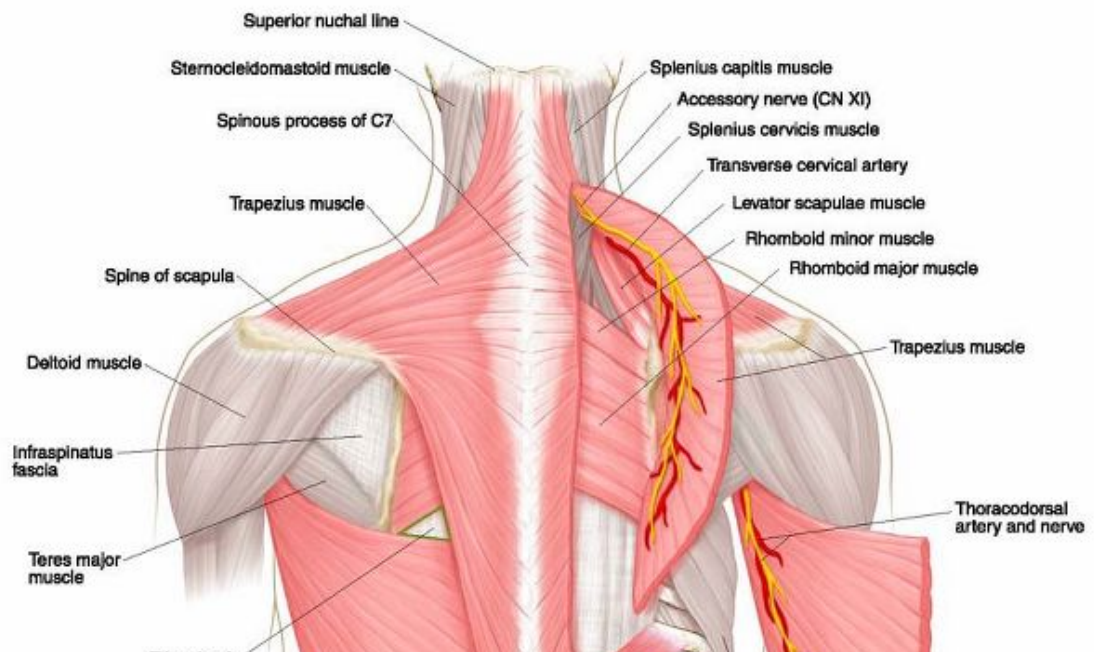


Plate 2-06 Muscle Attachments of the Proximal Upper Limb



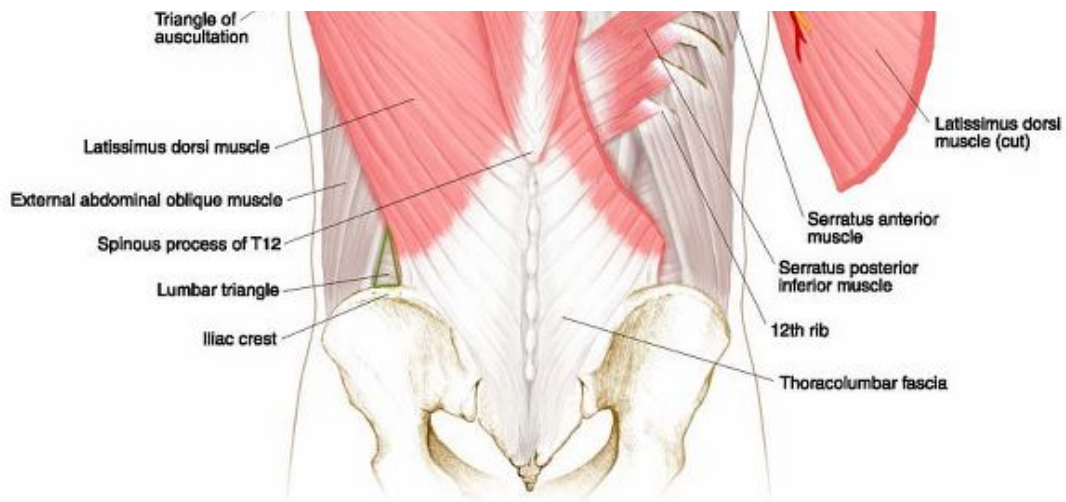
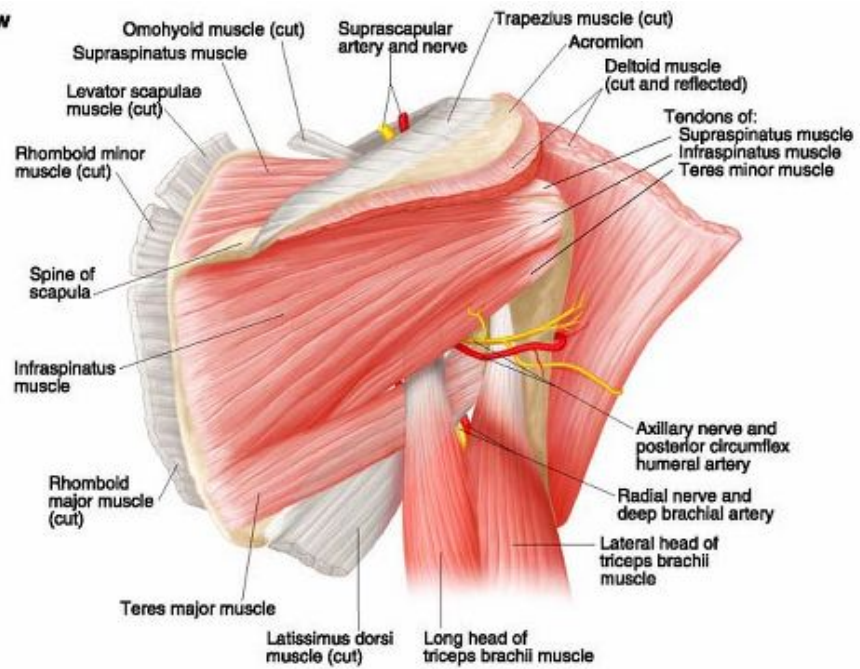
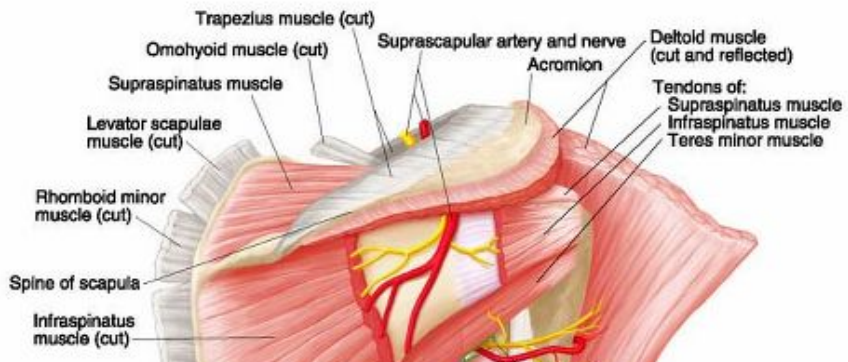


Plate 2-07 Superficial Muscles of the Back

A. Superficial view



B. Deep view



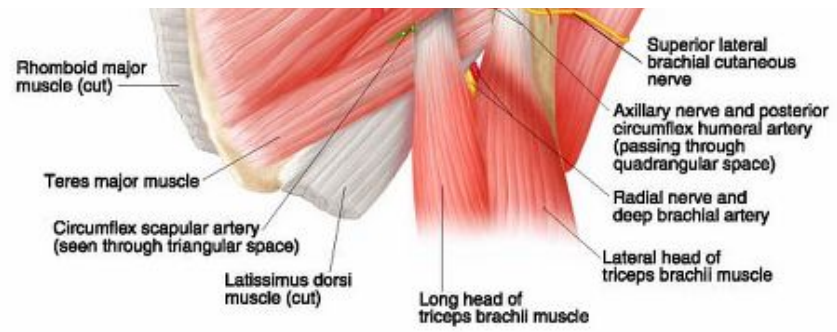
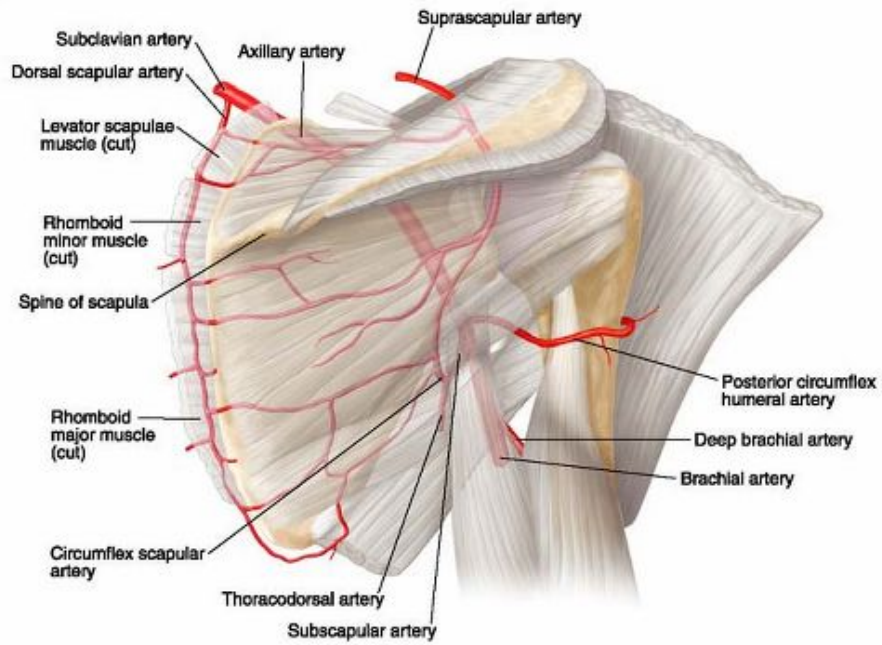


Plate 2-08 Shoulder Muscles

A. Arteries



B. Angiogram

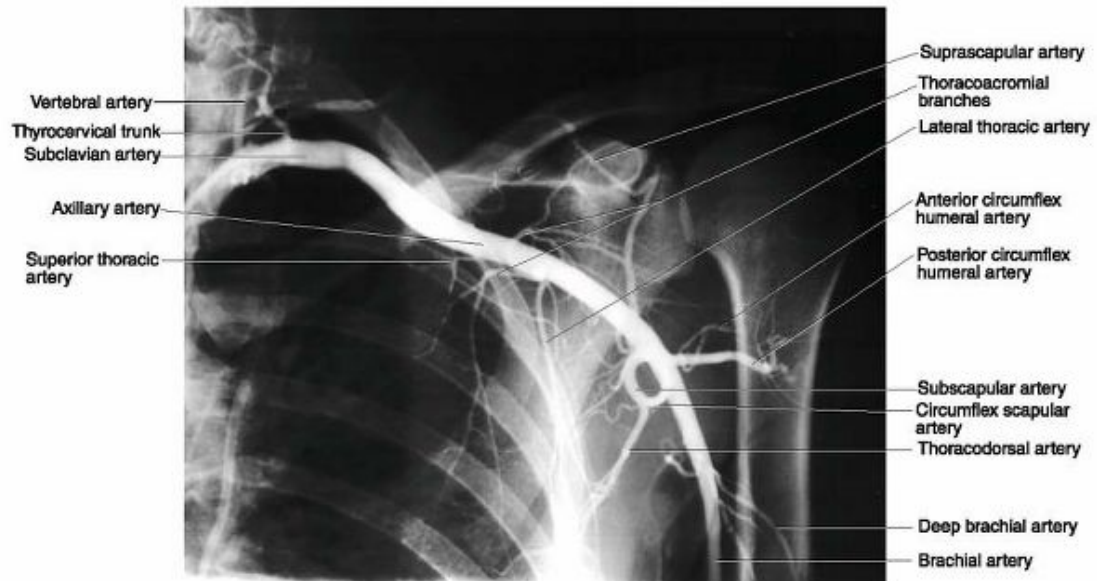
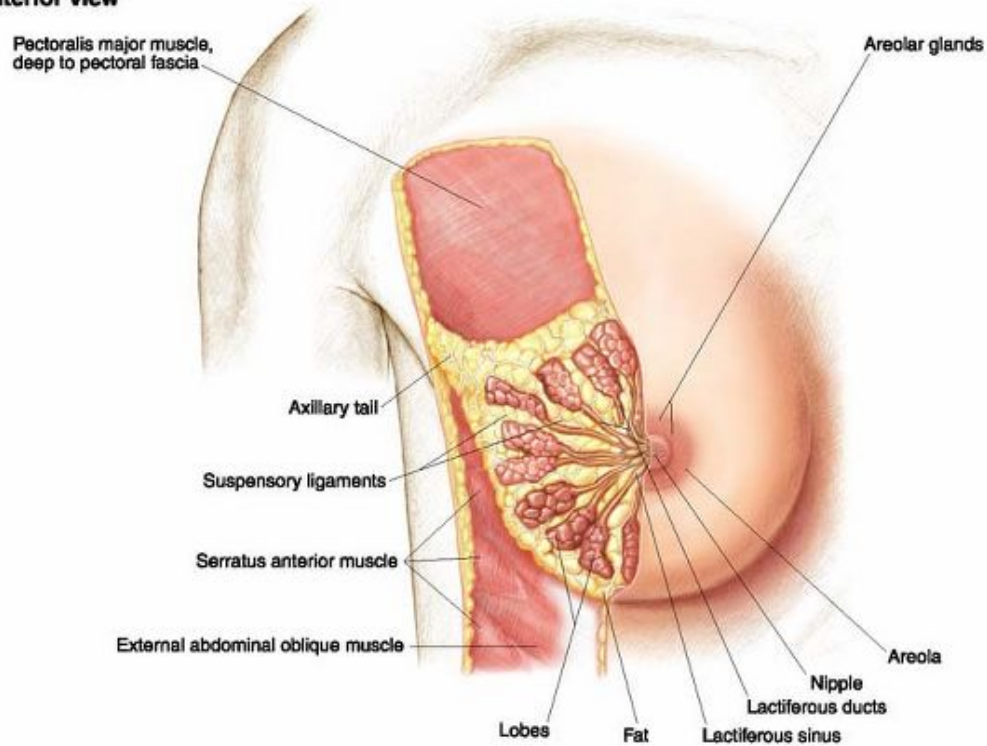
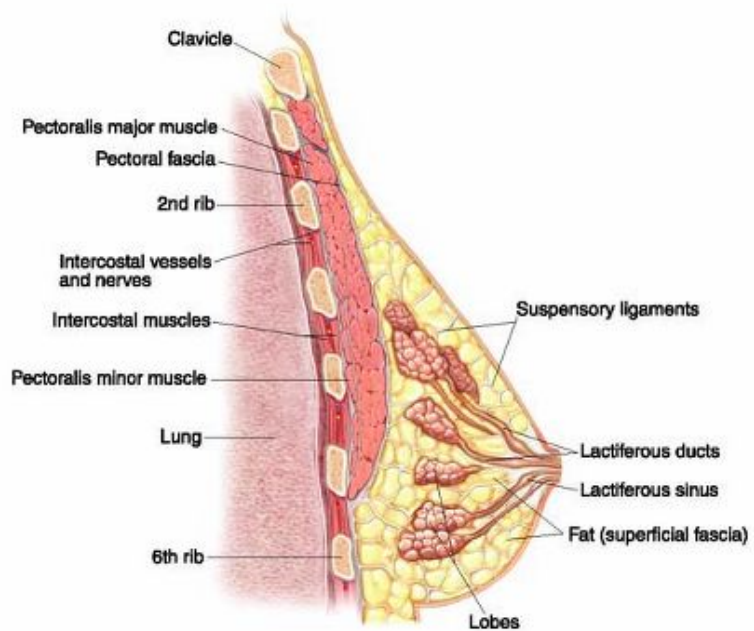


Plate 2-09 Blood Supply to the Shoulder

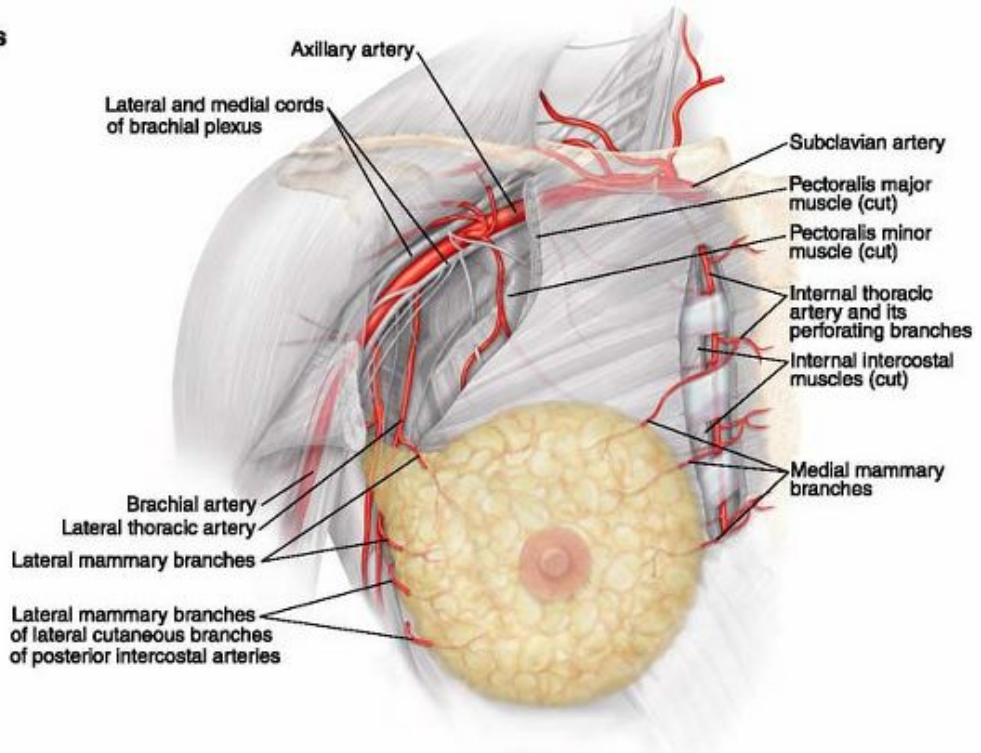
A. Anterior view



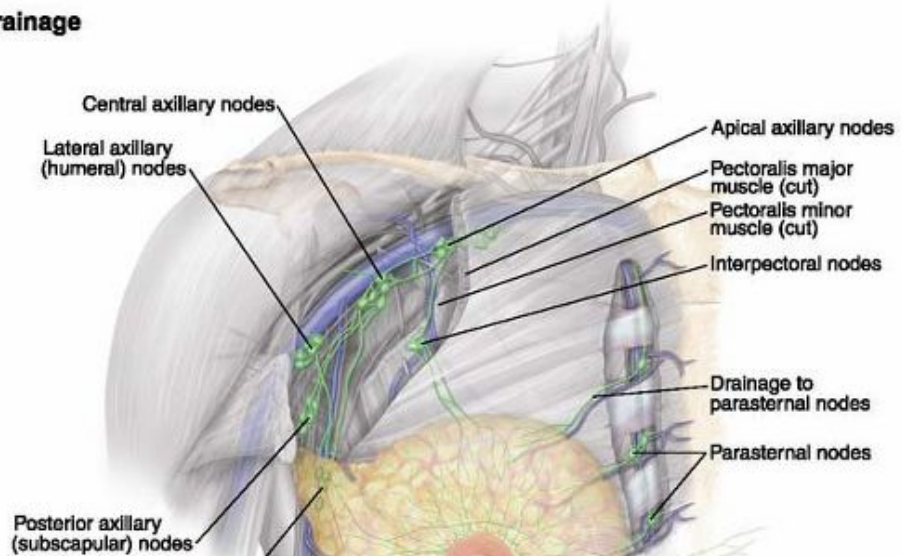
B. Sagittal section



A. Arteries



B. Lymphatic drainage



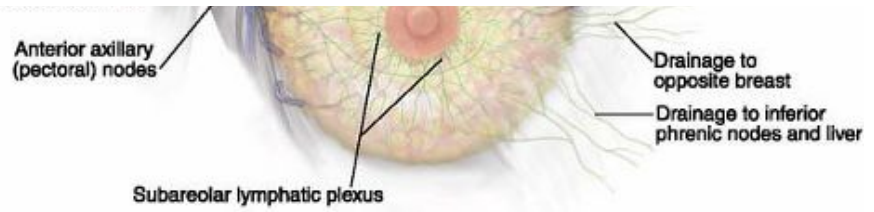
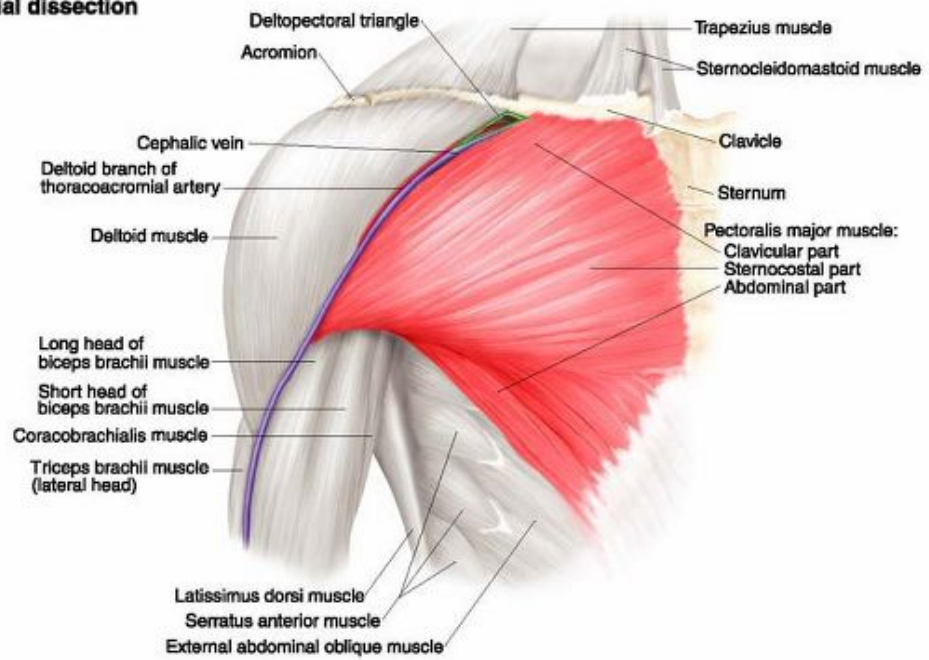


Plate 2-11 Blood Supply and Lymphatic Drainage of the Breast

A. Superficial dissection



B. Deep dissection

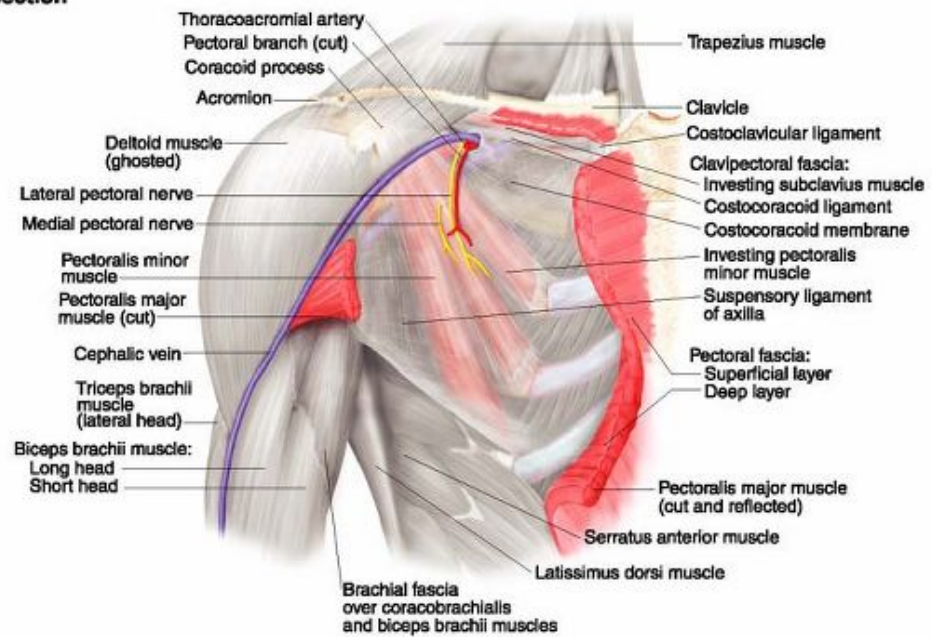


Plate 2-12 Pectoral Muscles

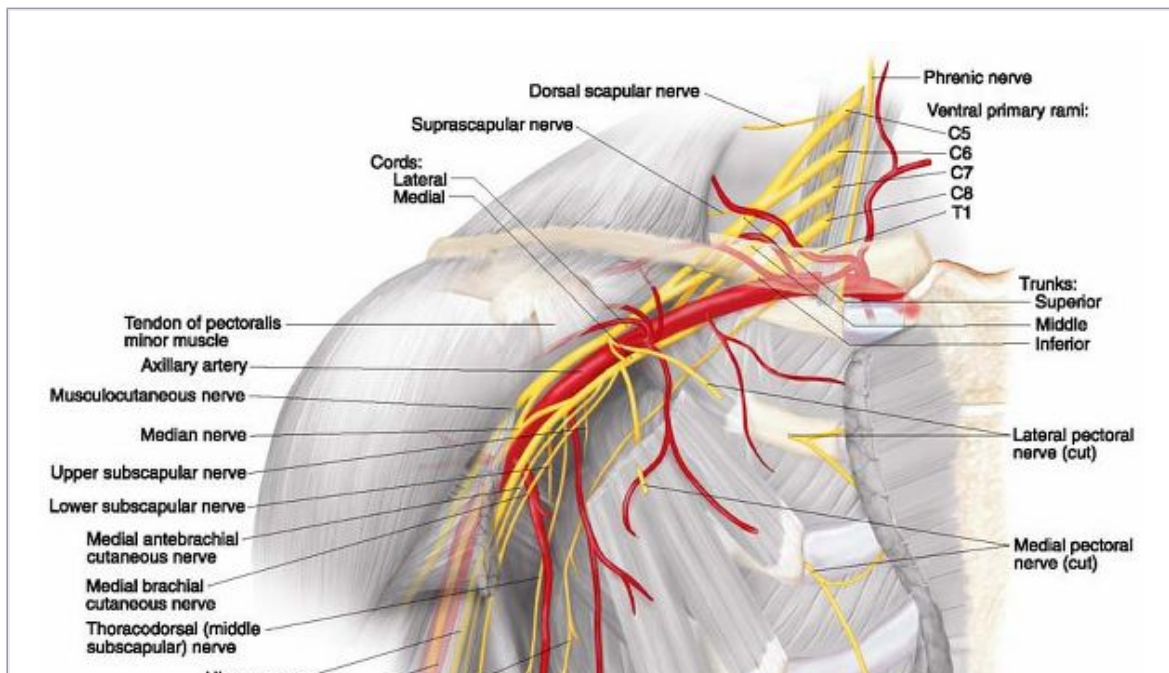
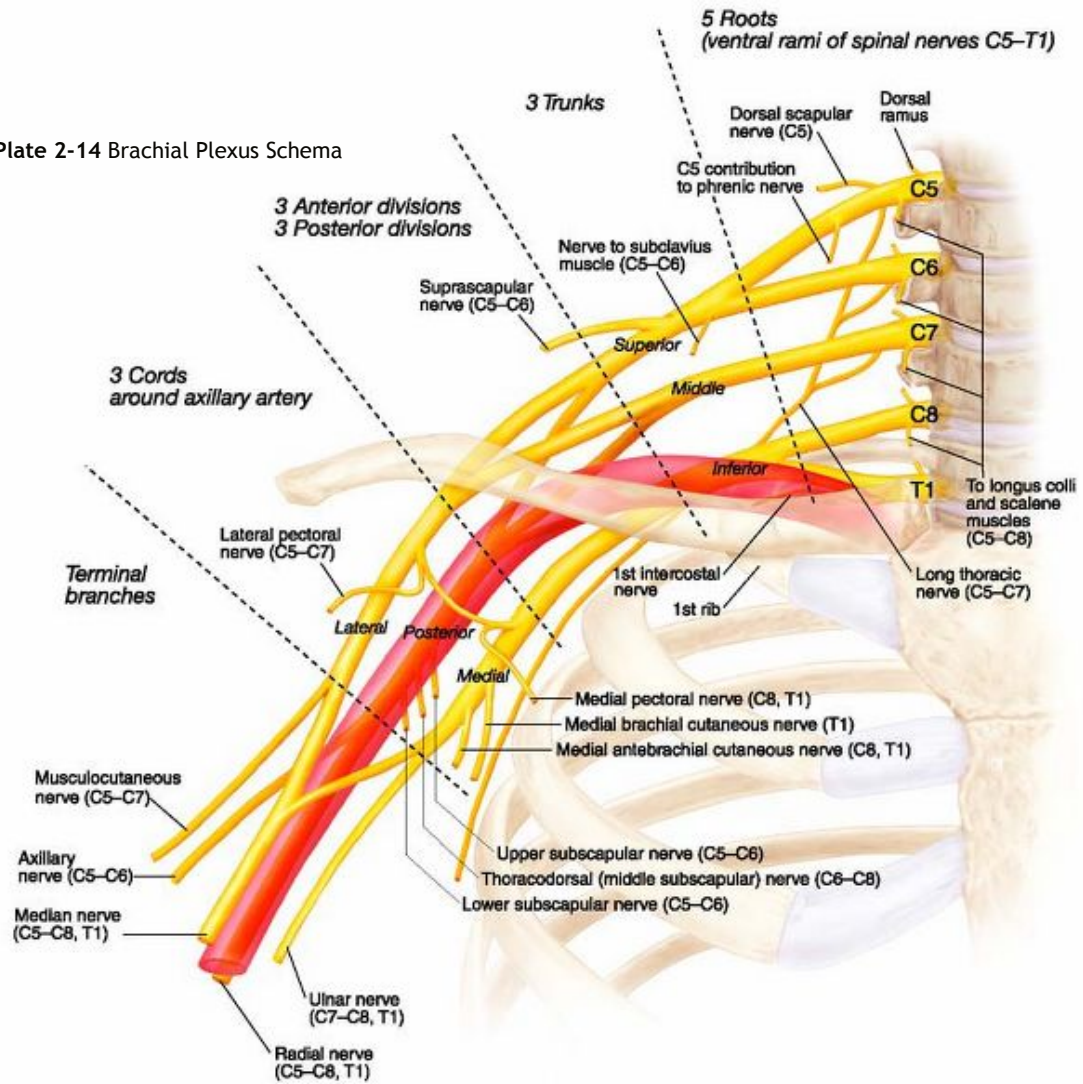




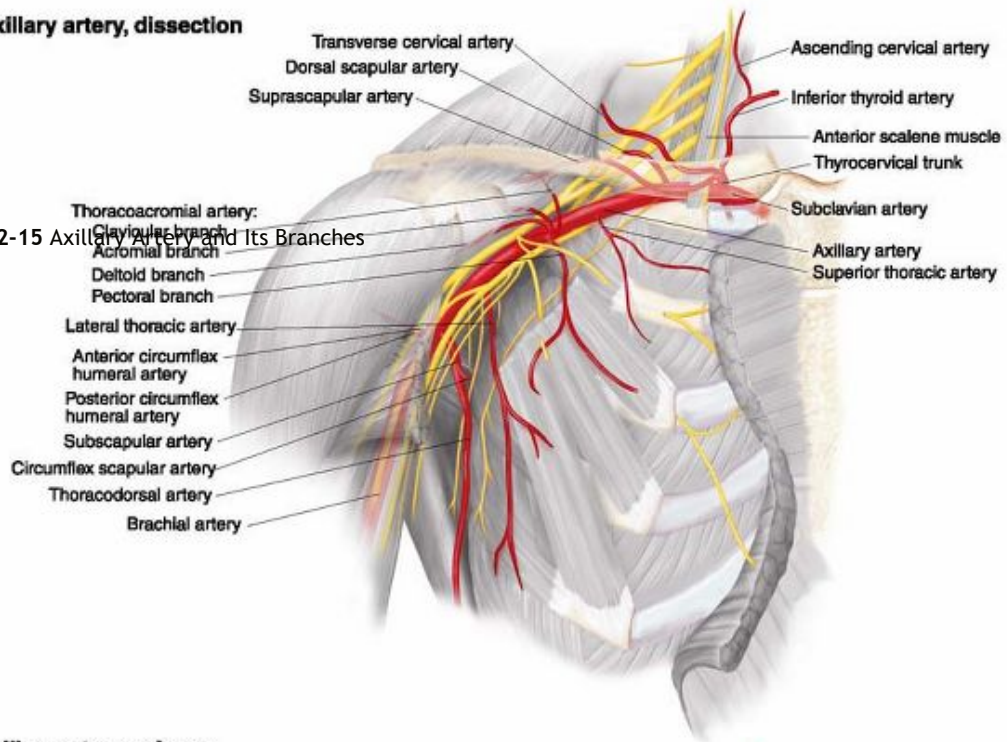
Plate 2-13 Brachial Plexus and Nerves of the Axilla

Plate 2-14 Brachial Plexus Schema



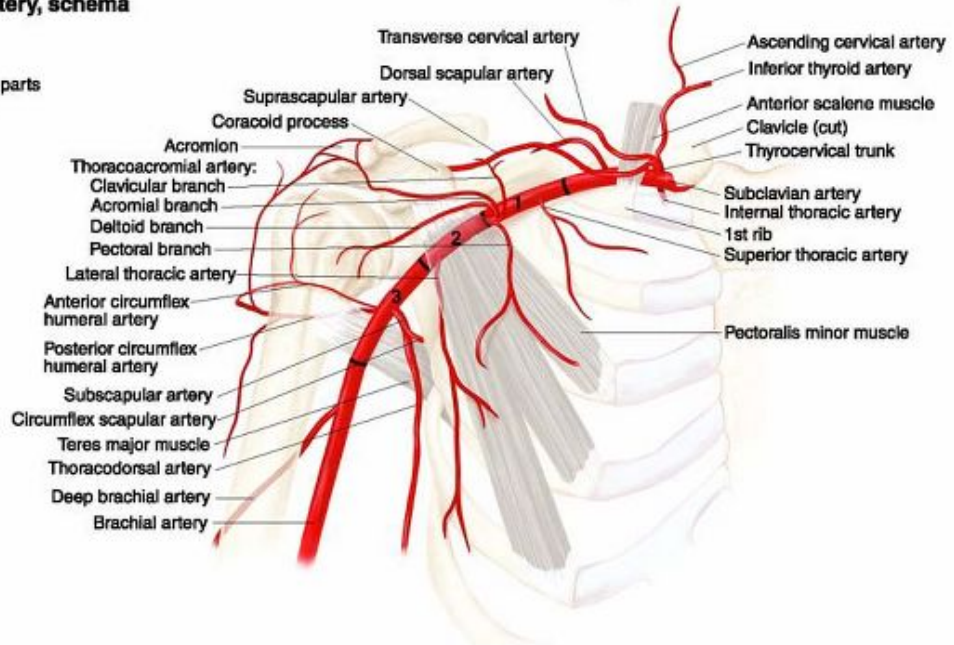
A. Axillary artery, dissection

Plate 2-15 Axillary Artery and Its Branches

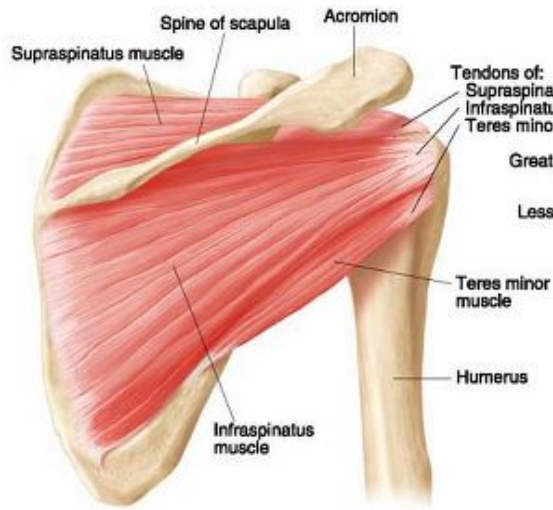


B. Axillary artery, schema

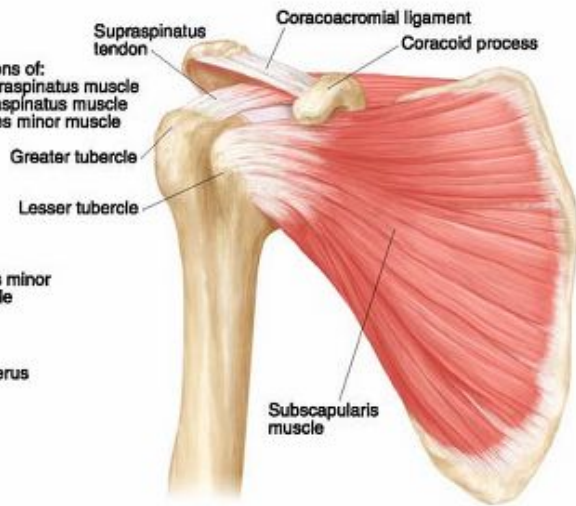
1, 2, 3 indicate
1st, 2nd, and 3rd parts
of axillary artery



A. Posterior view



B. Anterior view



C. Superolateral view

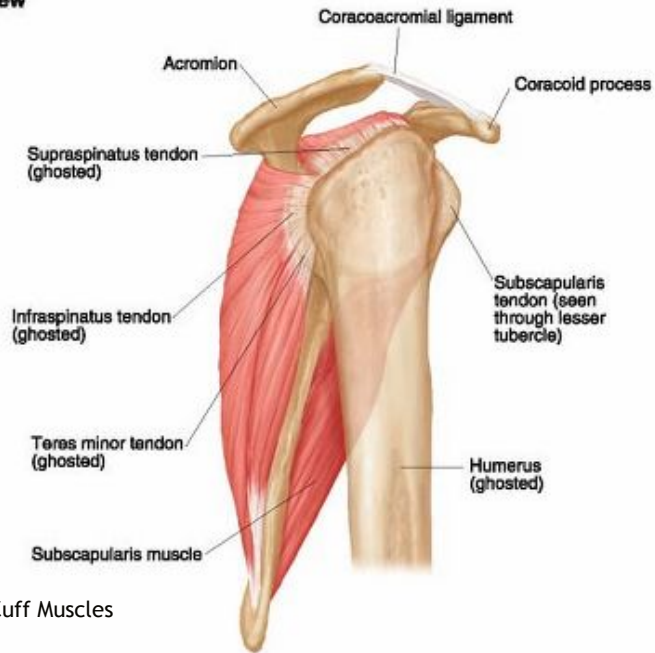
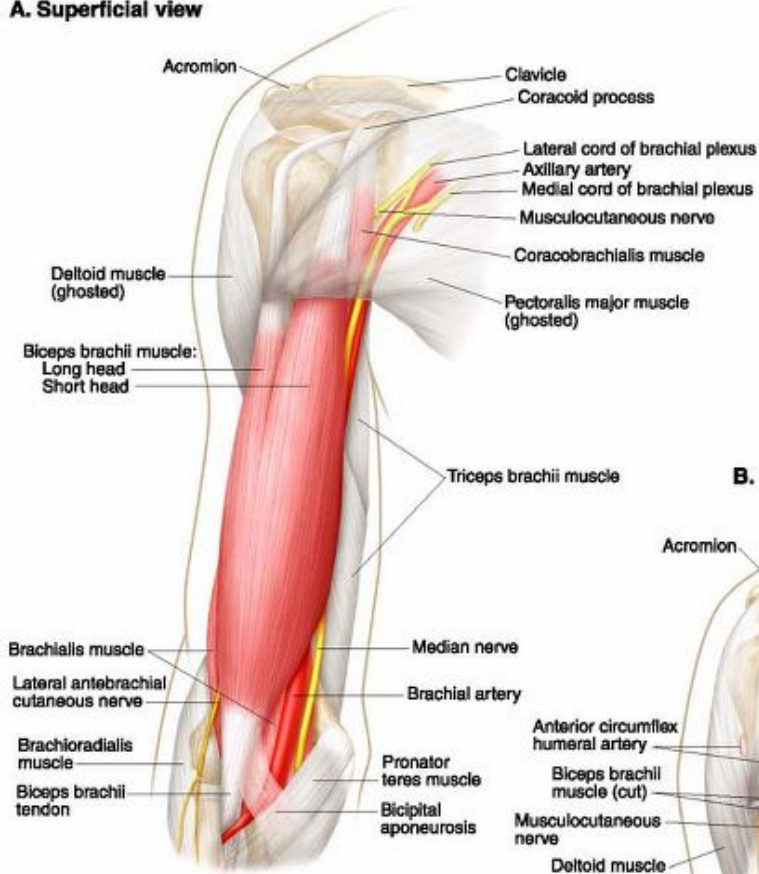


Plate 2-16 Rotator Cuff Muscles

A. Superficial view



B. Deep view

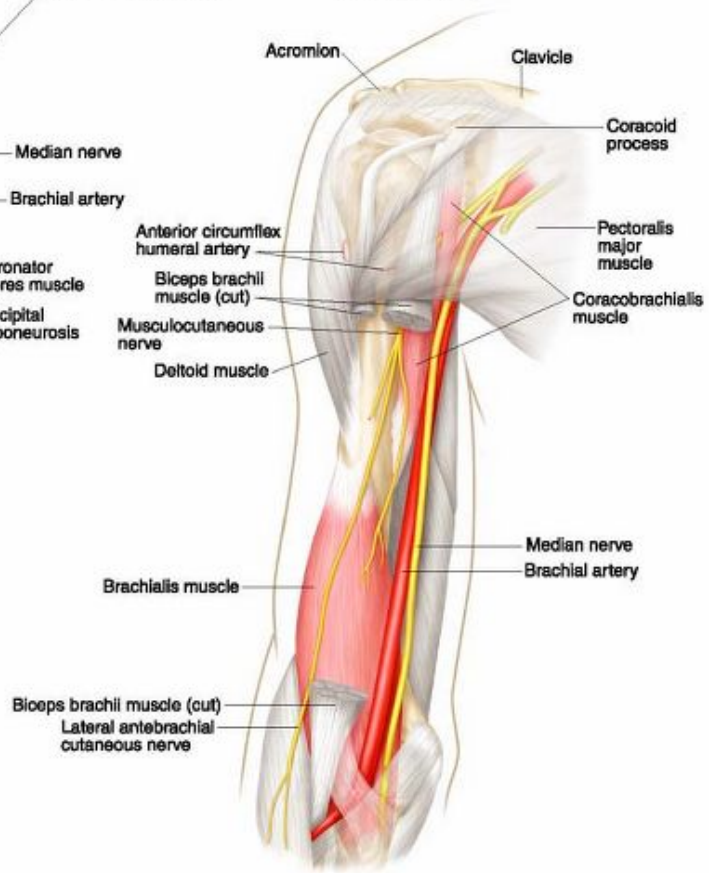
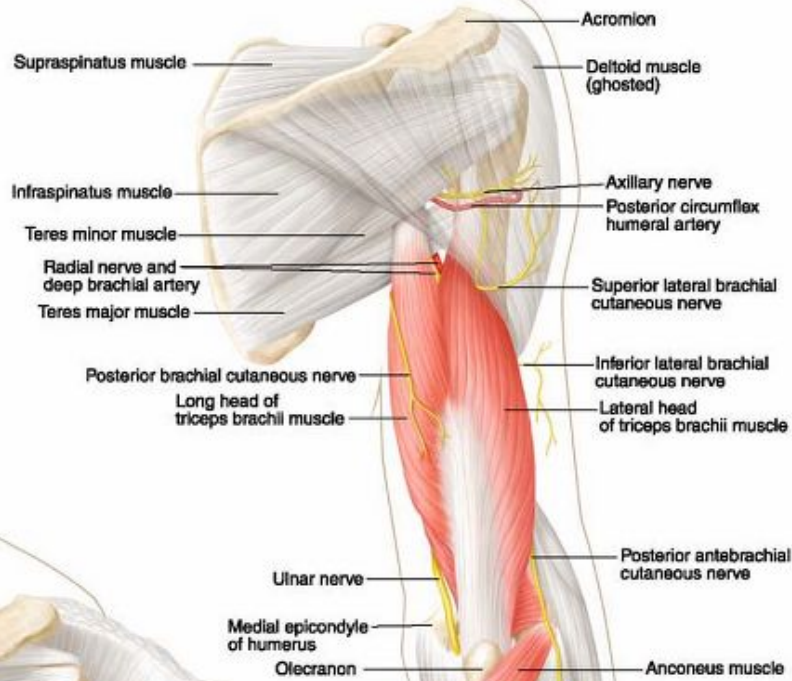


Plate 2-17 Muscles of the Anterior Arm

A. Superficial view



B. Deep view

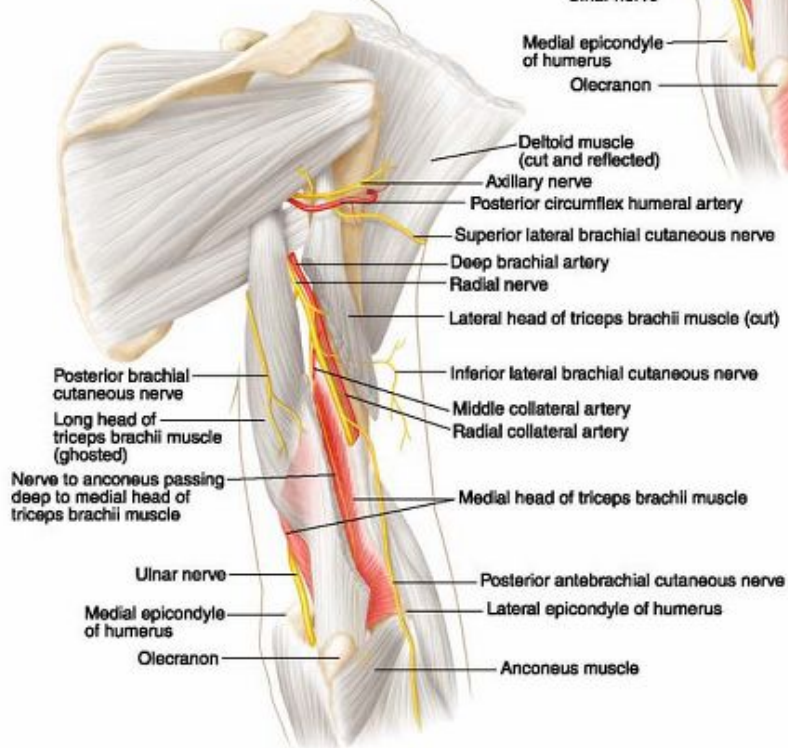
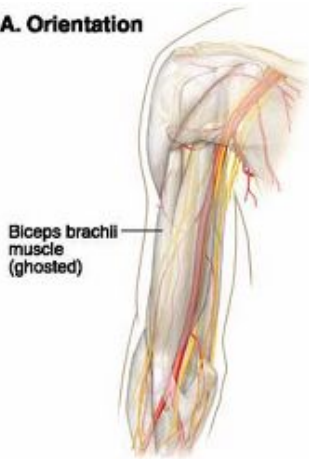


Plate 2-18 Muscles of the Posterior Arm

A. Orientation



B. Schema

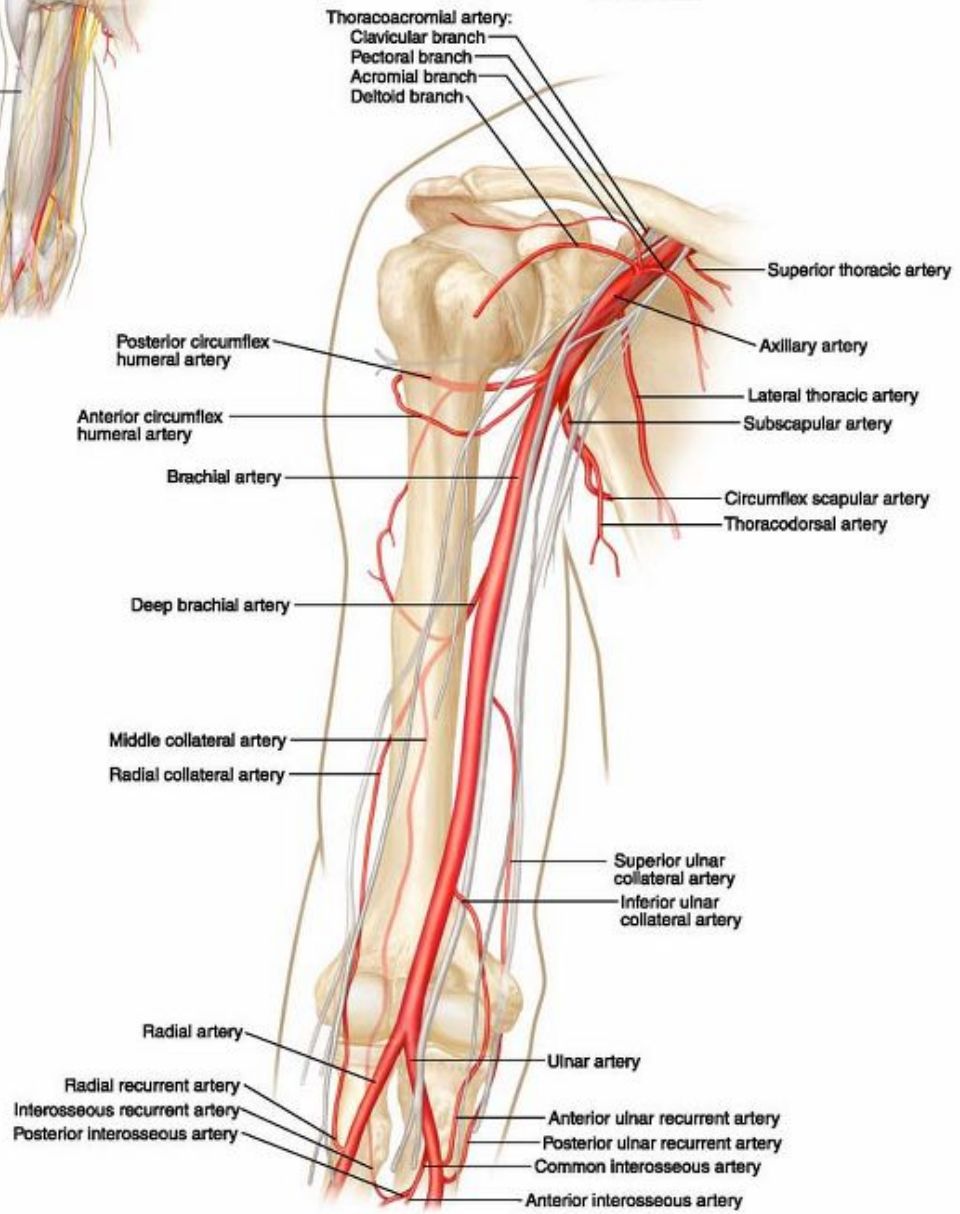
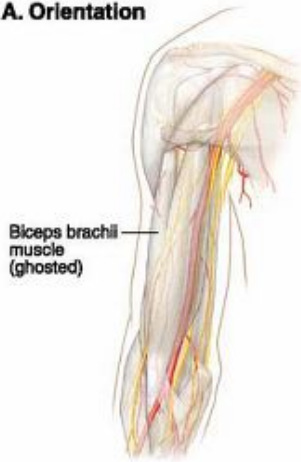


Plate 2-19 Arteries of the Arm

A. Orientation



B. Schema

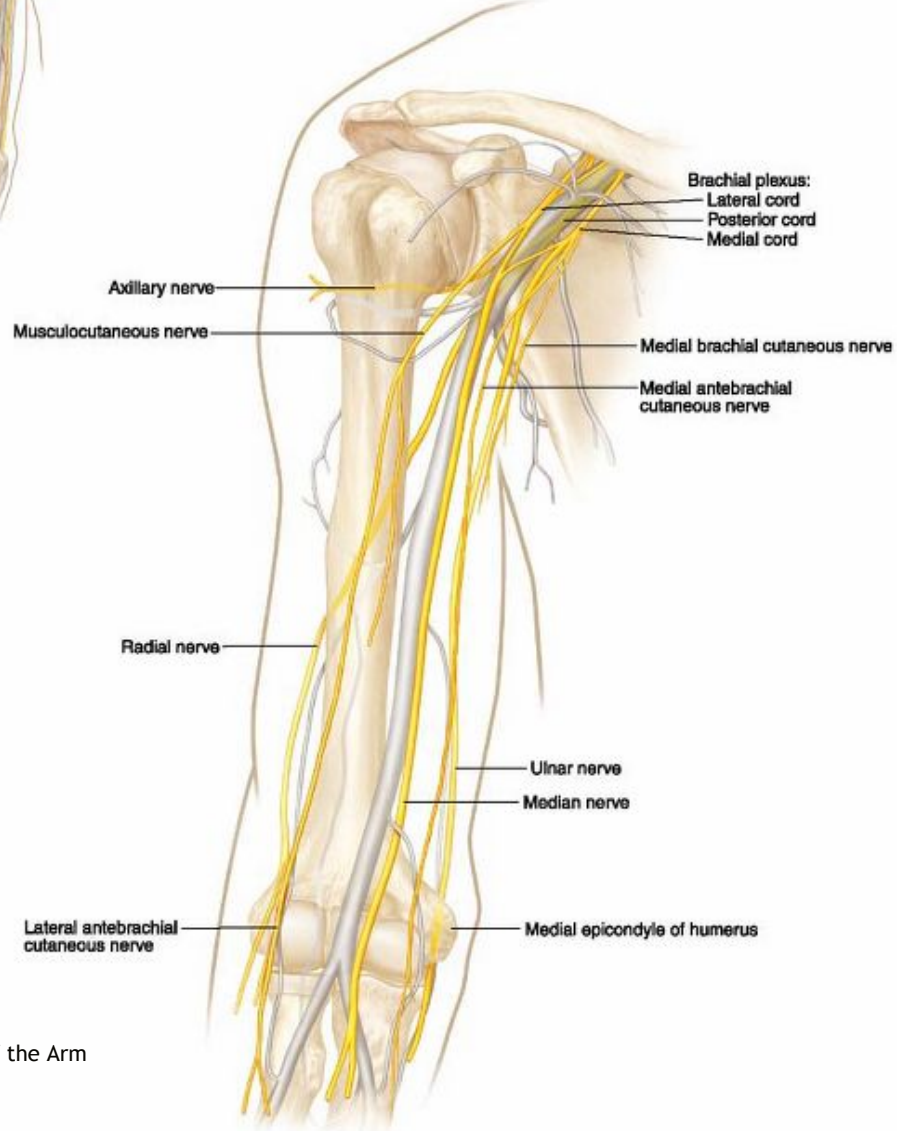


Plate 2-20 Nerves of the Arm

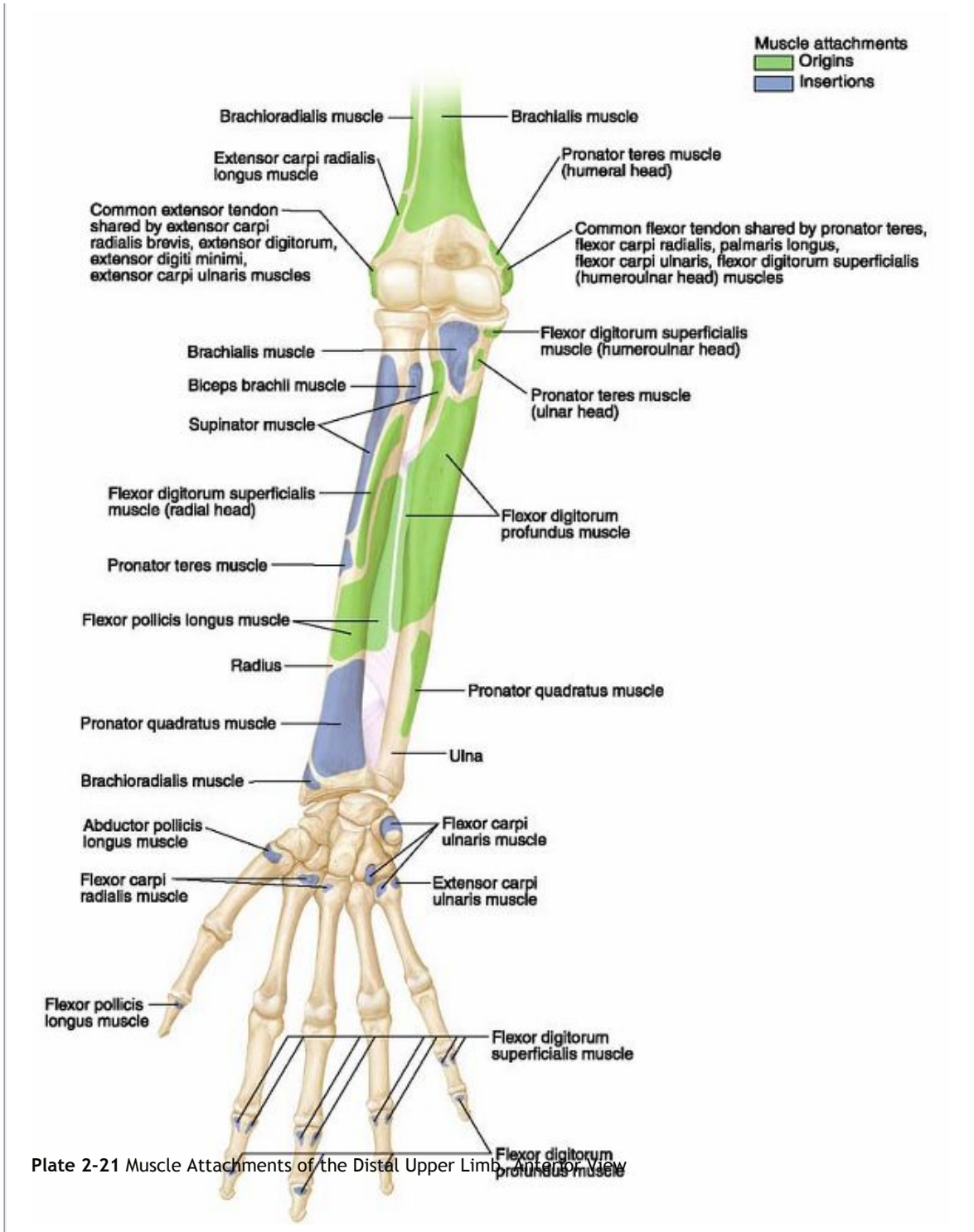


Plate 2-21 Muscle Attachments of the Distal Upper Limb, Anterior View

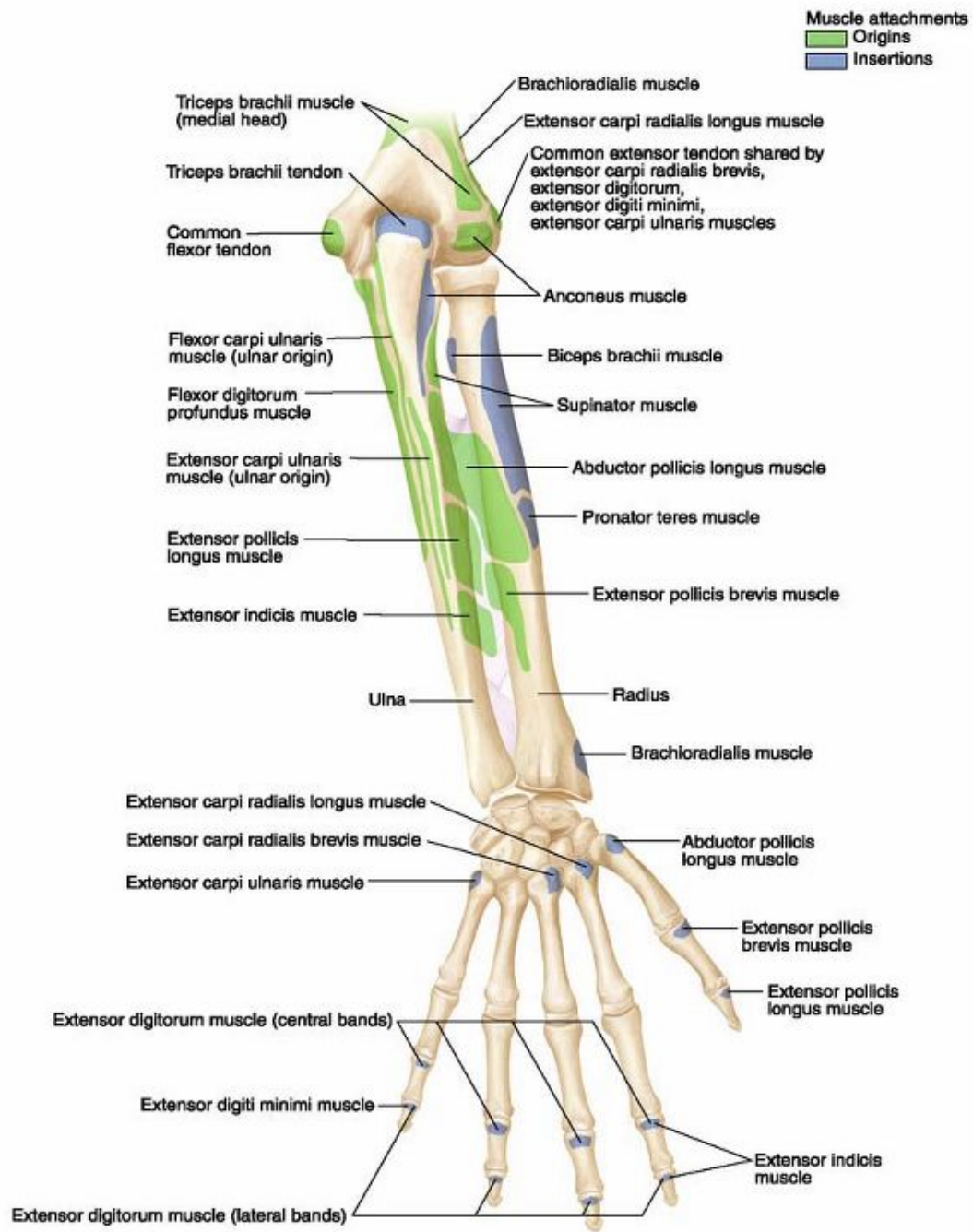


Plate 2-22 Muscle Attachments of the Distal Upper Limb, Posterior View

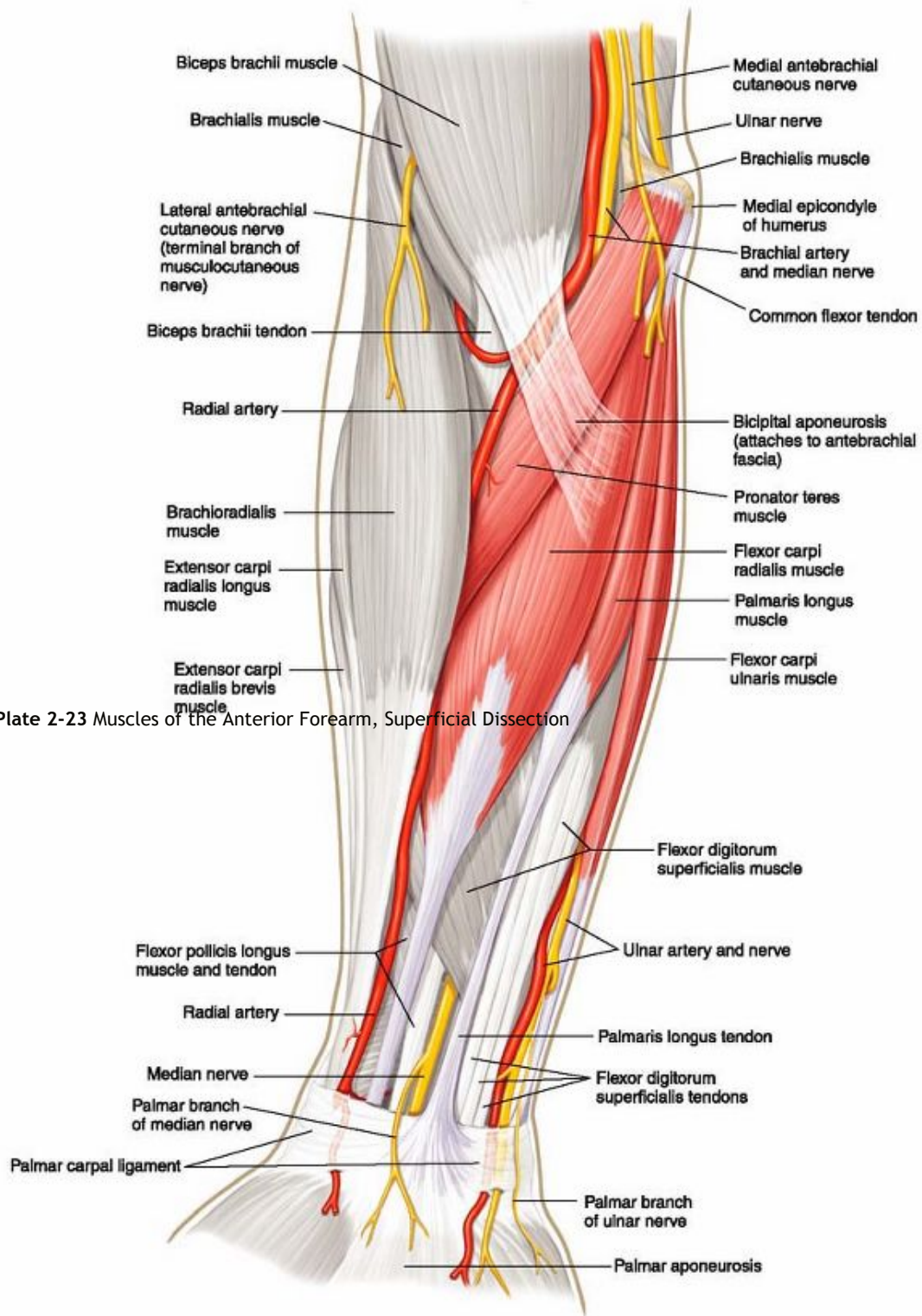


Plate 2-23 Muscles of the Anterior Forearm, Superficial Dissection

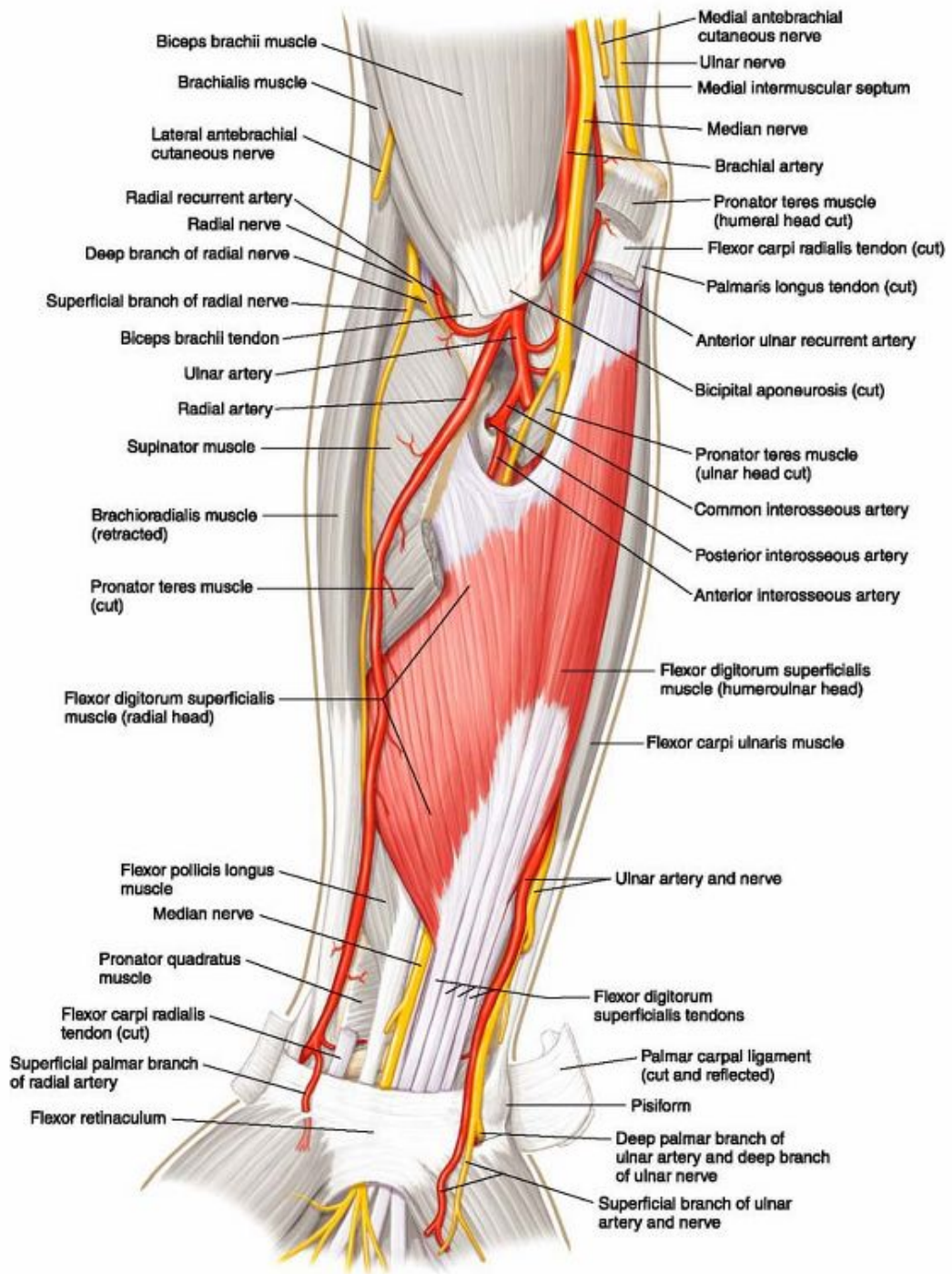
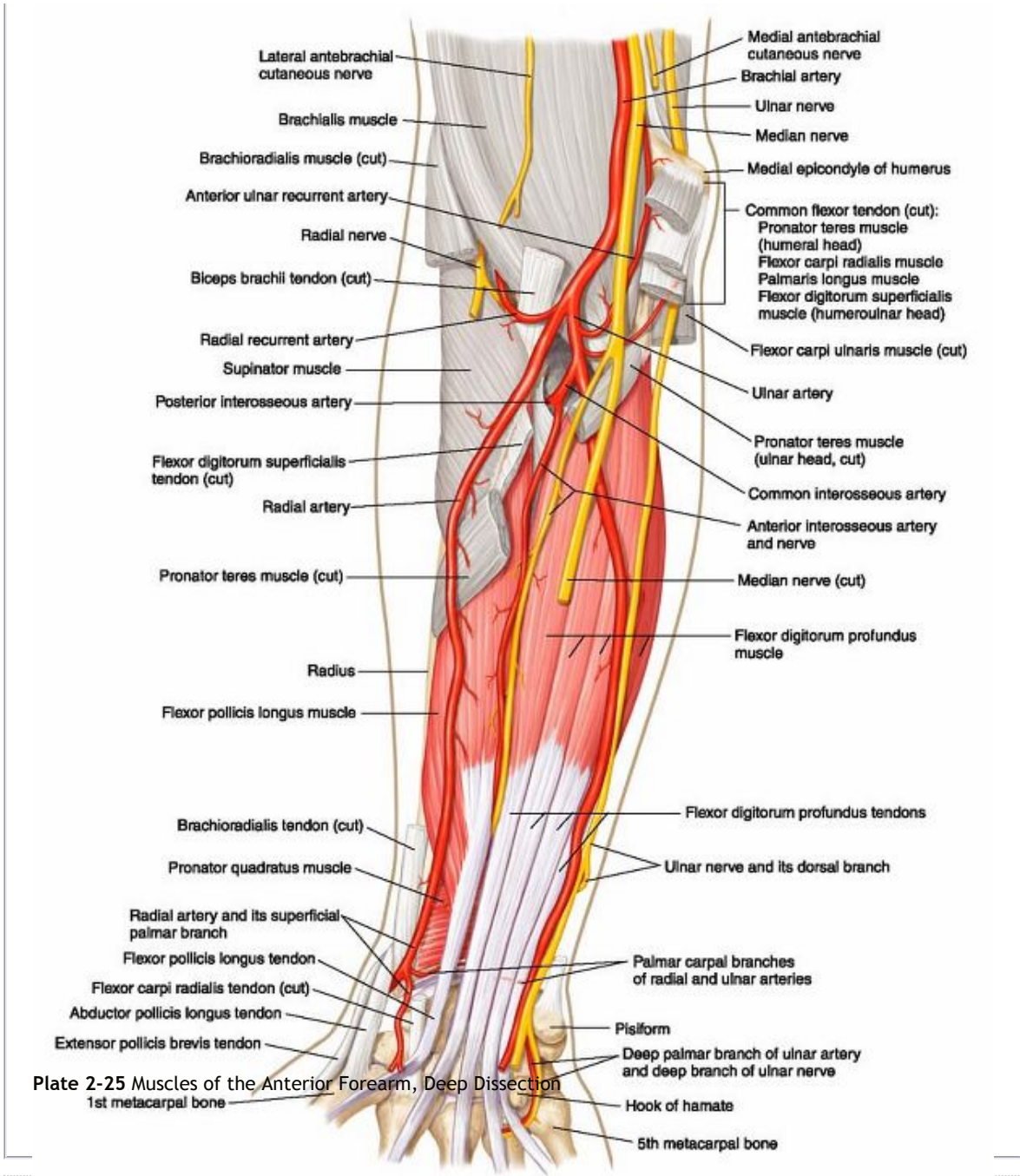


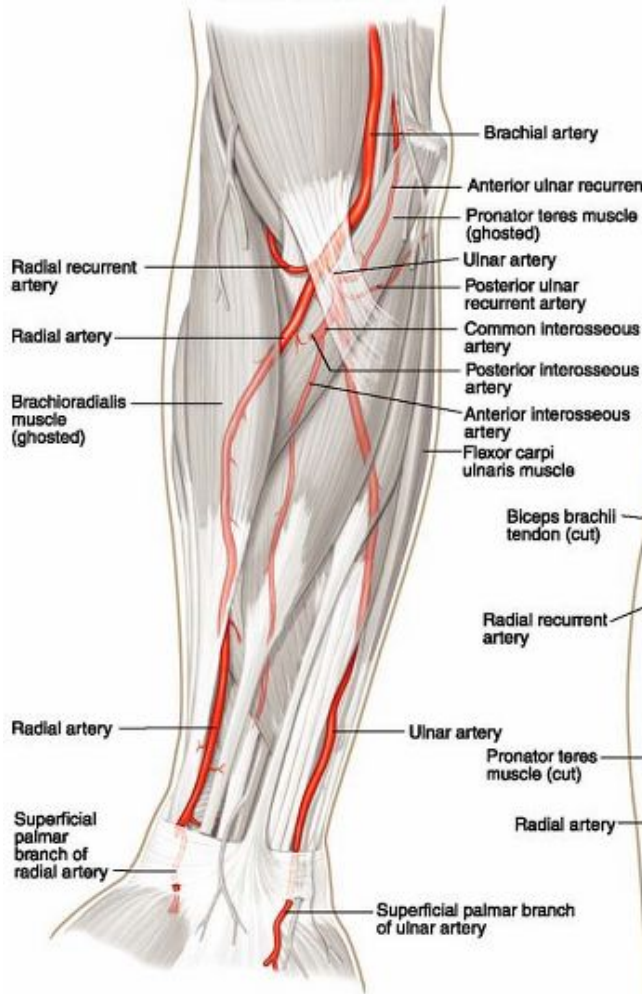
Plate 2-24 Muscles of the Anterior Forearm, Intermediate Dissection

P.54





A. Superficial view



B. Deep view

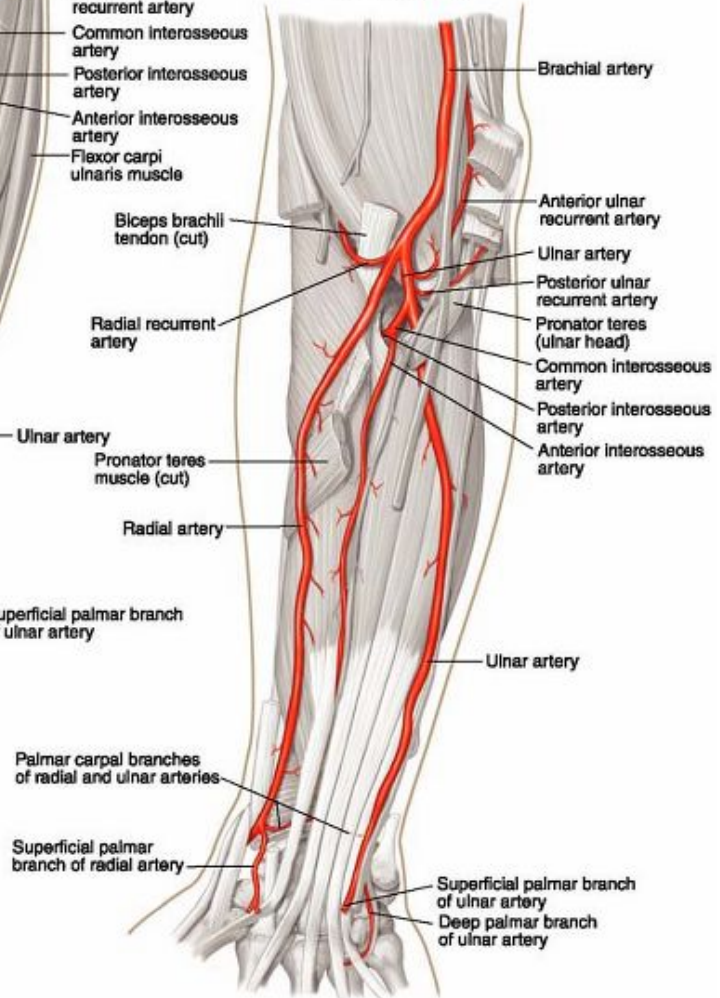
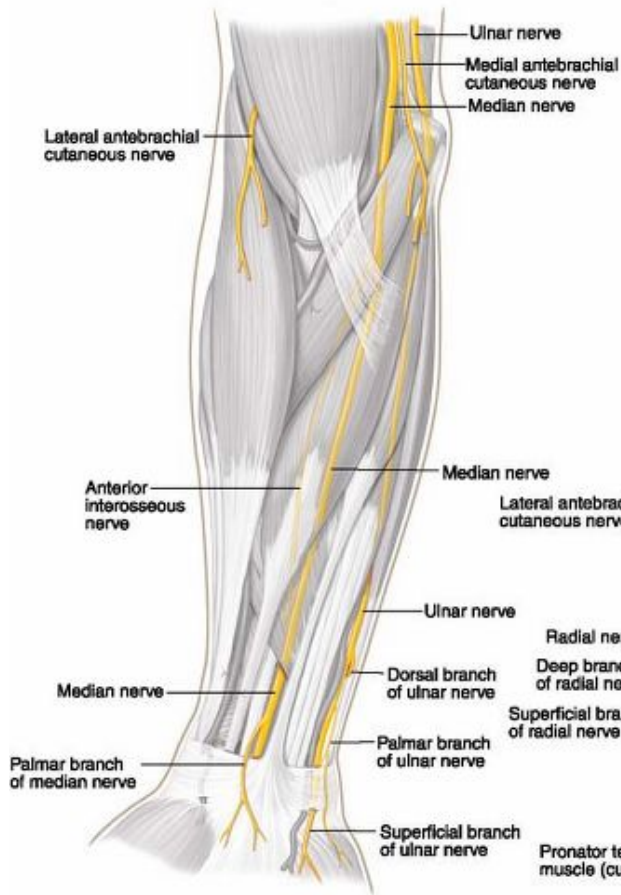


Plate 2-26 Arteries of the Anterior Forearm

A. Superficial view



B. Deep view

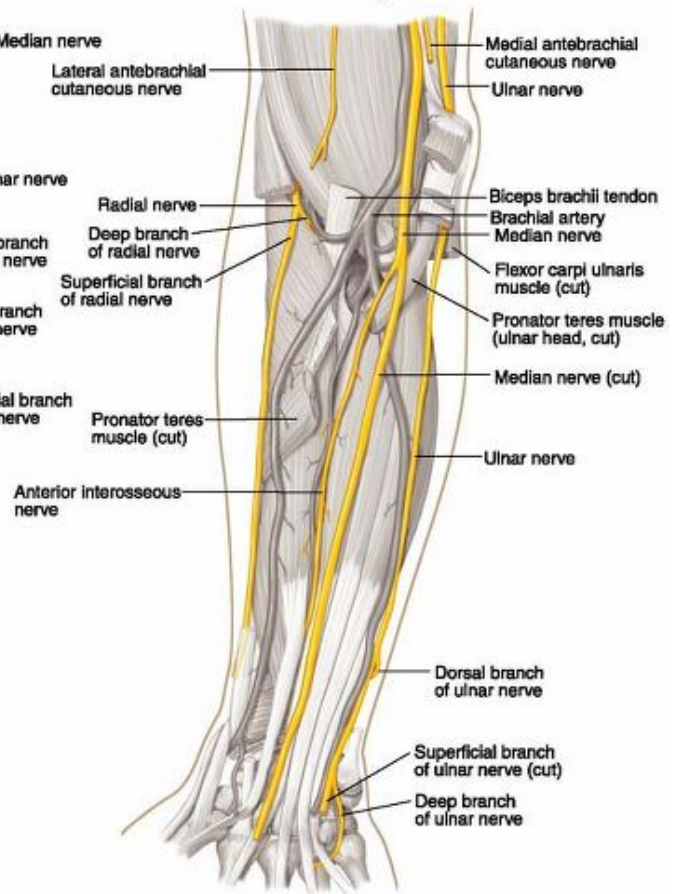
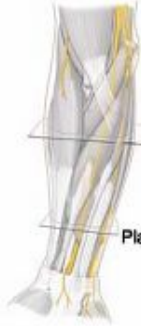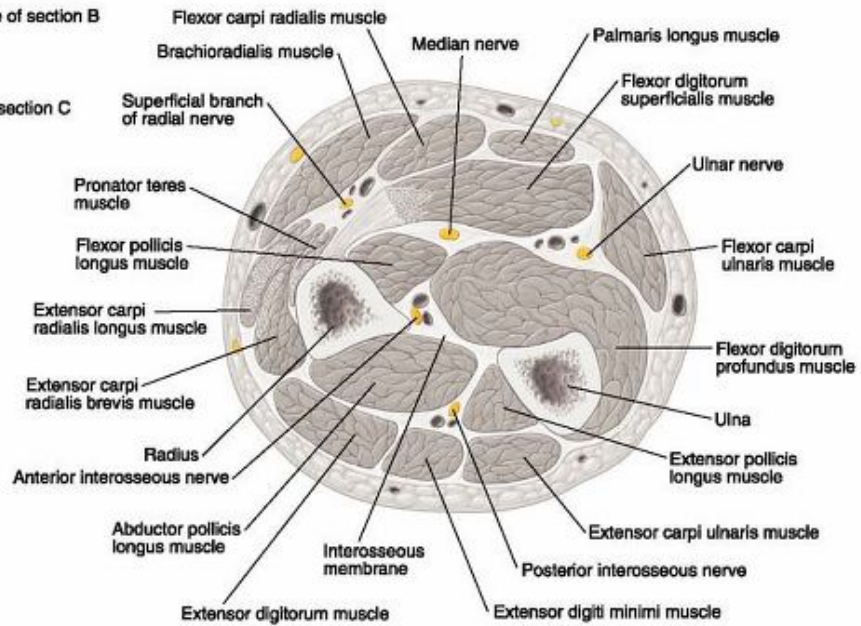


Plate 2-27 Nerves of the Anterior Forearm

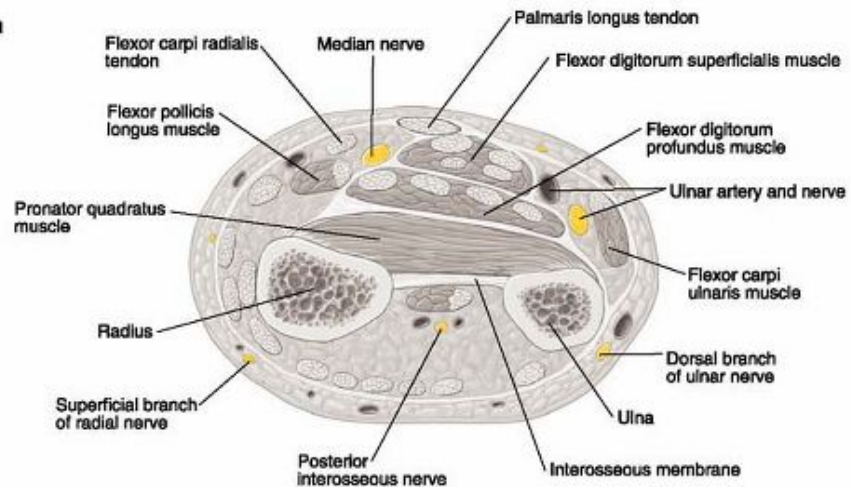
A. Orientation



B. Midforearm



C. Distal forearm



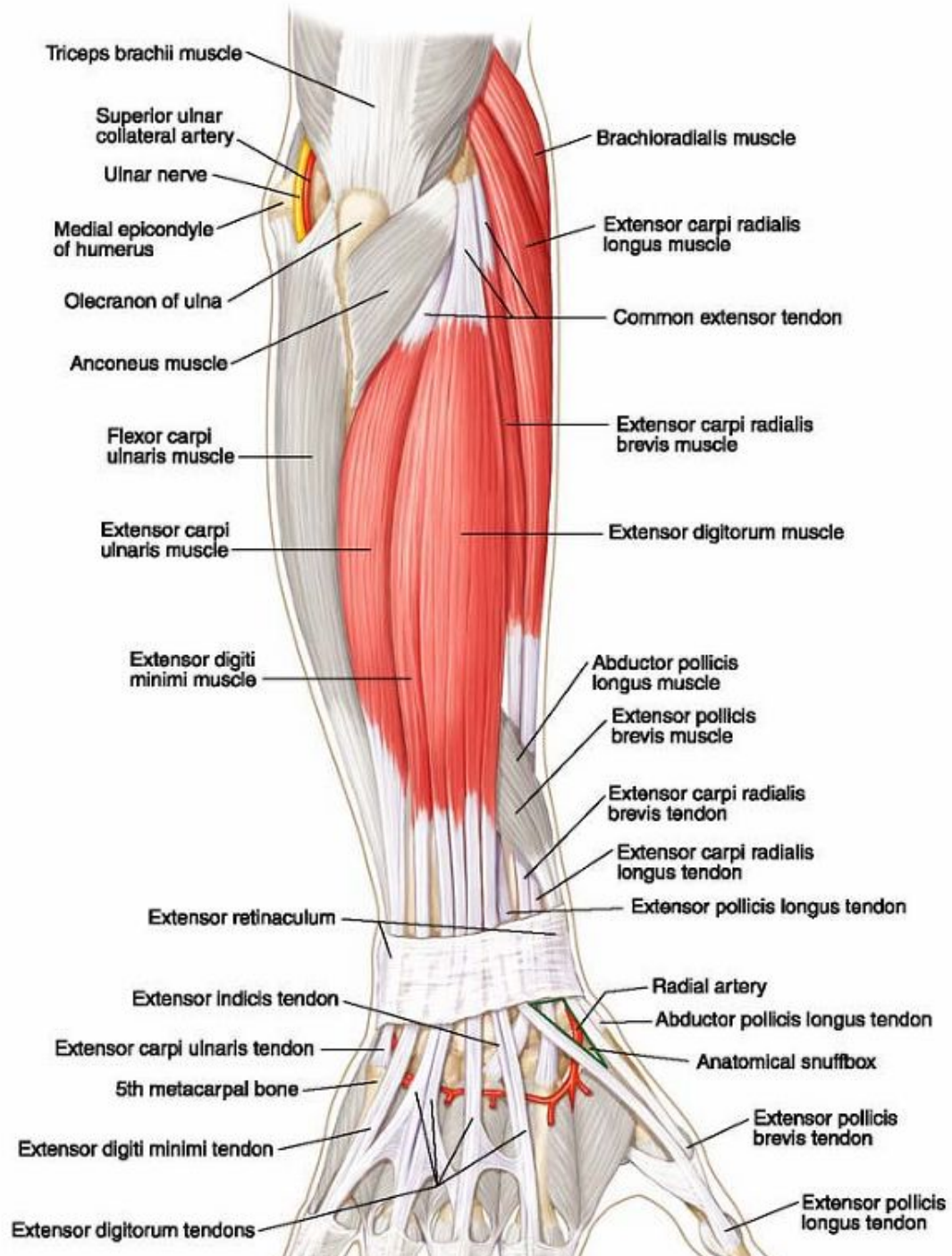
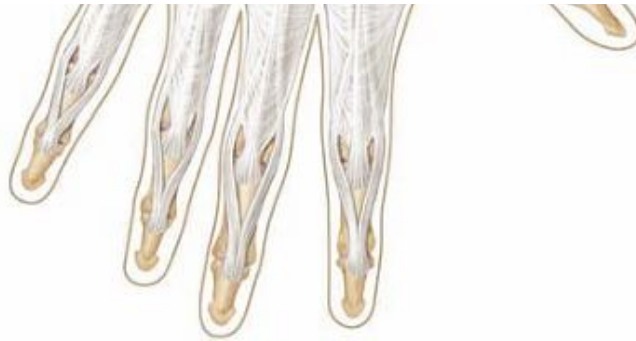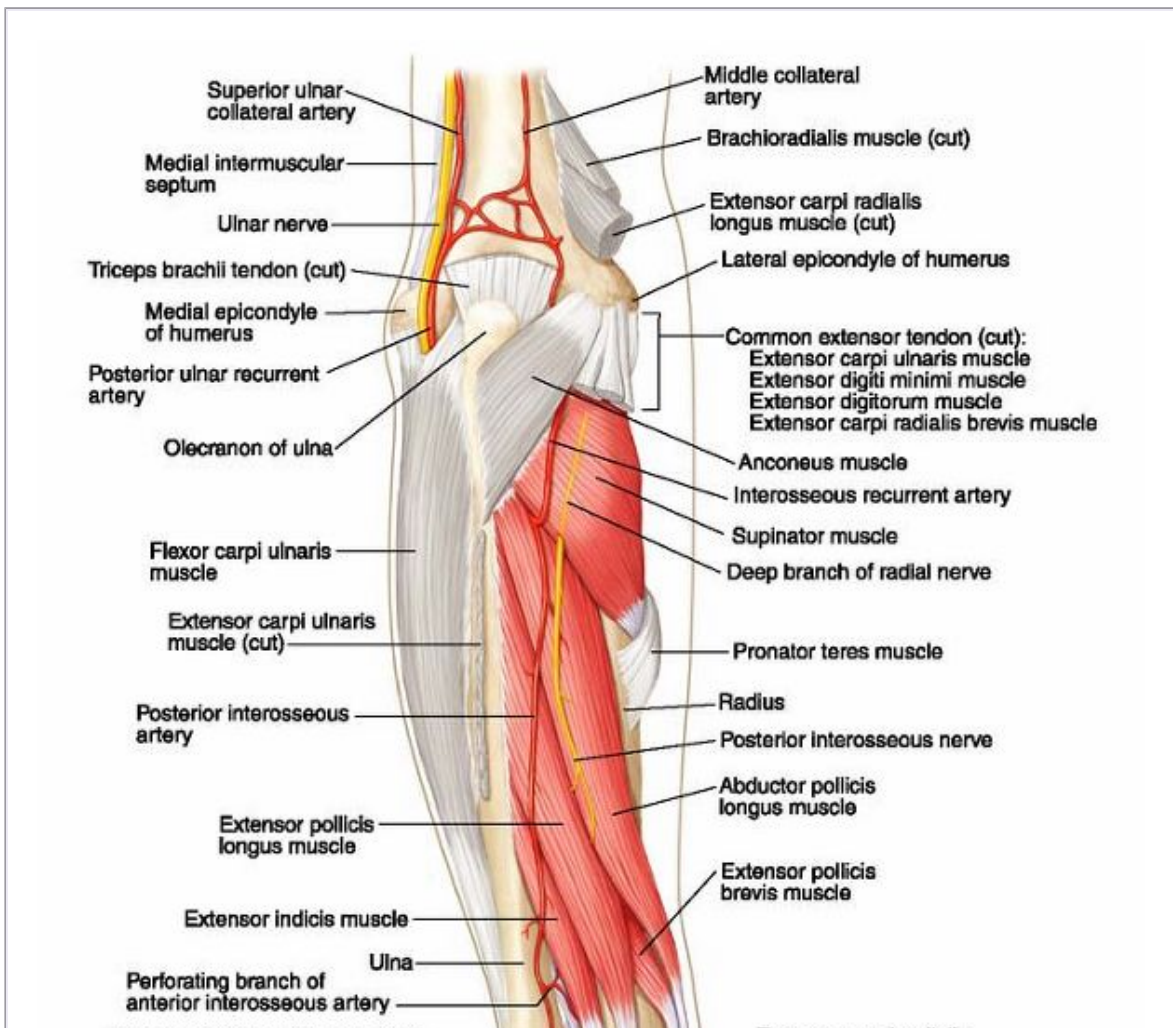




Plate 2-29 Muscles of the Posterior Forearm, Superficial Dissection



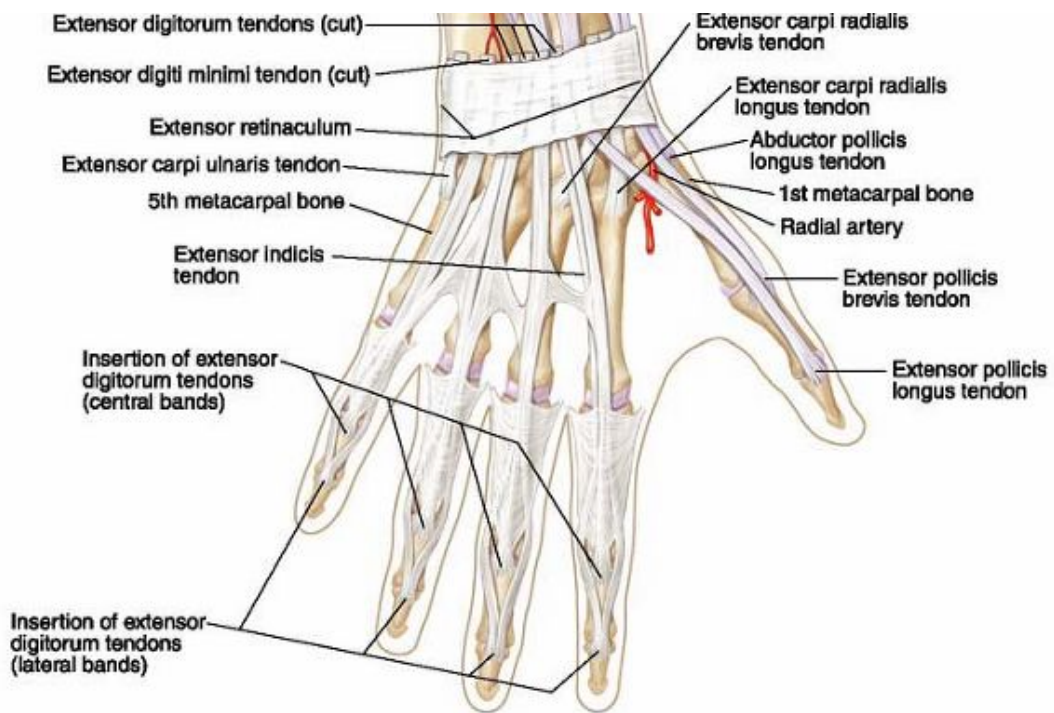
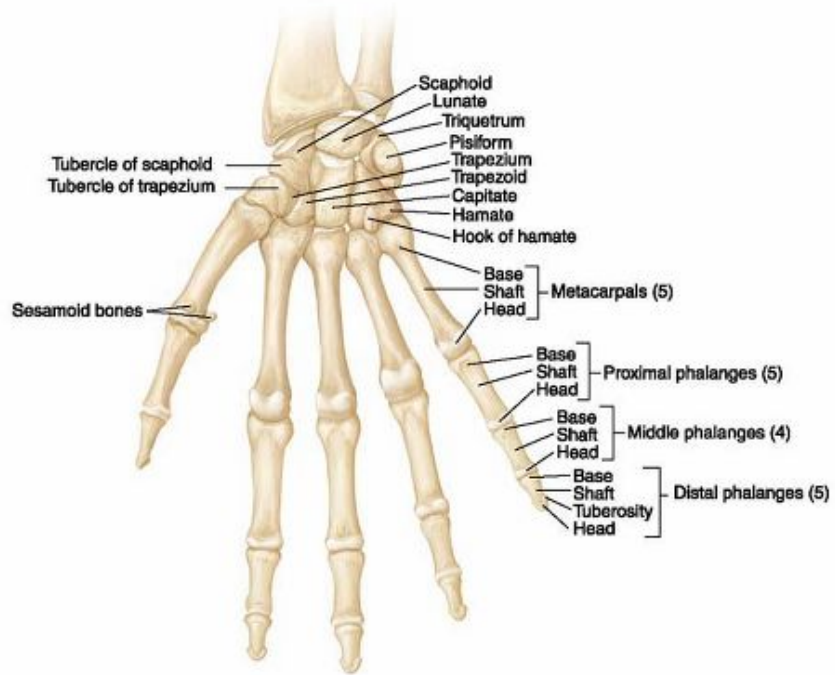


Plate 2-30 Muscles of the Posterior Forearm, Deep Dissection

A. Bones



B. Muscle attachments

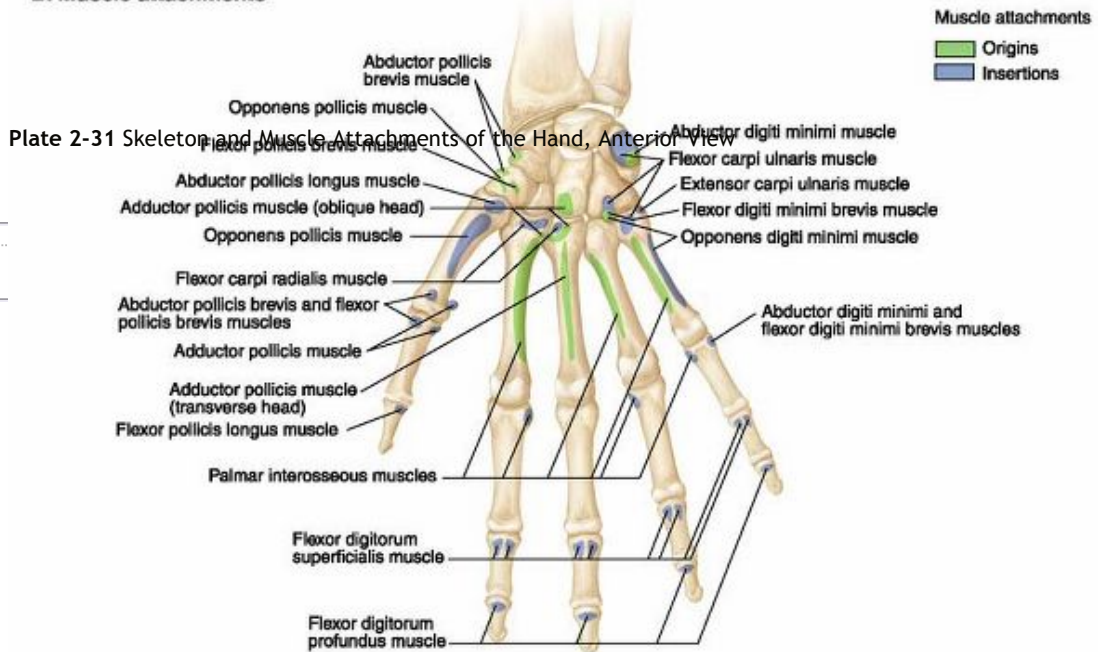
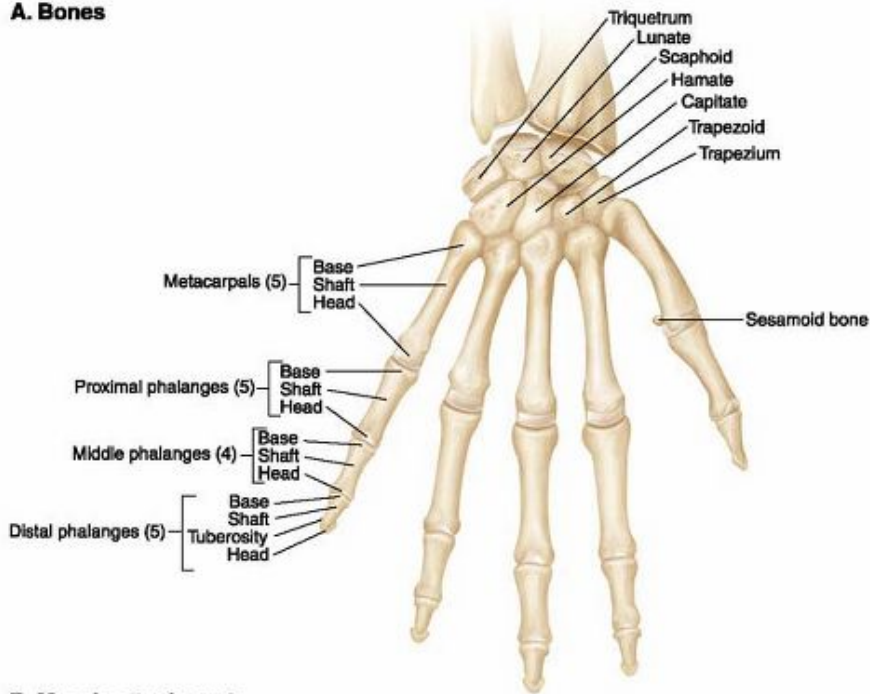


Plate 2-31 Skeleton and Muscle Attachments of the Hand, Anterior View

A. Bones



B. Muscle attachments

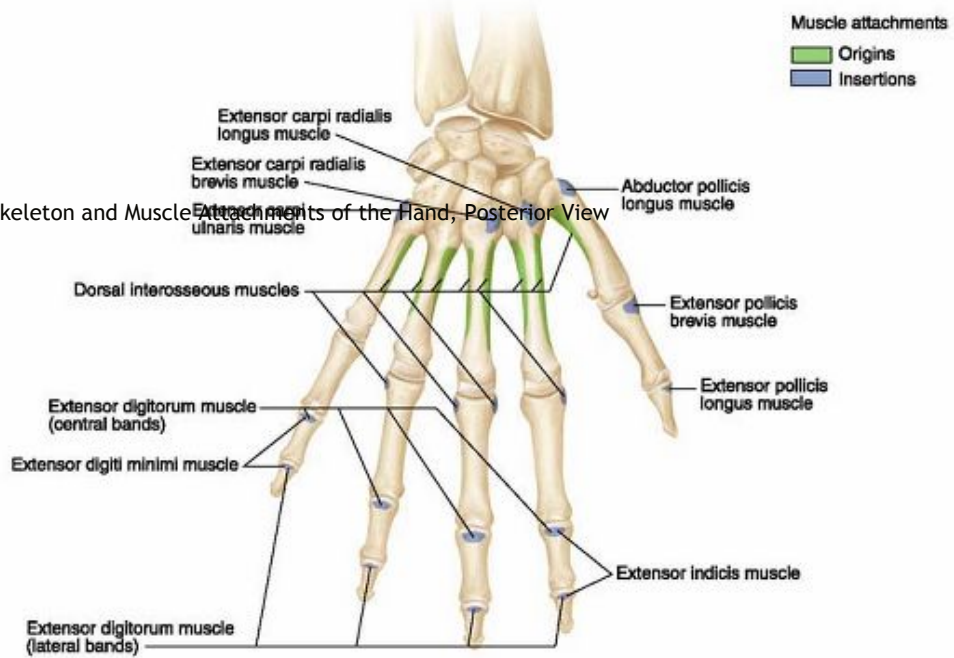
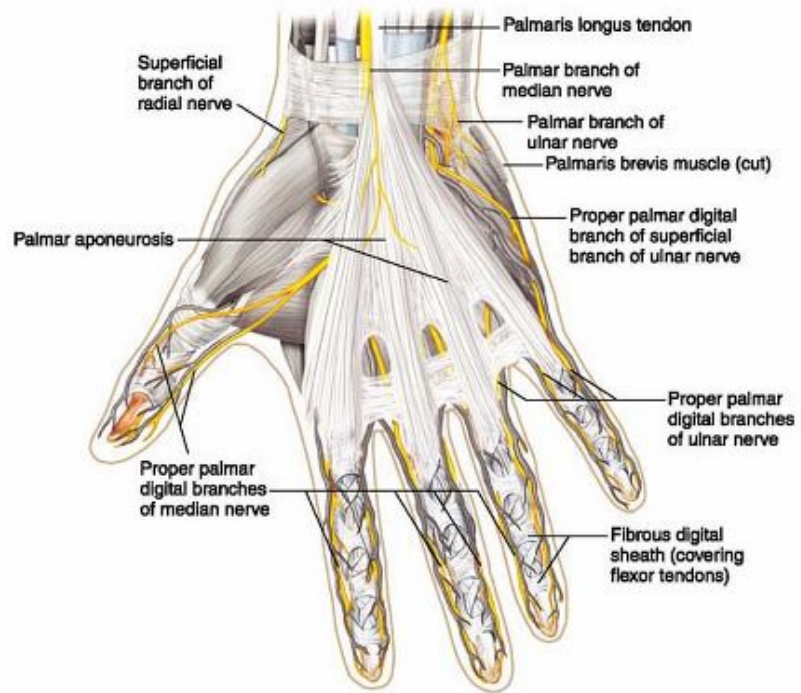


Plate 2-32 Skeleton and Muscle Attachments of the Hand, Posterior View

A. Dissection



B. Nerve territories

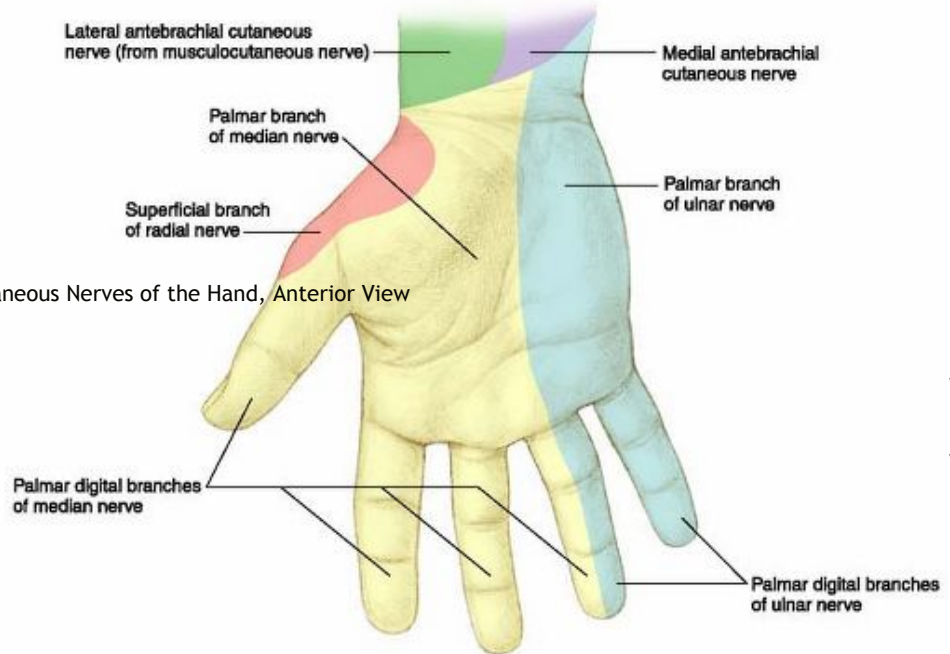
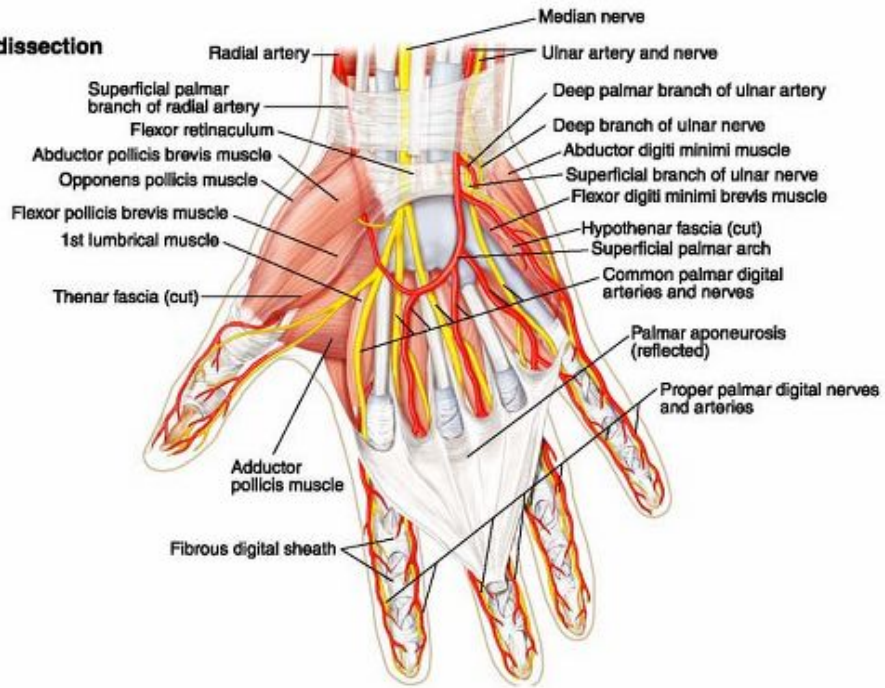
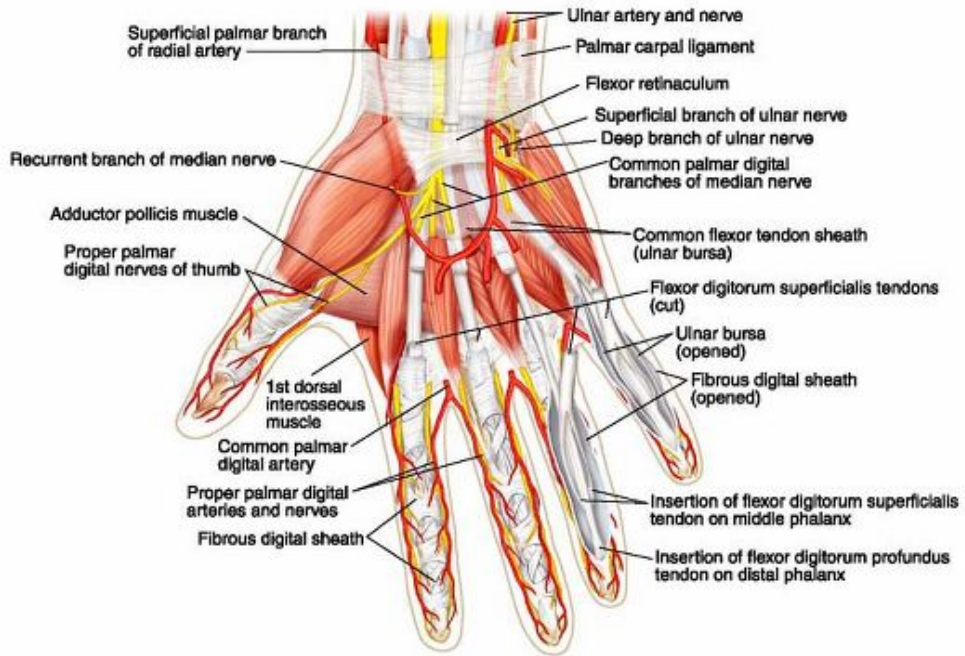


Plate 2-33 Cutaneous Nerves of the Hand, Anterior View

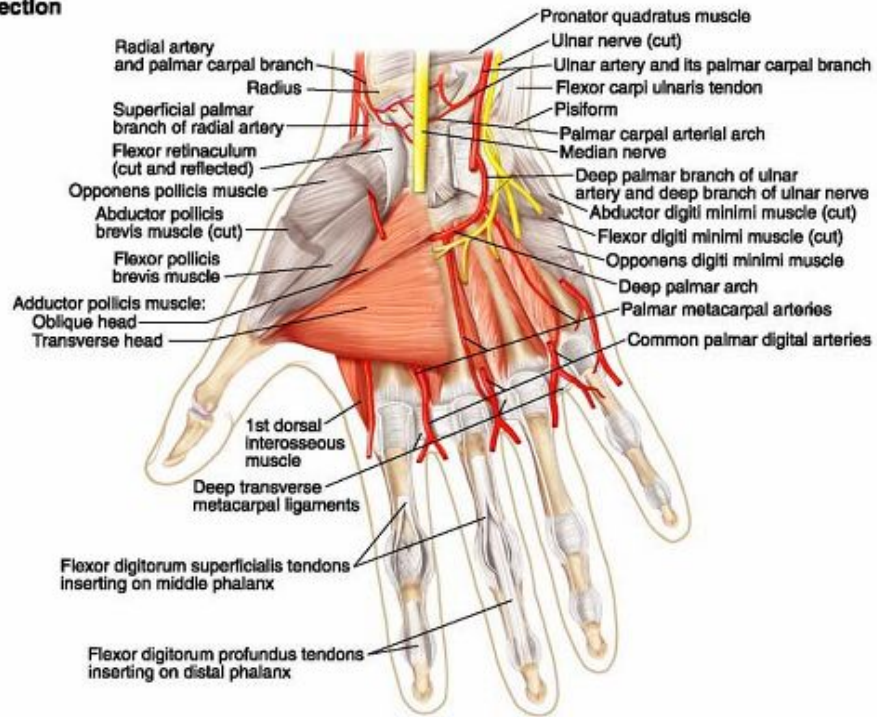
A. Superficial dissection



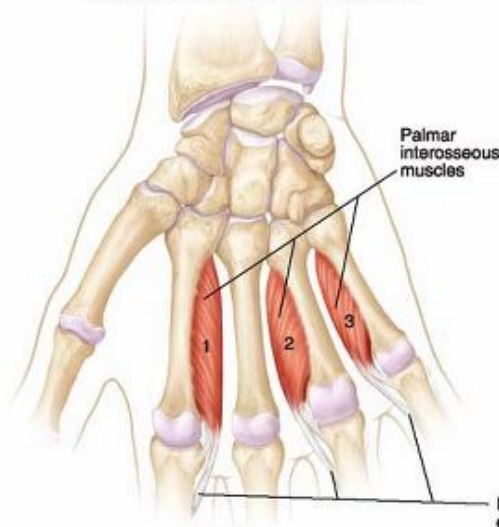
B. Intermediate dissection



A. Deep dissection



B. Palmar interosseous muscles



C. Dorsal interosseous muscles

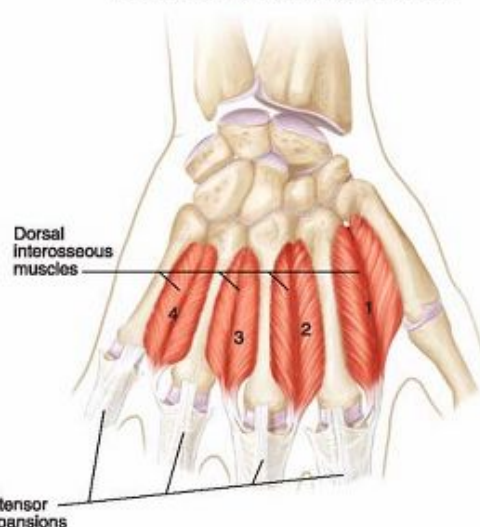
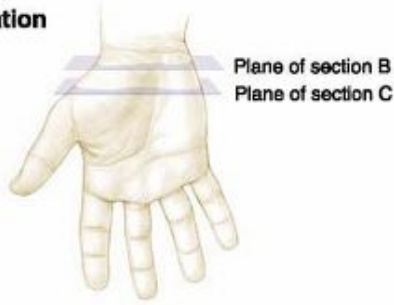
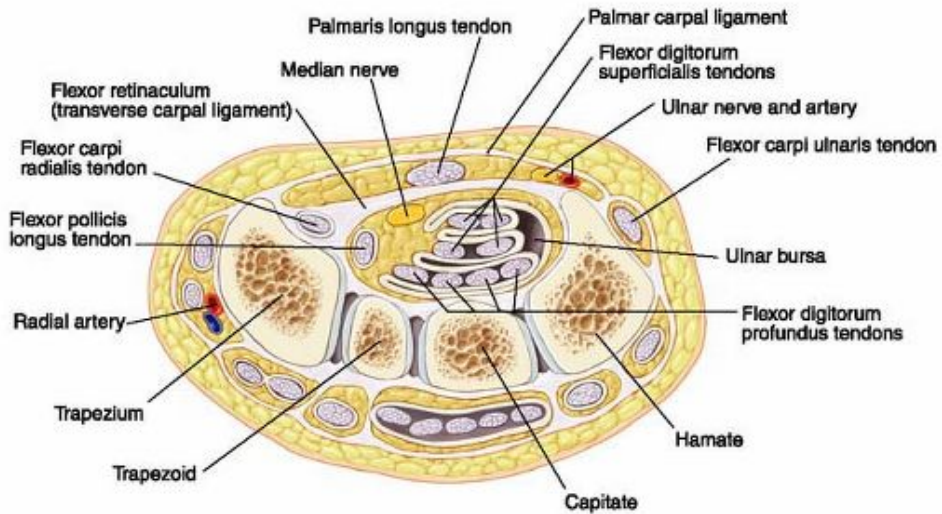


Plate 2-35 Wrist and Palm of the Hand II

A. Orientation



B. Wrist



C. Palm

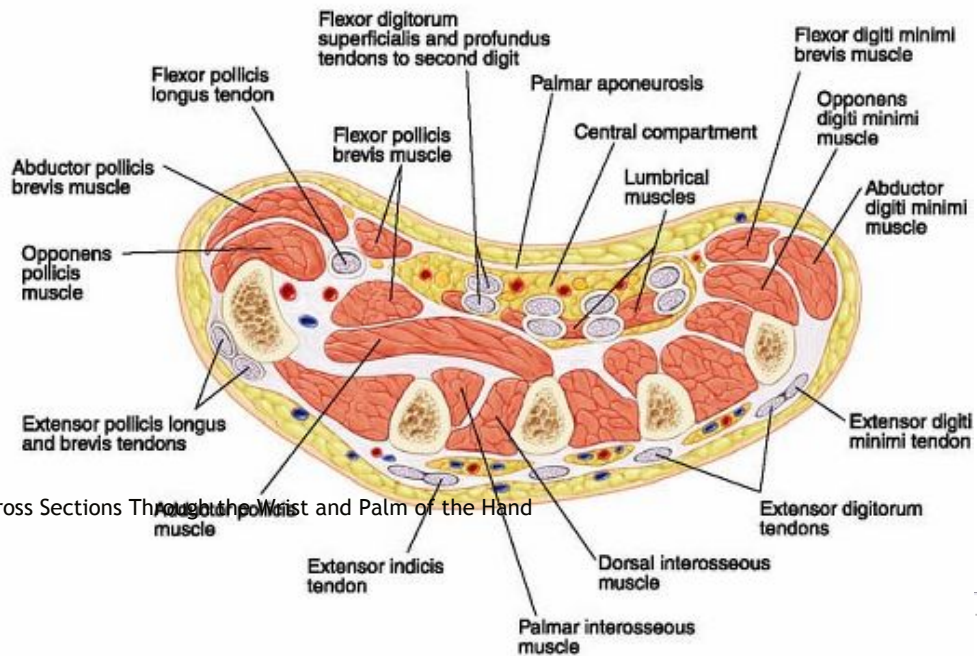
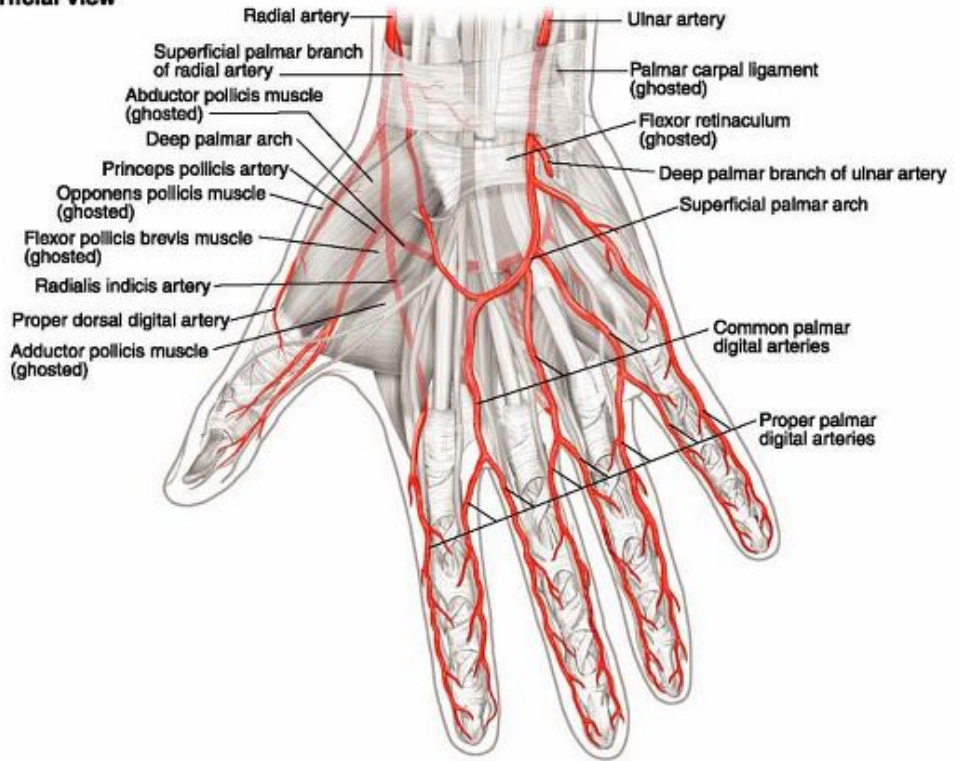


Plate 2-36 Cross Sections Through the Wrist and Palm of the Hand

A. Superficial view



B. Deep view

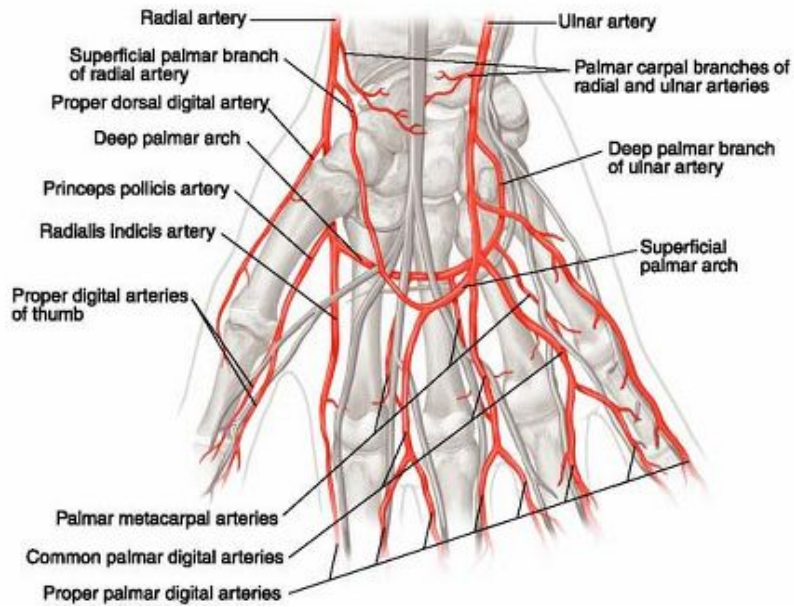
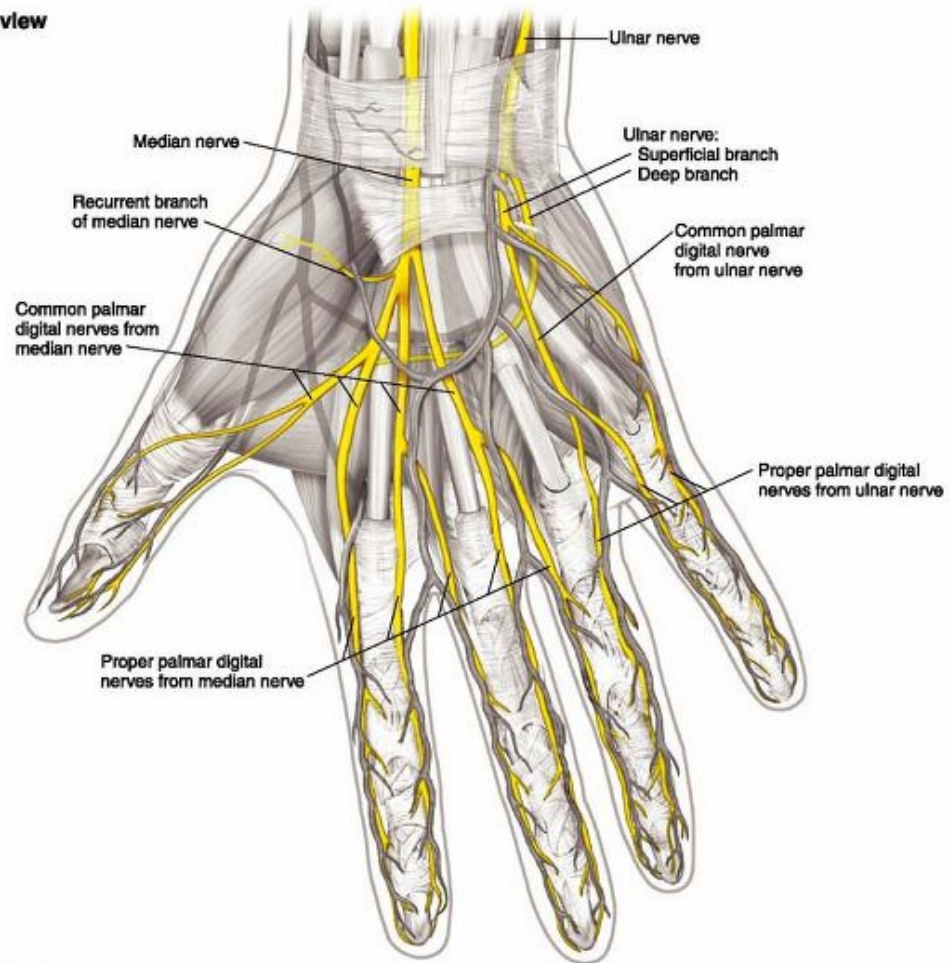


Plate 2-37 Arteries of the Hand, Anterior View

A. Anterior view



B. Lateral view

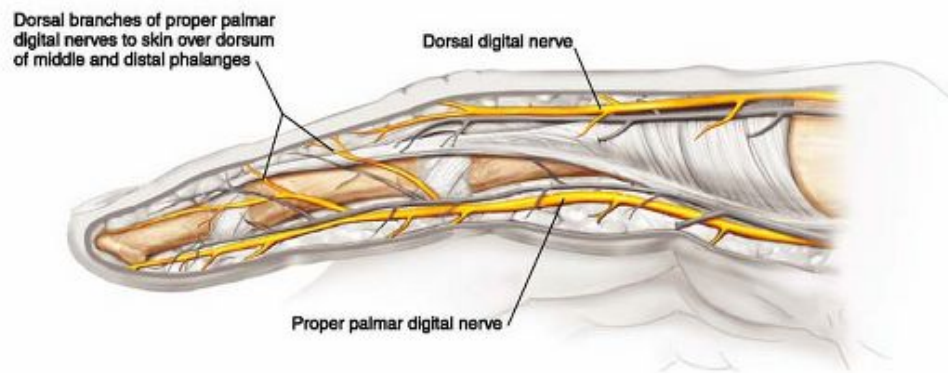
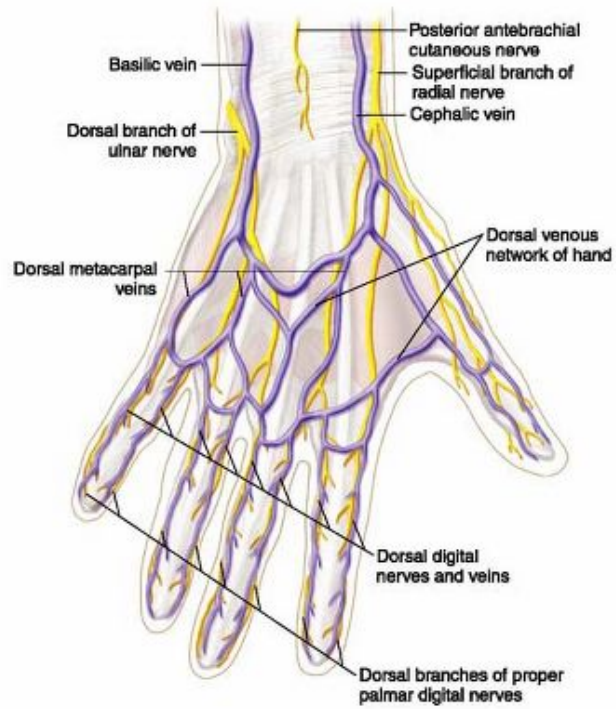


Plate 2-38 Nerves of the Hand

A. Dissection



B. Nerve territories

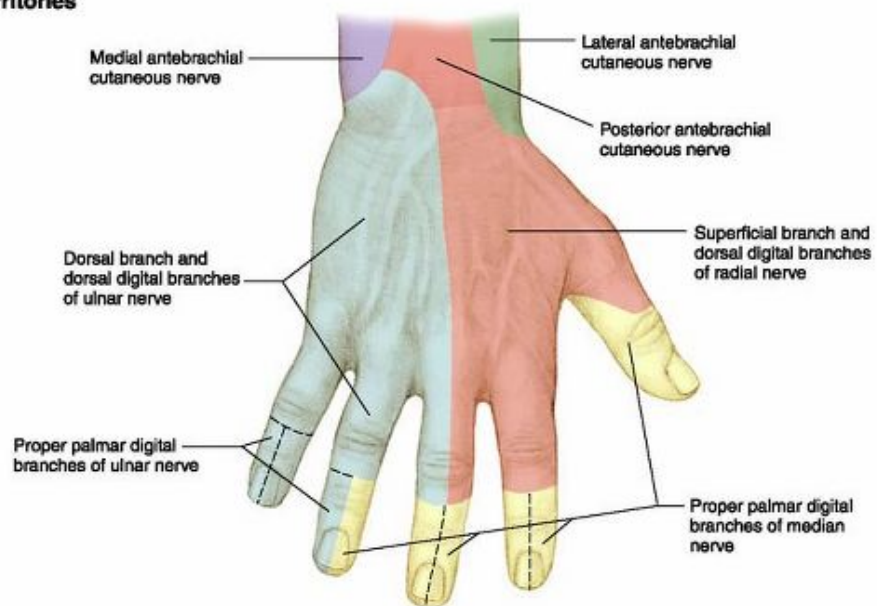
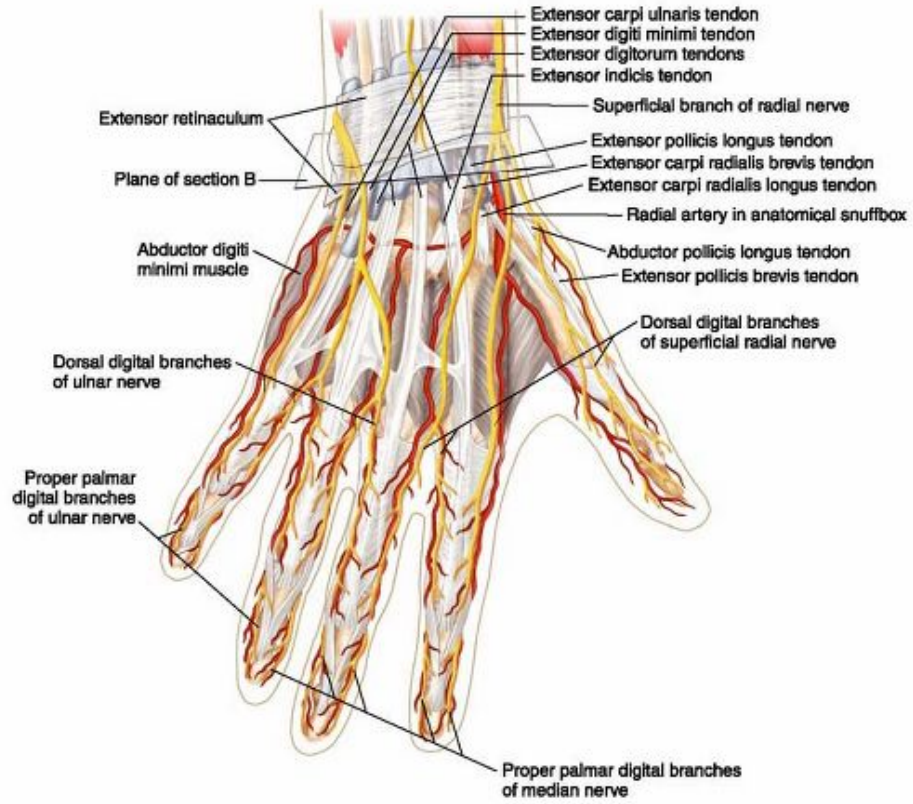


Plate 2-39 Cutaneous Nerves and Superficial Veins of the Hand, Posterior View

P.69



A. Dissection



B. Cross section through the wrist

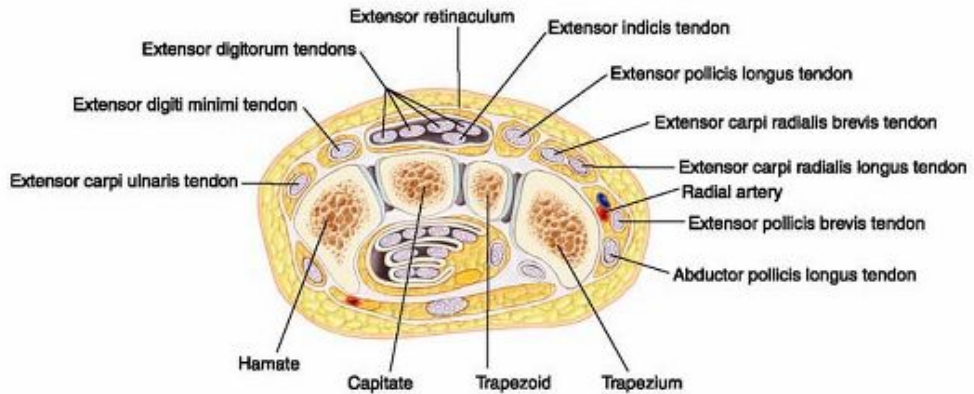
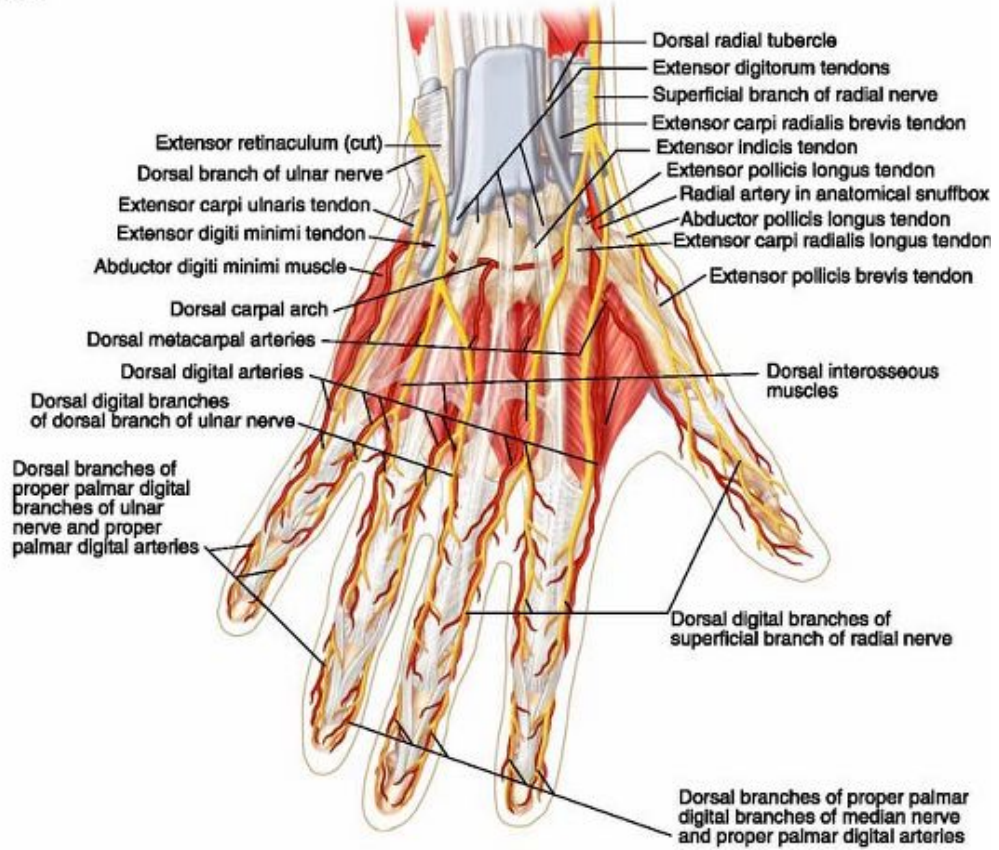


Plate 2-40 Dorsum of the Wrist and Hand, Superficial Dissection

A. Dissection



B. Extensor expansion, right index finger

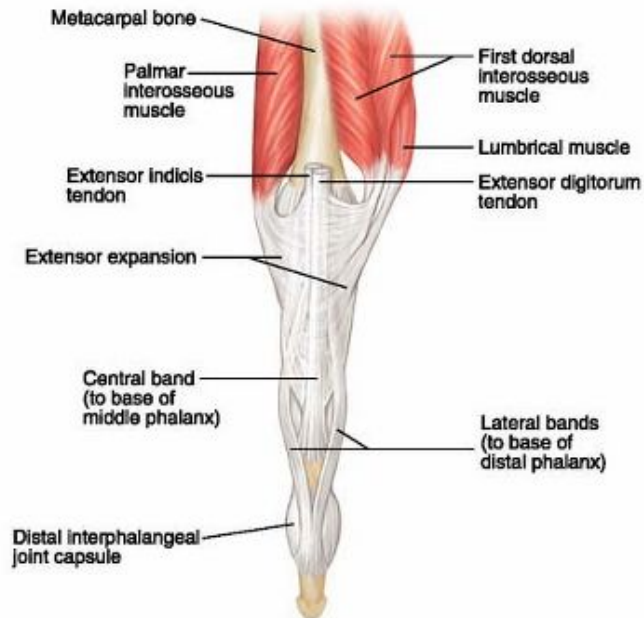
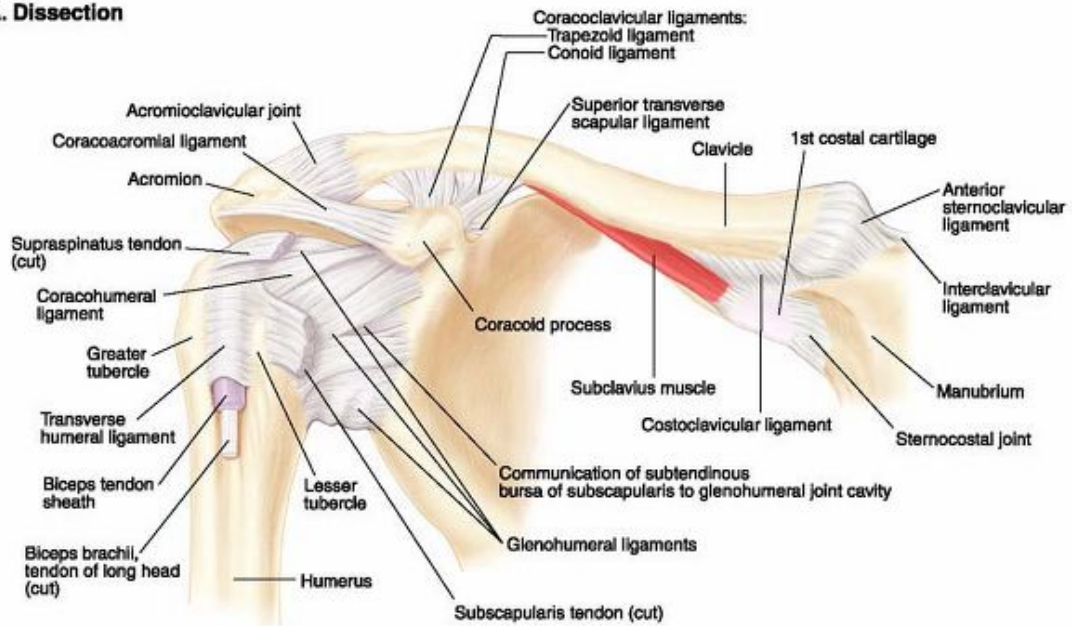
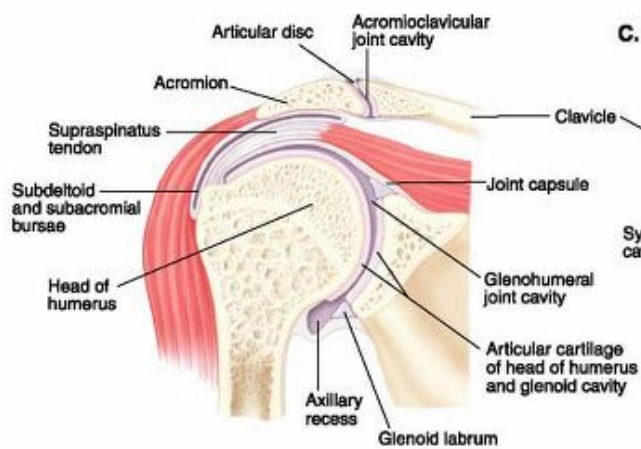


Plate 2-41 Dorsum of the Wrist and Hand, Deep Dissection

A. Dissection



B. Shoulder joint, coronal section



C. Sternoclavicular joint, coronal section

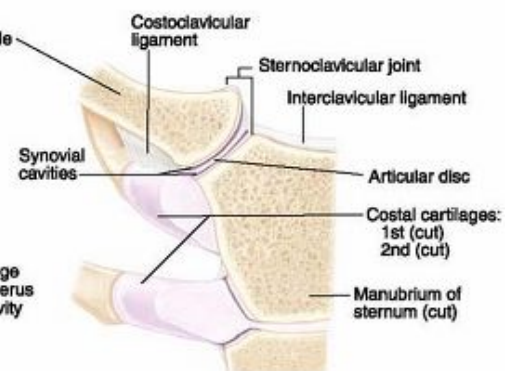
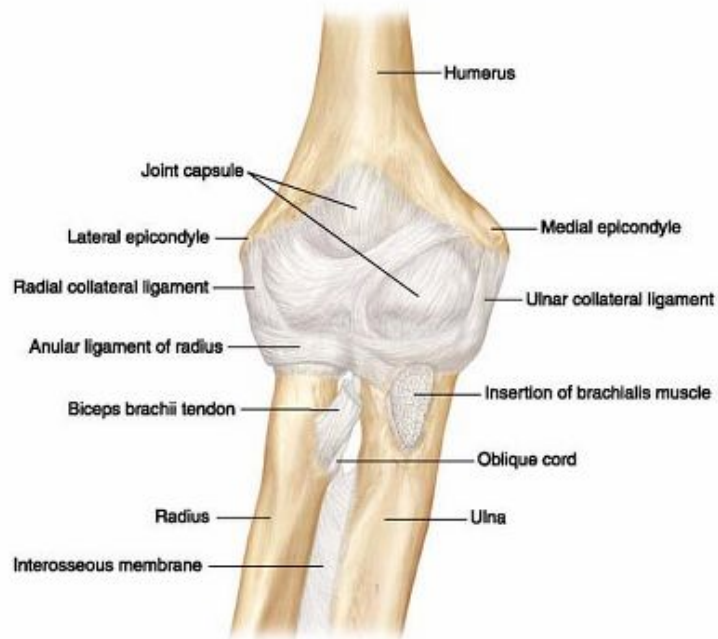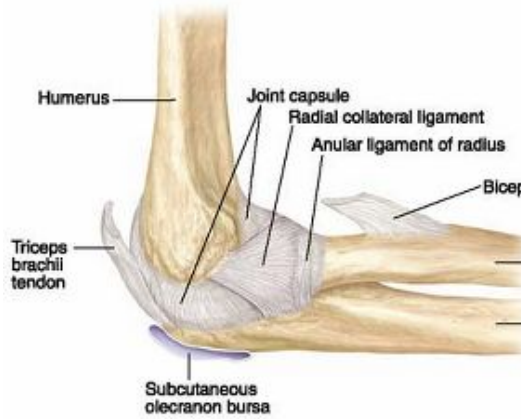


Plate 2-42 Joints of the Proximal Upper Limb

A. Anterior view



B. Lateral view



C. Medial view

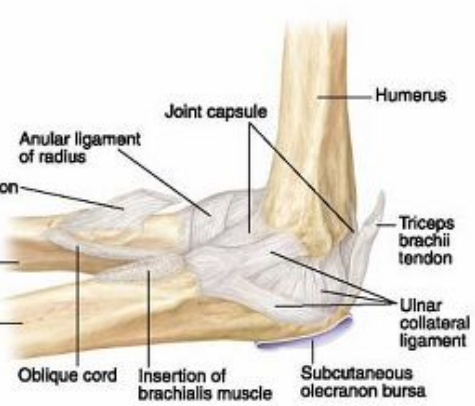
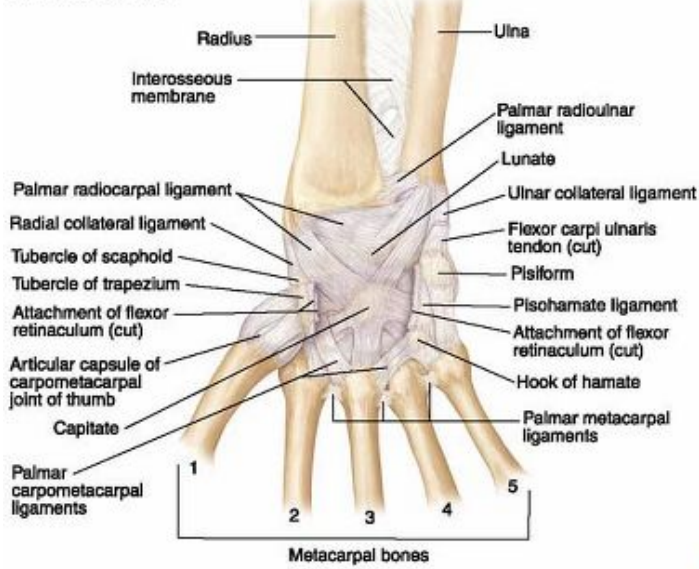


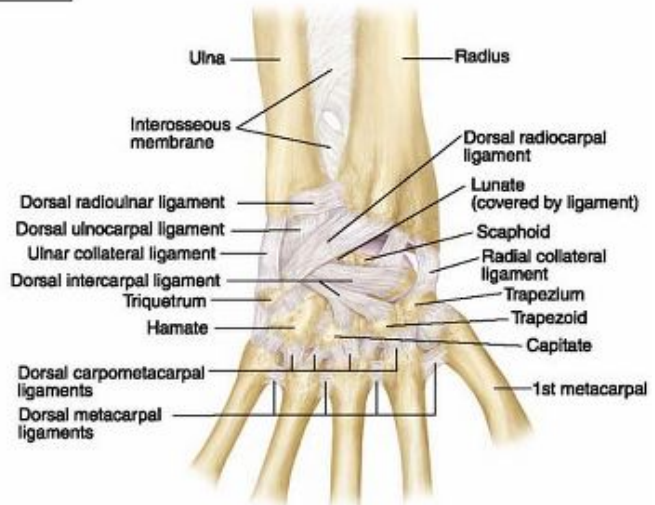
Plate 2-43 Elbow Joint

P.73

A. Anterior view



B. Posterior view



C. Coronal section, posterior view

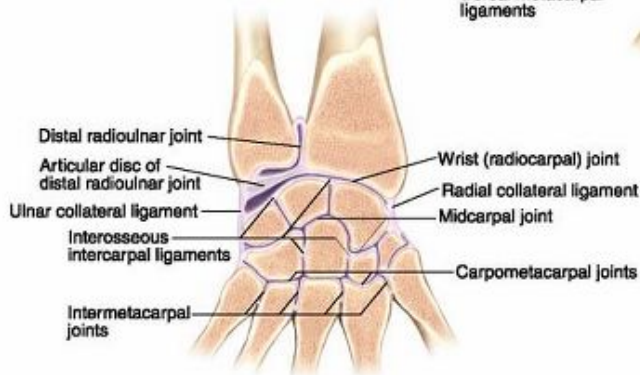
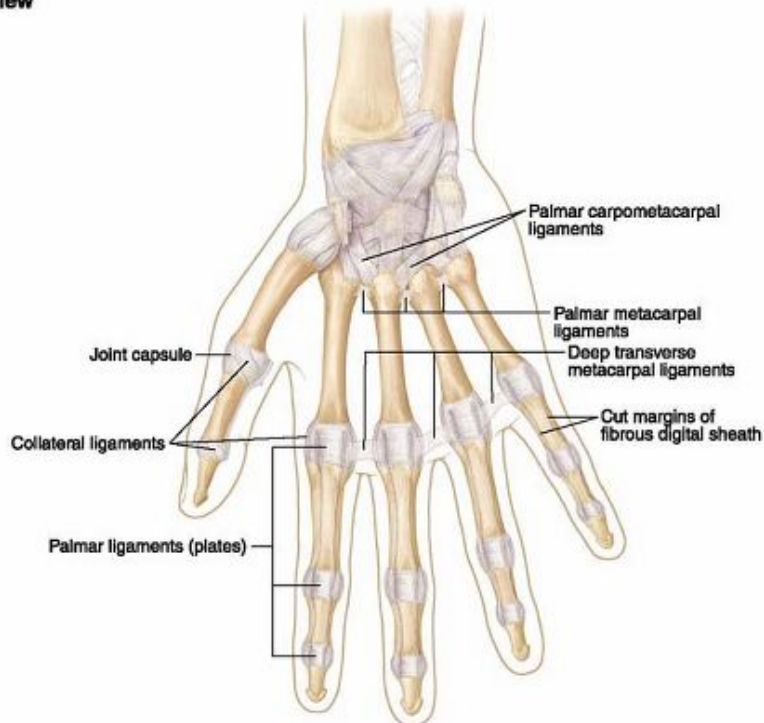
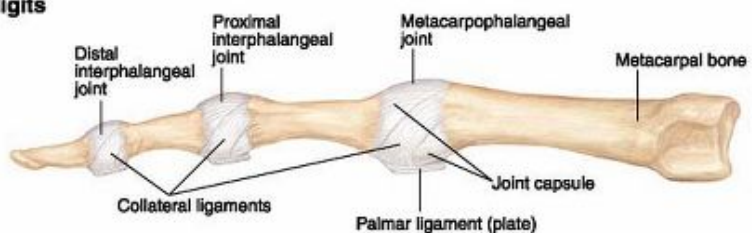


Plate 2-44 Joints of the Wrist

A. Anterior view



B. Joints of the digits



C. Extensor expansion

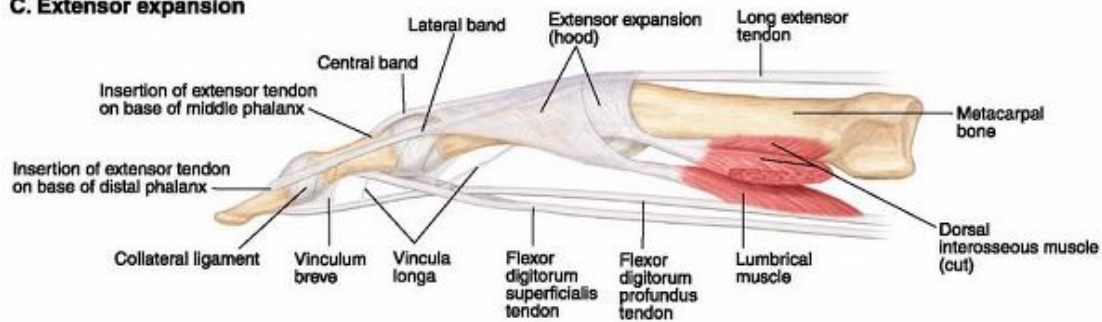
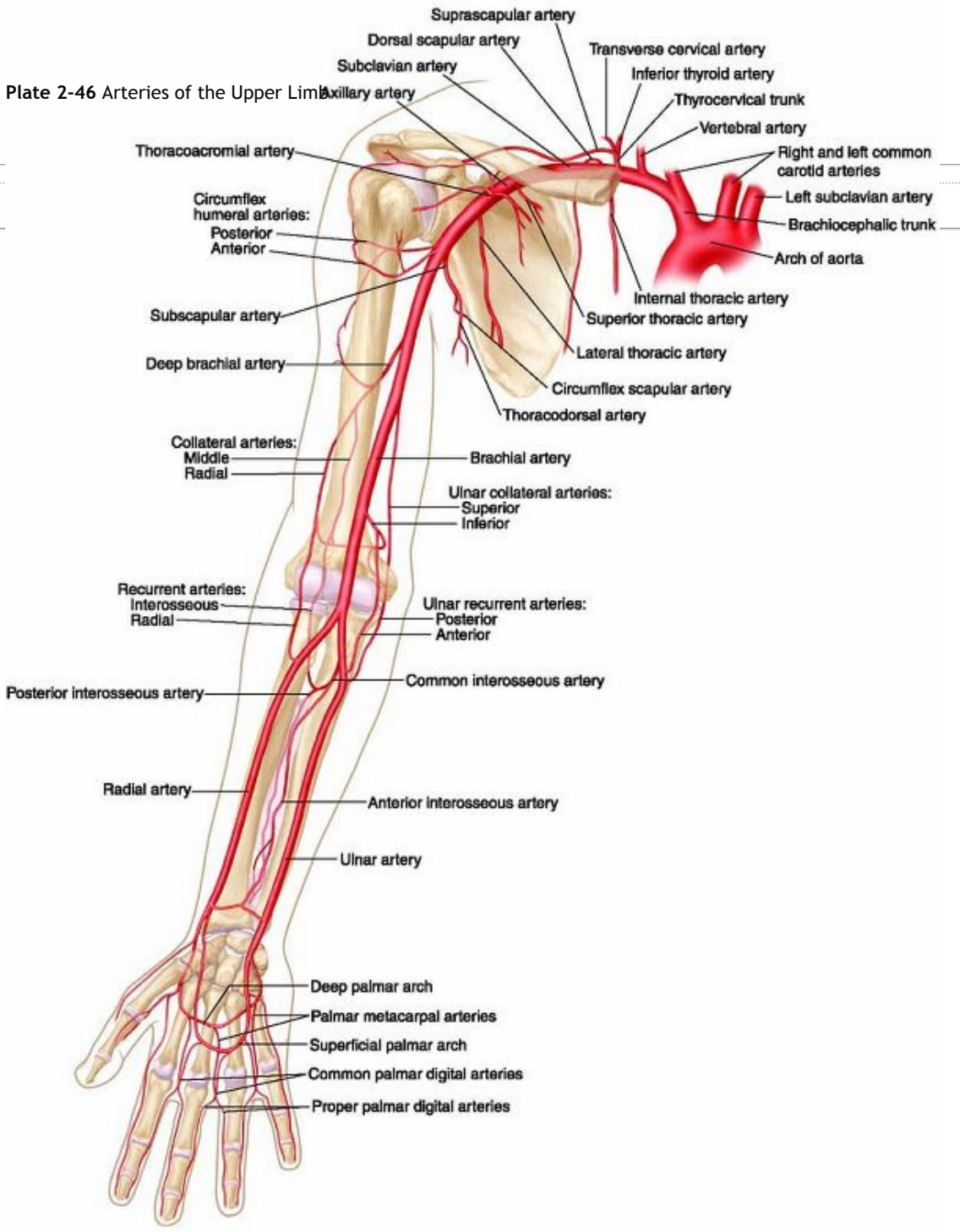




Plate 2-46 Arteries of the Upper Limb



A. Anterior view

Plate 2-47 Musculocutaneous Nerve

Musculocutaneous nerve
(C5-C7)

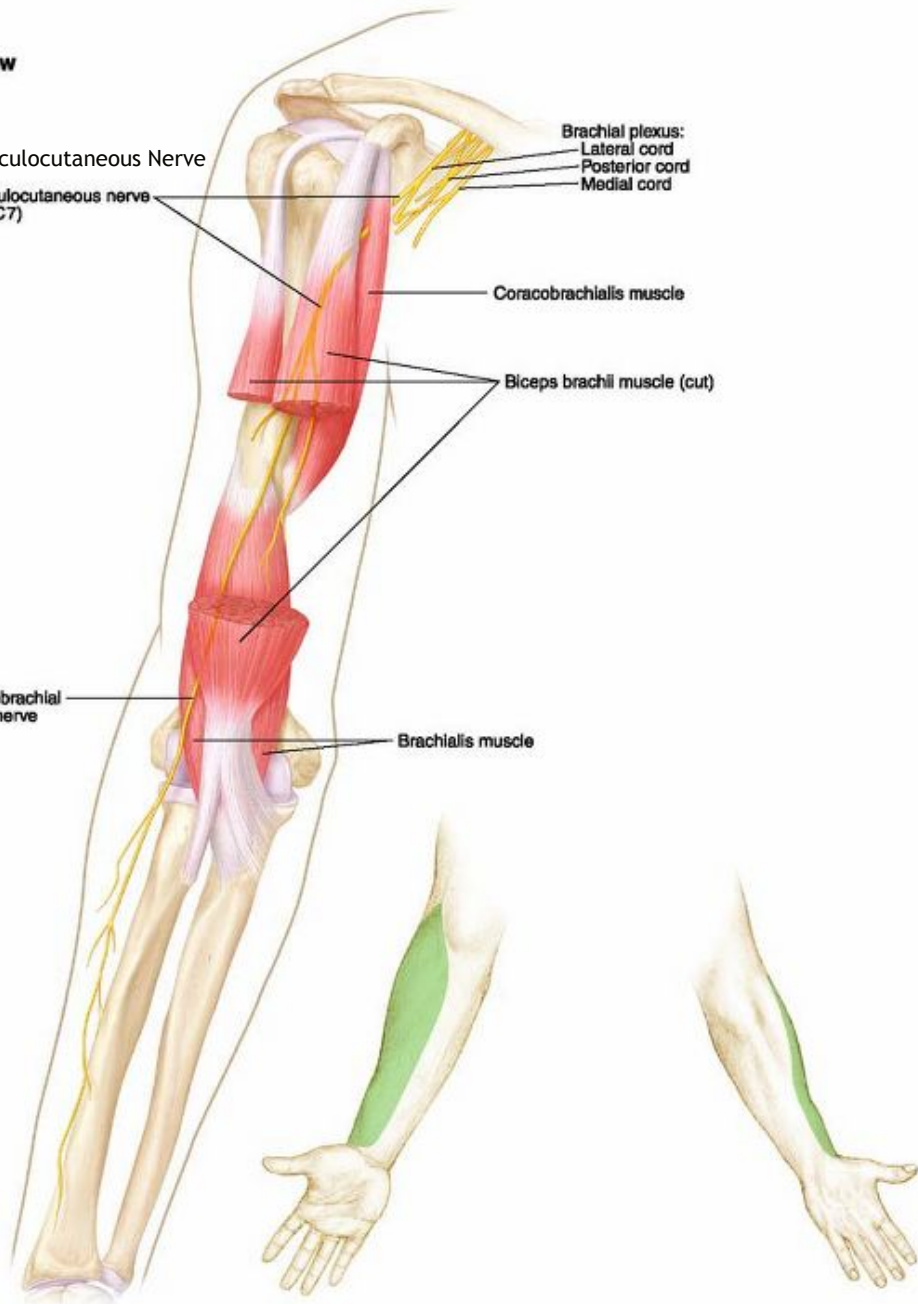
Brachial plexus:
Lateral cord
Posterior cord
Medial cord

Coracobrachialis muscle

Biceps brachii muscle (cut)

Lateral antebrachial
cutaneous nerve

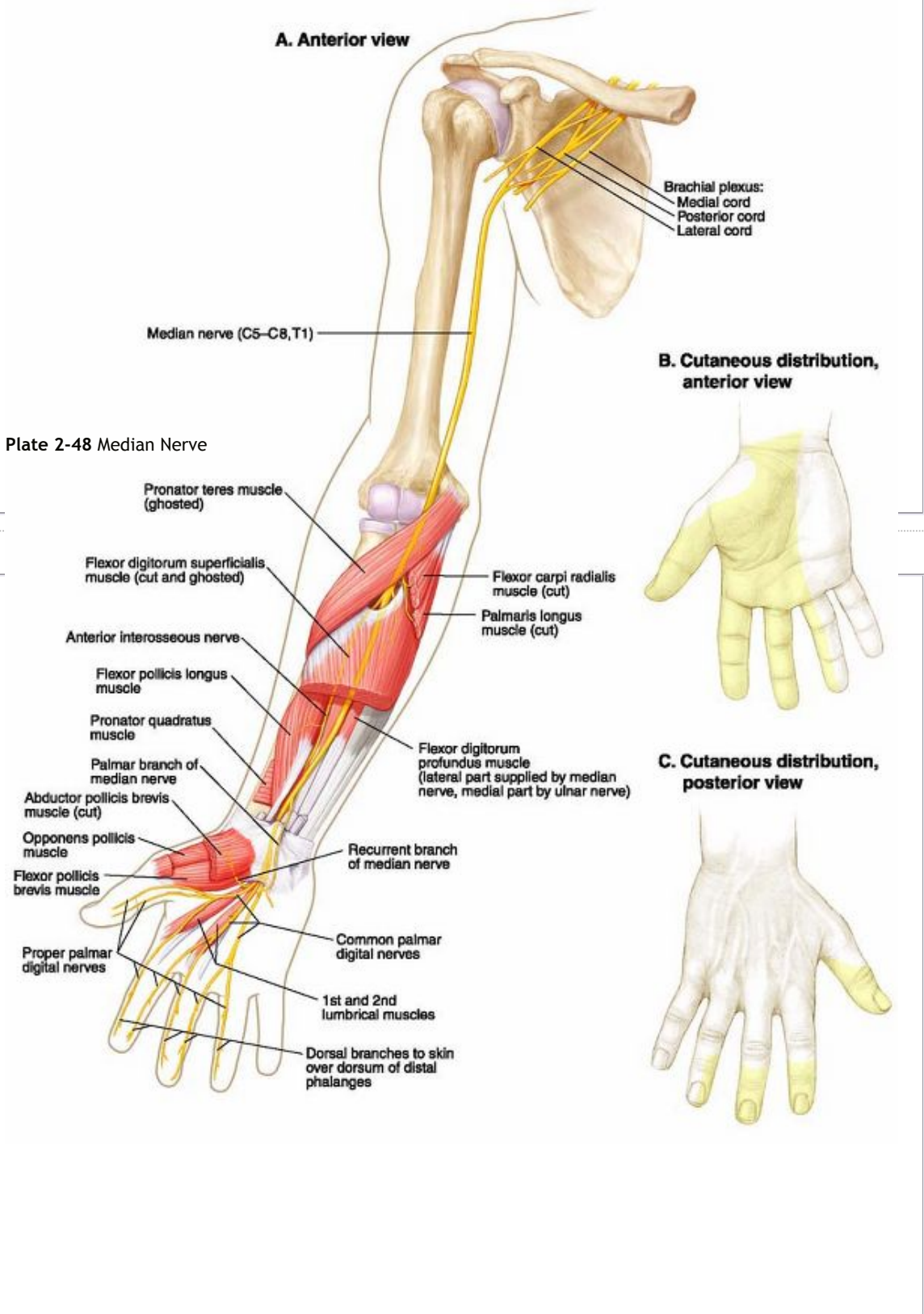
Brachialis muscle

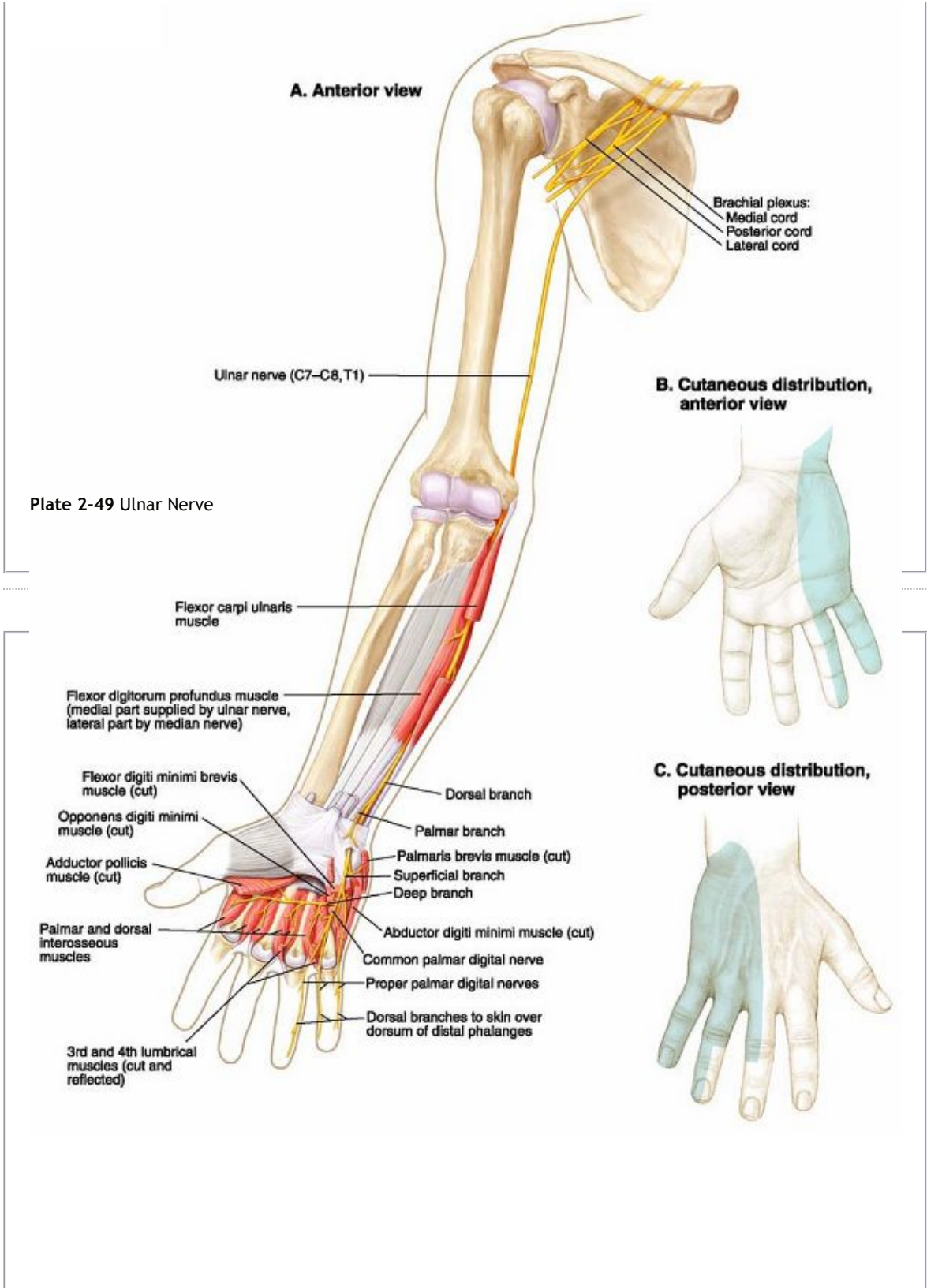


**B. Cutaneous distribution,
anterior view**

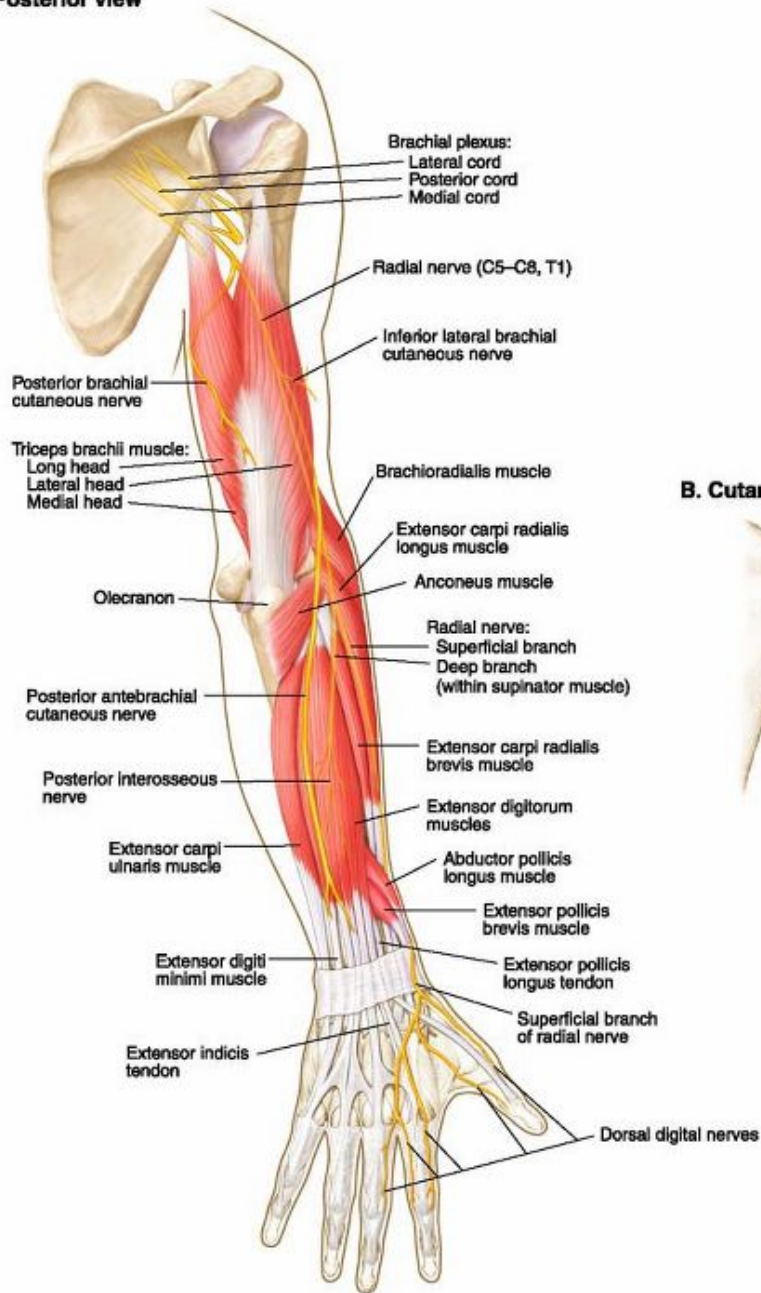
**C. Cutaneous distribution,
posterior view**

Plate 2-48 Median Nerve





A. Posterior view

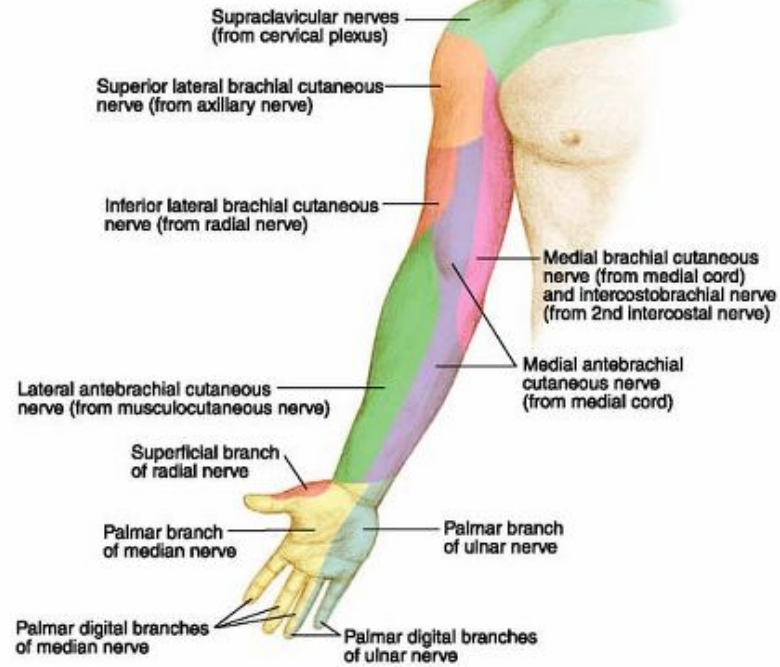


B. Cutaneous distribution

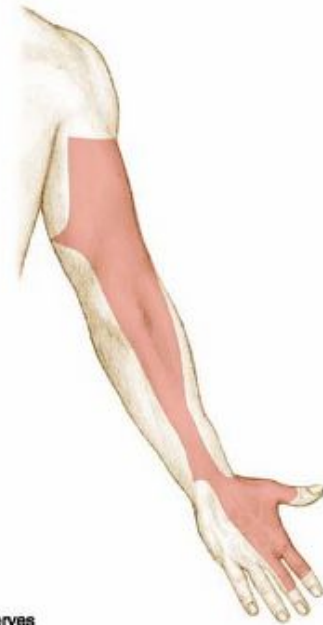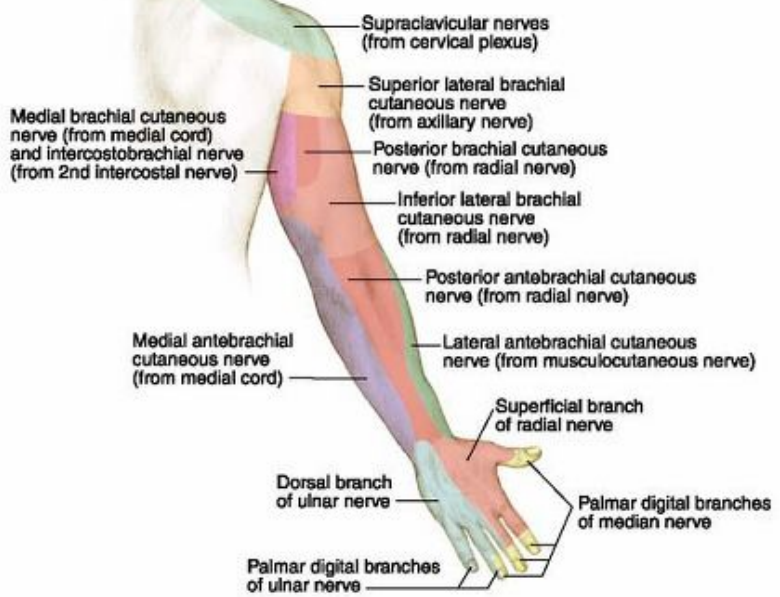


Plate 2-50 Radial Nerve

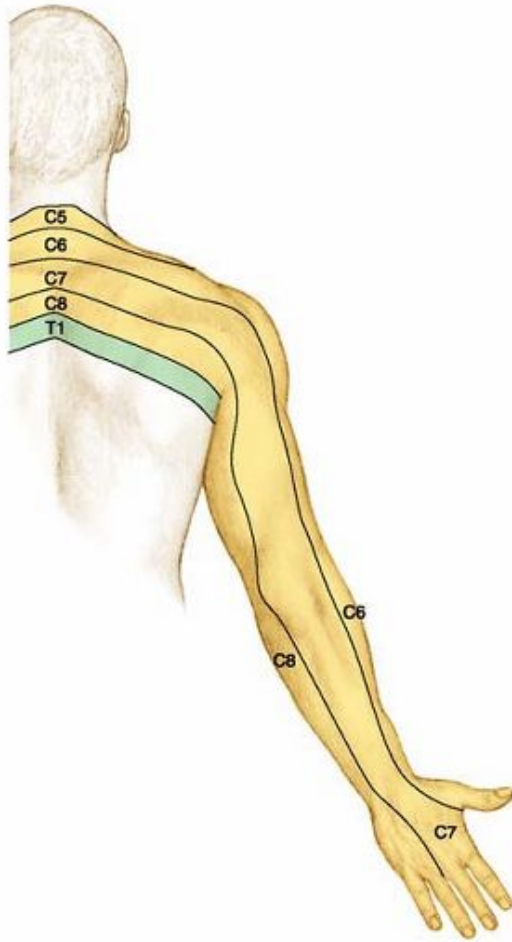
A. Anterior view



B. Posterior view



A. Posterior view



B. Anterior view

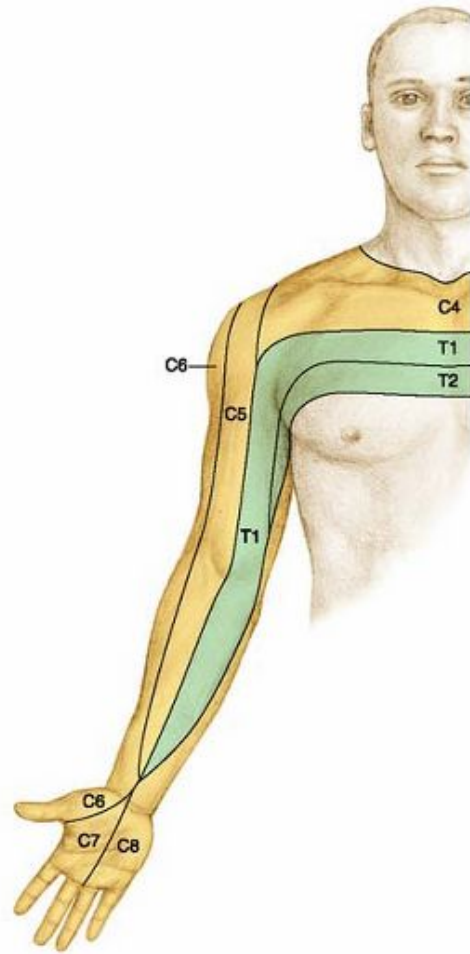
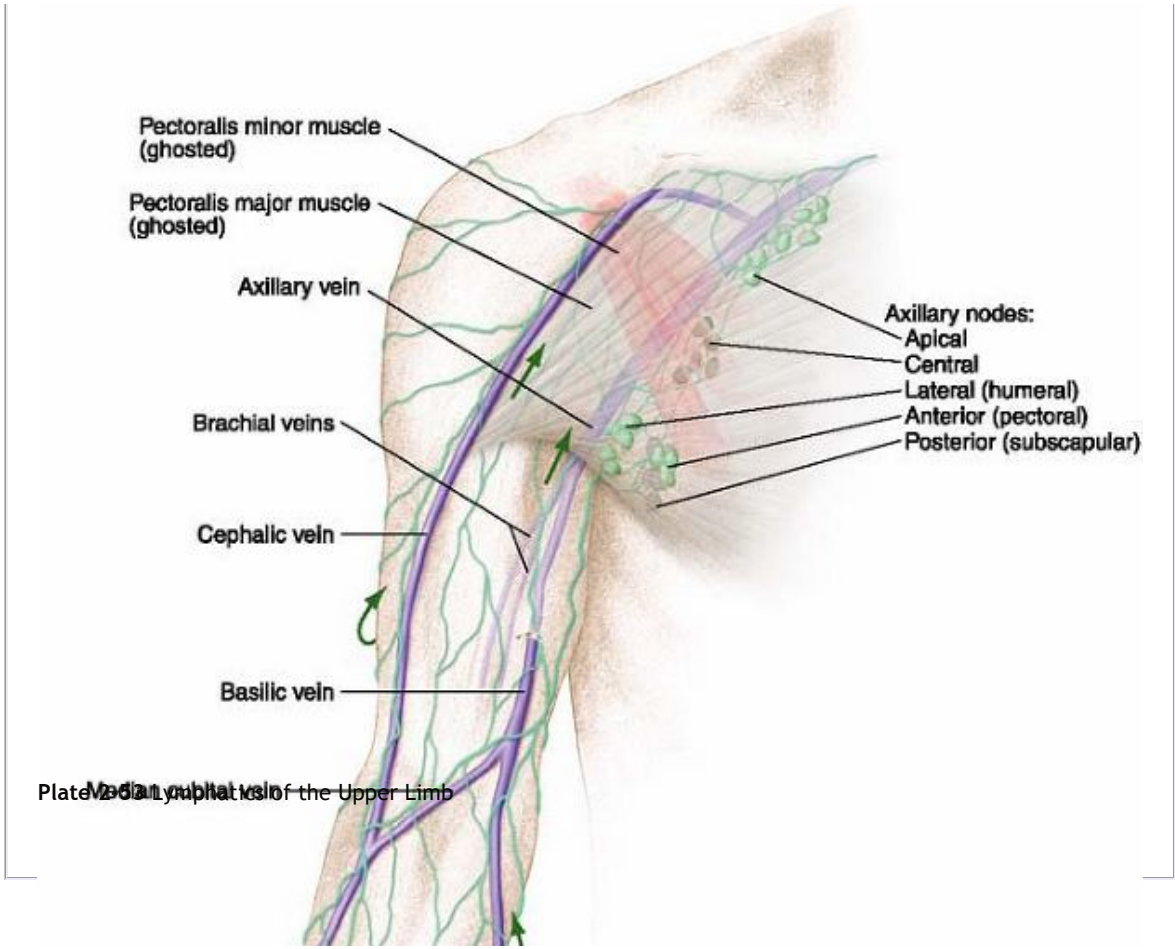


Plate 2-52 Dermatomes of the Upper Limb



Authors: Tank, Patrick W.; Gest, Thomas R.

Title: *Lippincott Williams & Wilkins Atlas of Anatomy, 1st Edition*

Copyright ©2009 Lippincott Williams & Wilkins

> Table of Contents > Chapter 3 - The Lower Limb

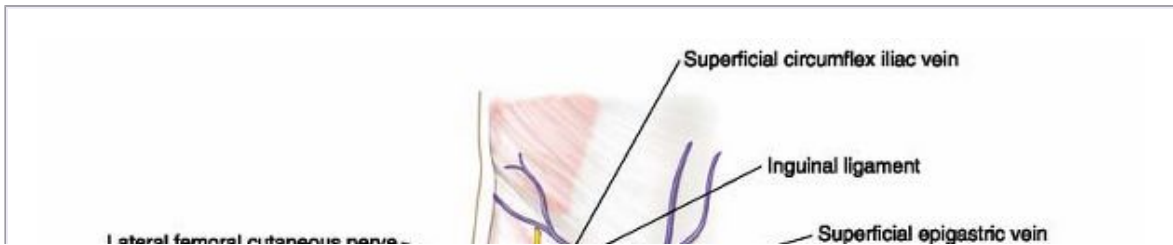
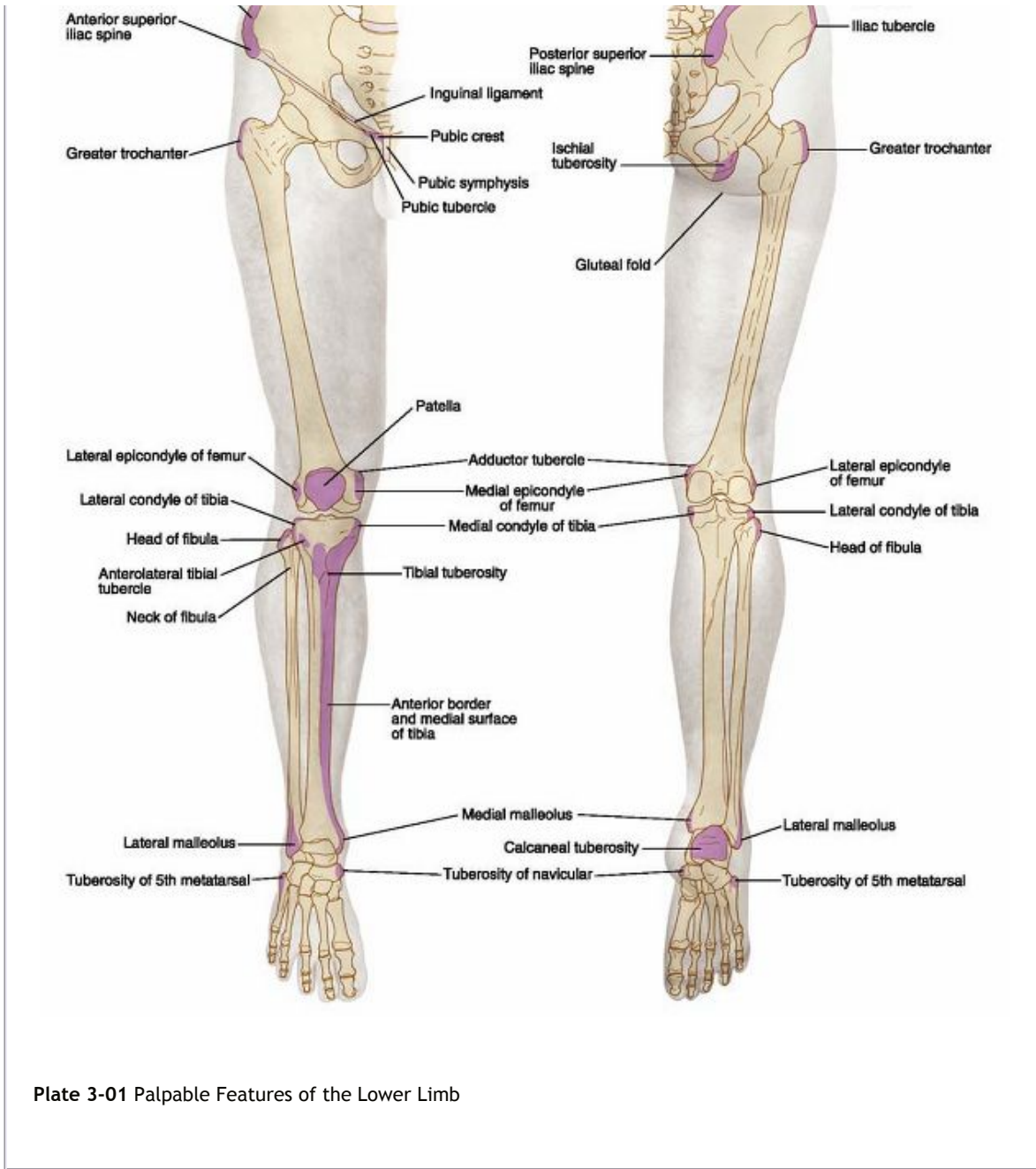
Chapter 3

The Lower Limb

P.86

P.87





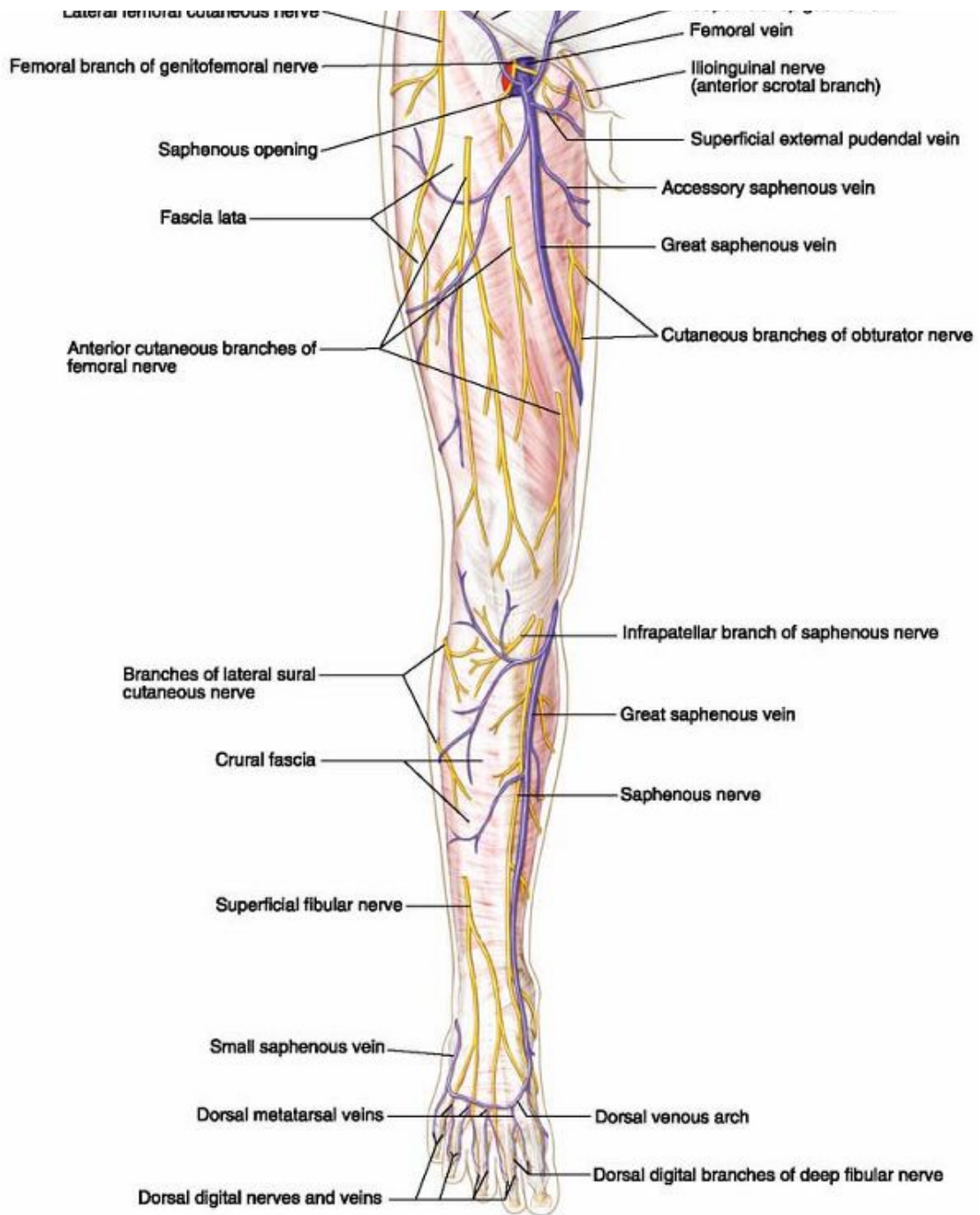
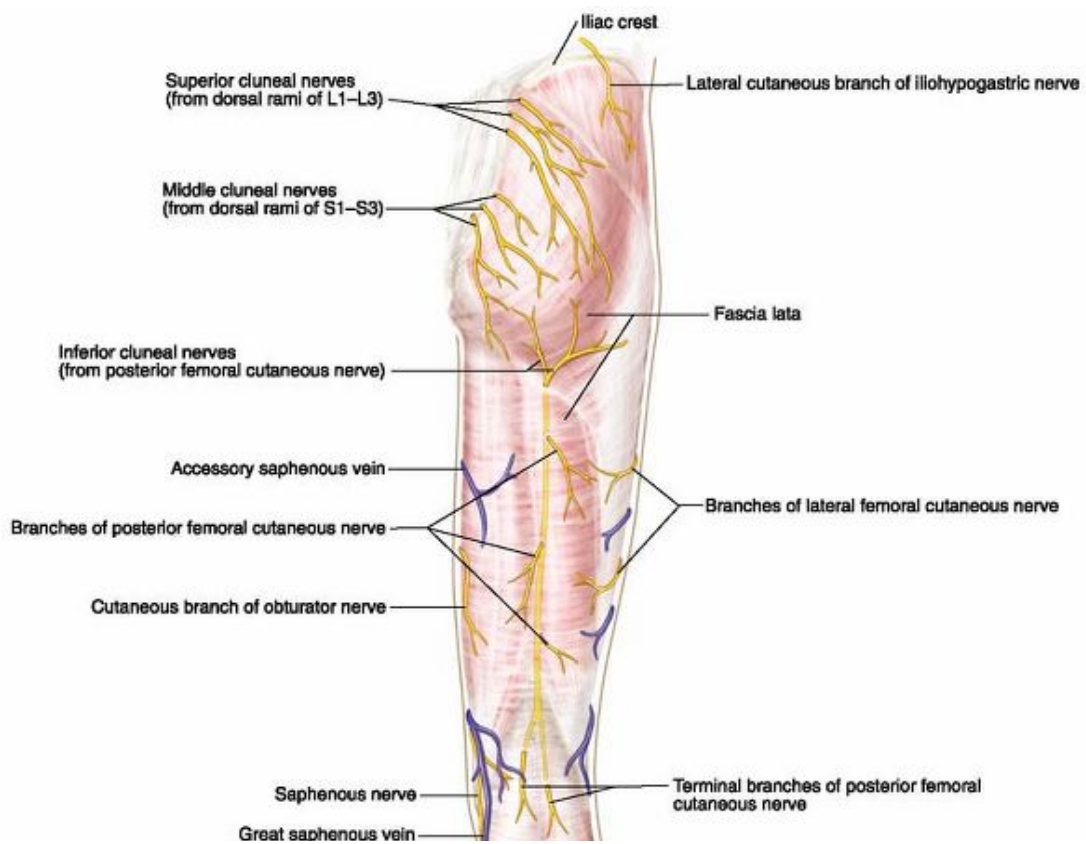


Plate 3-02 Cutaneous Nerves and Superficial Veins of the Lower Limb, Anterior View



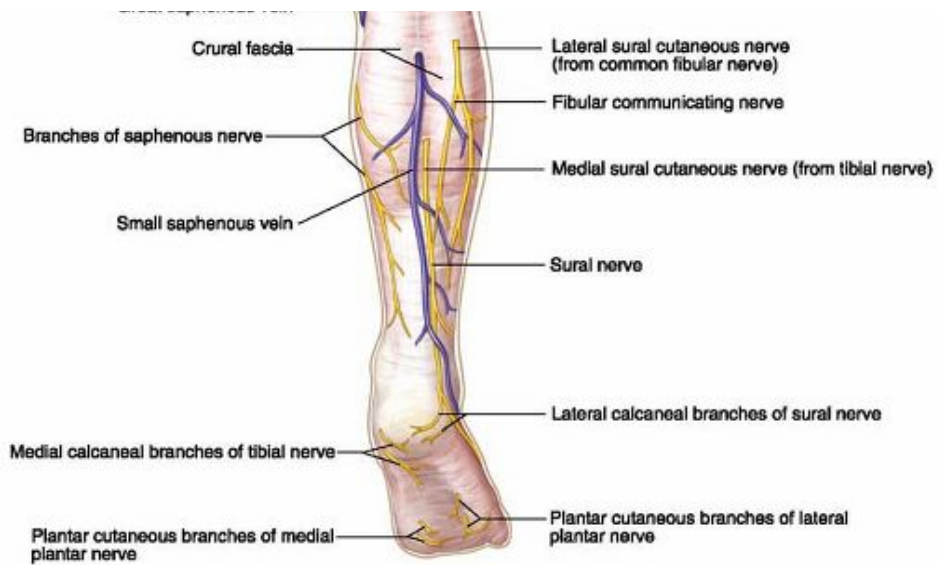
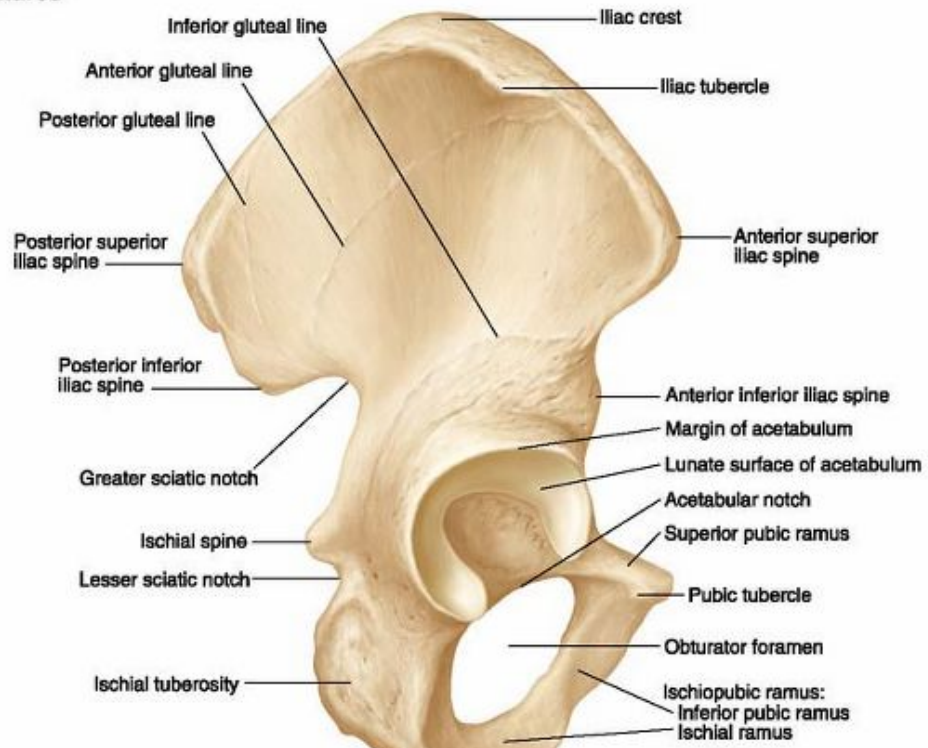


Plate 3-03 Cutaneous Nerves and Superficial Veins of the Lower Limb, Posterior View

A. Bony features



B. Parts of os coxae

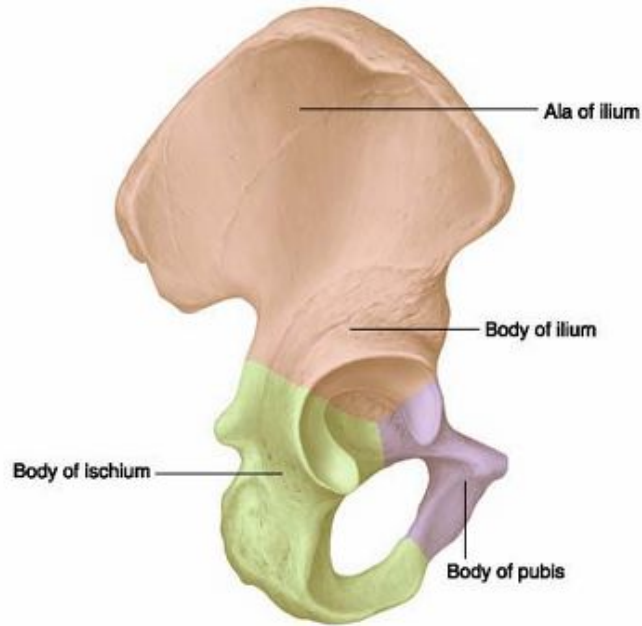
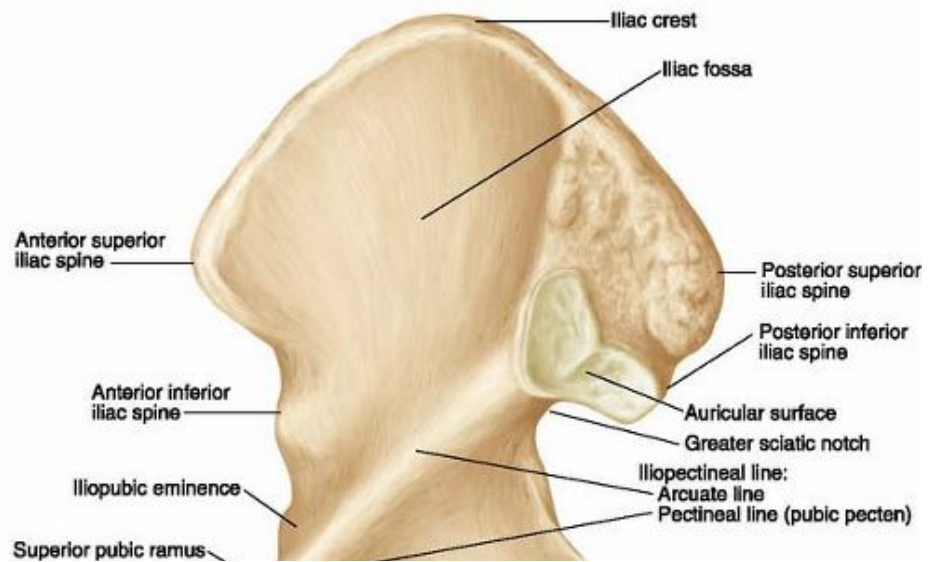
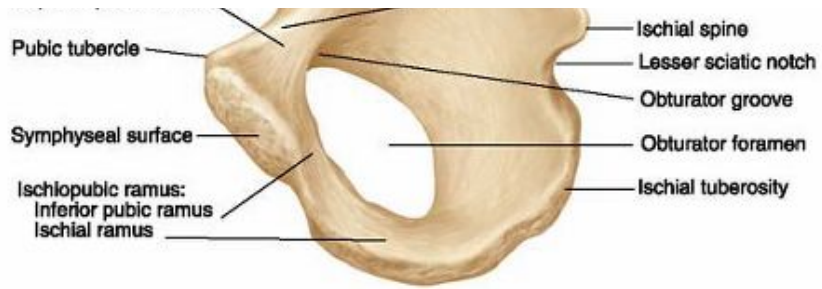


Plate 3-04 Skeleton of the Hip (Os Coxae Bone), Lateral View

A. Bony features





B. Parts of os coxae

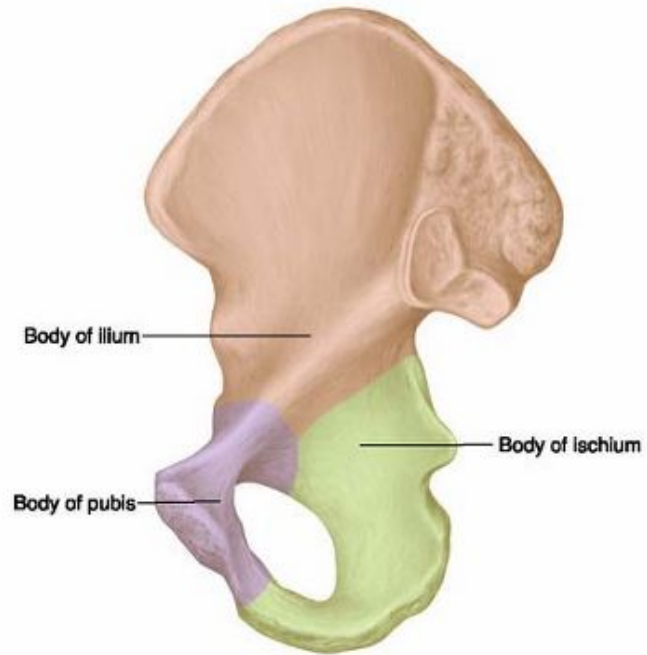
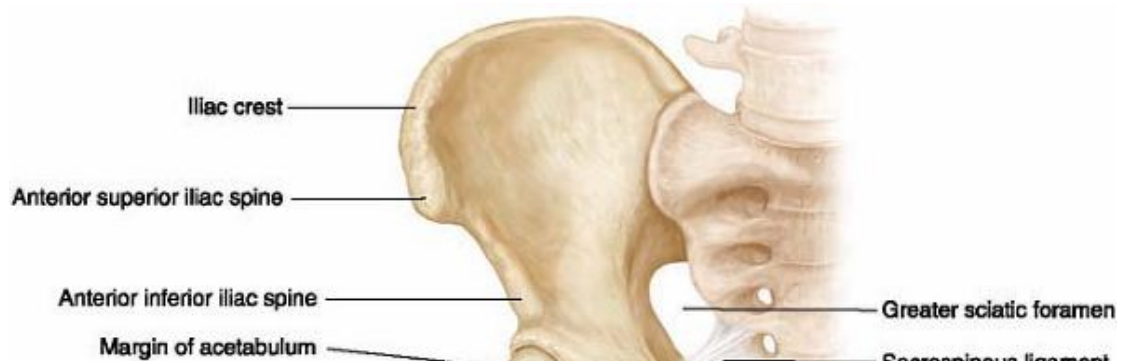


Plate 3-05 Skeleton of the Hip (Os Coxae Bone), Medial View



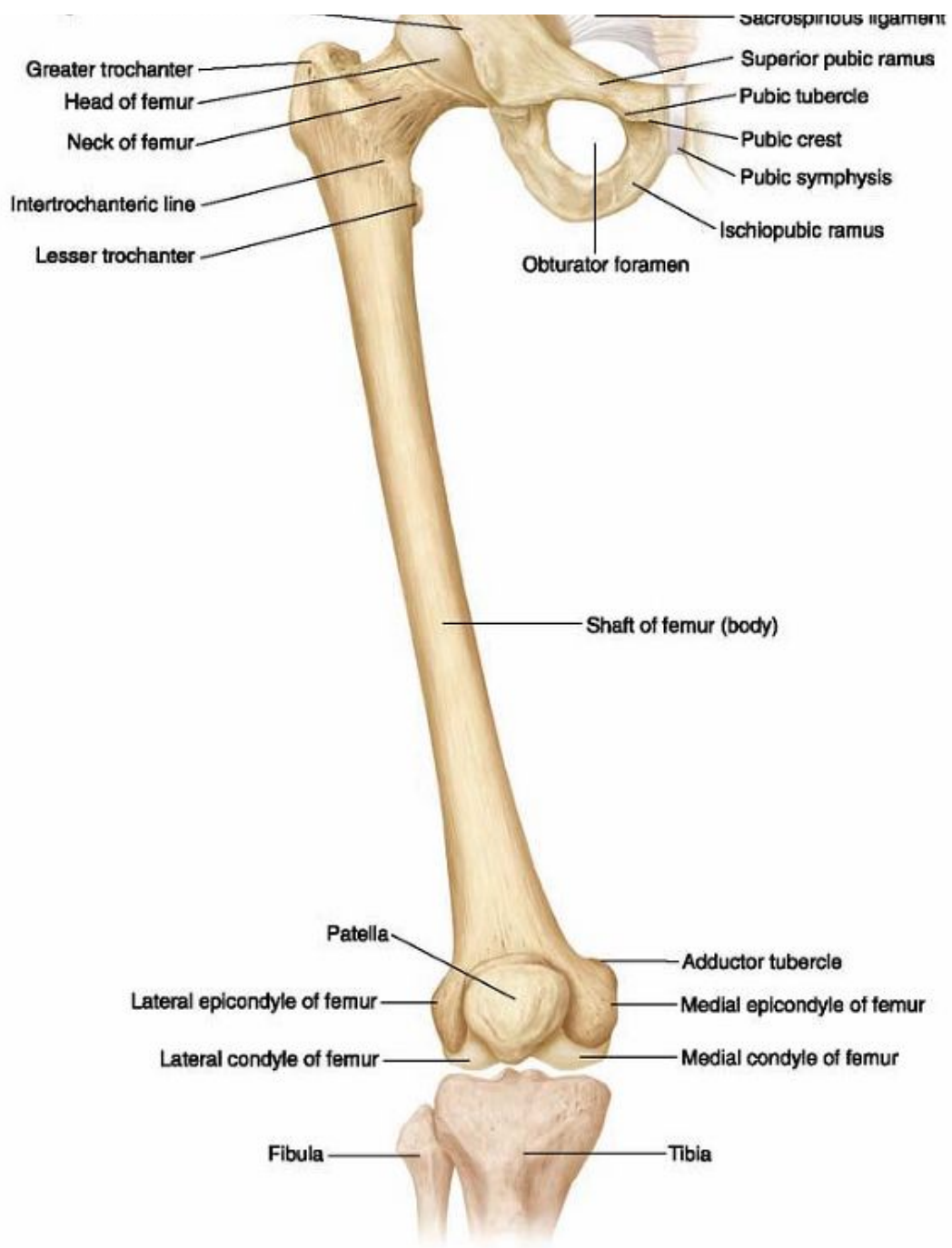


Plate 3-06 Skeleton of the Proximal Lower Limb, Anterior View

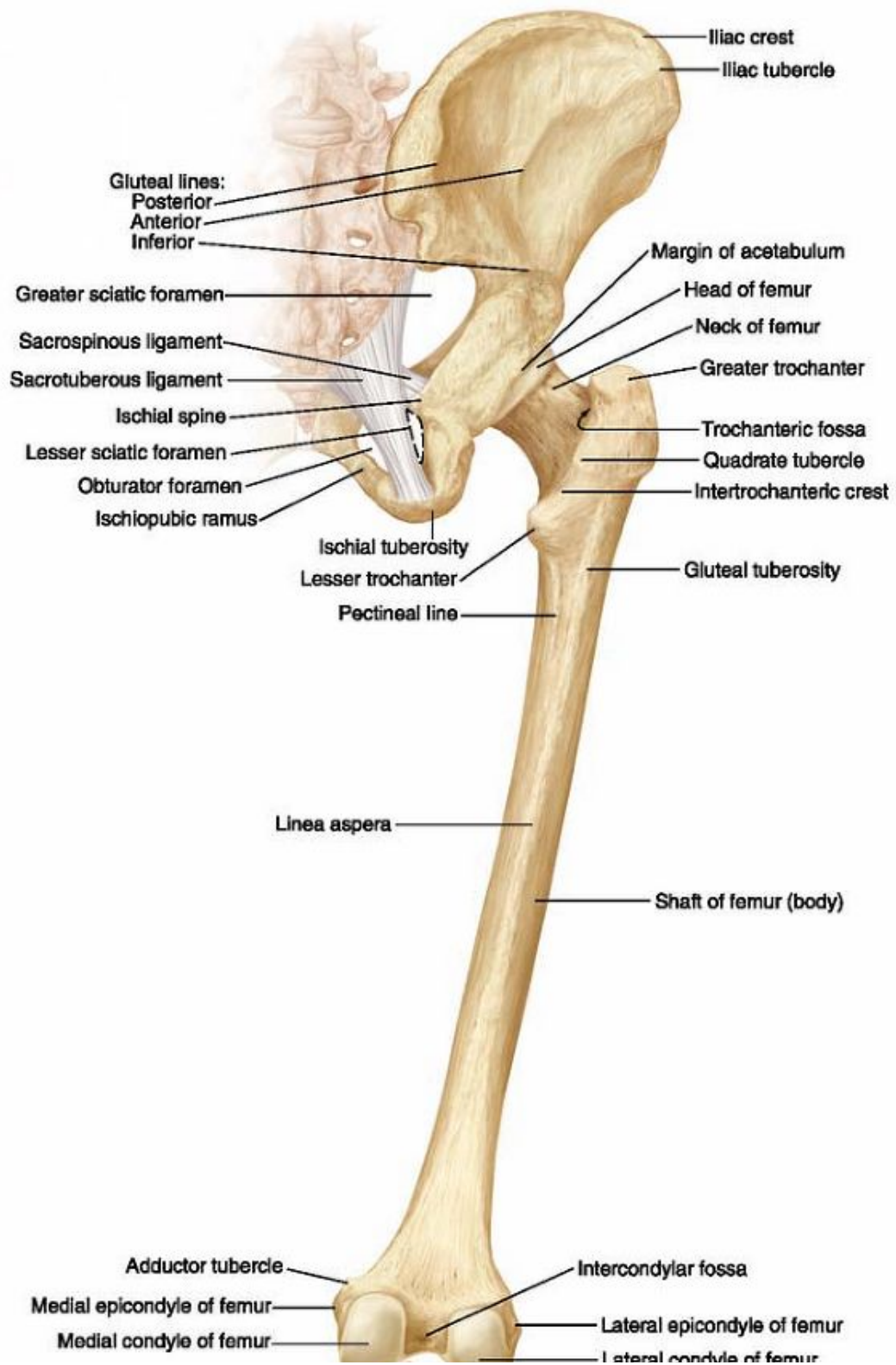
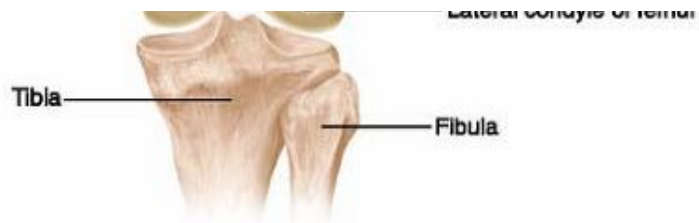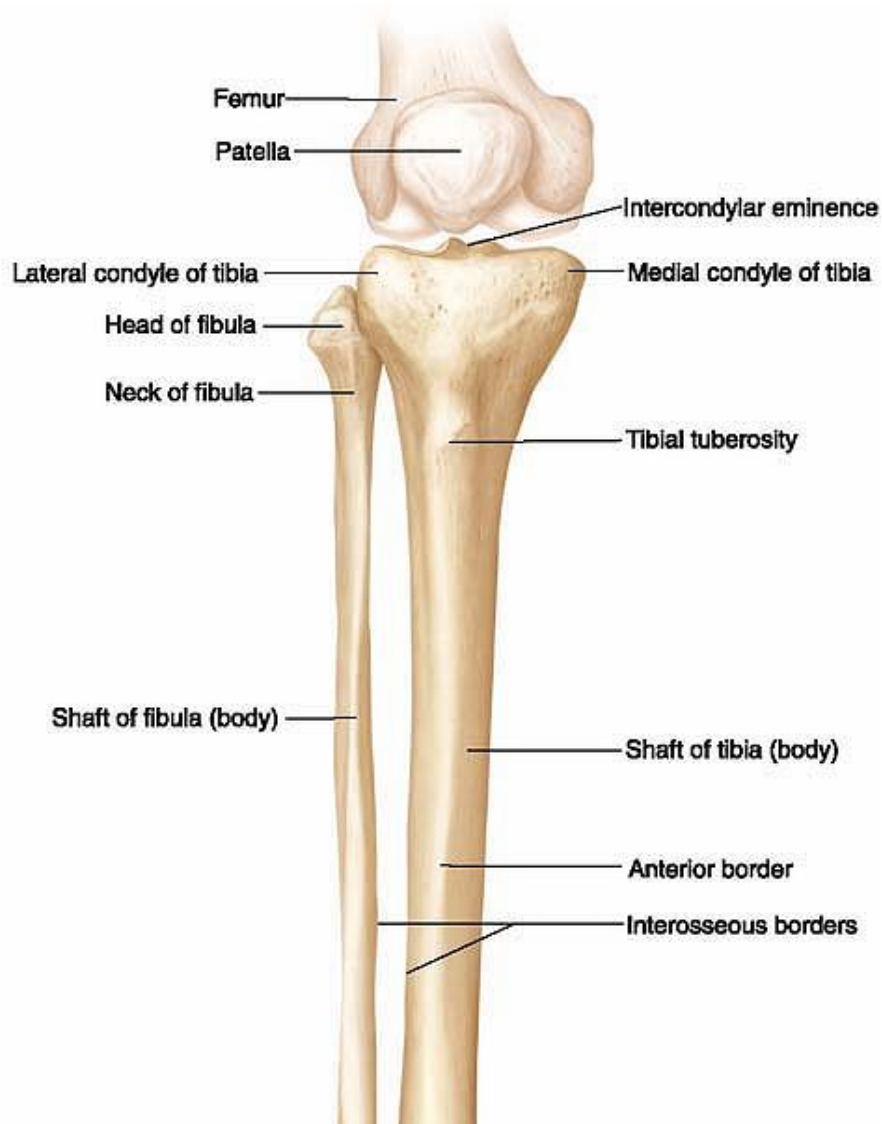




Plate 3-07 Skeleton of the Proximal Lower Limb, Posterior View



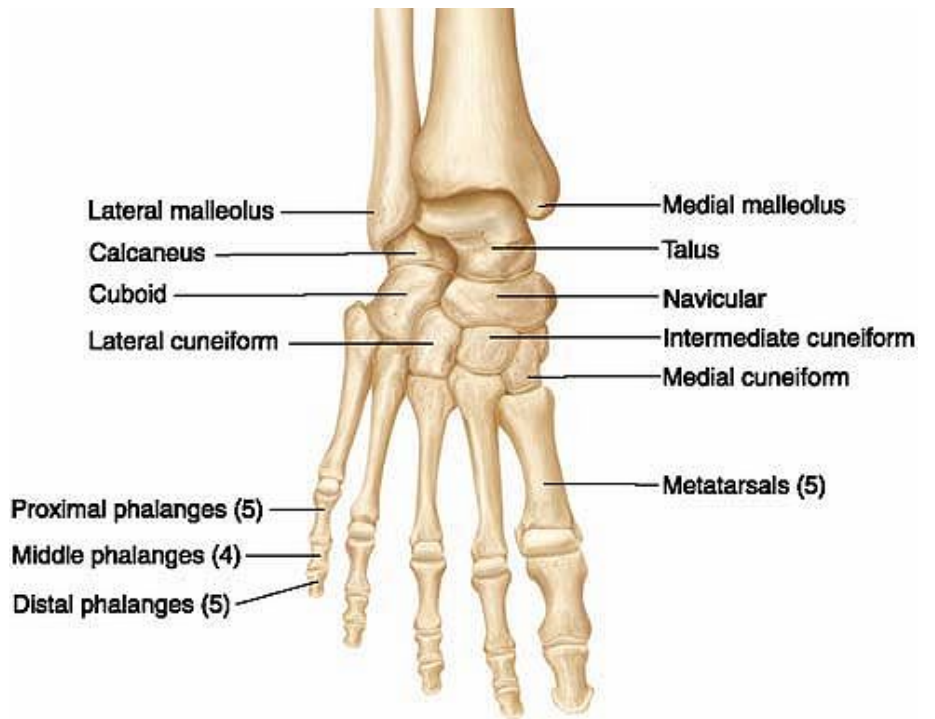
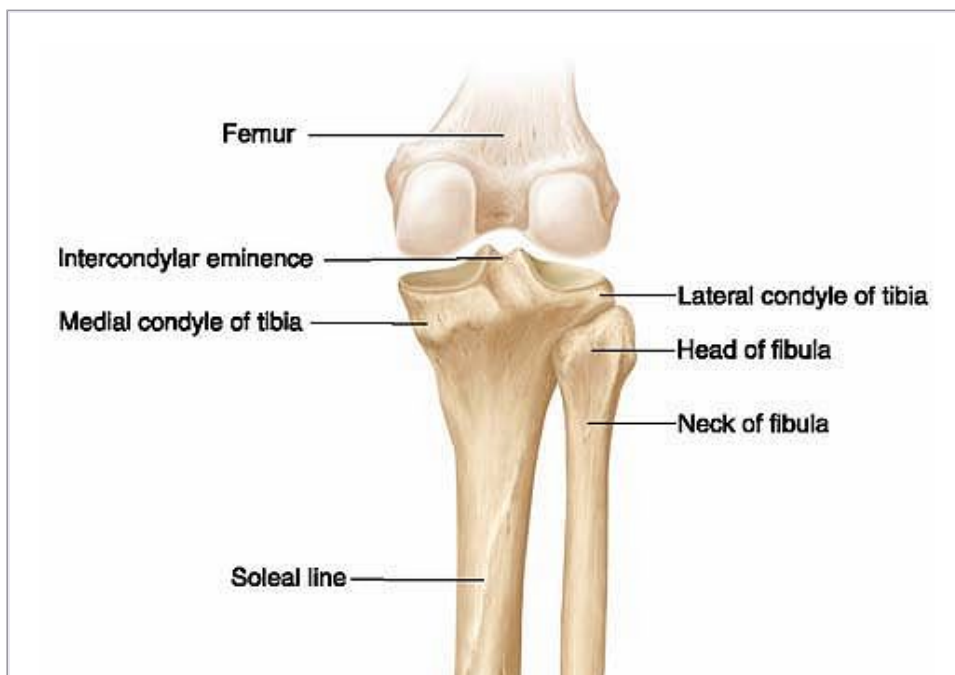


Plate 3-08 Skeleton of the Distal Lower Limb, Anterior View



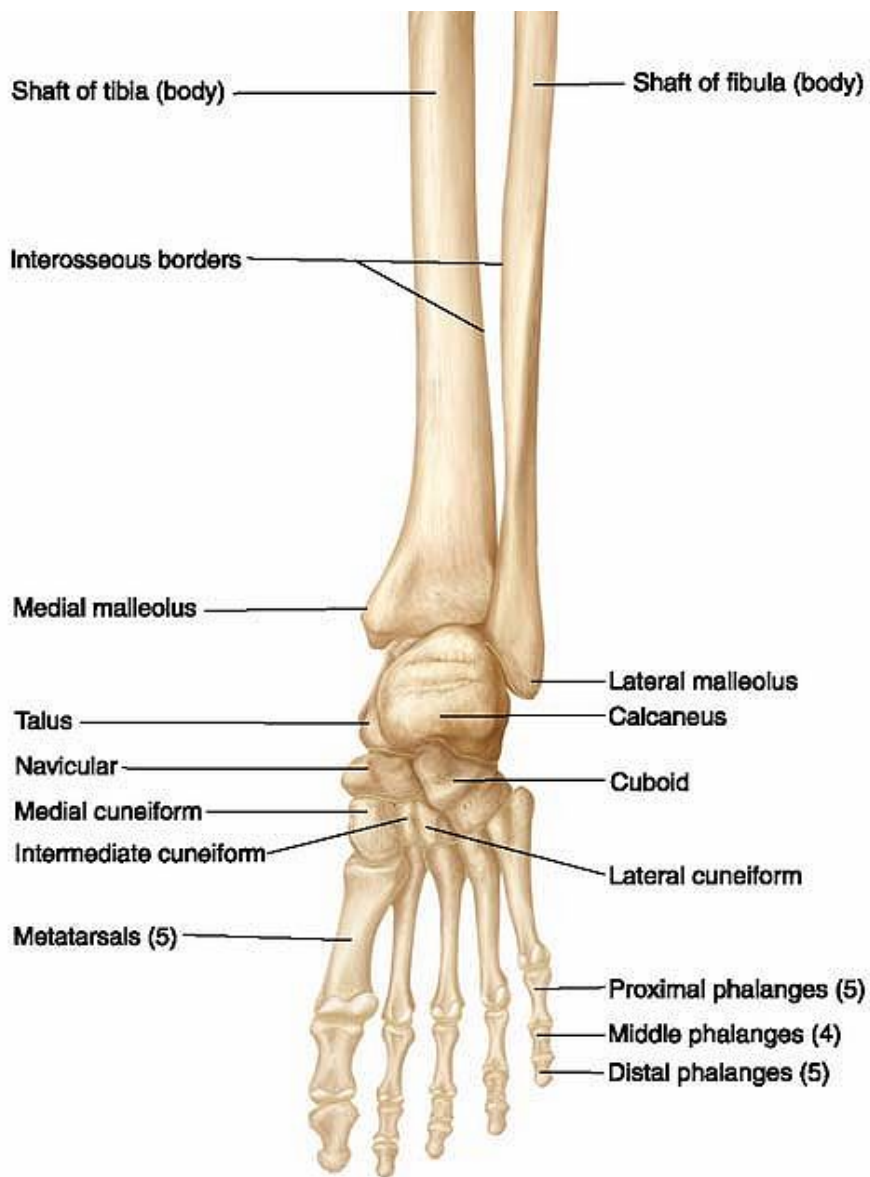
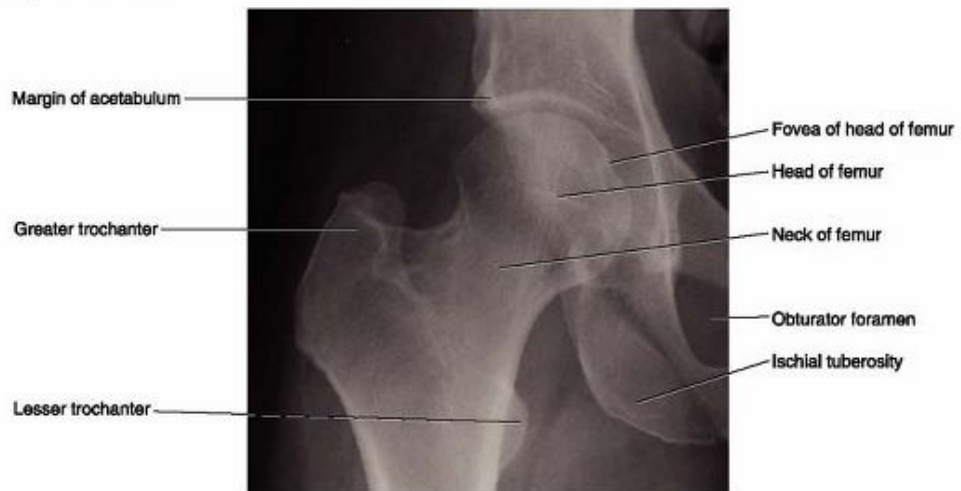

Plate 3-09 Skeleton of the Distal Lower Limb, Posterior View

A. Hip joint, anterior view



B. Knee joint, anterior view

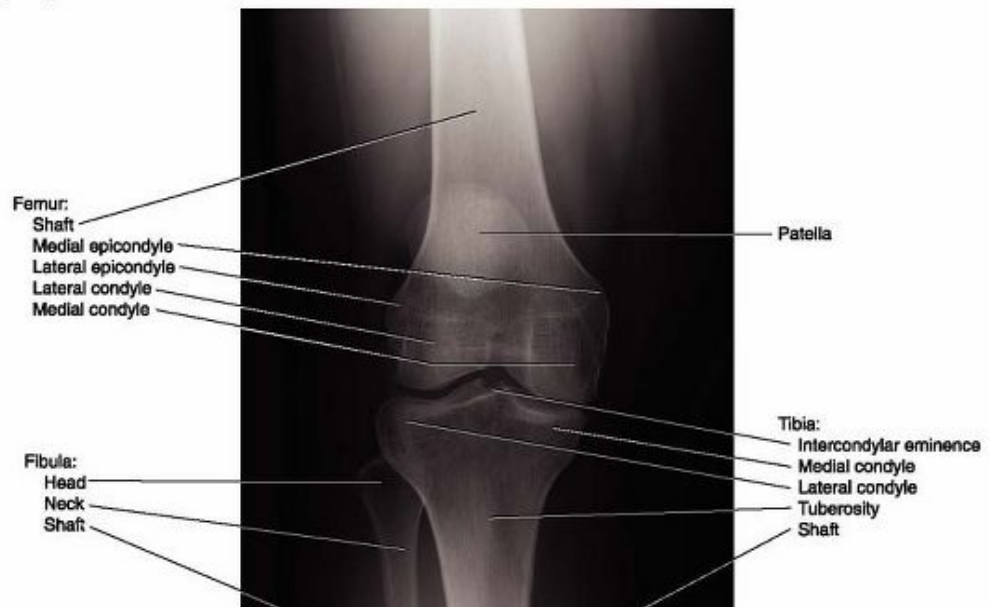
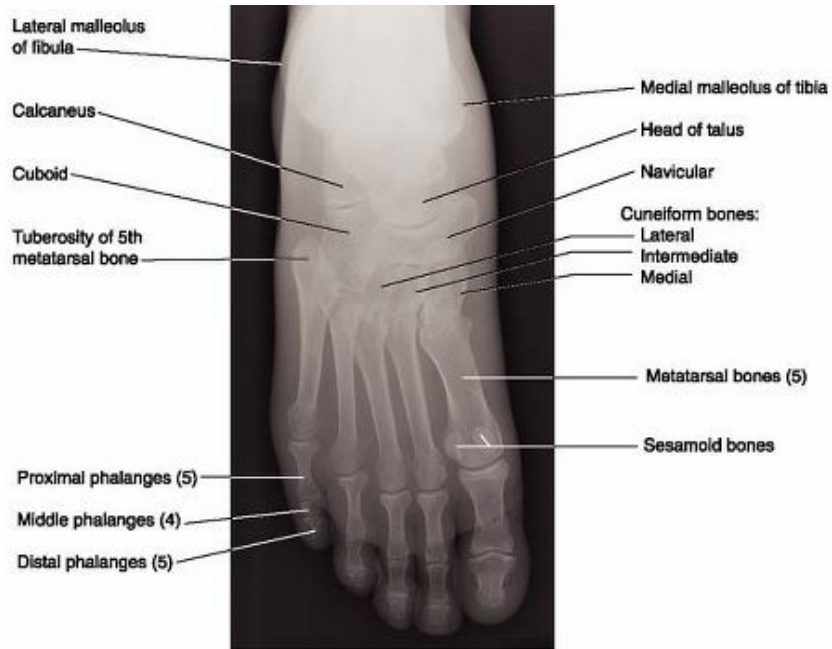




Plate 3-10 Radiographs of the Lower Limb

A. Anterior view





B. Lateral view

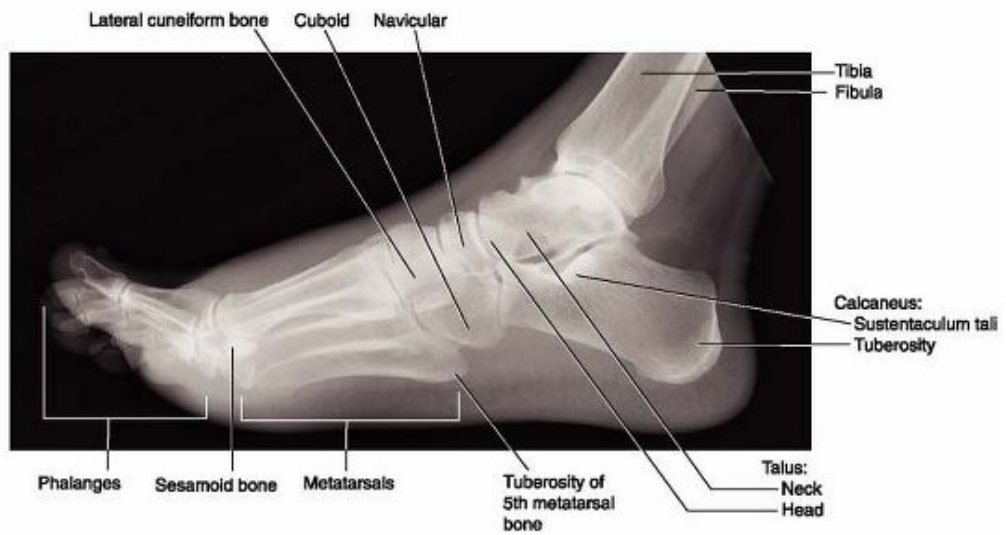


Plate 3-11 Radiographs of the Foot and Ankle

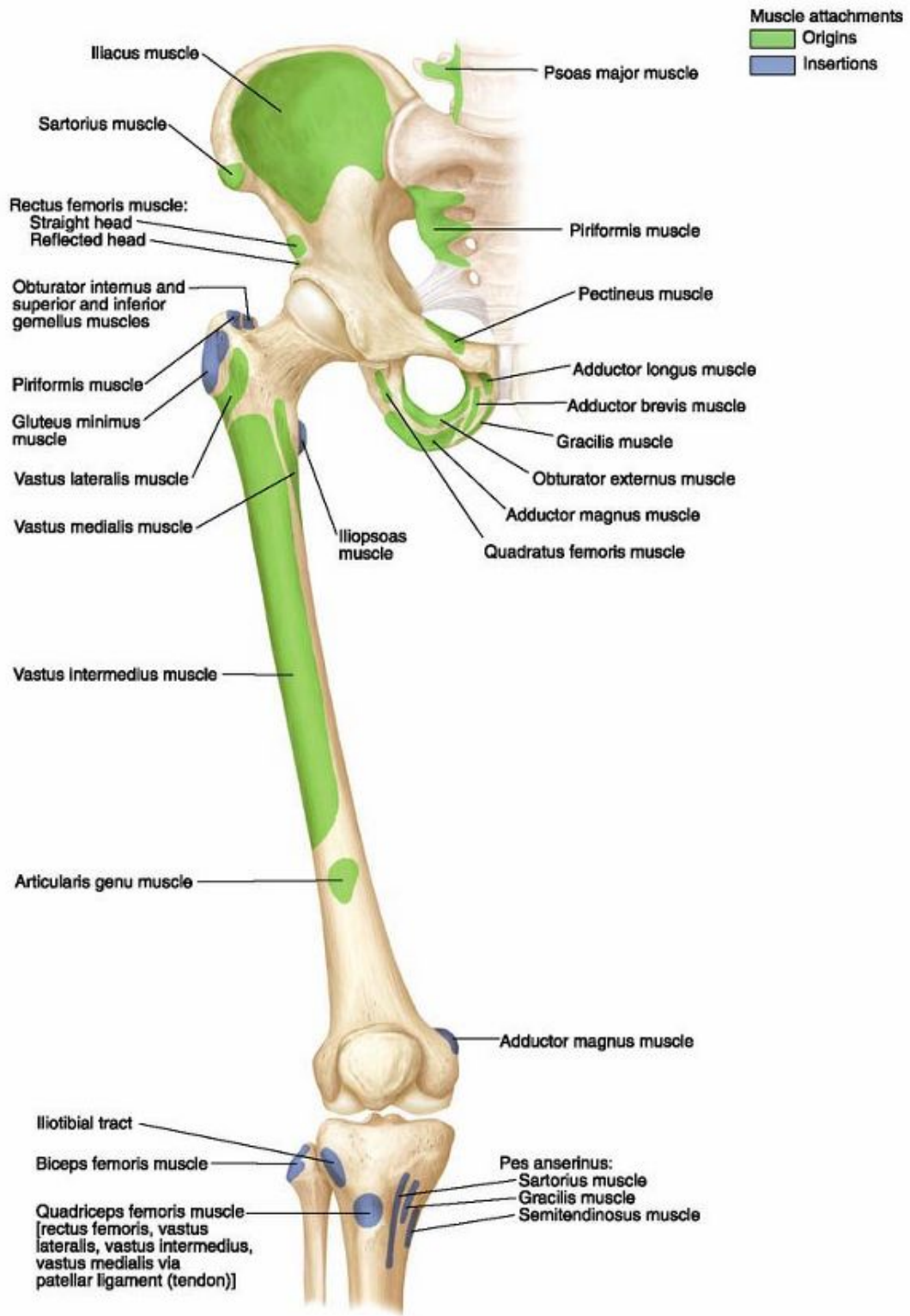


Plate 3-17 Muscle Attachments of the Proximal Lower Limb Anterior View

FIGURE 12.12 Muscle Attachments of the Proximal Lower Limb, Anterior View

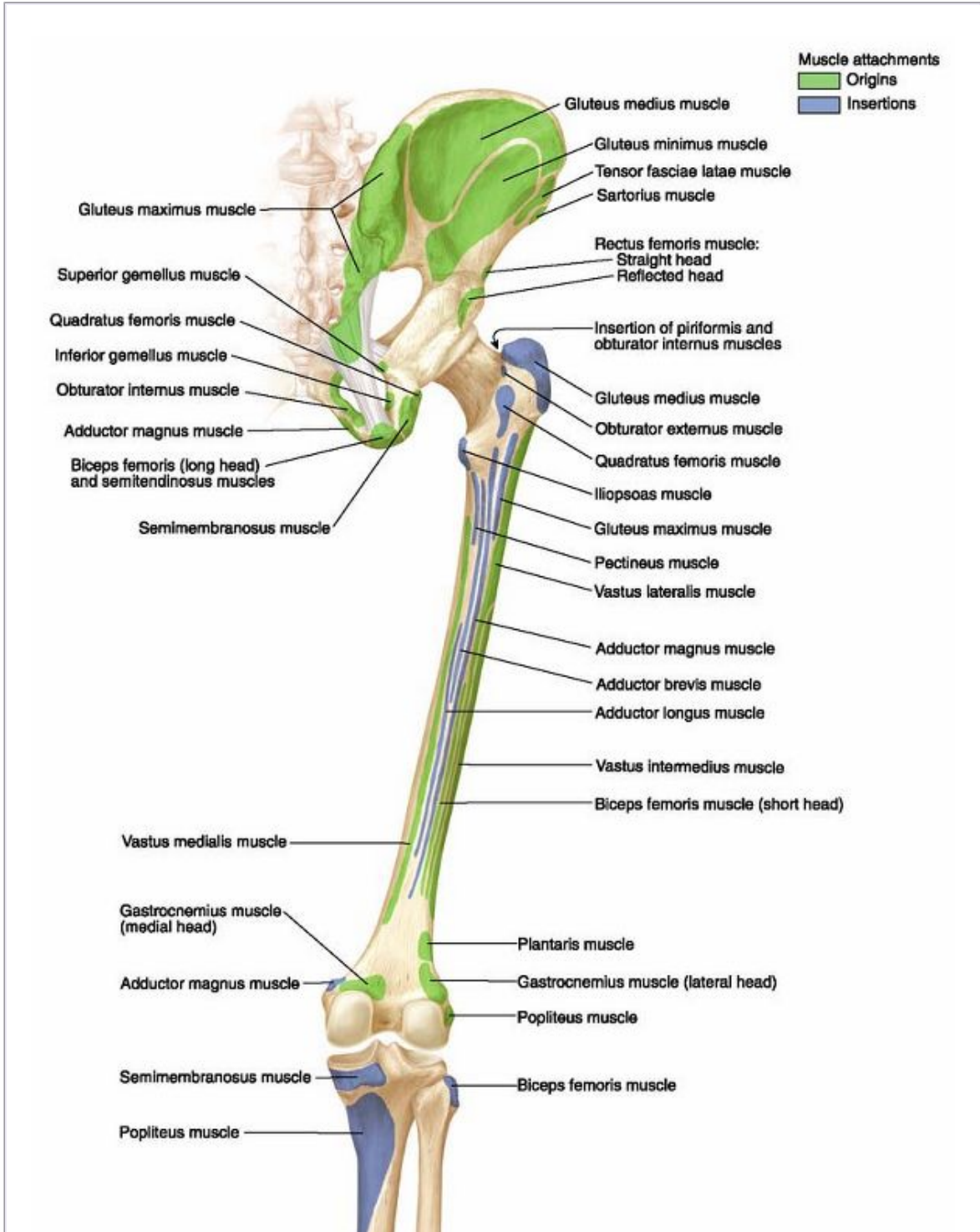




Plate 3-13 Muscle Attachments of the Proximal Lower Limb, Posterior View

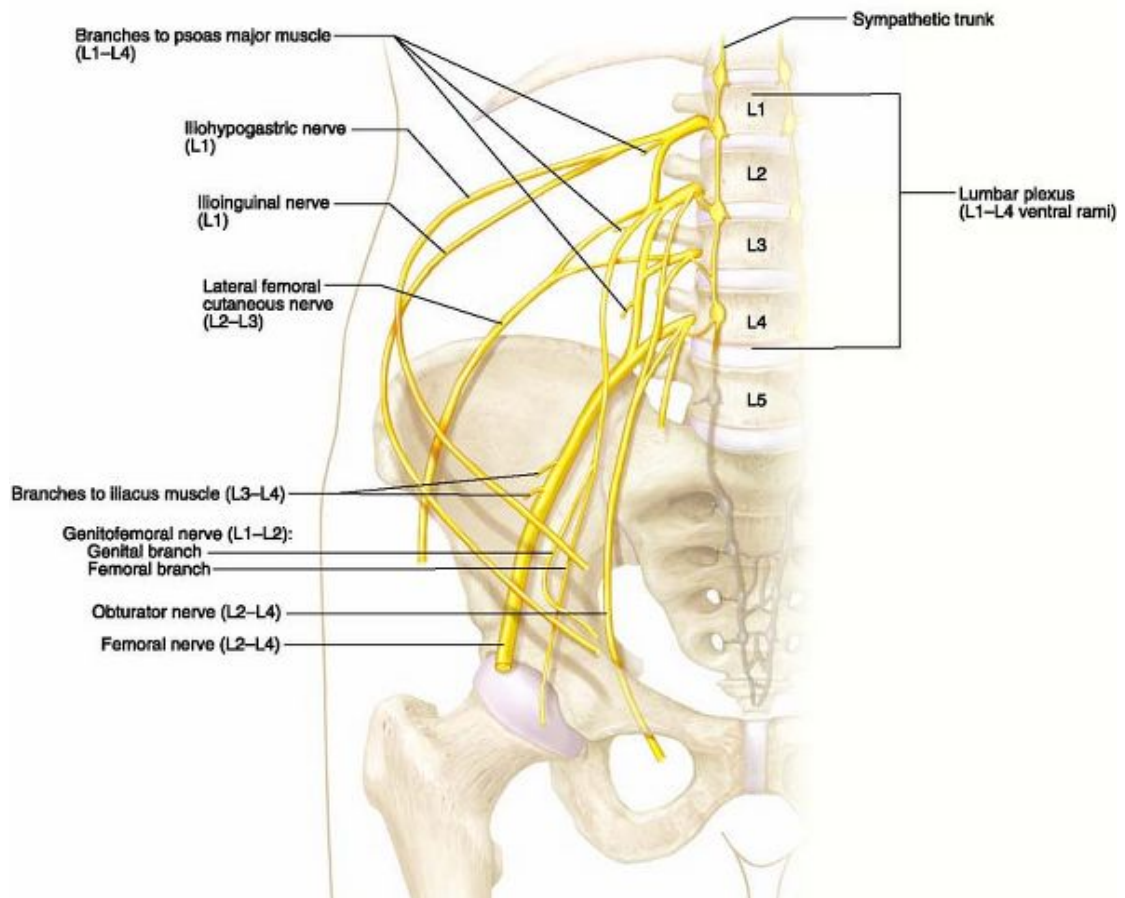
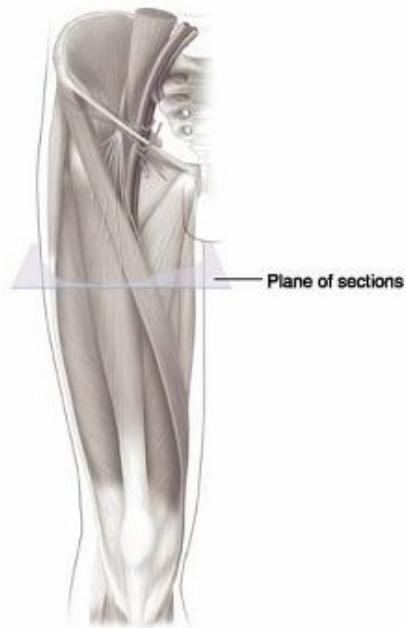


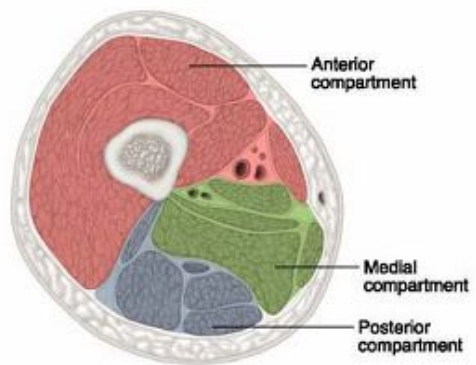


Plate 3-14 Lumbar Plexus

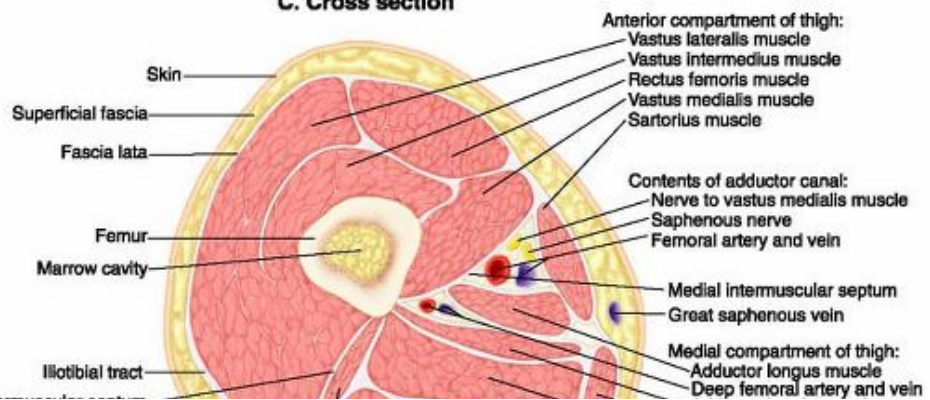
A. Orientation



B. Compartments of the thigh



C. Cross section



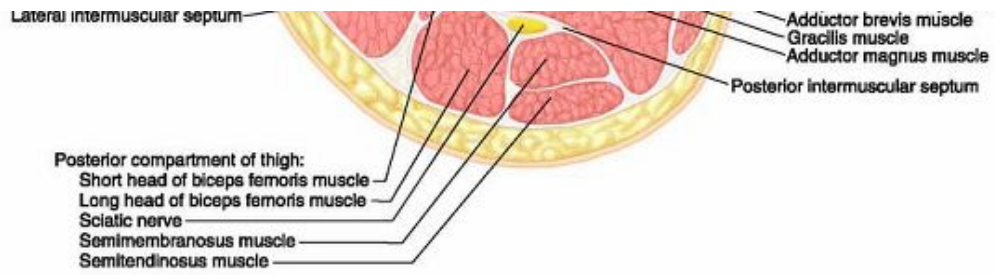
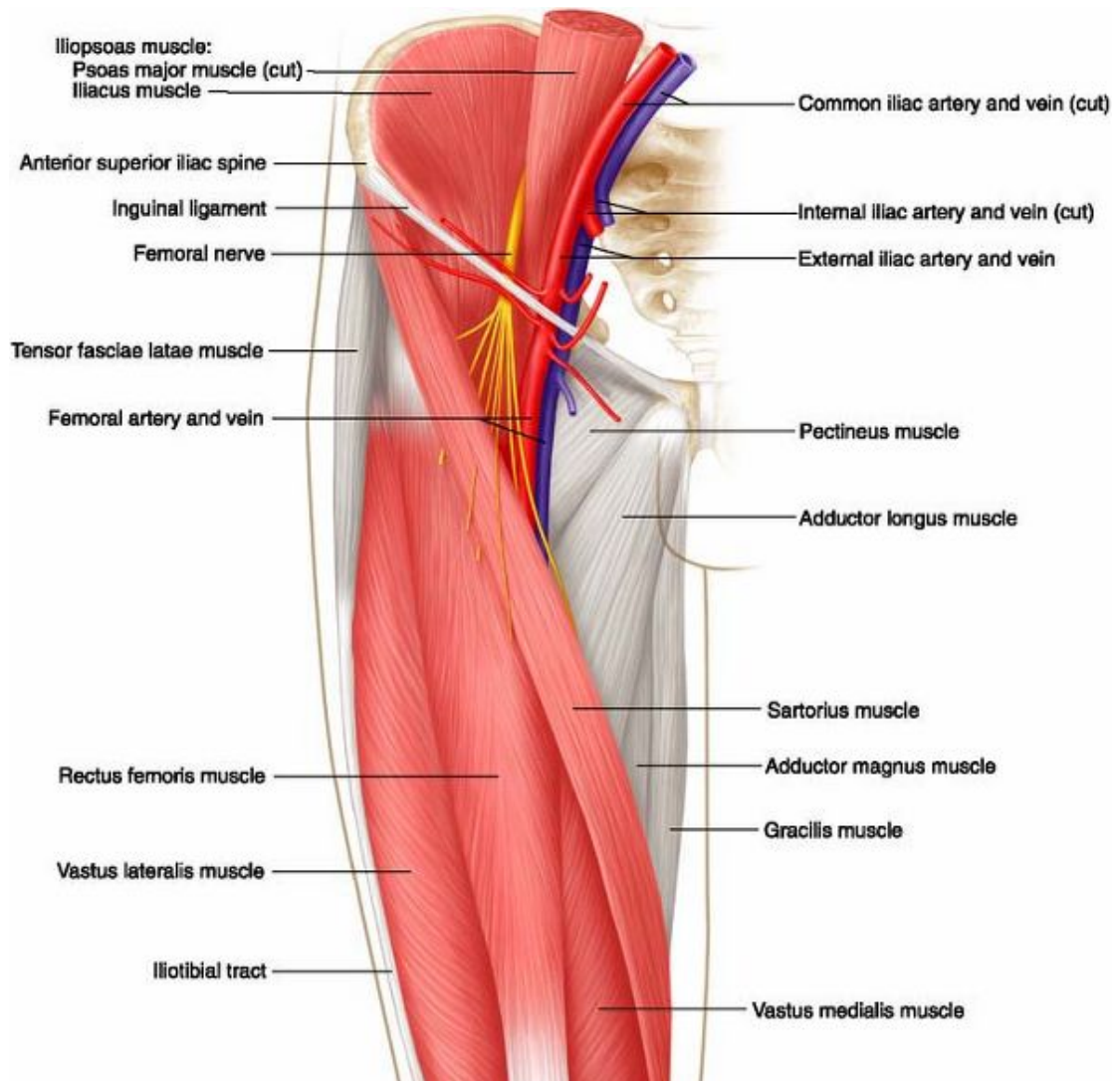


Plate 3-15 Compartmental Organization of the Thigh



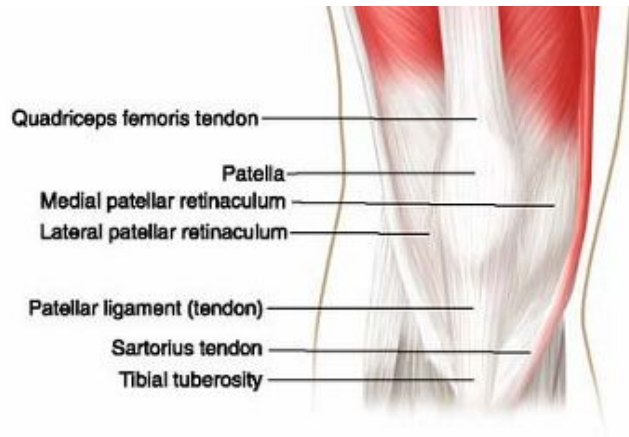
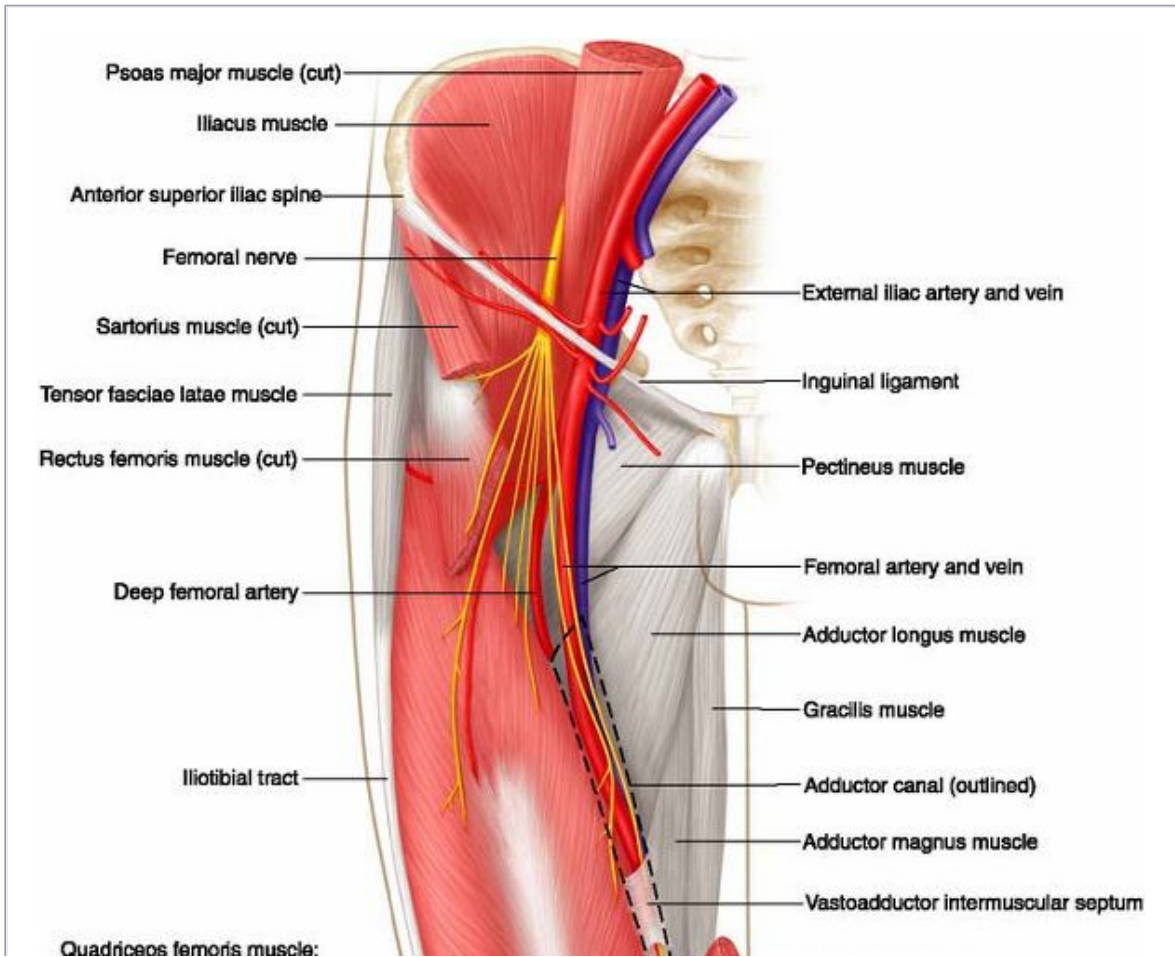


Plate 3-16 Muscles of the Anterior Thigh, Superficial Dissection



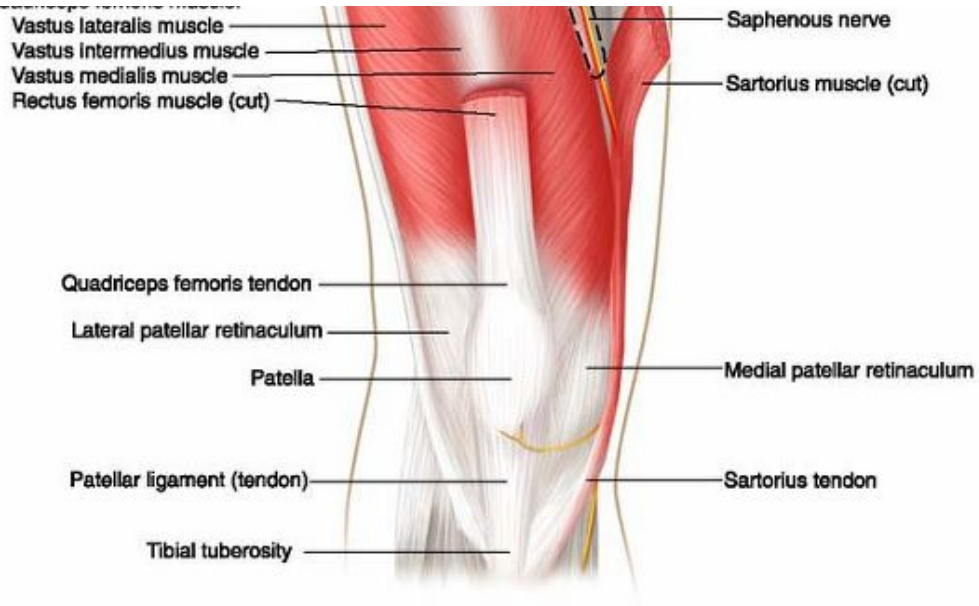

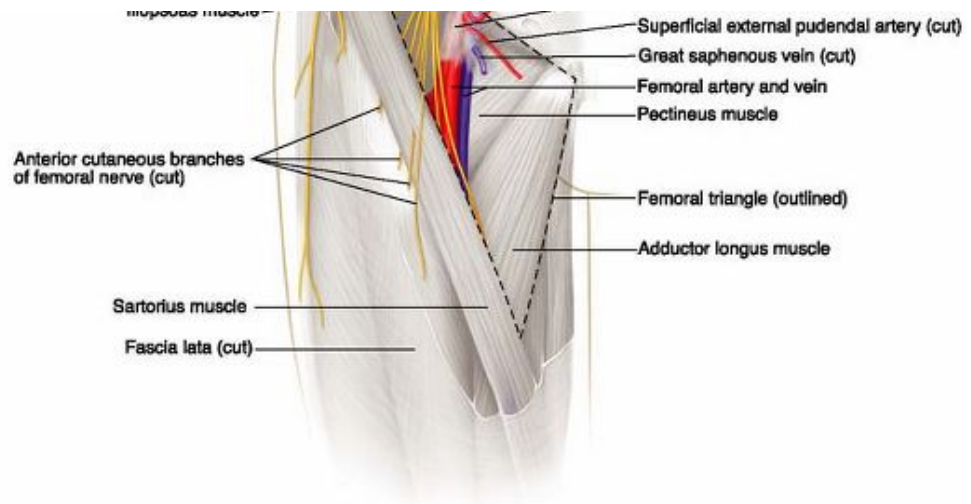


Plate 3-17 Muscles of the Anterior Thigh, Deep Dissection

A. Anterior view





B. Section through the femoral sheath

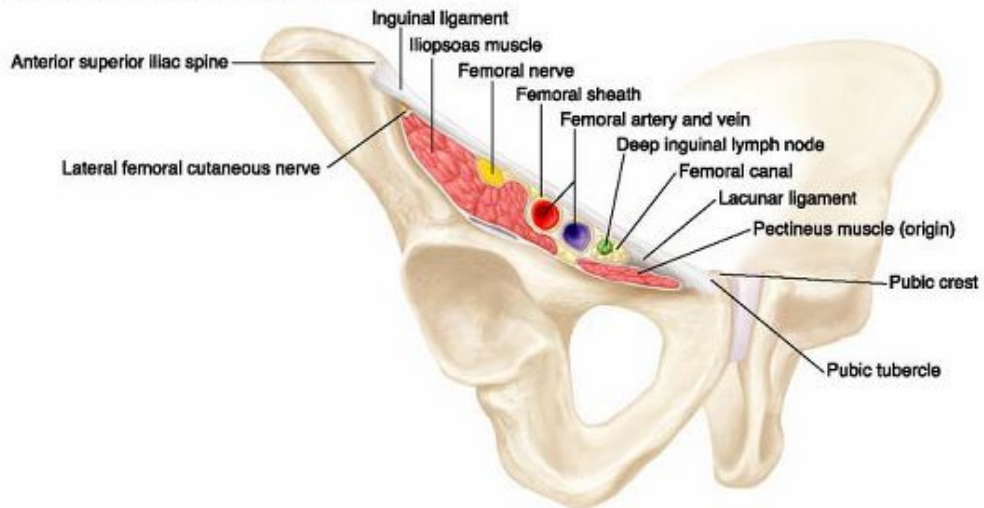


Plate 3-18 Femoral Triangle

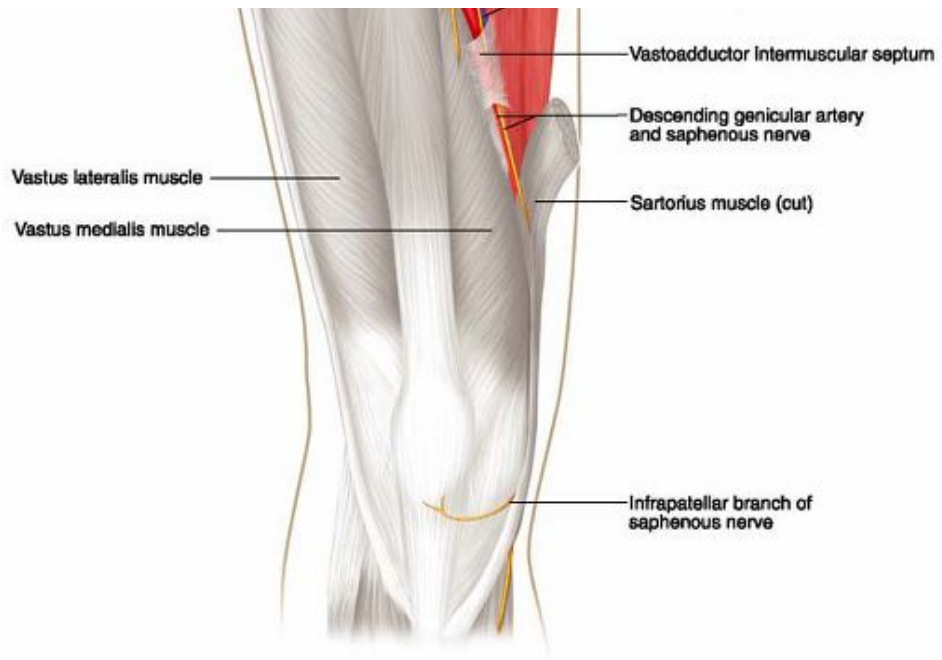


Plate 3-19 Muscles of the Medial Thigh, Superficial Dissection

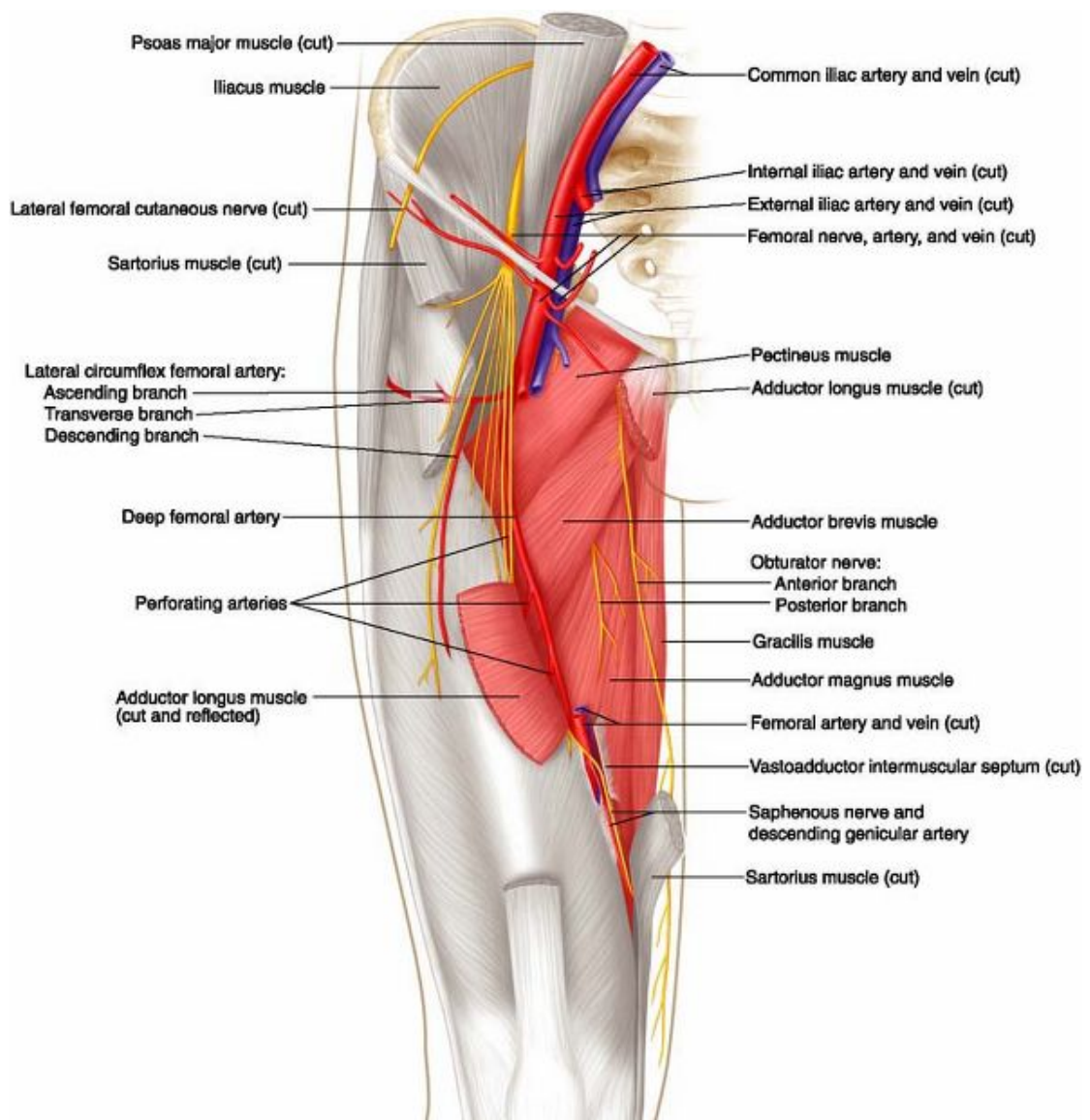

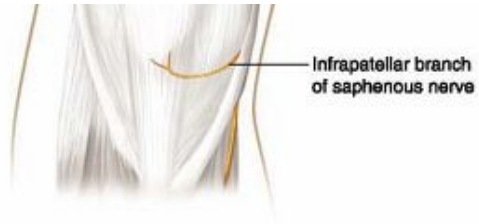


Plate 3-20 Muscles of the Medial Thigh, Intermediate Dissection

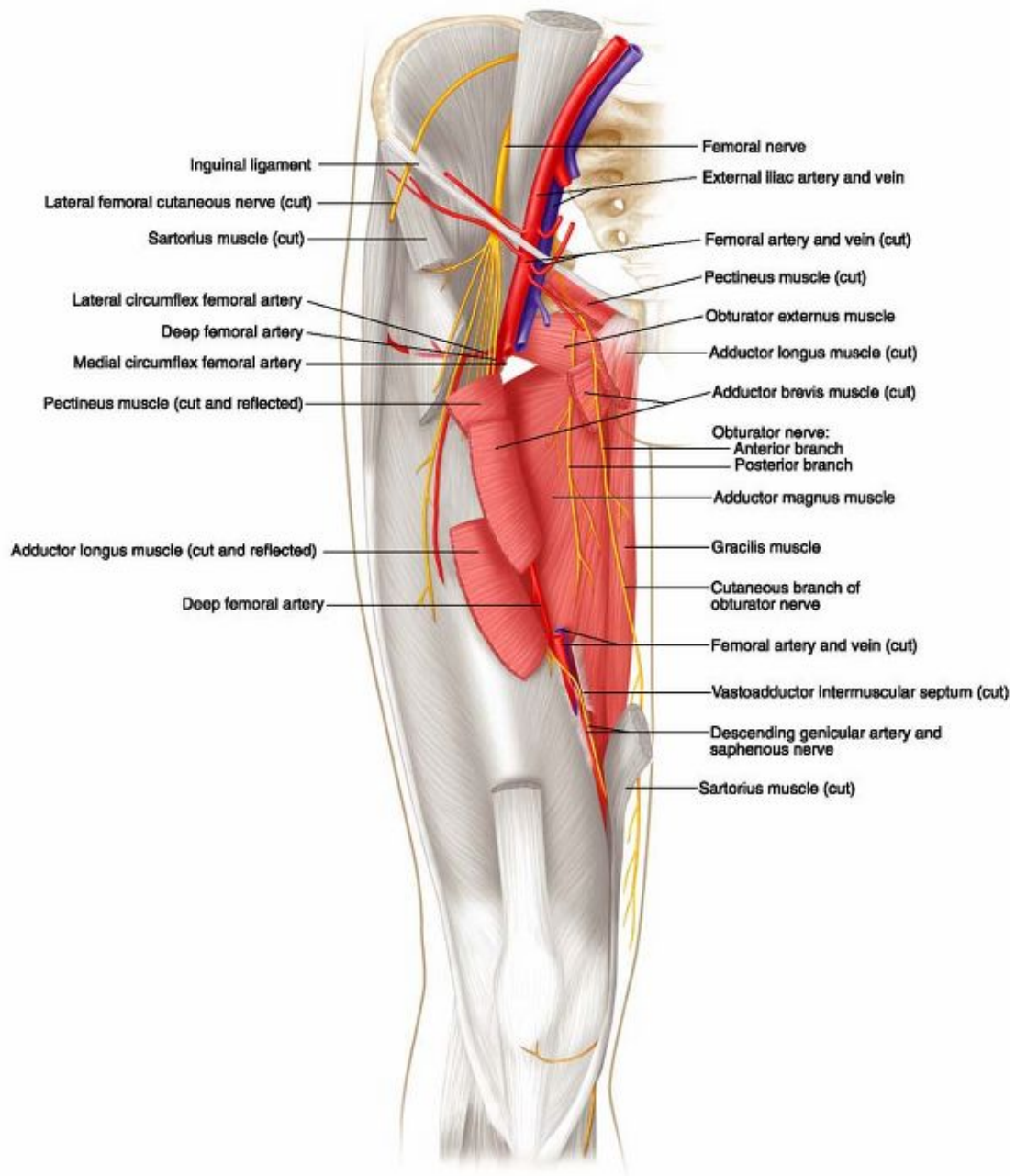


Plate 3-21 Muscles of the Medial Thigh, Deep Dissection

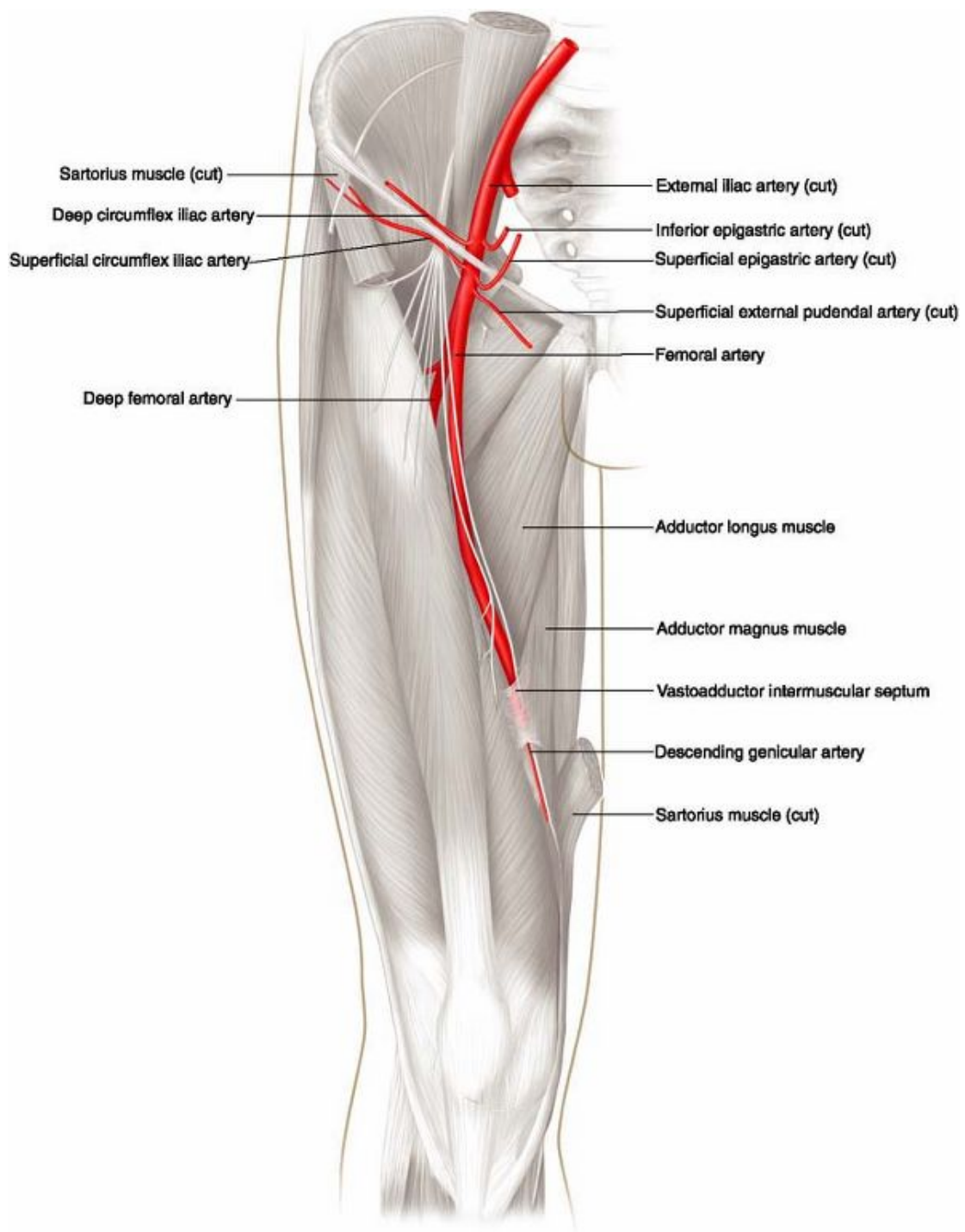


Plate 3-22 Arteries of the Anterior and Medial Thigh, Superficial Dissection

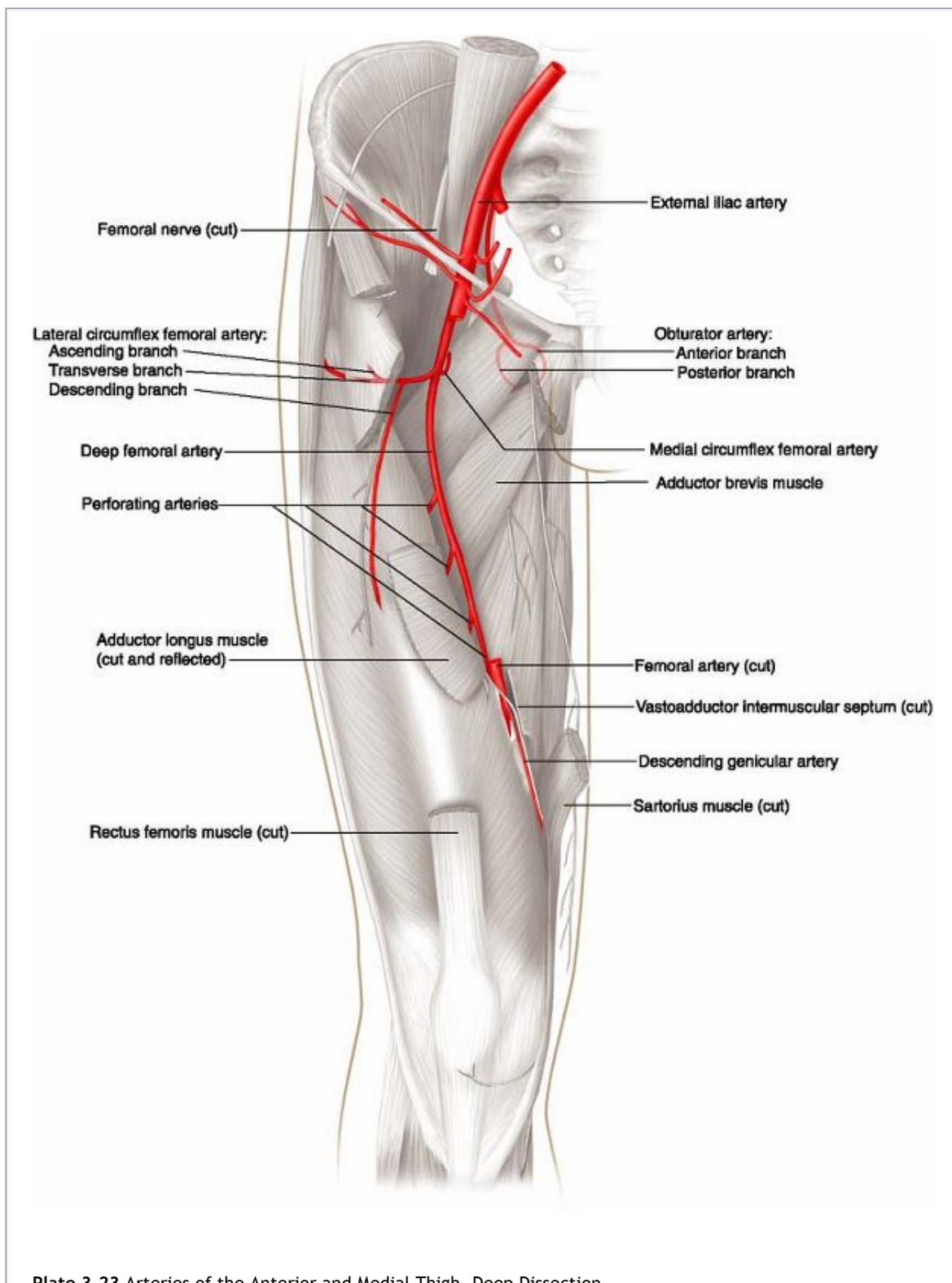
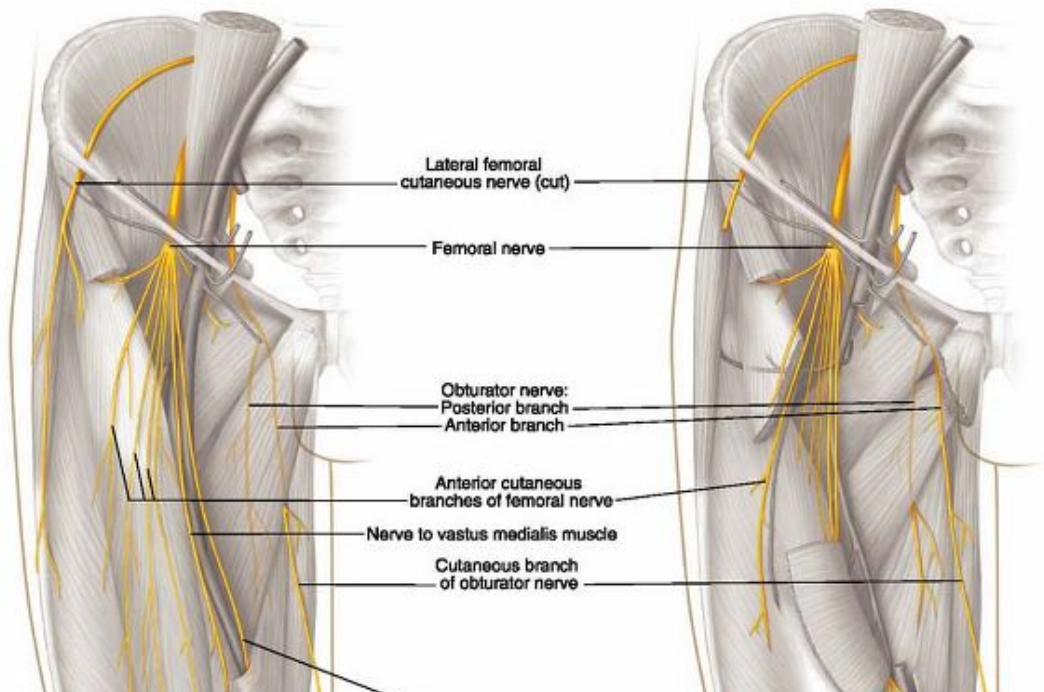


Plate 3-23 Arteries of the Anterior and Medial Thigh. Deep Dissection

A. Superficial dissection

B. Deep dissection



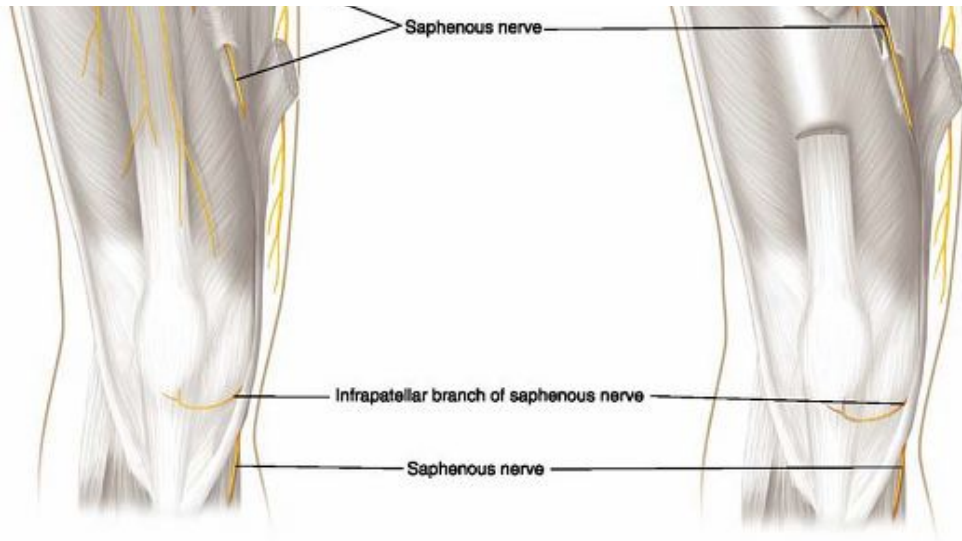
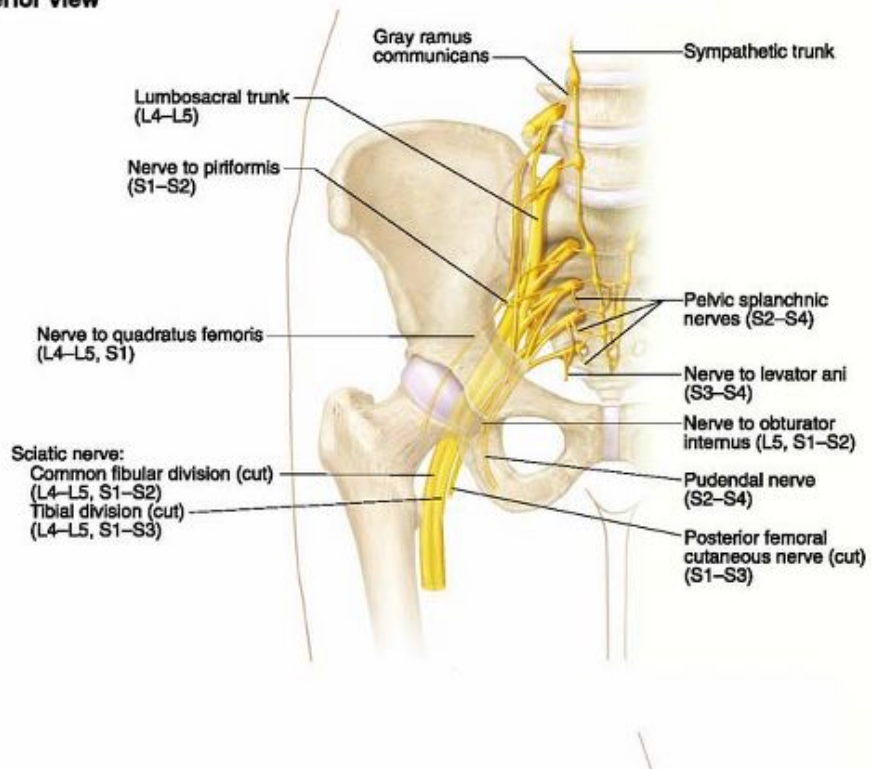


Plate 3-24 Nerves of the Anterior and Medial Thigh

A. Anterior view



B. Posterior view

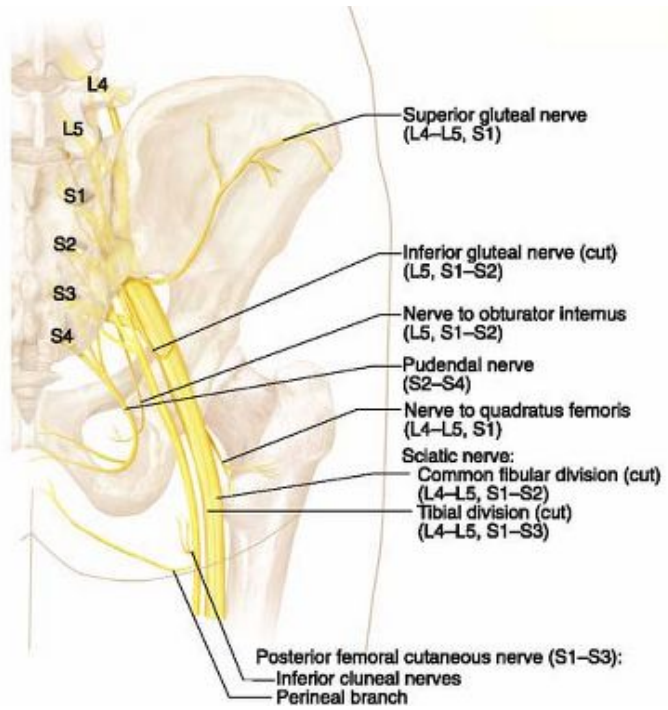
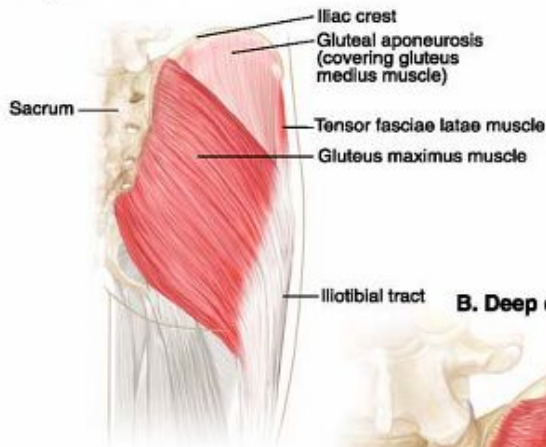


Plate 3-25 Sacral Plexus

A. Superficial dissection



B. Deep dissection

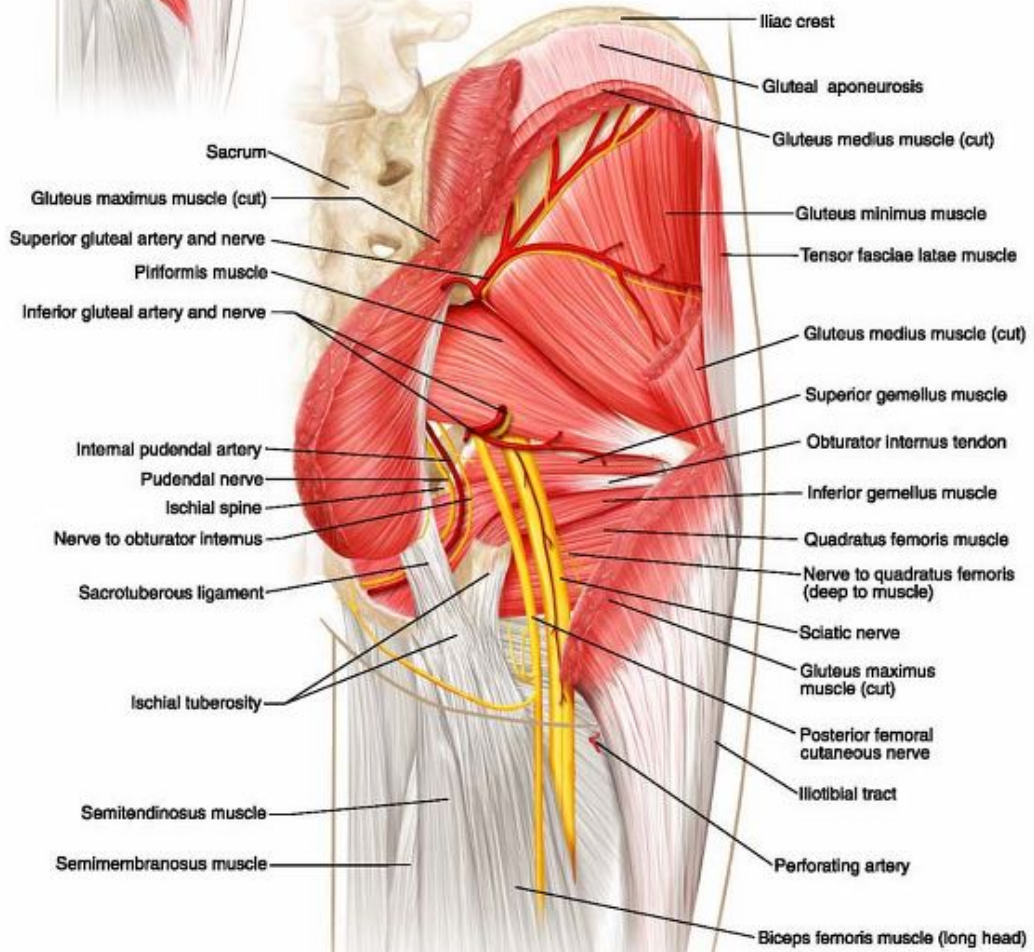
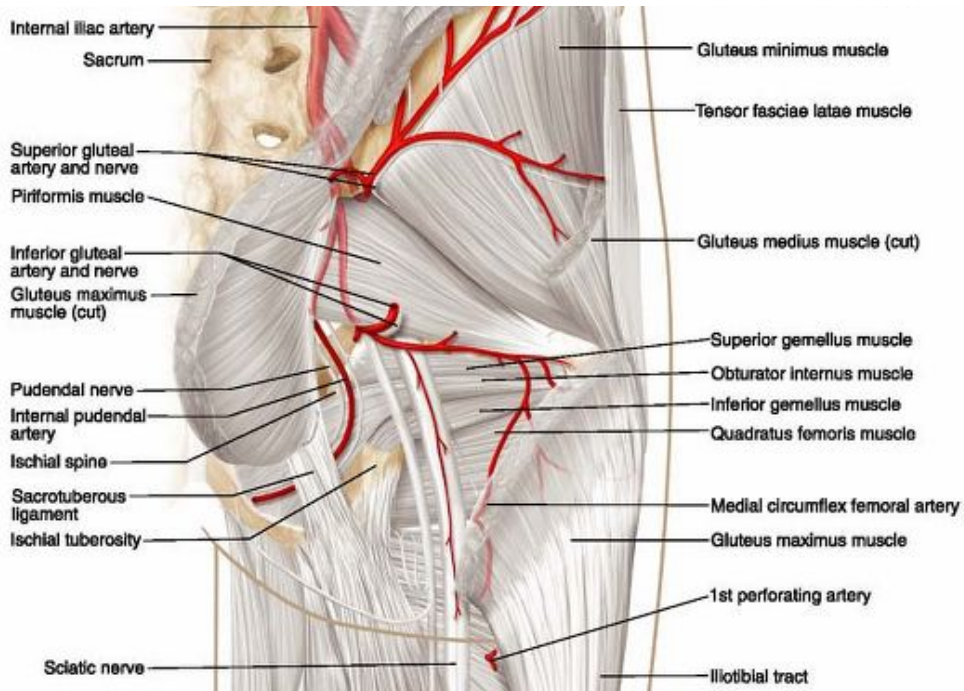


Plate 3-26 Muscles of the Gluteal Region

A. Arteries





B. Cruciate anastomosis

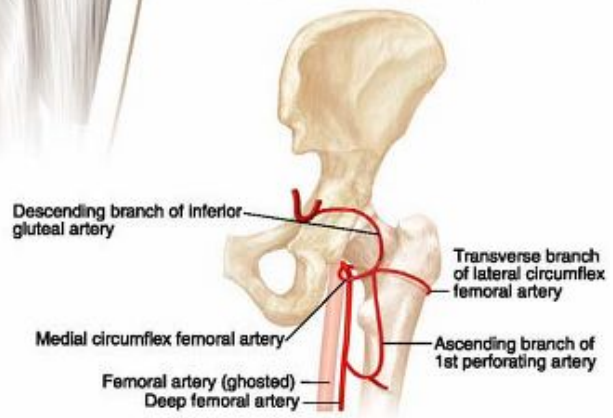


Plate 3-27 Arteries of the Gluteal Region



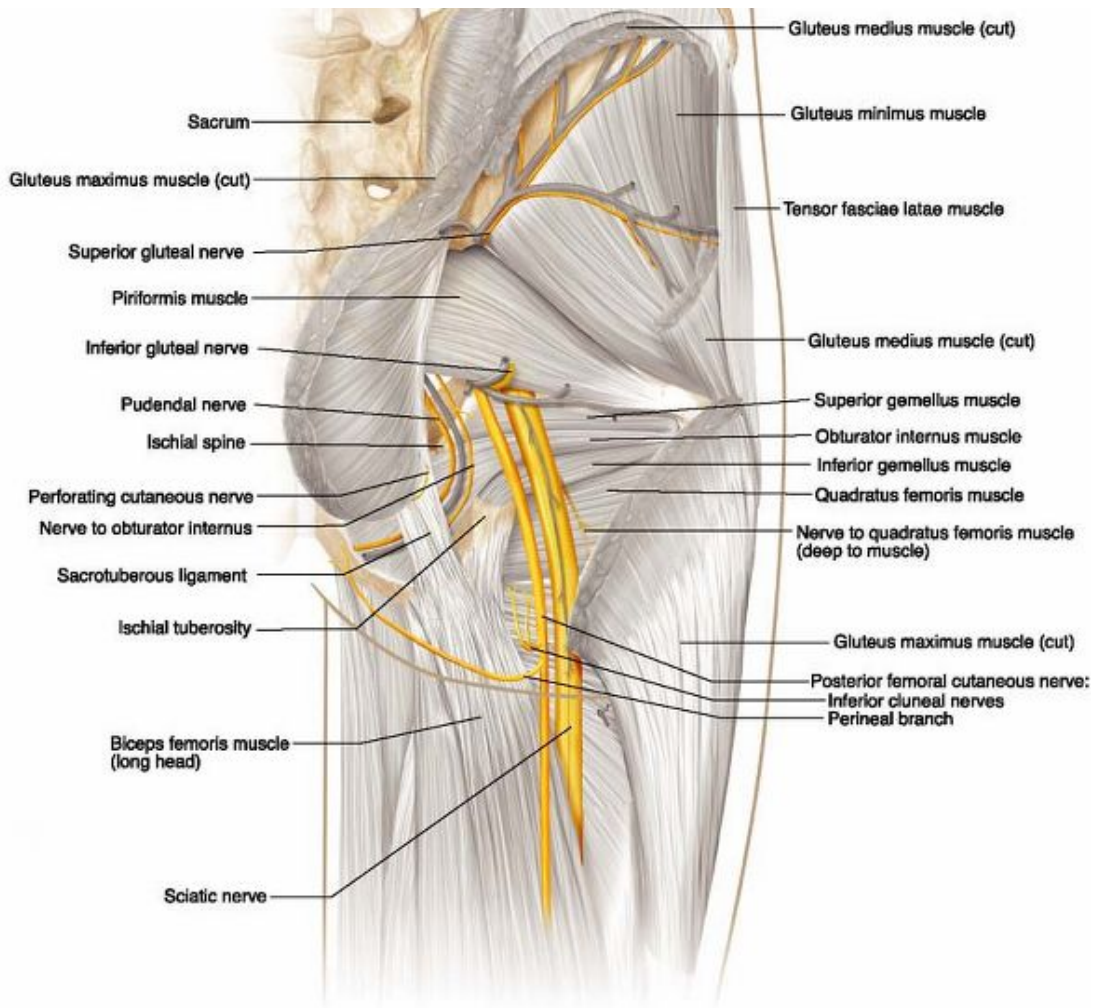
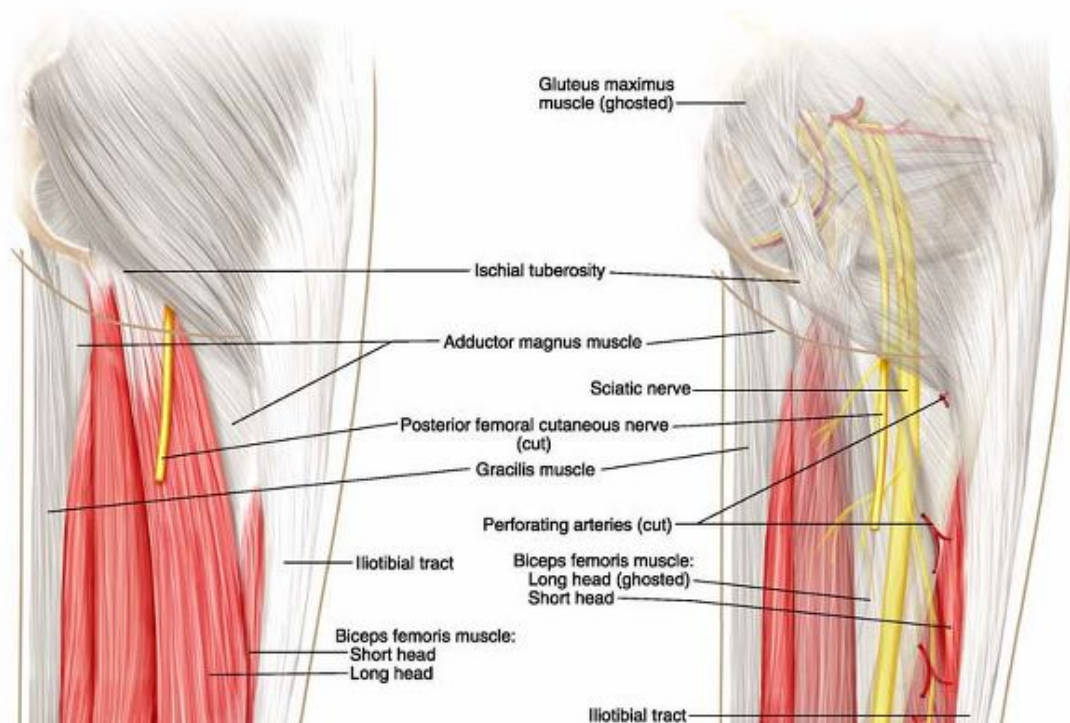


Plate 3-28 Nerves of the Gluteal Region

A. Superficial dissection

B. Deep dissection



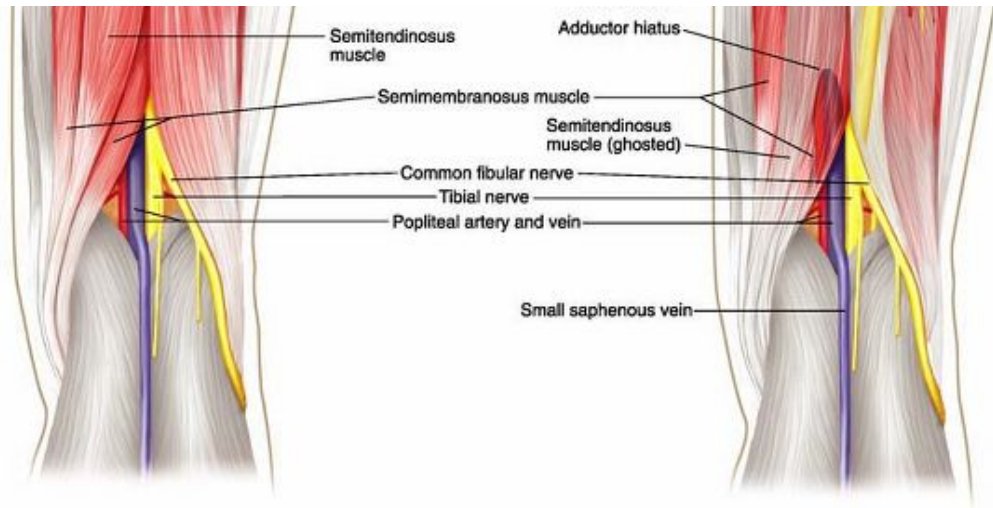
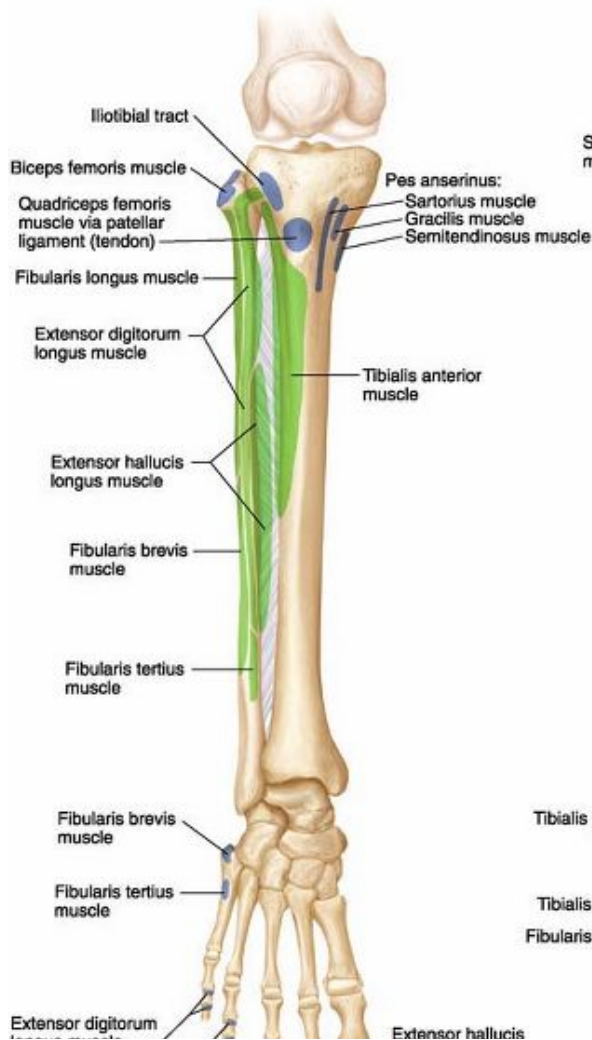


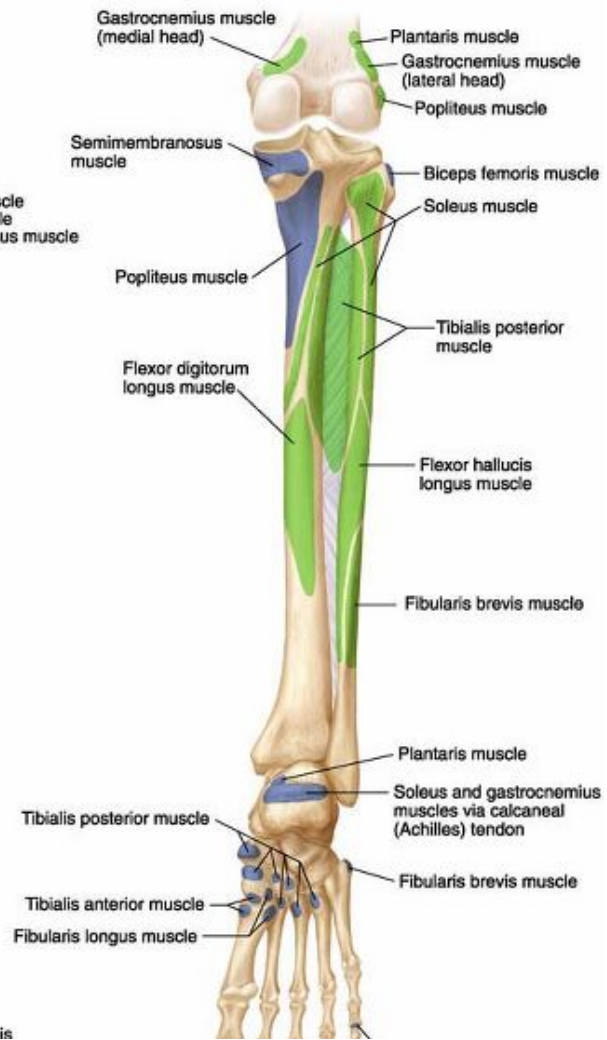
Plate 3-29 Muscles of the Posterior Thigh

Muscle attachments
 Origins
 Insertions

A. Anterior view



B. Posterior view

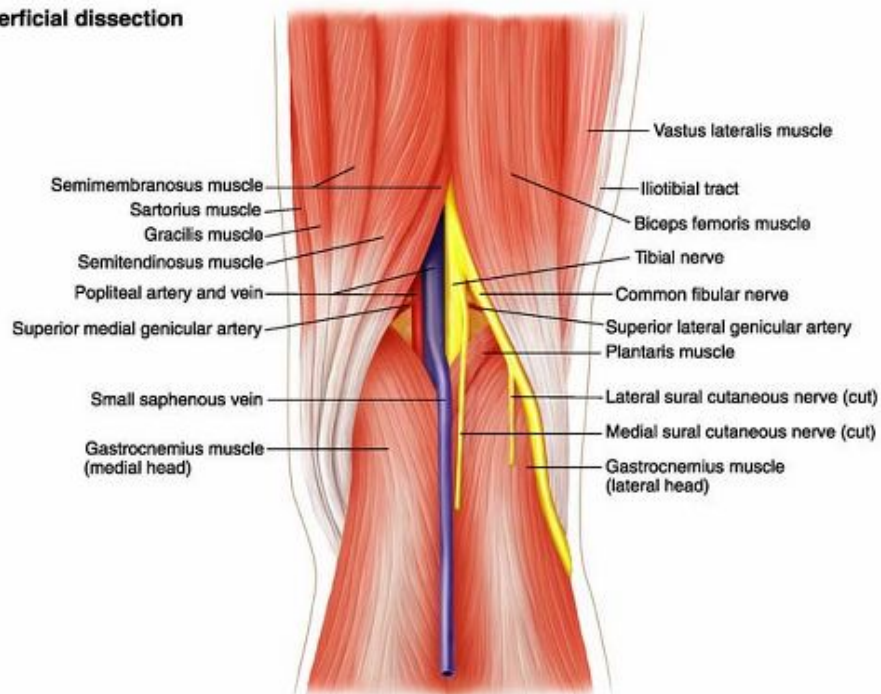




Note: Attachments of intrinsic muscles of foot not shown

Plate 3-30 Muscle Attachments of the Distal Lower Limb

A. Superficial dissection



B. Deep dissection

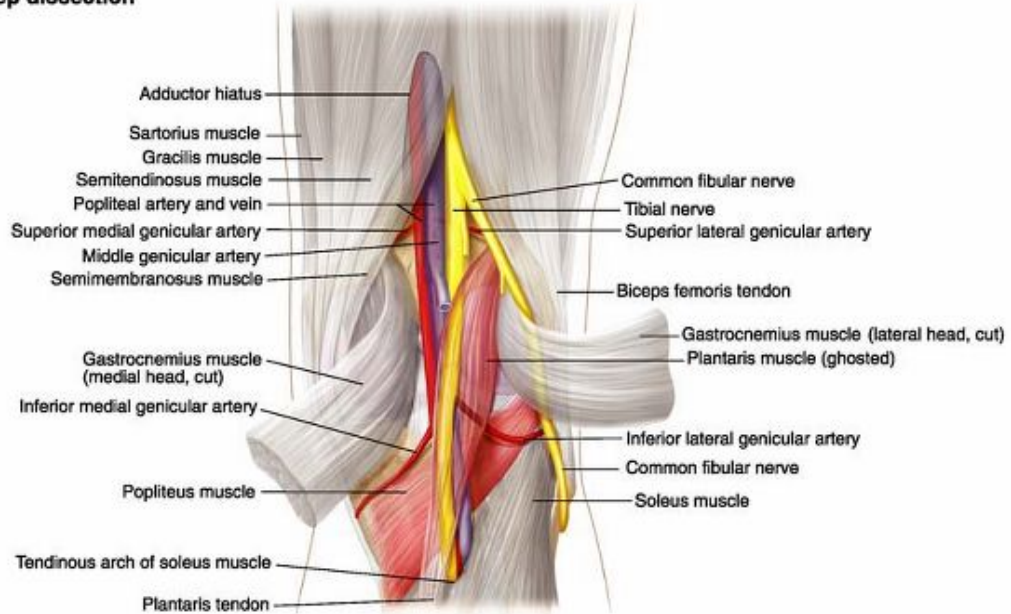
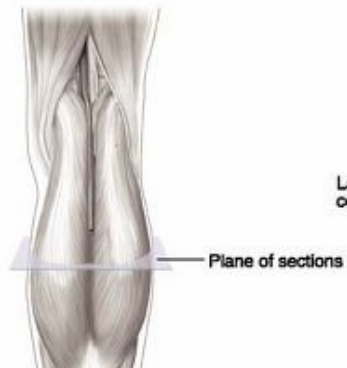
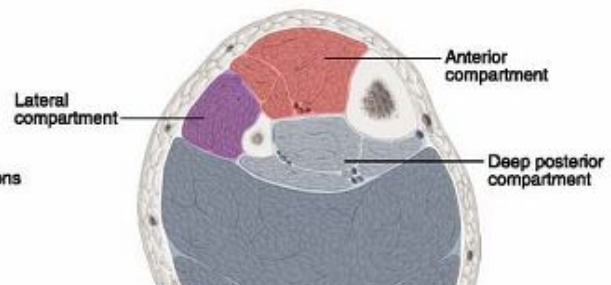


Plate 3-31 Popliteal Fossa

A. Orientation



B. Compartments of the leg





C. Cross section

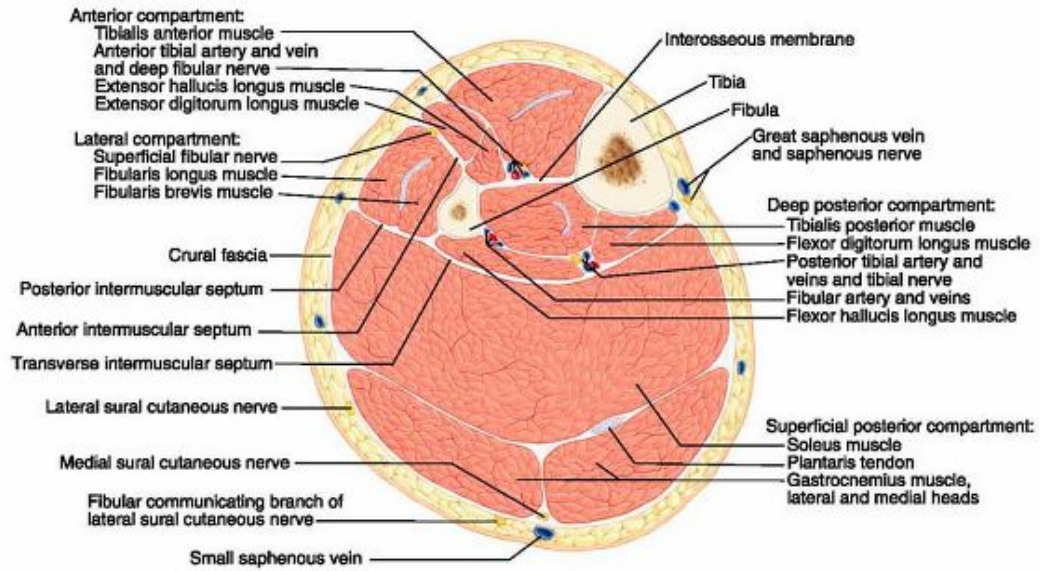
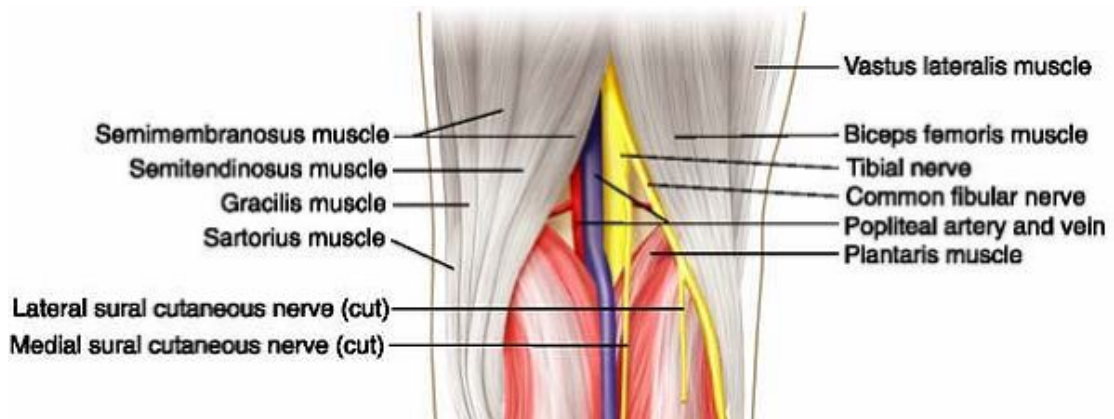


Plate 3-32 Compartmental Organization of the Leg



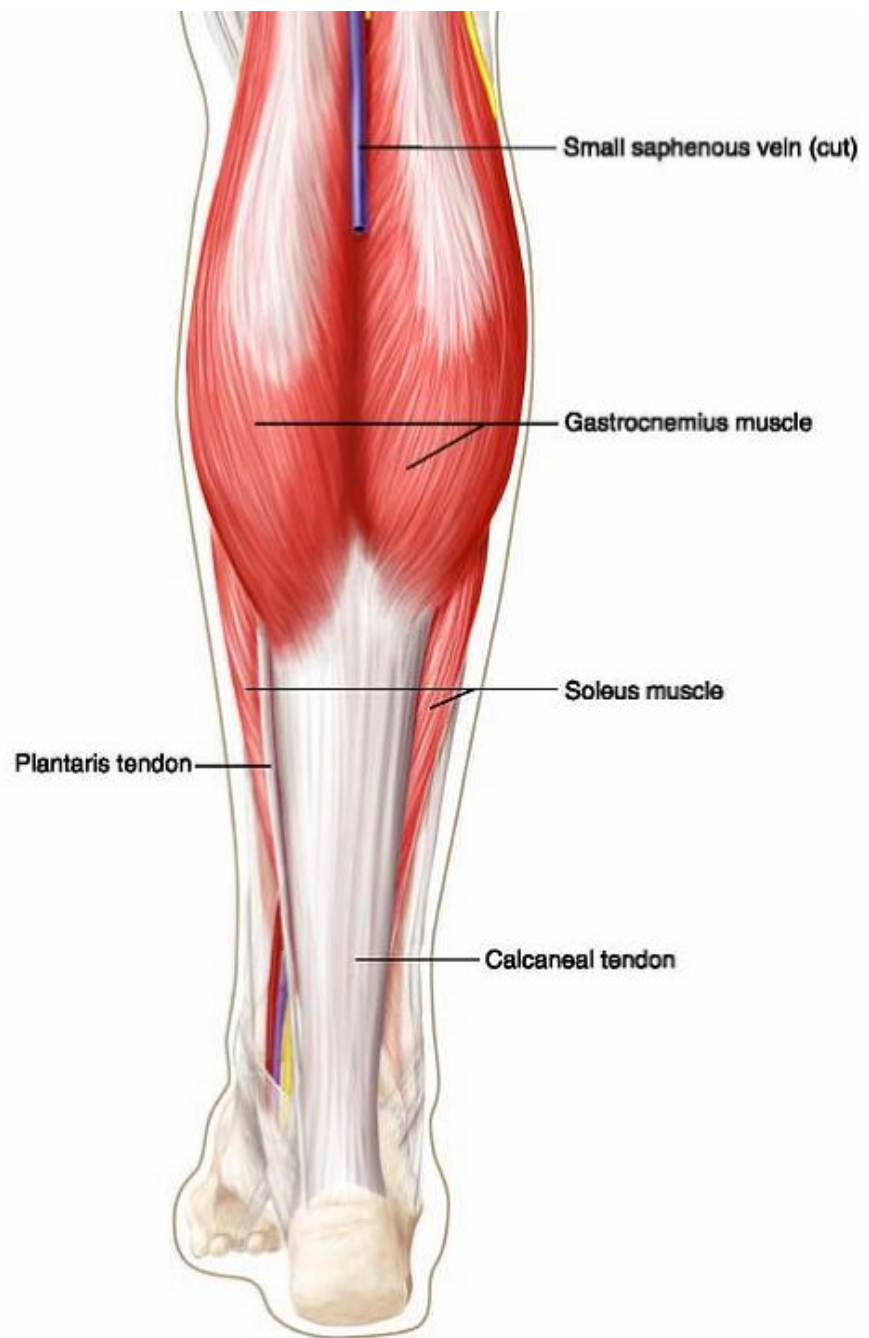


Plate 3-33 Muscles of the Posterior Leg, Superficial Dissection

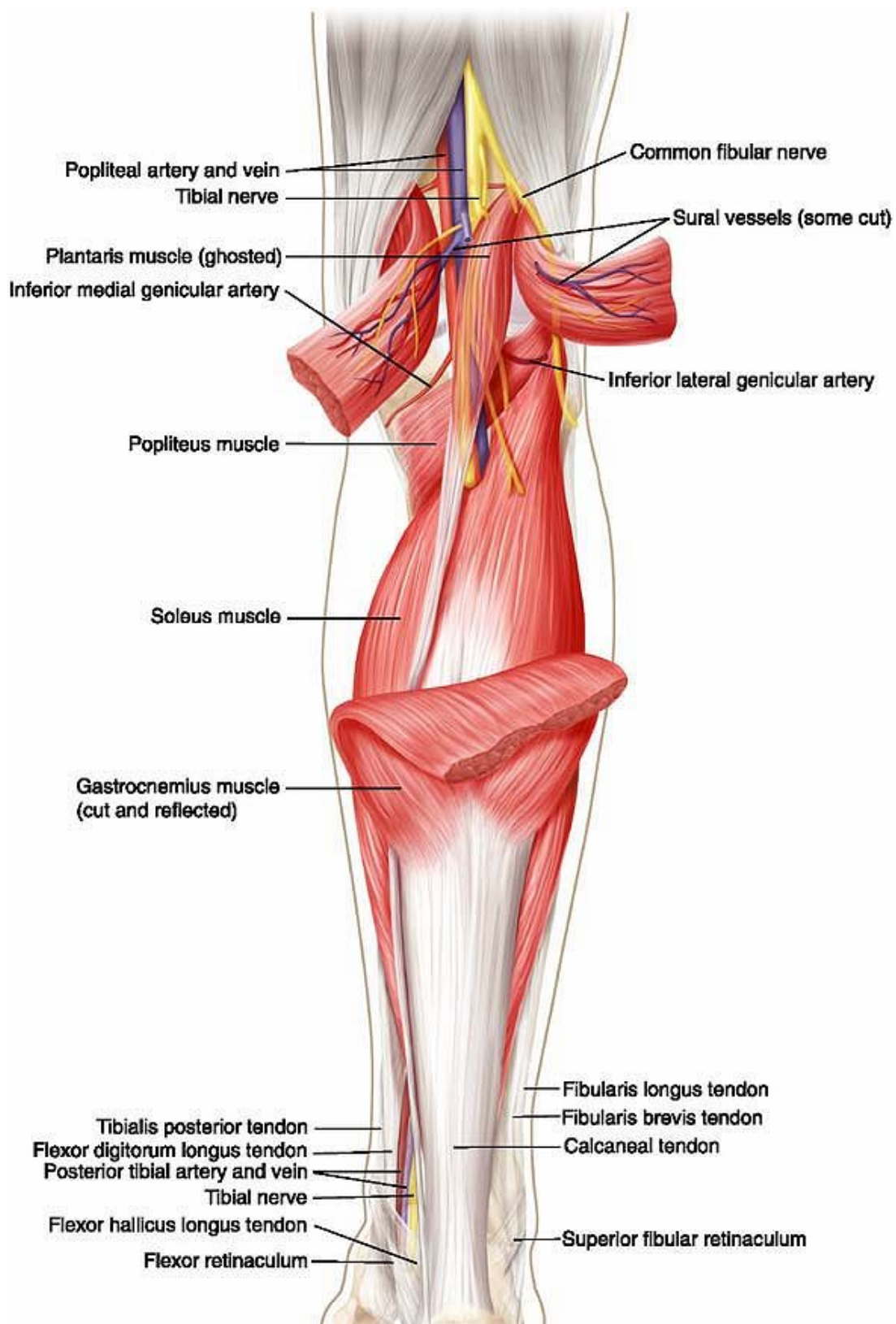




Plate 3-34 Muscles of the Posterior Leg, Intermediate Dissection

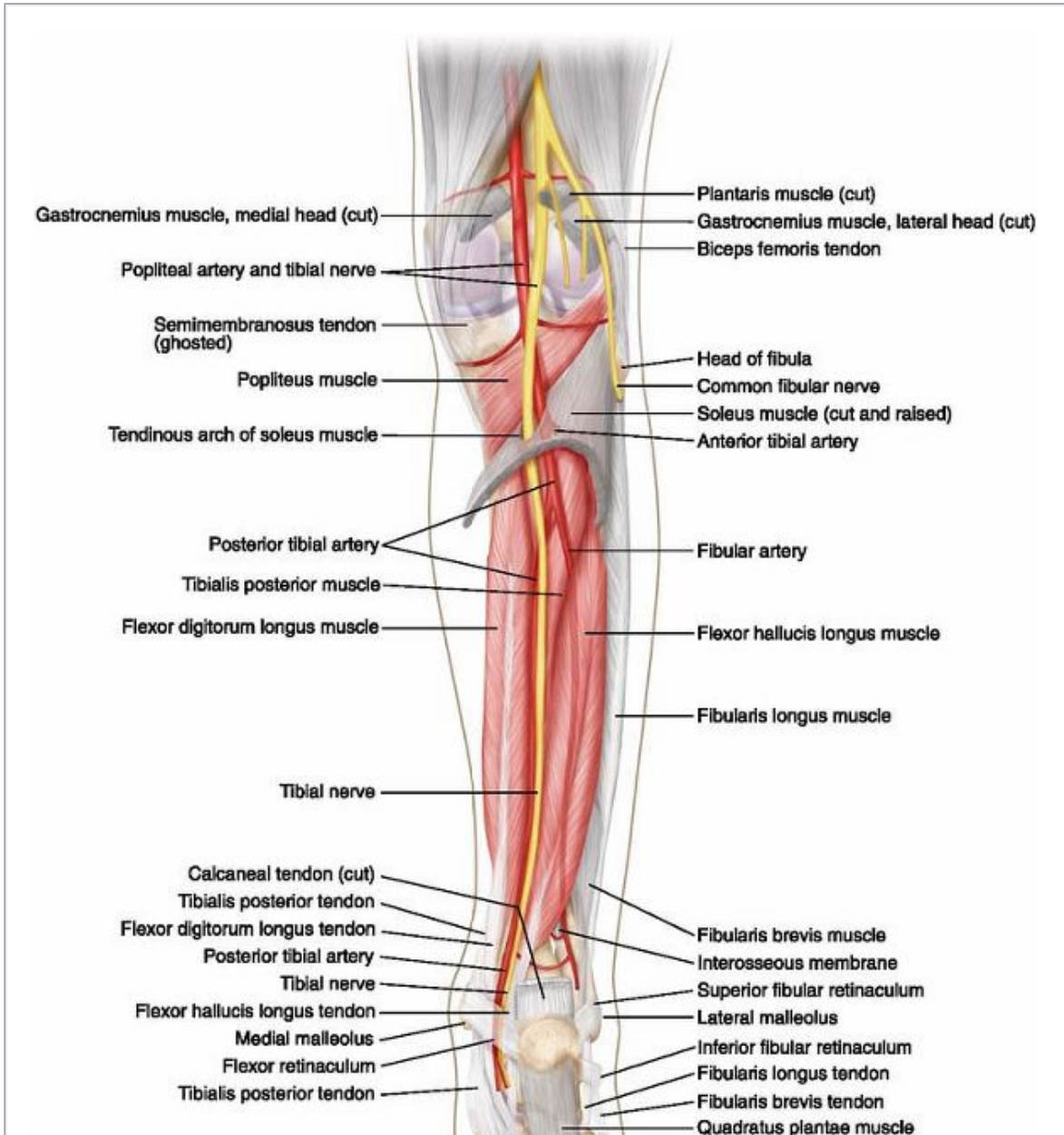

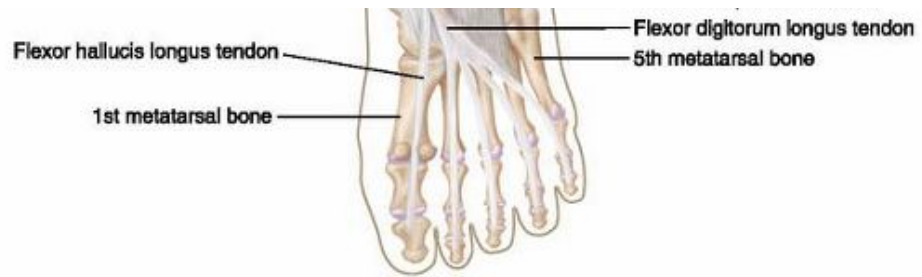


Plate 3-35 Muscles of the Posterior Leg, Deep Dissection

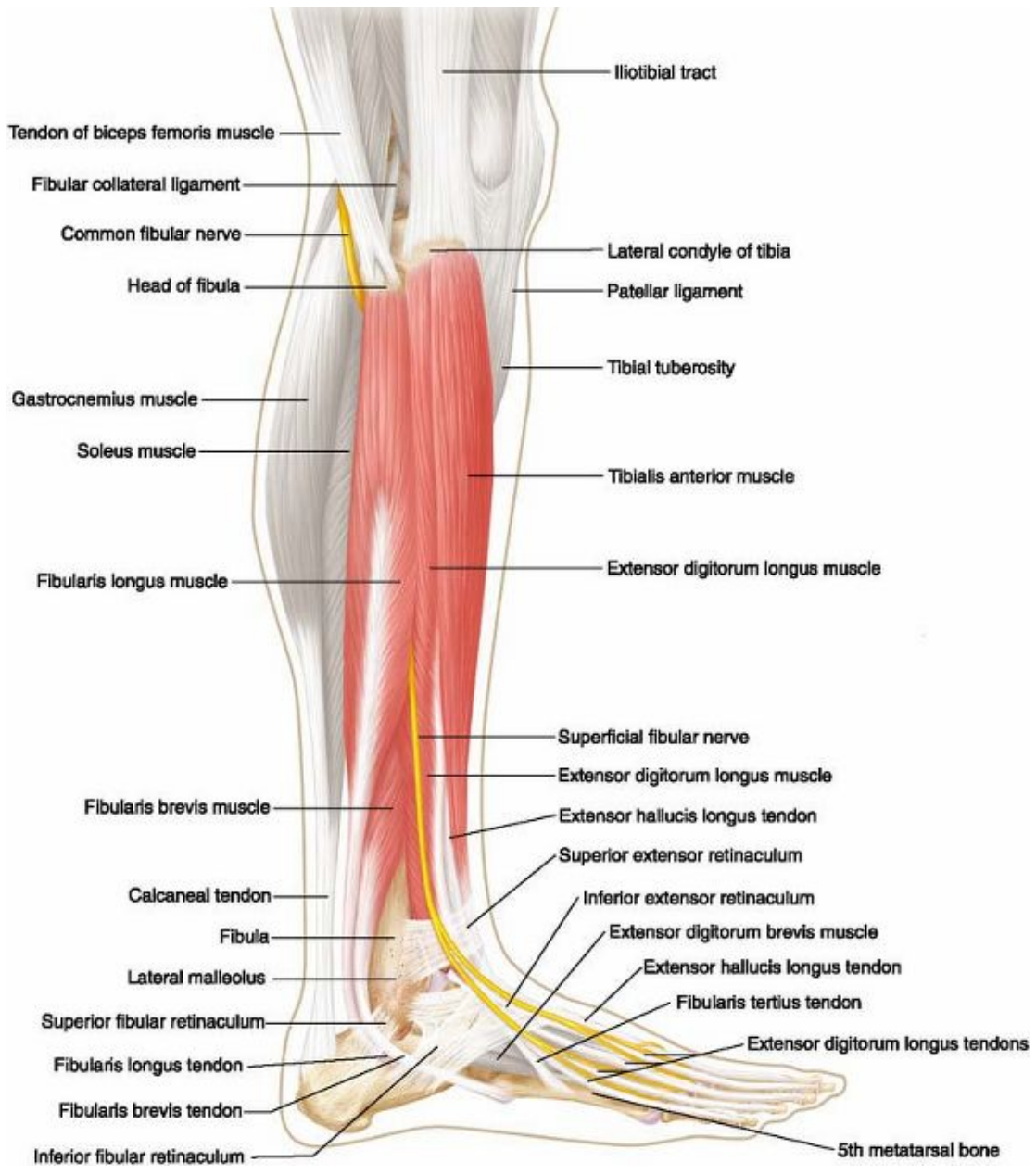
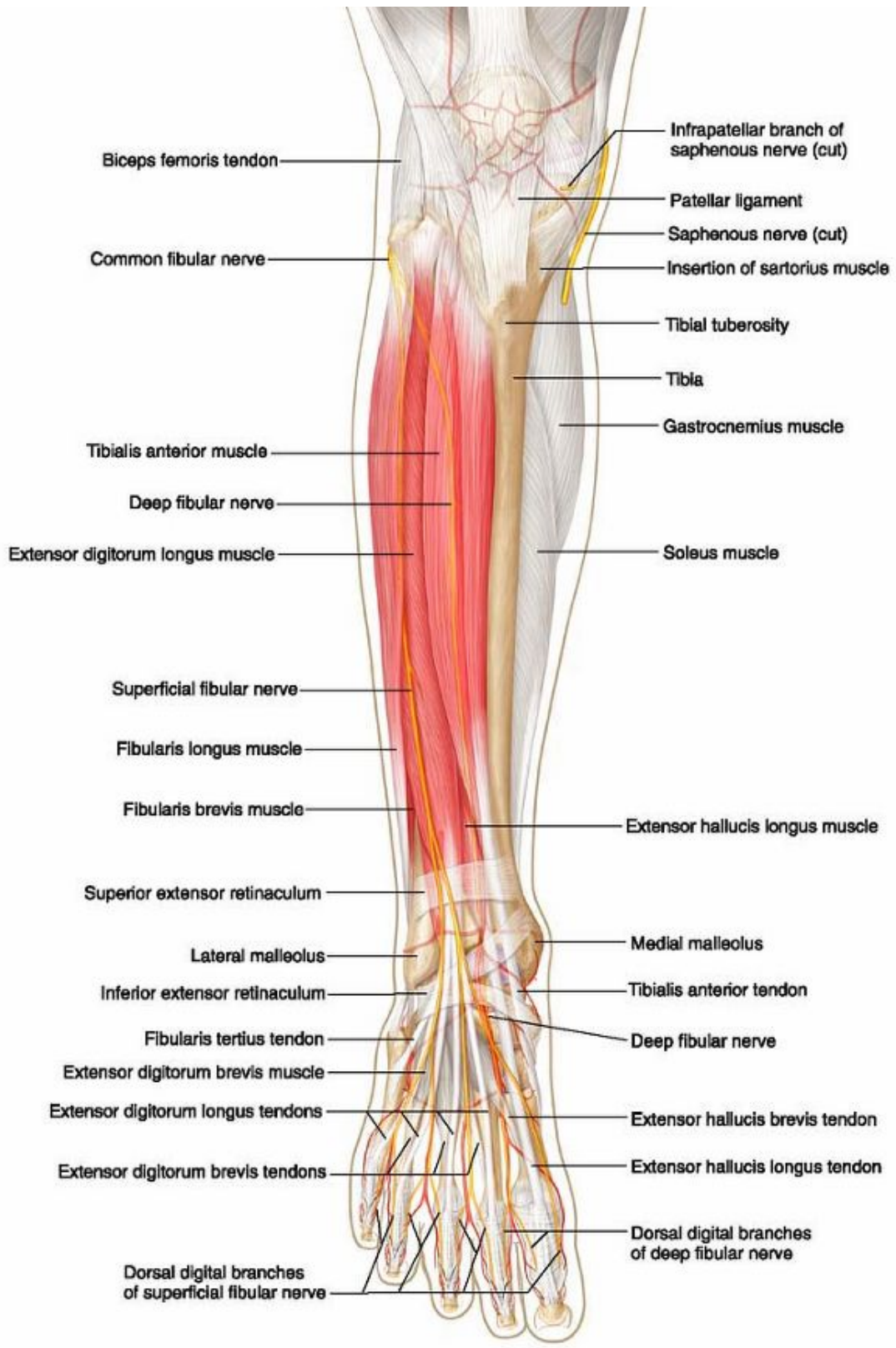


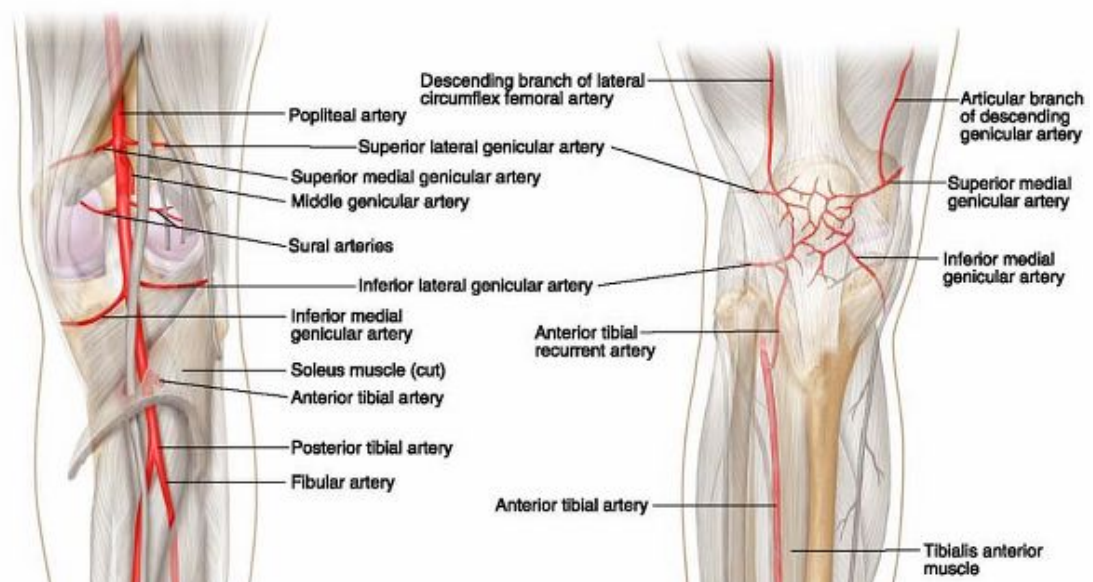
Plate 3-36 Muscles of the Lateral and Anterior Leg, Lateral View





A. Posterior view

B. Anterior view



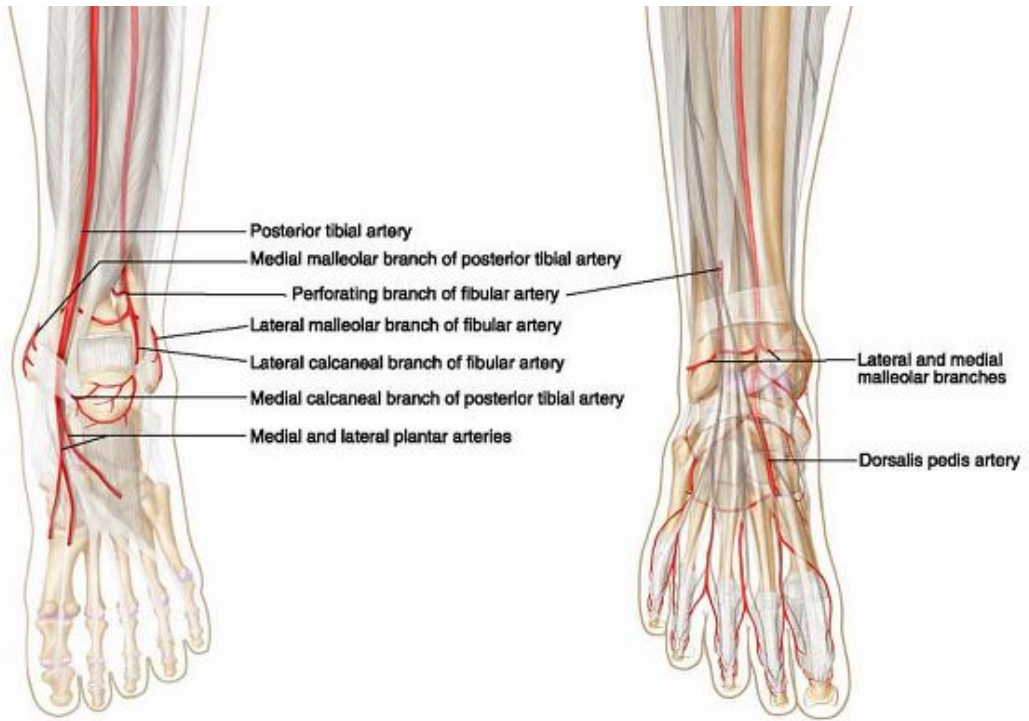
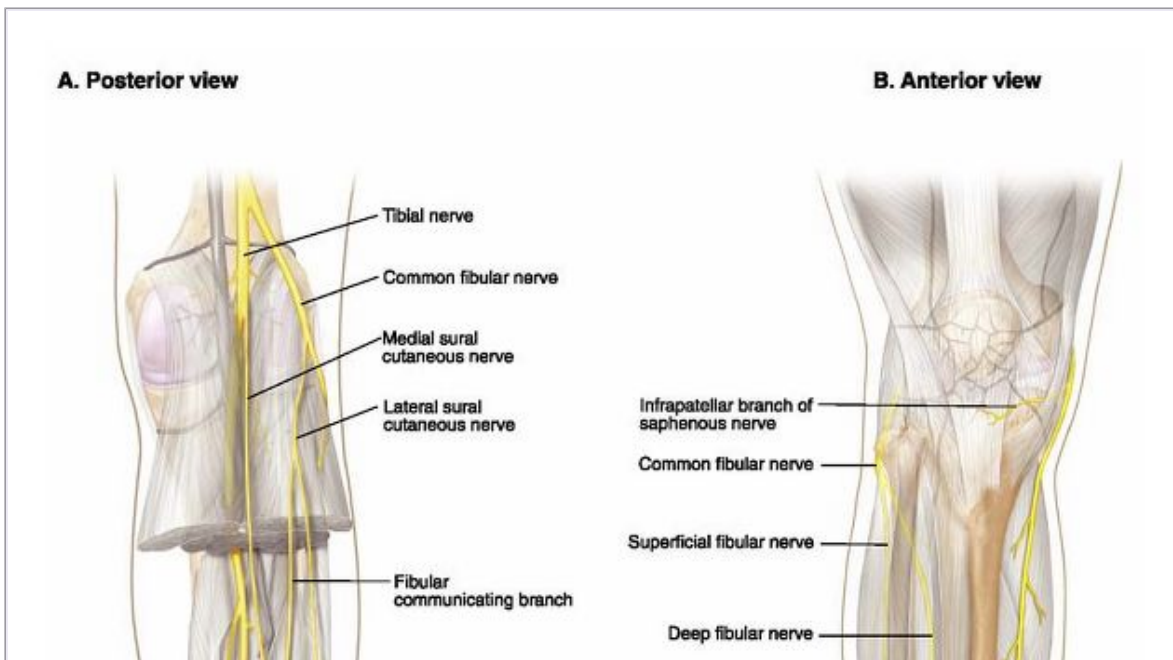


Plate 3-38 Arteries of the Leg



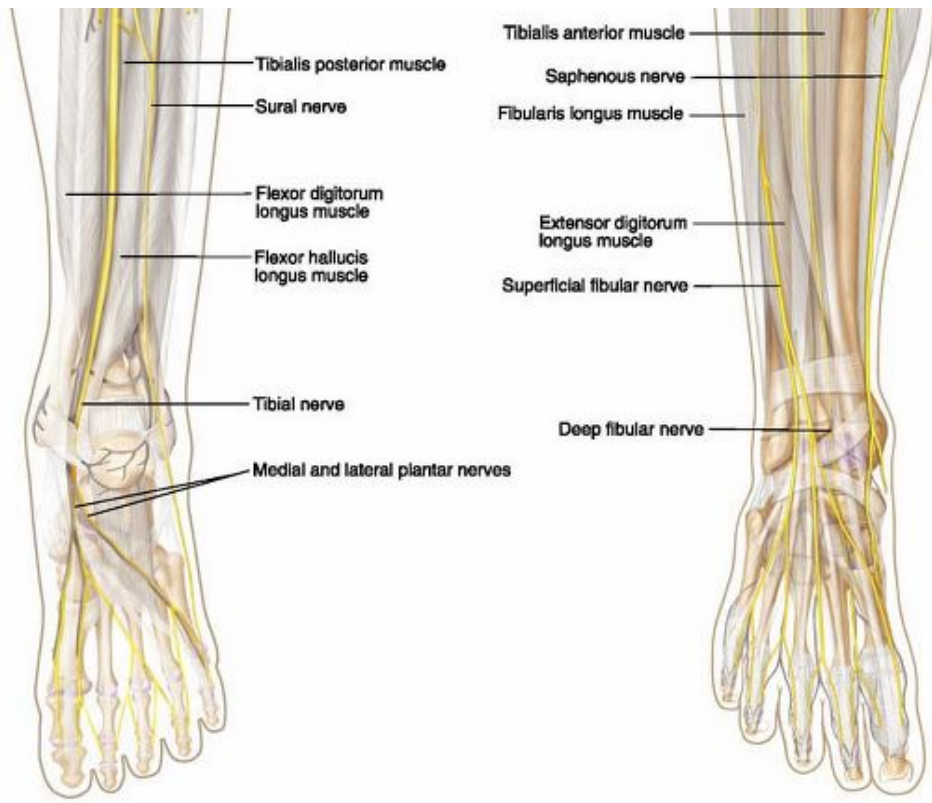
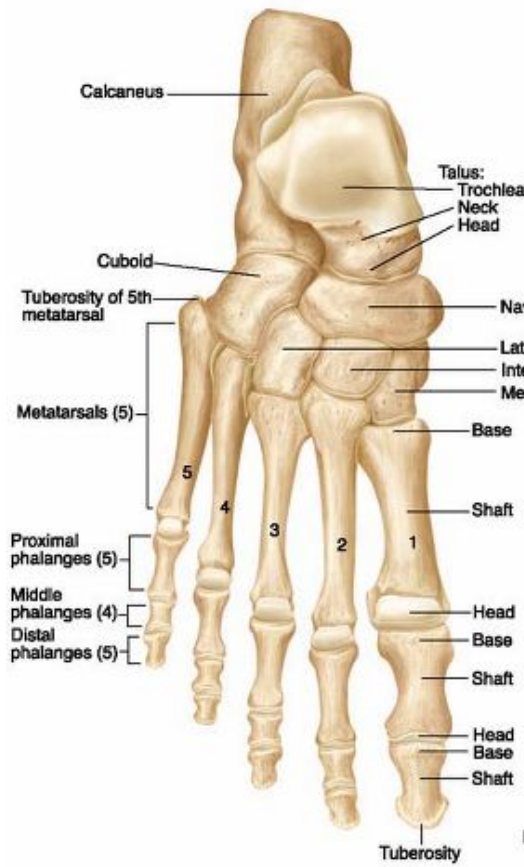


Plate 3-39 Nerves of the Leg

A. Dorsal view



B. Plantar view

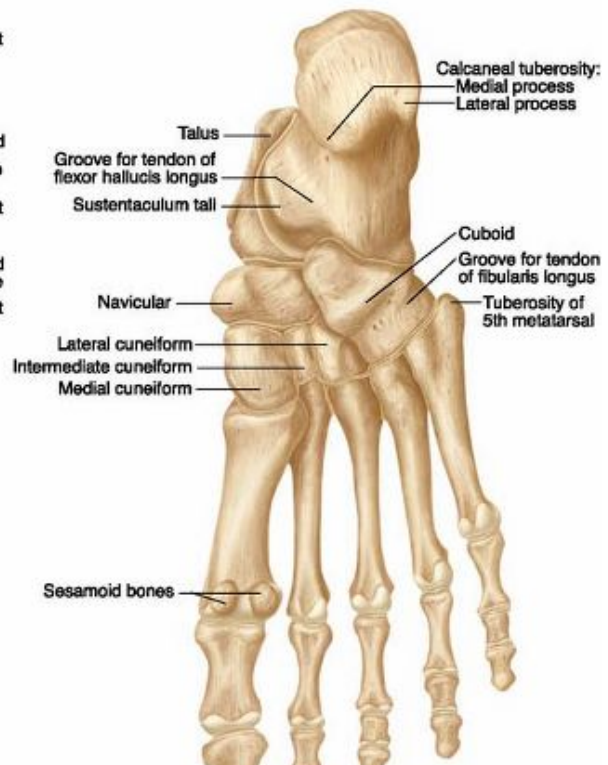
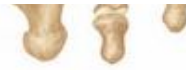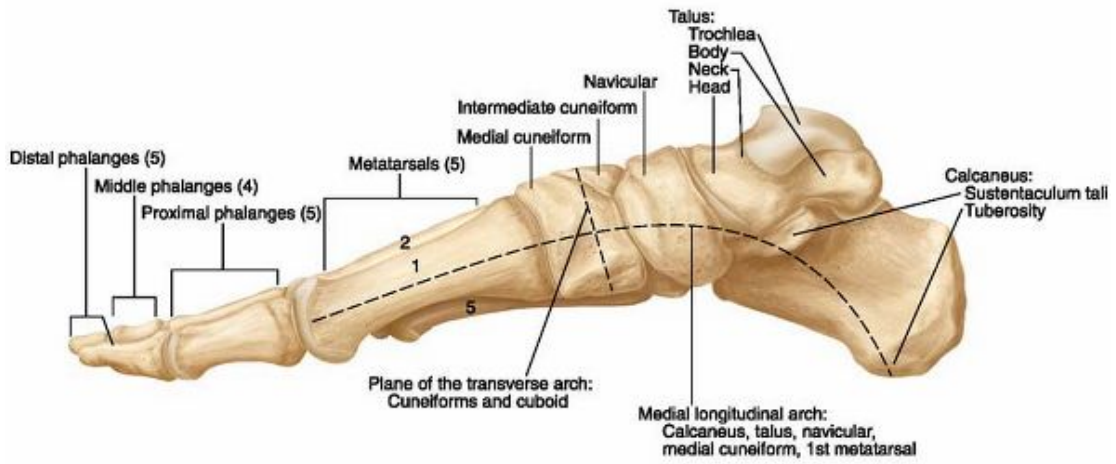




Plate 3-40 Skeleton of the Foot

A. Medial view



B. Lateral view

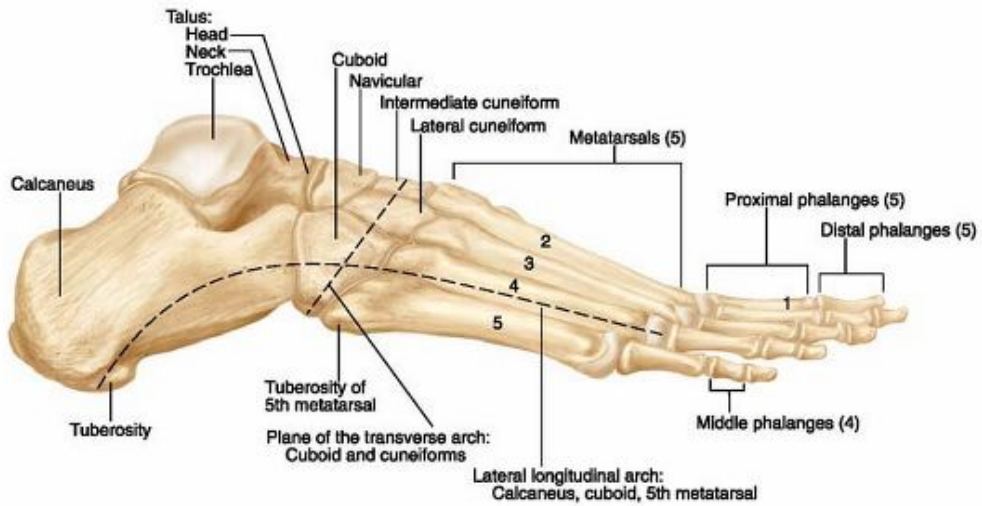
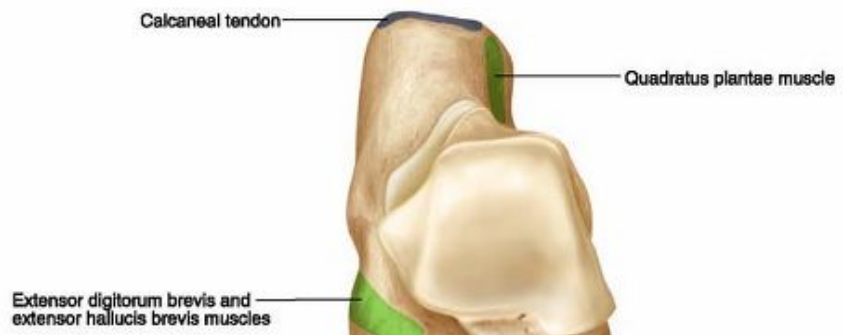


Plate 3-41 Arches of the Foot

Muscle attachments
Origins
Insertions



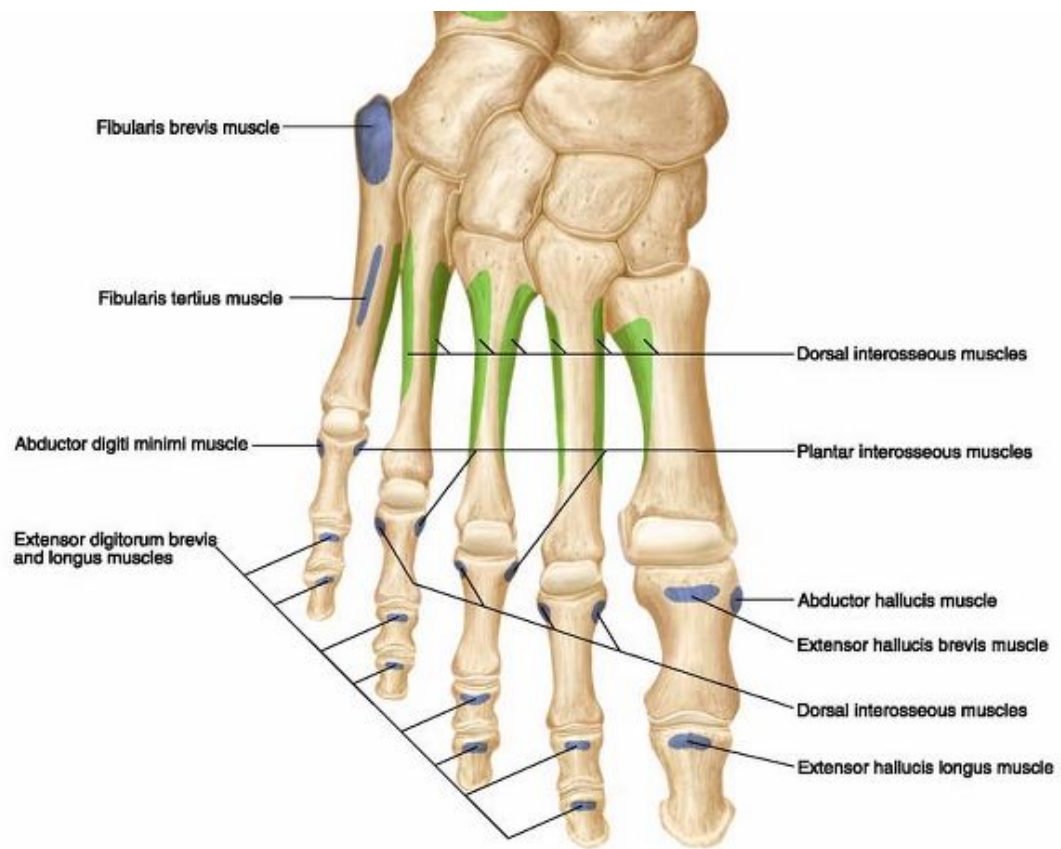
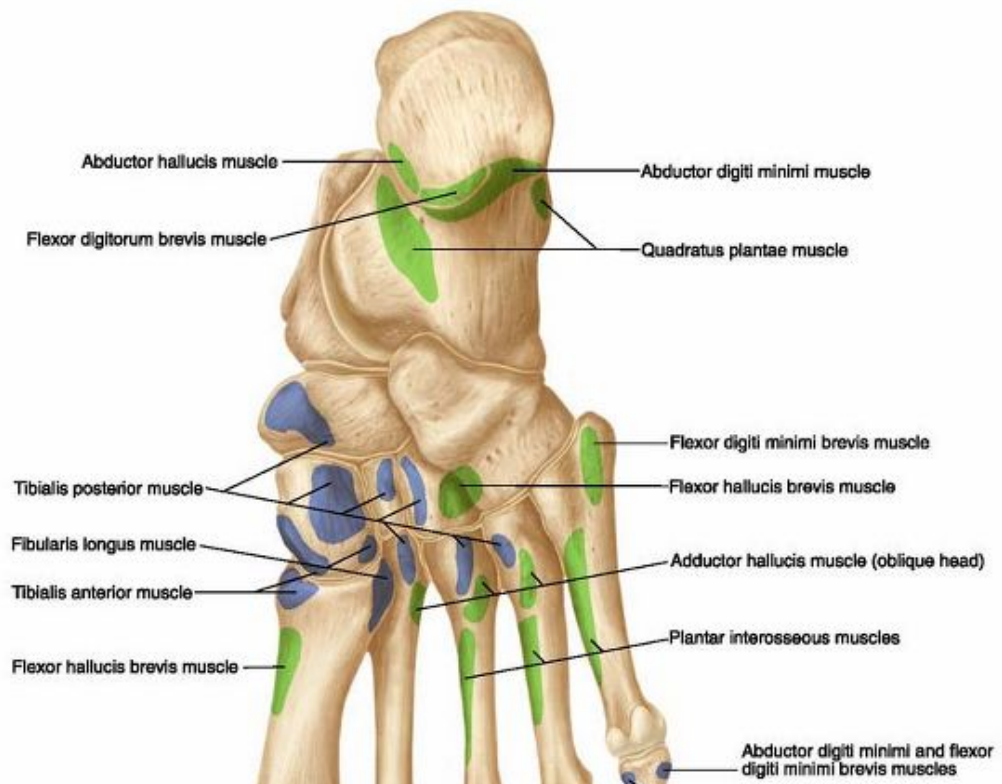


Plate 3-42 Muscle Attachments of the Foot, Dorsal Surface

Muscle attachments
 Origins
 Insertions



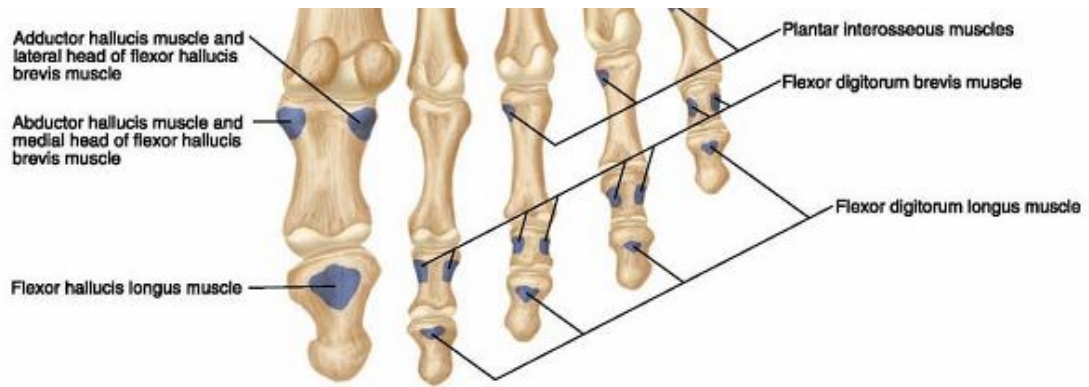


Plate 3-43 Muscle Attachments of the Foot, Plantar Surface

A. Dissection

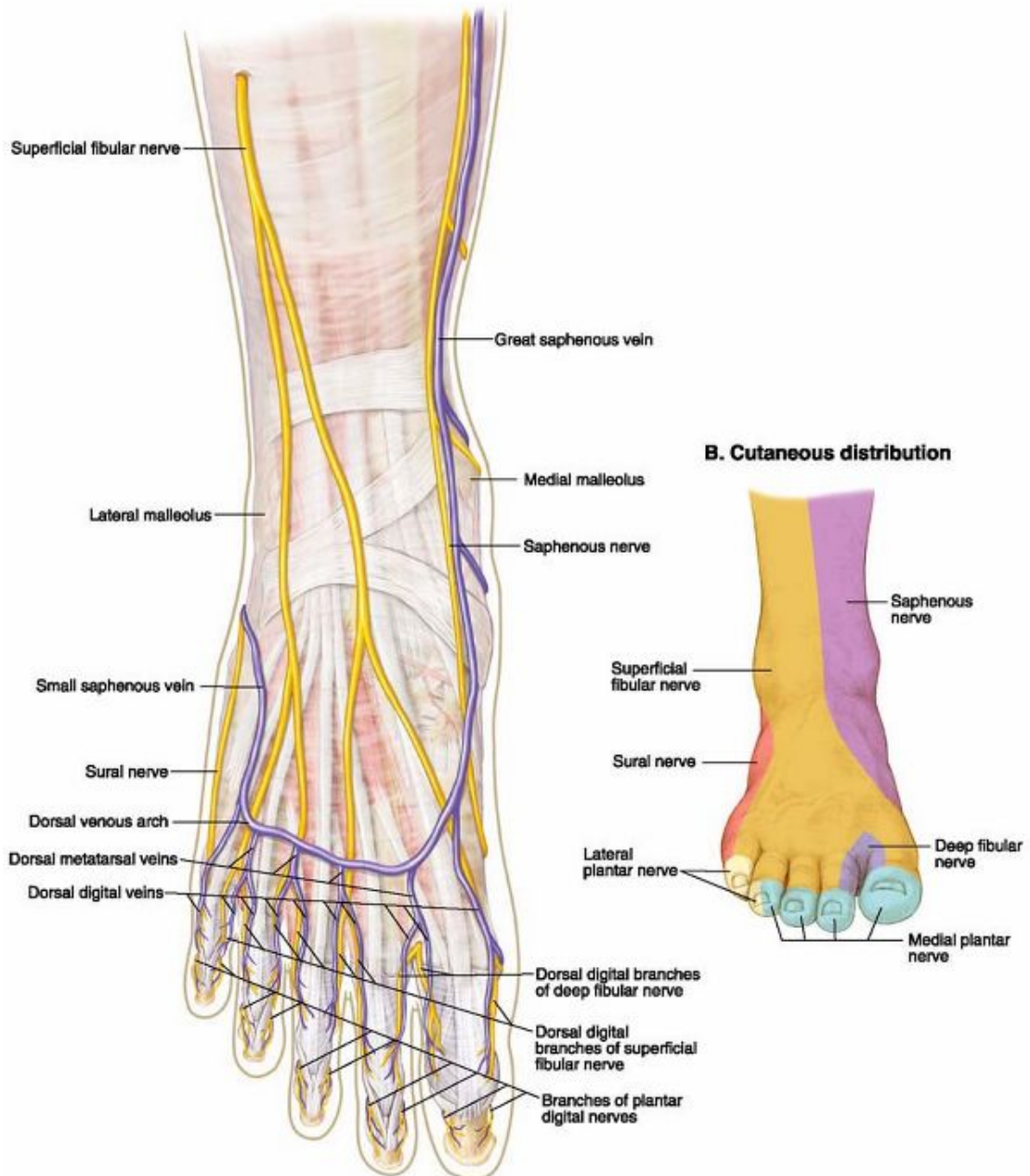



Plate 3-44 Cutaneous Nerves and Superficial Veins of the Dorsum of the Foot

P.131



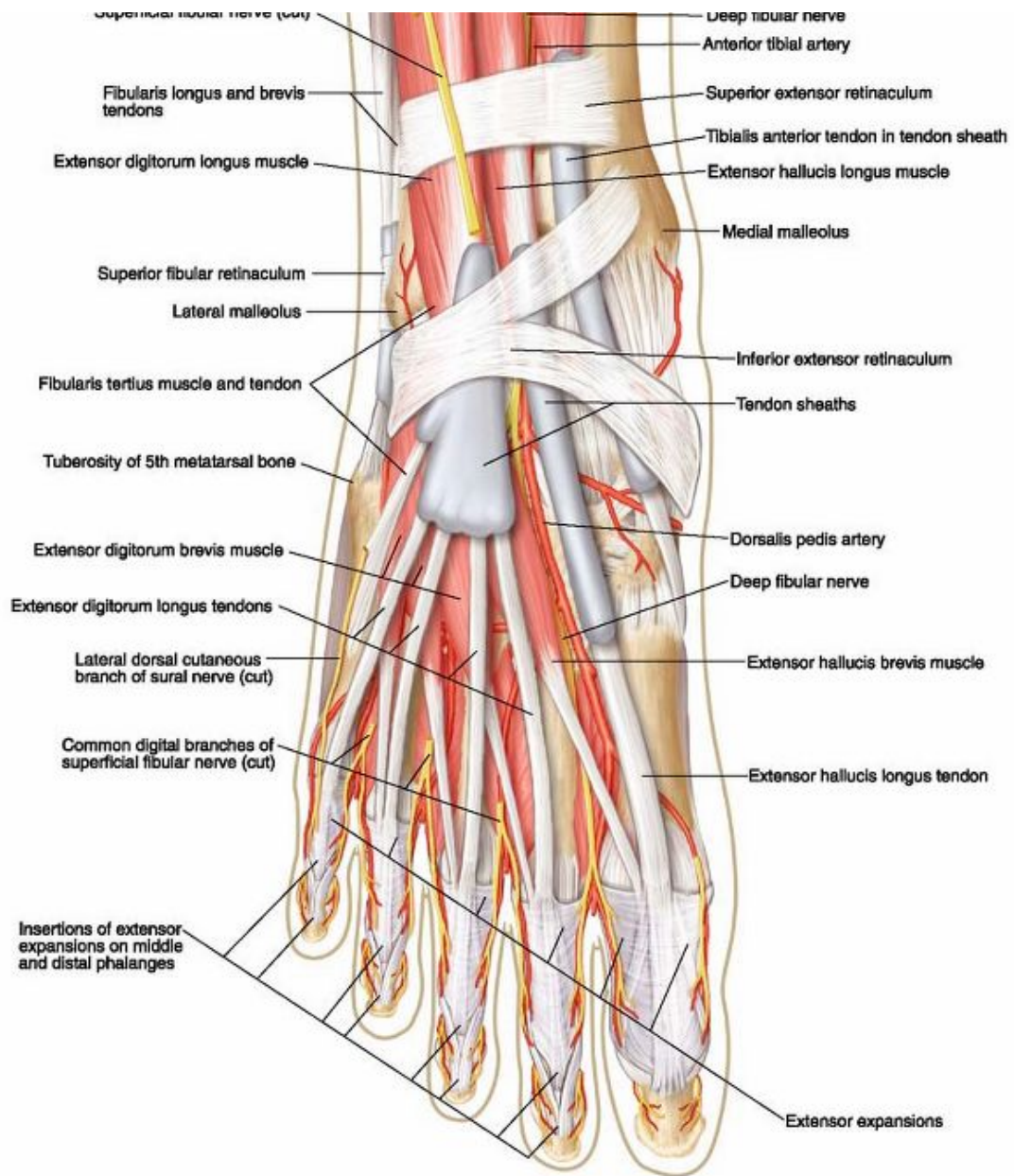
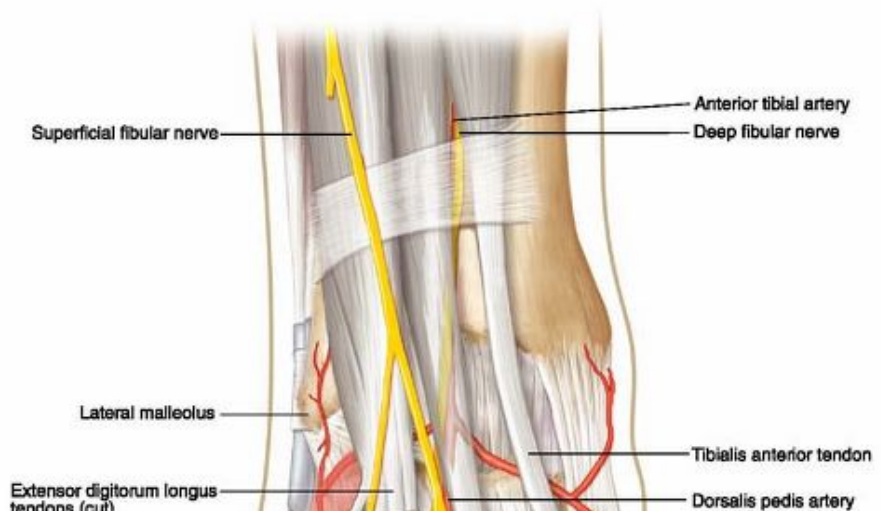


Plate 3-45 Dorsum of the Foot, Superficial Dissection



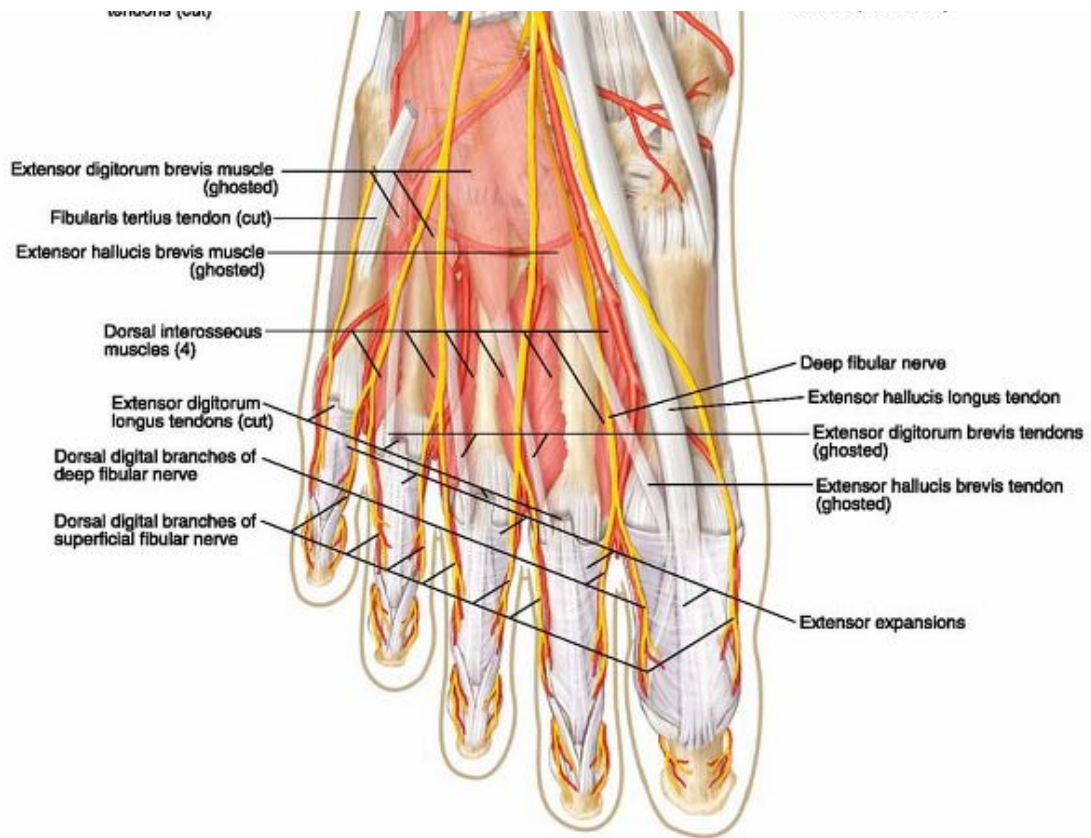
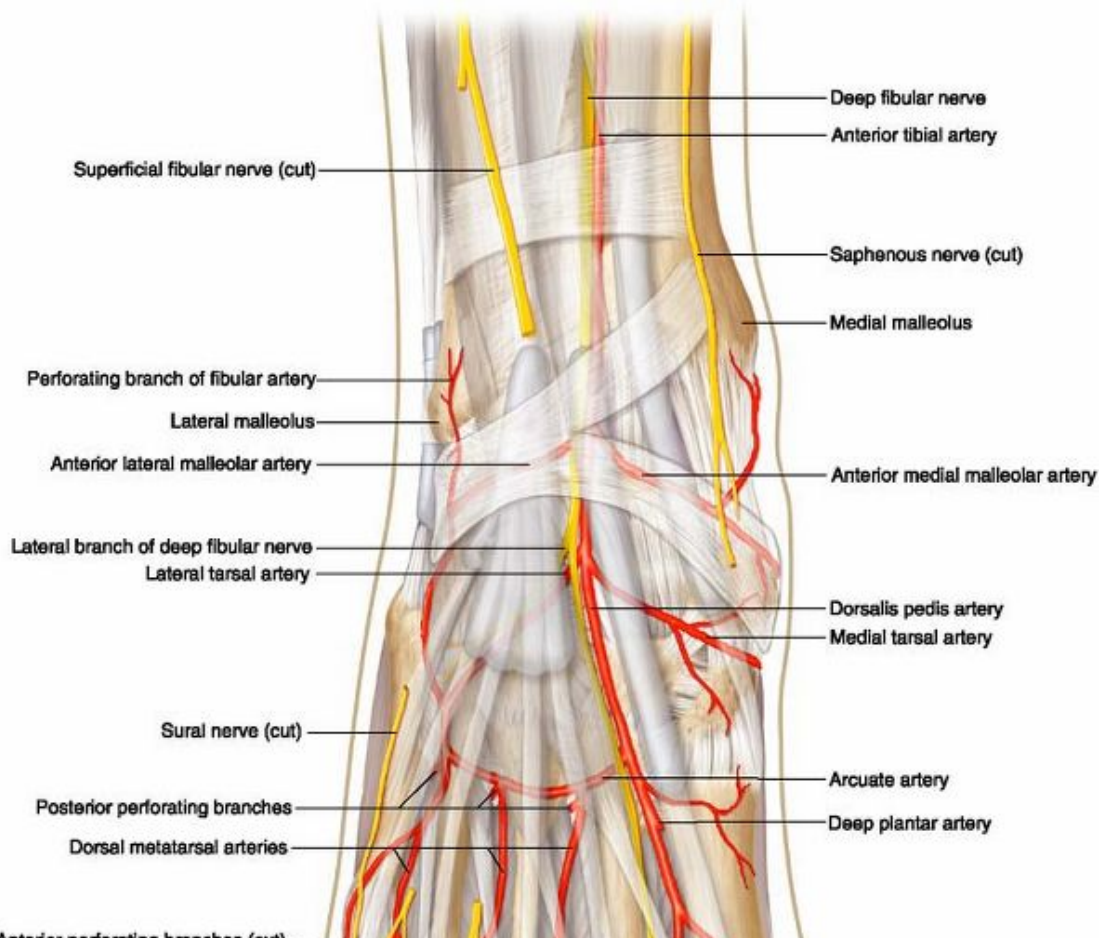
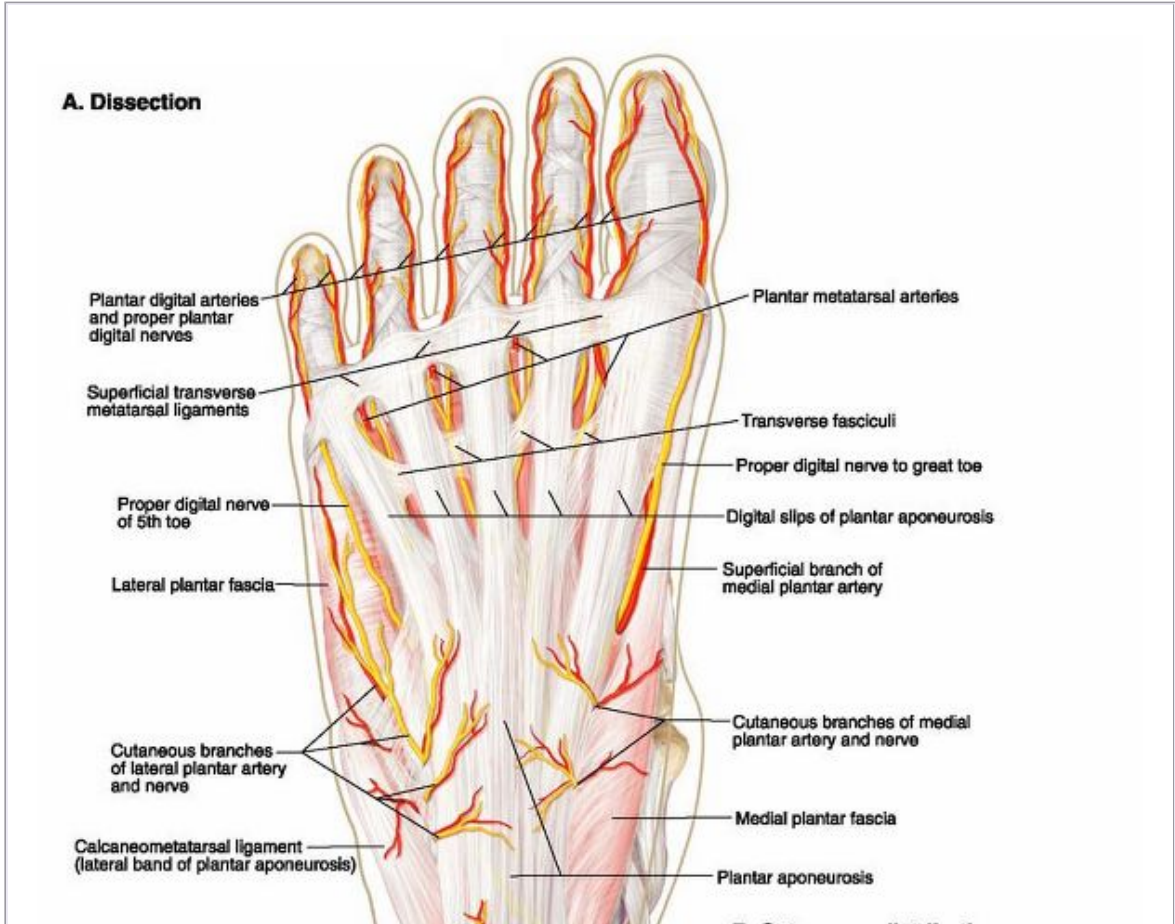
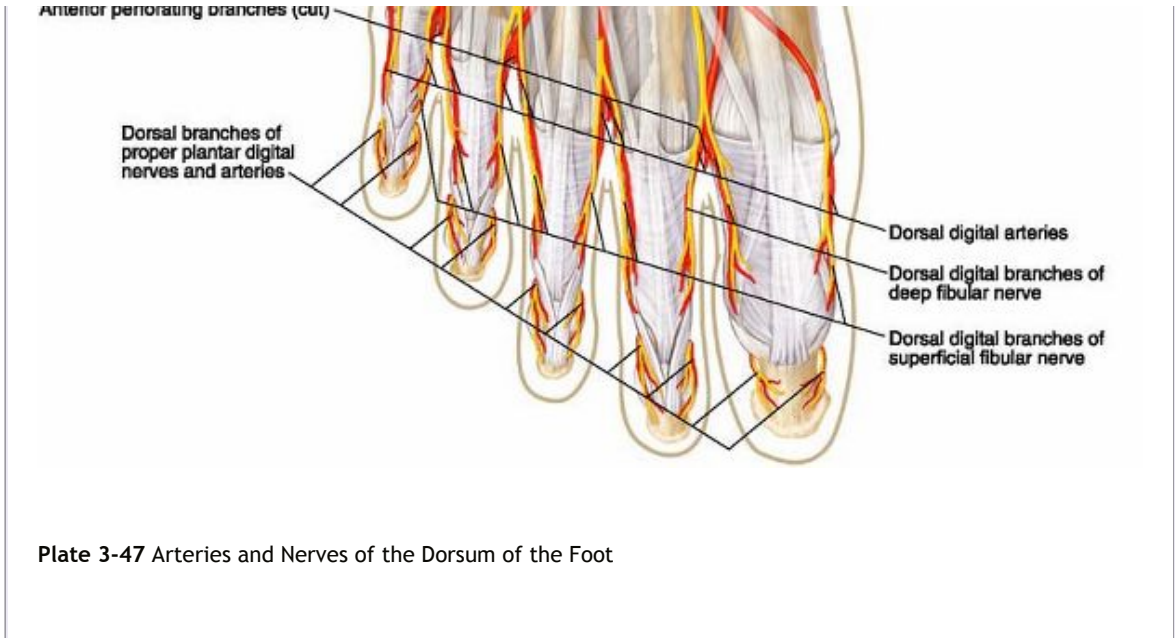


Plate 3-46 Dorsum of the Foot, Deep Dissection





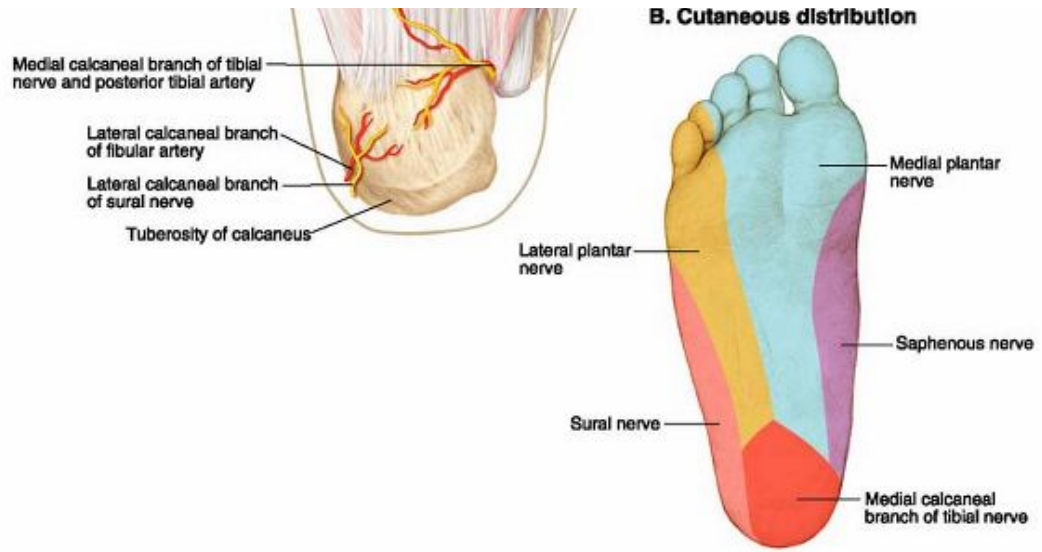


Plate 3-48 Cutaneous Nerves of the Sole of the Foot

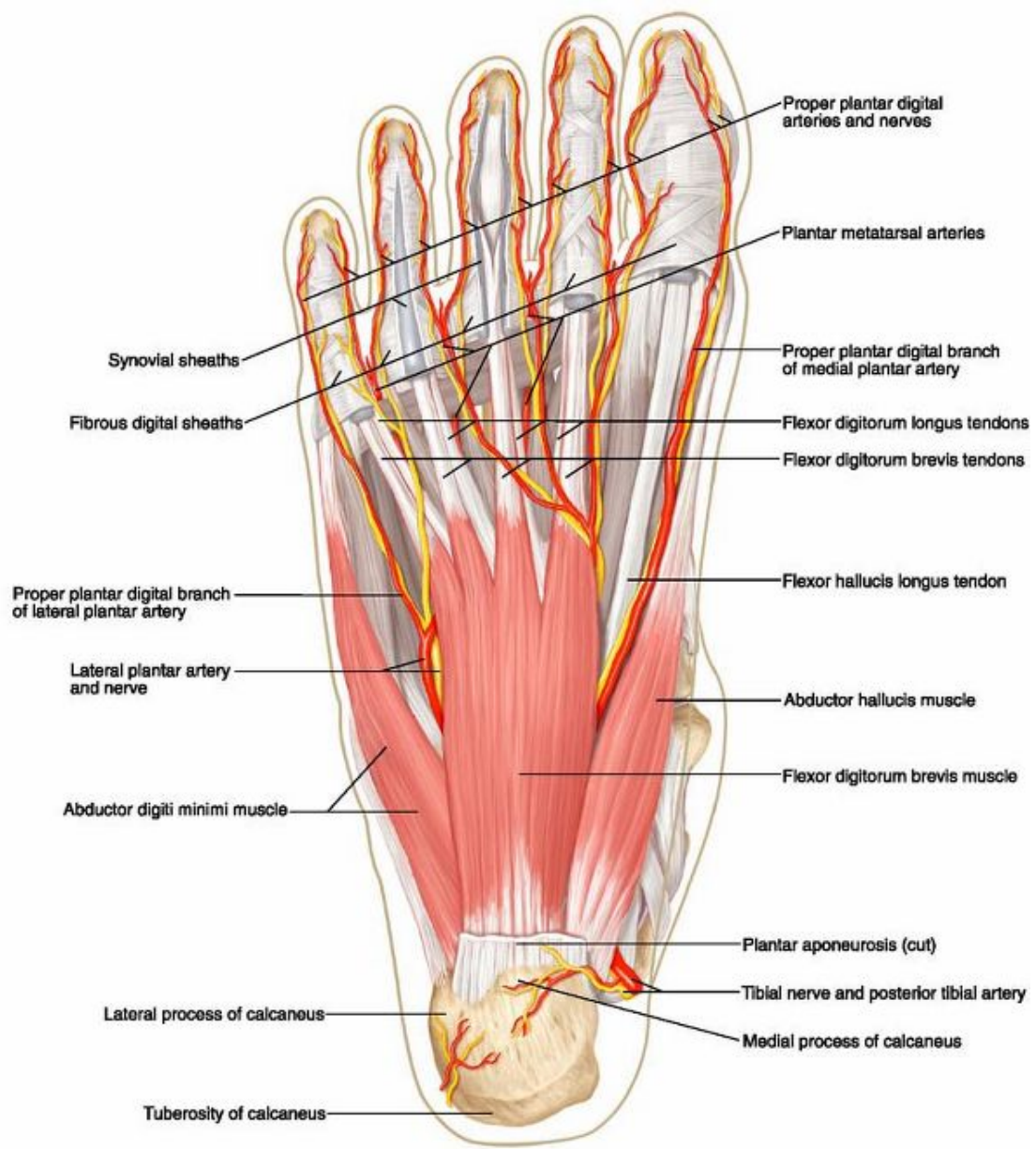


Plate 3-49 Muscles of the Sole of the Foot, First Layer



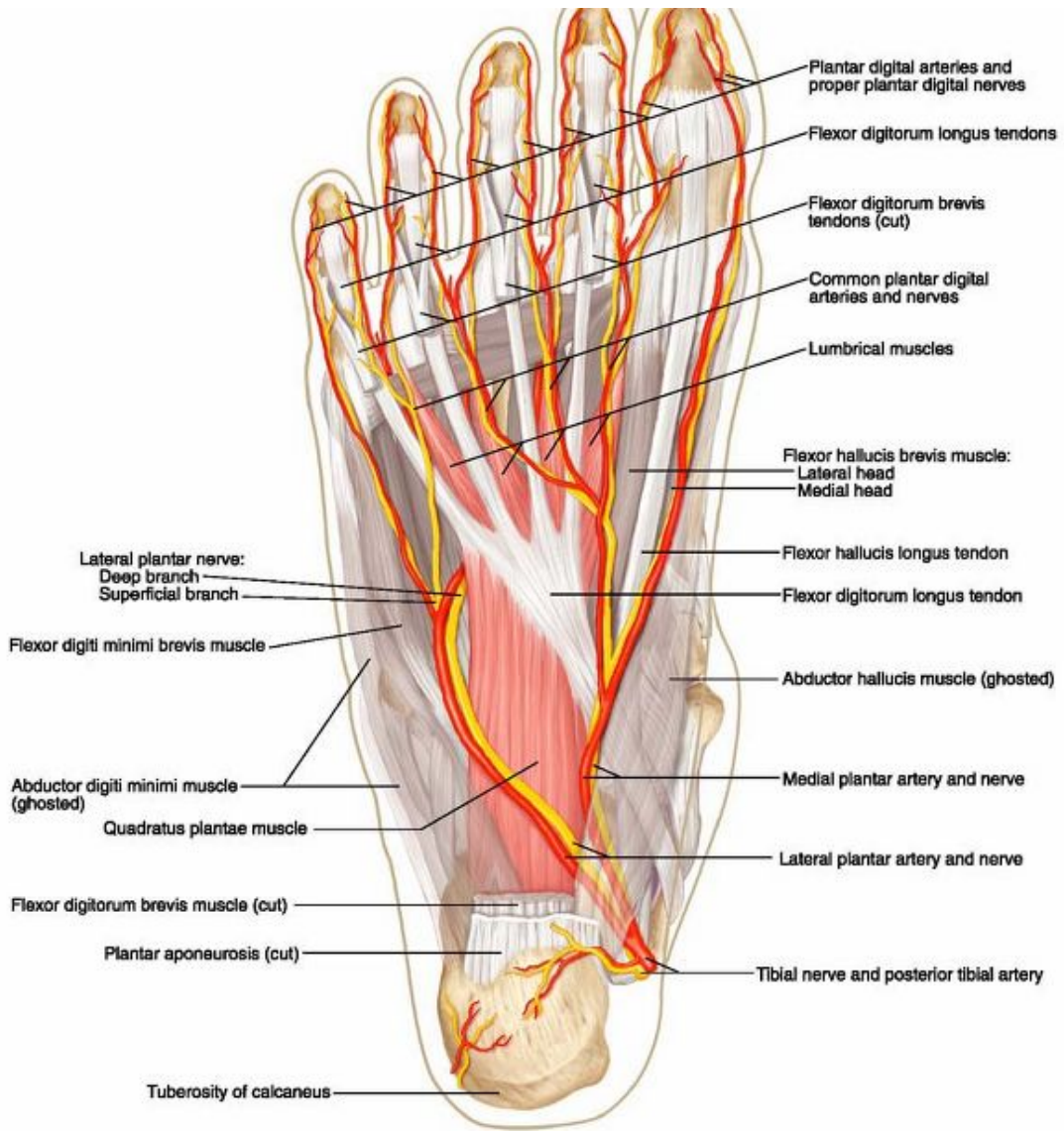
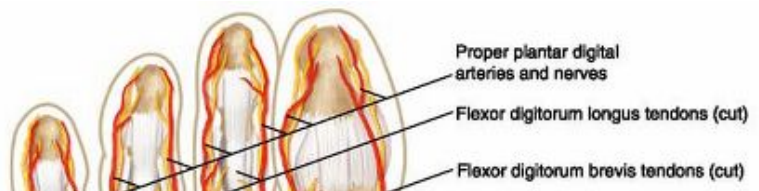


Plate 3-50 Muscles of the Sole of the Foot, Second Layer



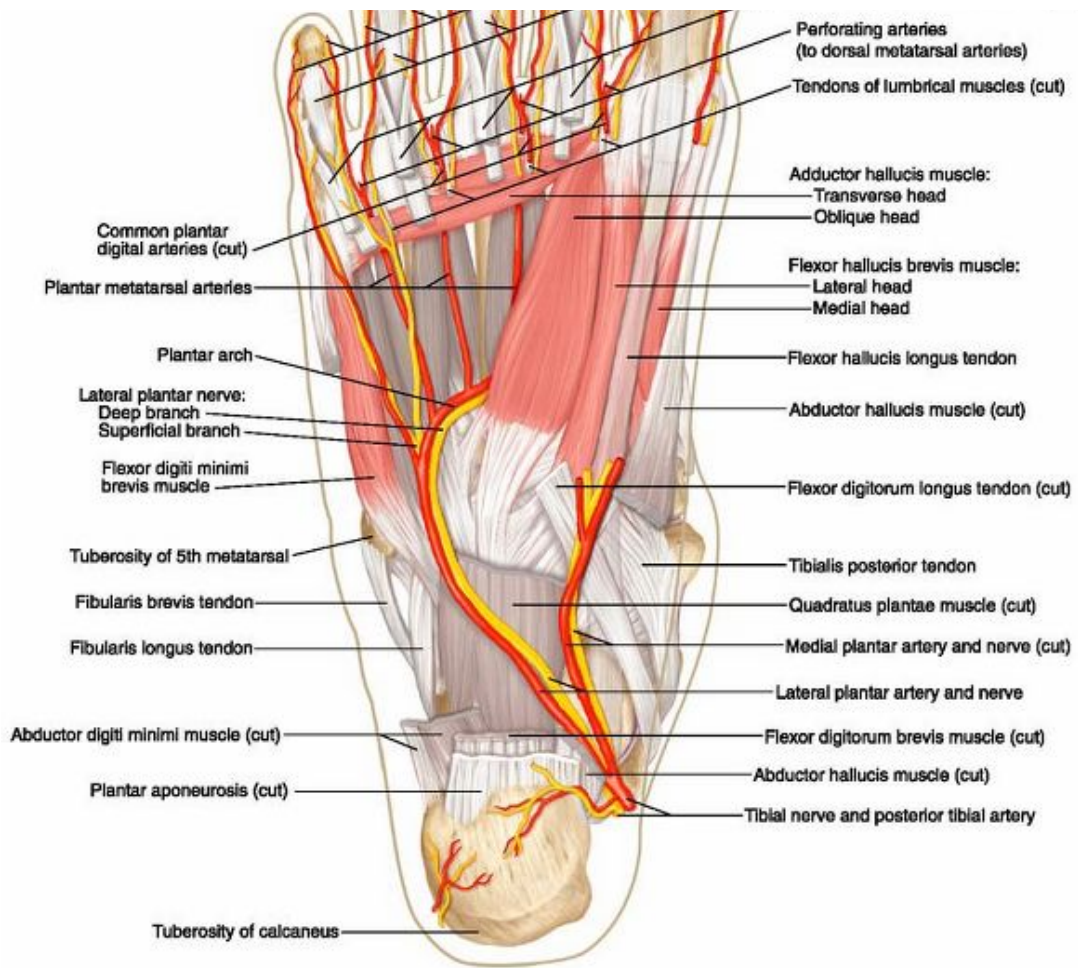
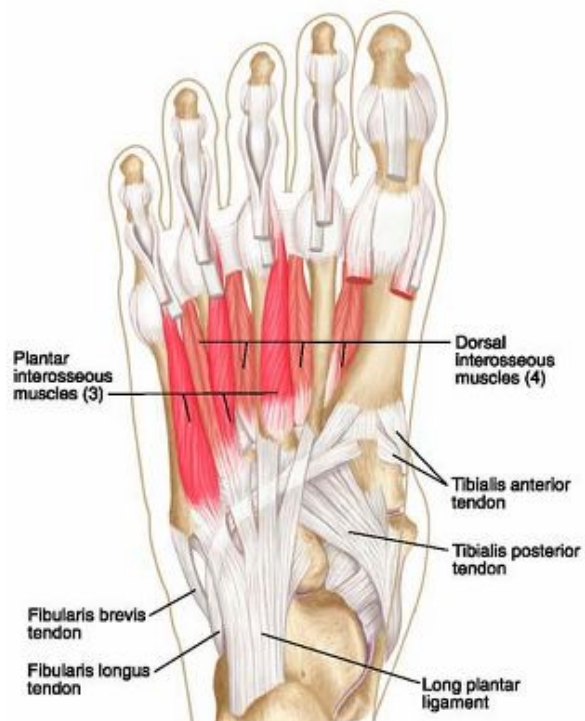
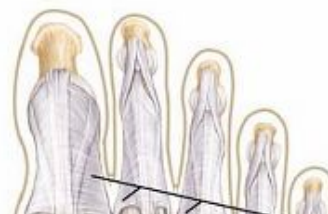
Plate 3-51 Muscles of the Sole of the Foot, Third Layer

A. Plantar view



B. Dorsal view



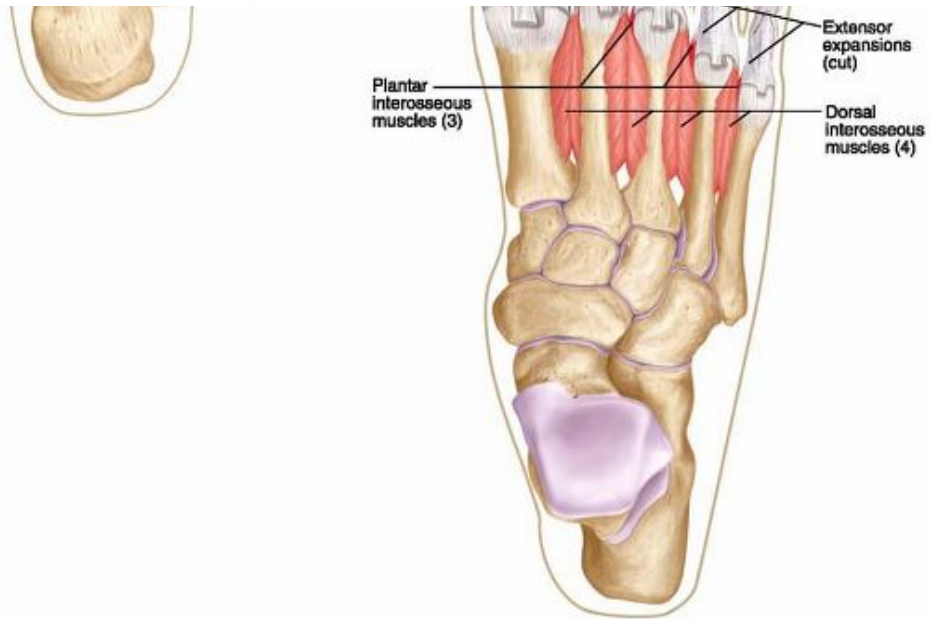
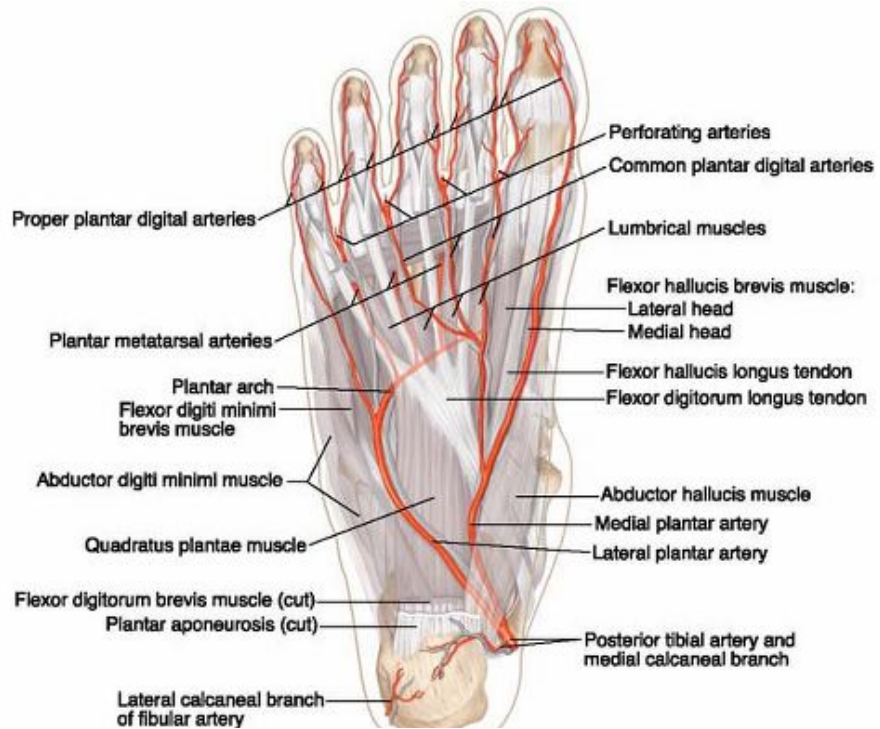


Plate 3-52 Muscles of the Sole of the Foot, Fourth Layer

A. Arteries



B. Nerves

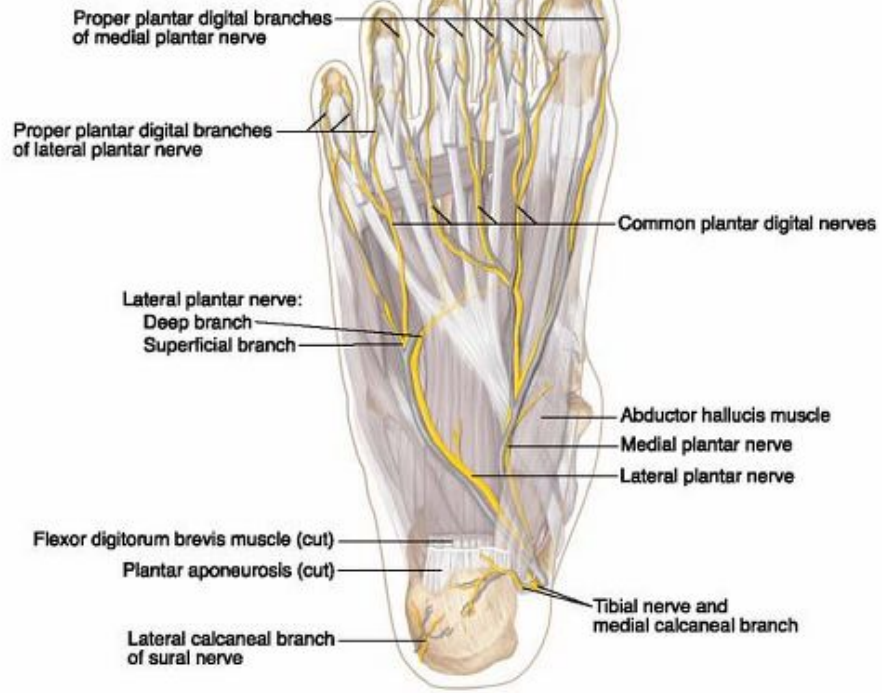
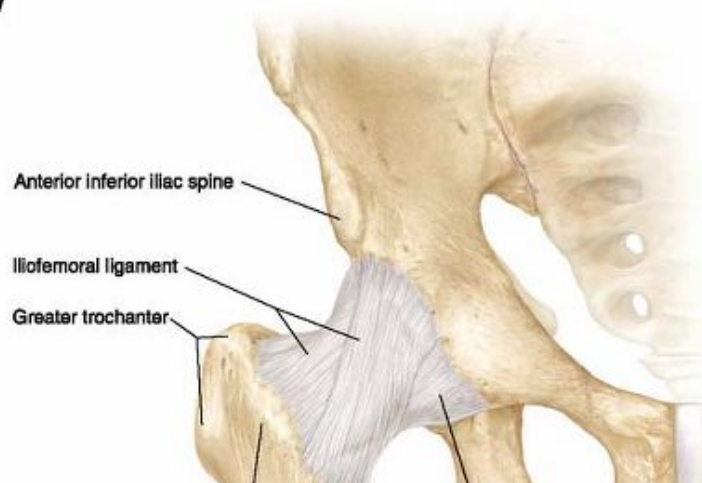
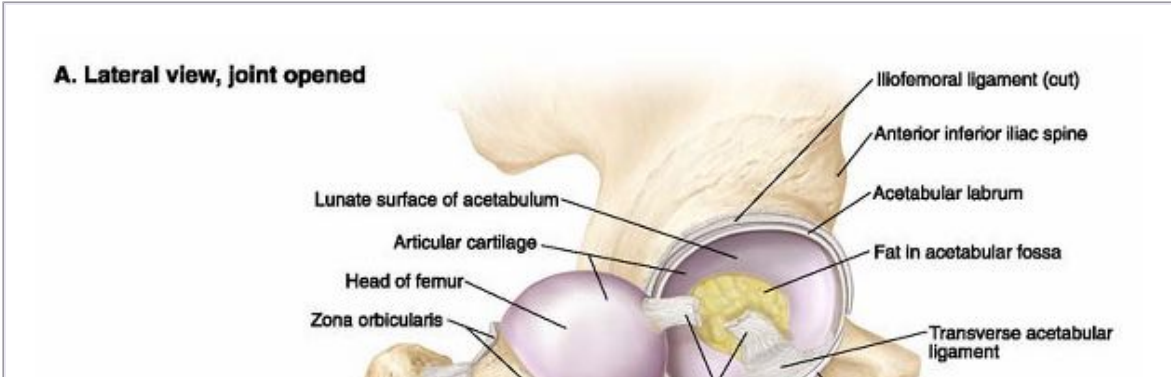
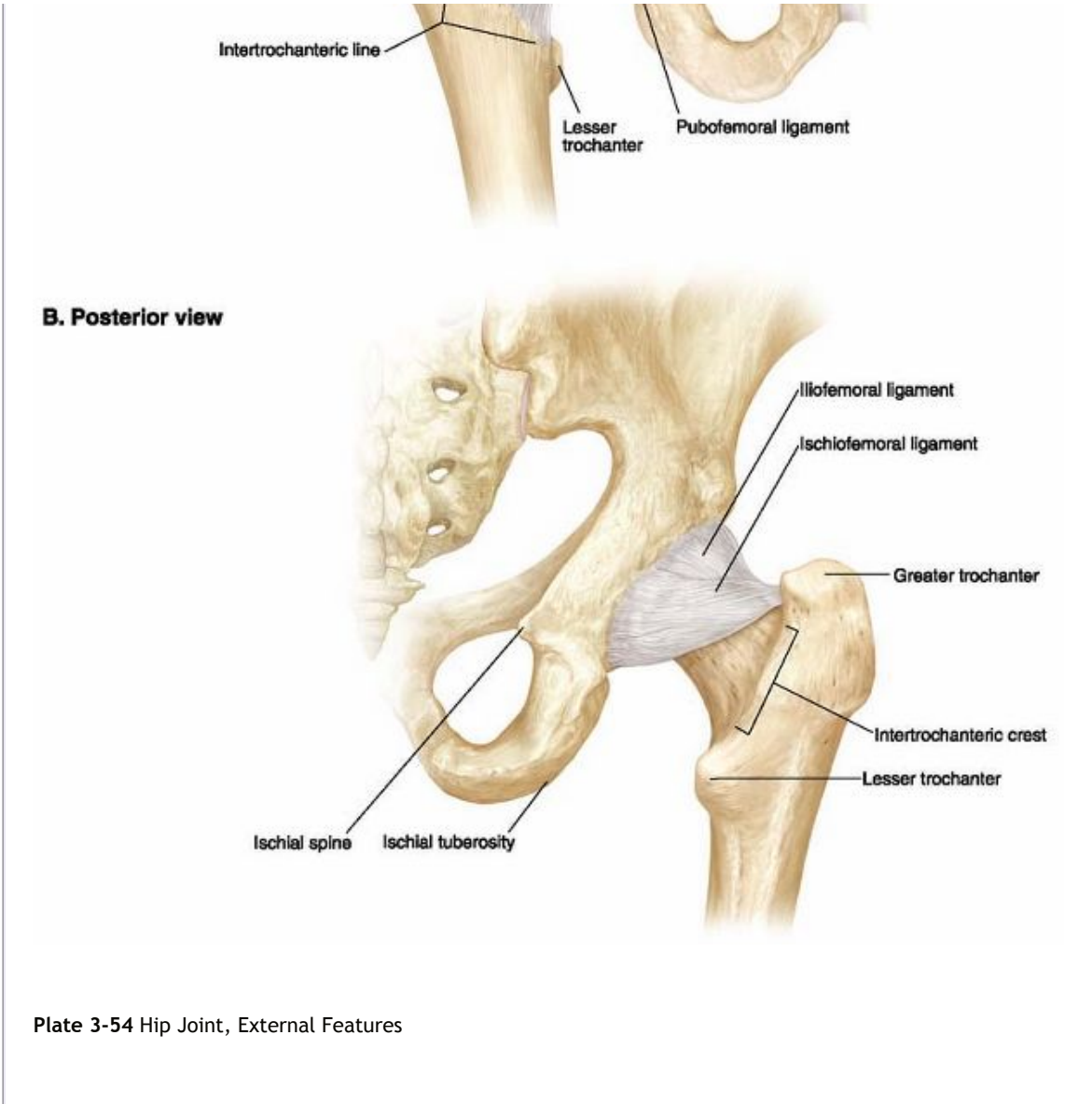
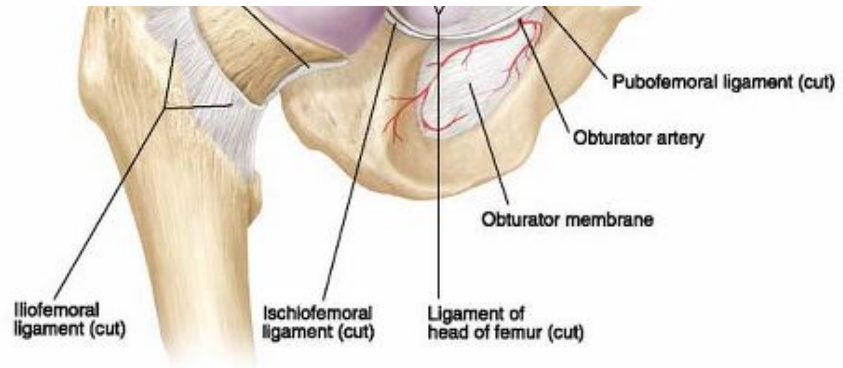


Plate 3-53 Arteries and Nerves of the Sole of the Foot

A. Anterior view







B. Blood supply

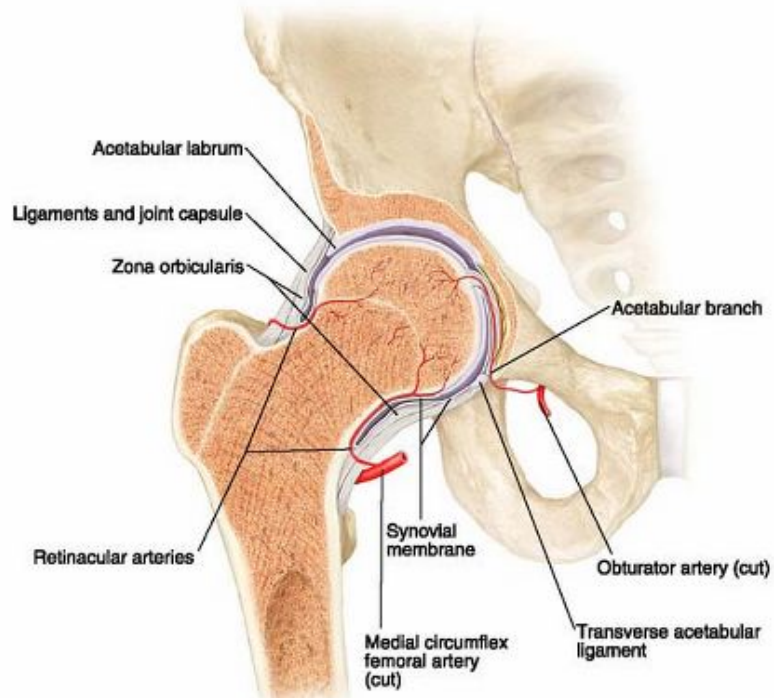
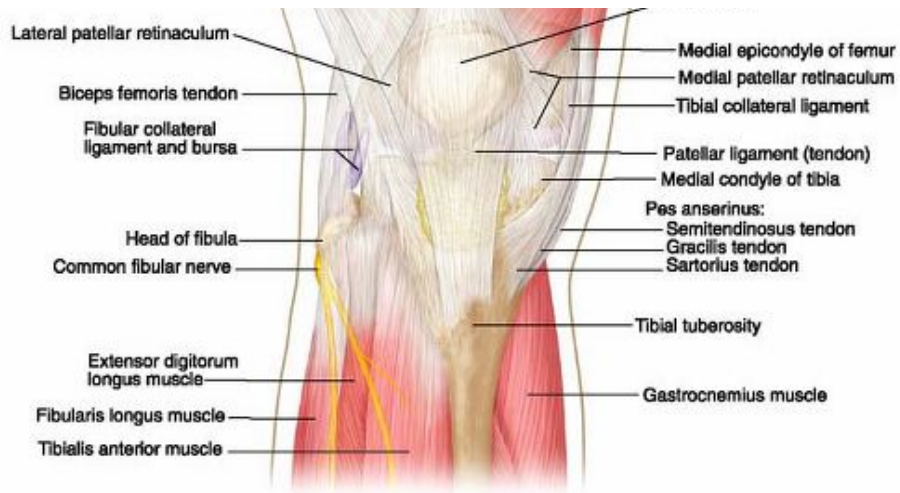


Plate 3-55 Hip Joint, Internal Features

A. Right knee, anterior view





B. Right knee, posterior view

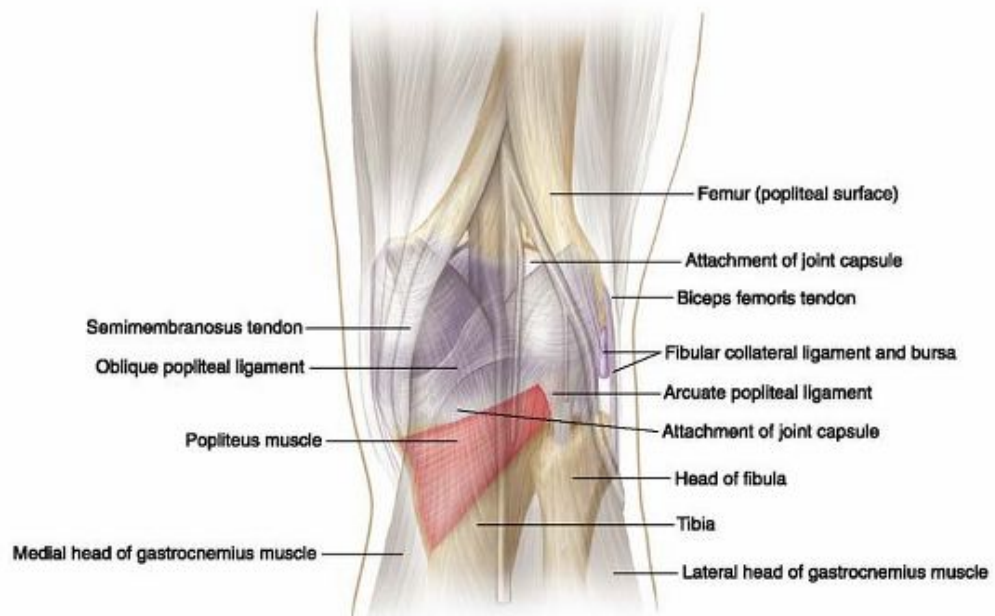
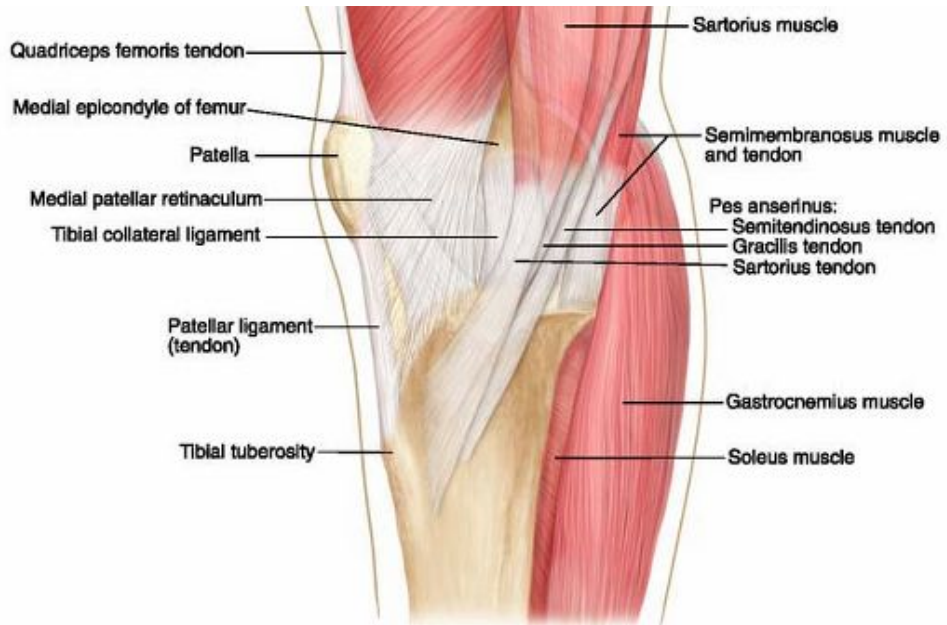


Plate 3-56 Knee Joint, Anterior and Posterior Views

A. Right knee, medial view





B. Right knee, lateral view

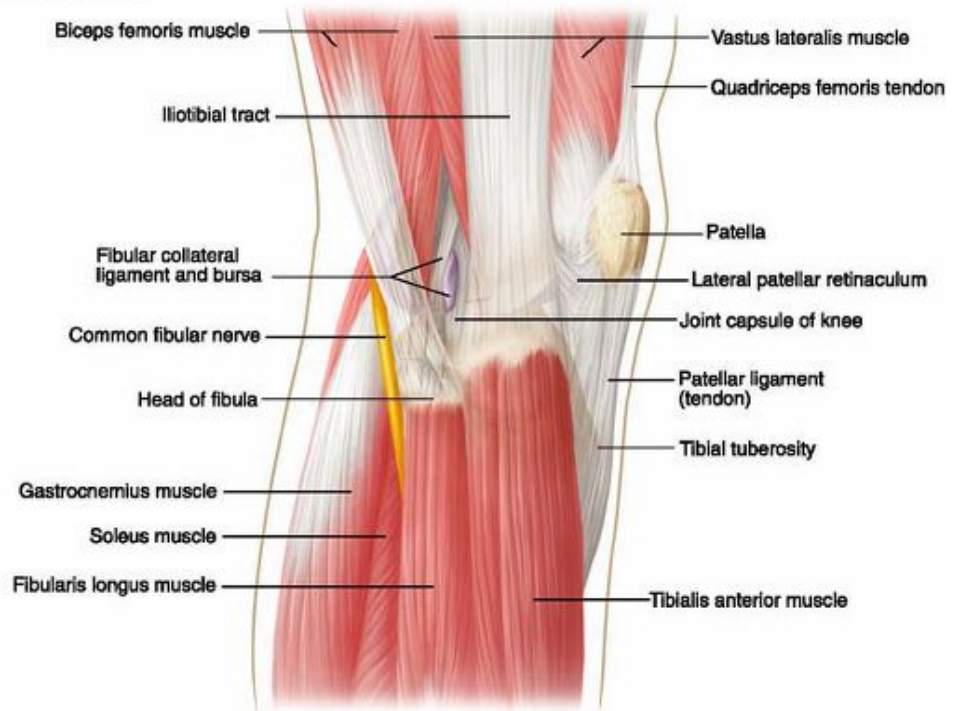
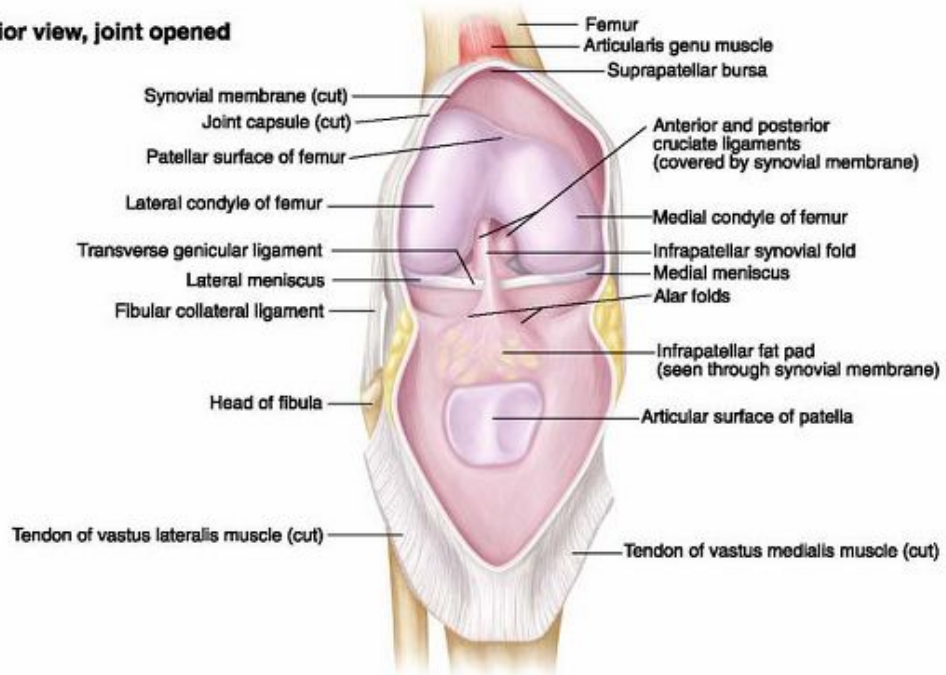
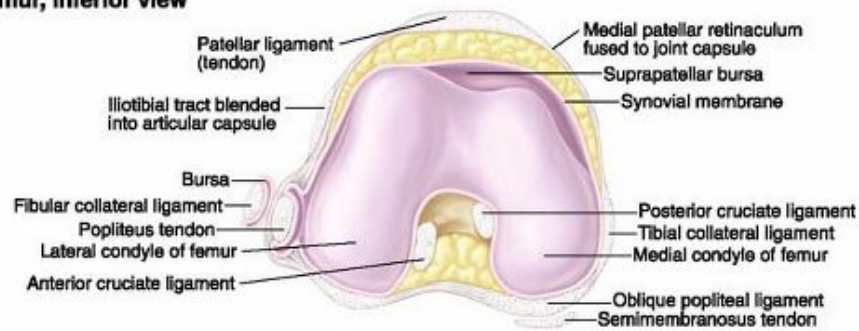


Plate 3-57 Knee Joint, Medial and Lateral Views

A. Anterior view, joint opened



B. Distal femur, inferior view



C. Proximal tibia, superior view

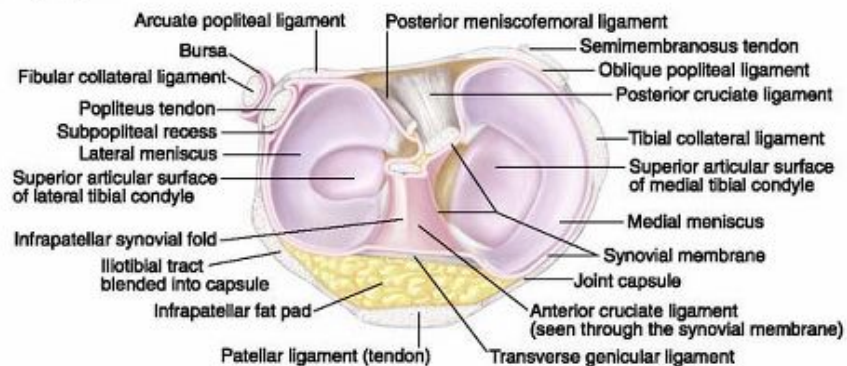
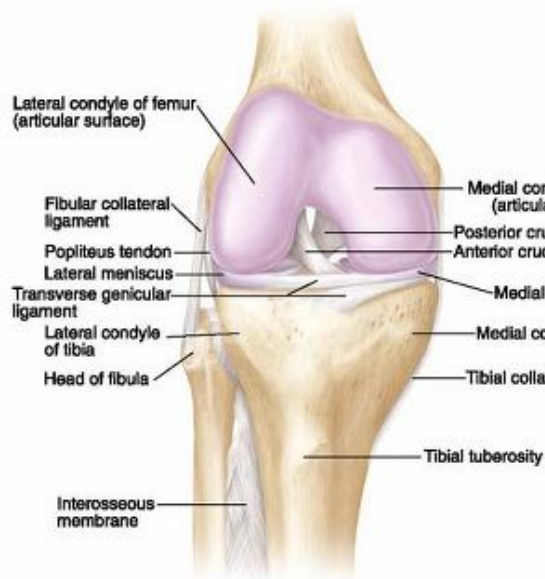
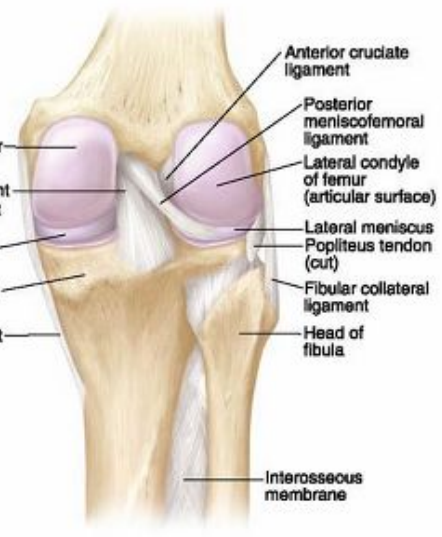


Plate 3-58 Knee Joint, Internal View

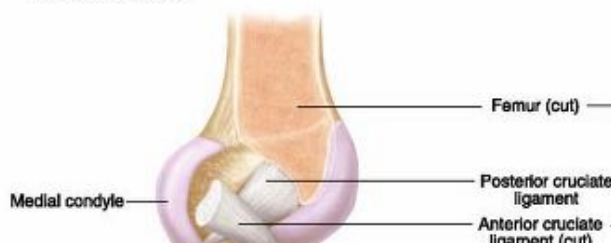A. Ligaments, anterior view



B. Ligaments, posterior view



C. Cruciate ligaments, lateral view, knee extended



D. Cruciate ligaments, lateral view, knee flexed

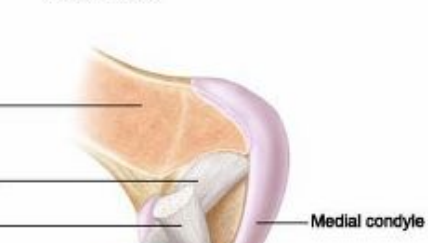


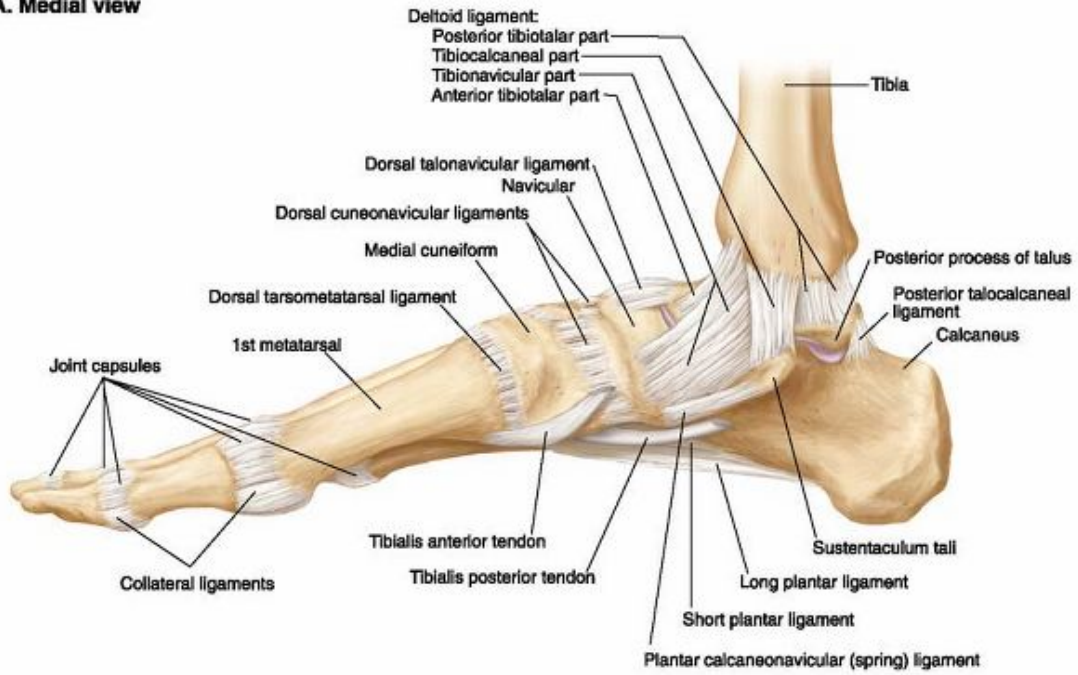


Plate 3-59 Ligaments of the Knee Joint, Internal View

A. Medial view



B. Lateral view

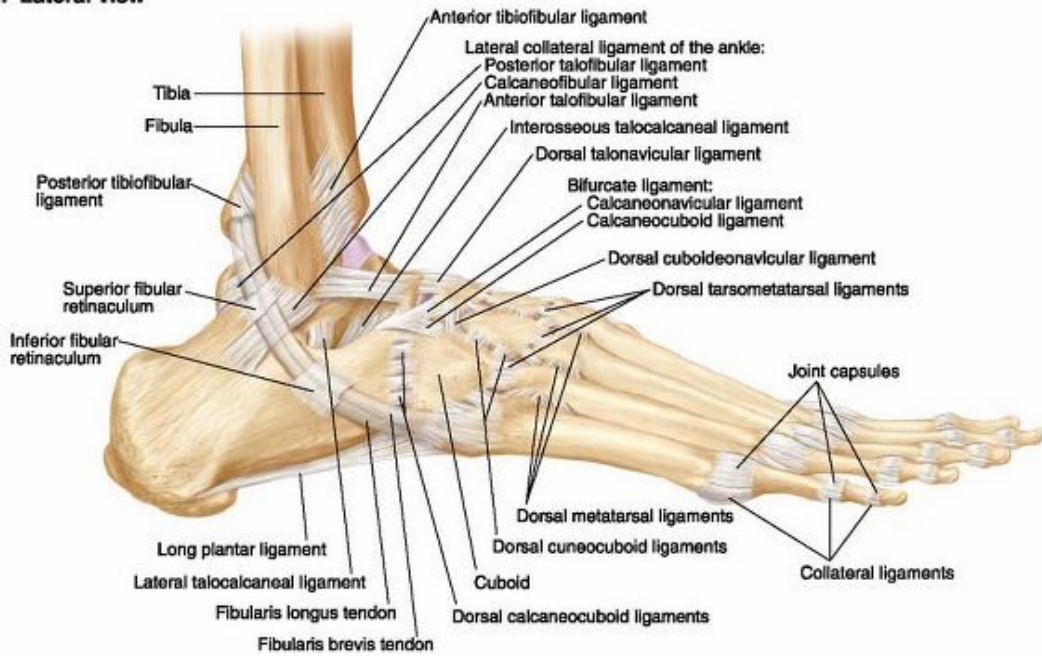
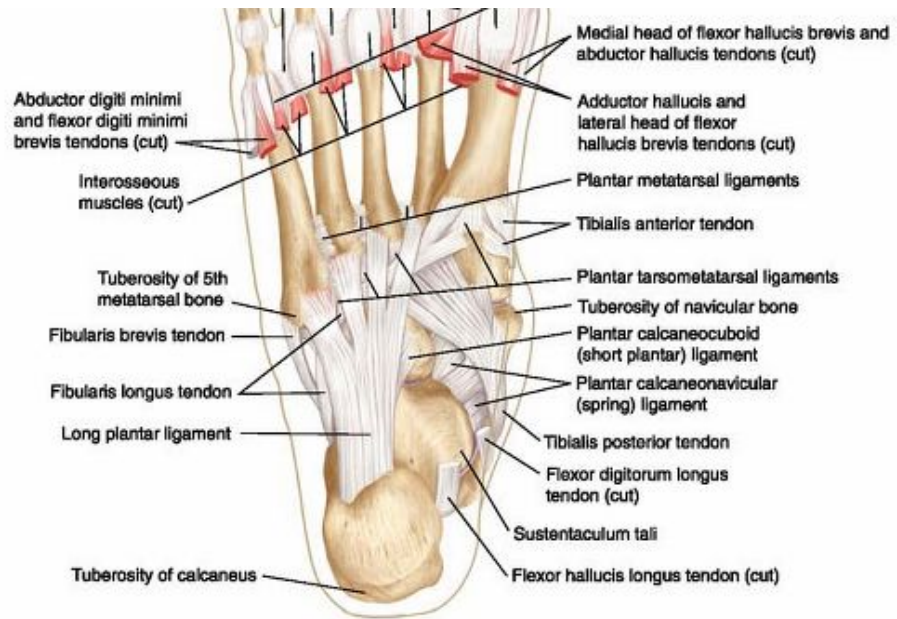


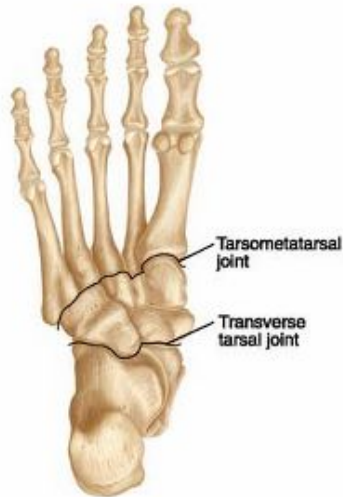Plate 3-60 Ankle Joint and Joints of the Foot

A. Plantar view





B. Joints of inversion and eversion



C. Ligament attachments

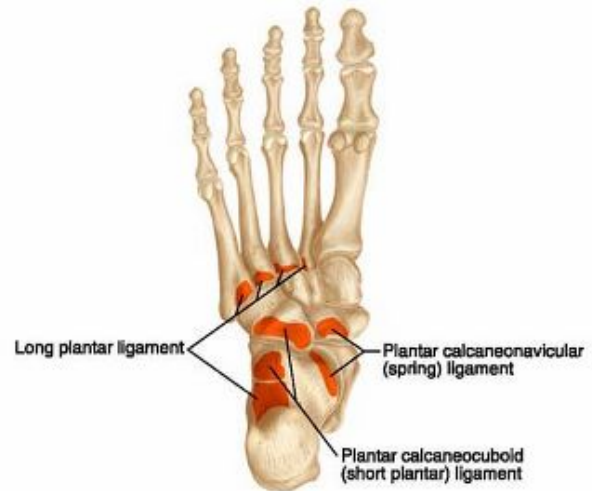
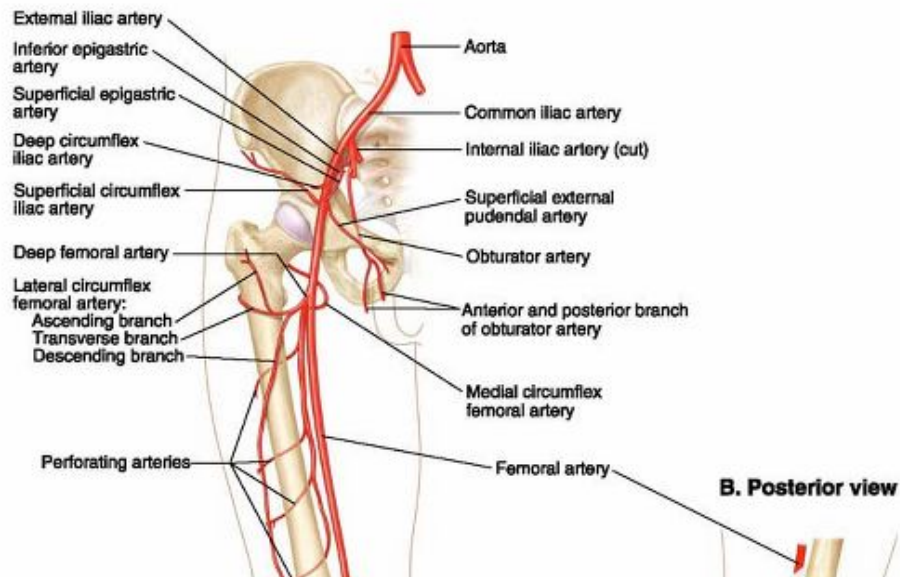


Plate 3-61 Joints of Foot

A. Anterior view



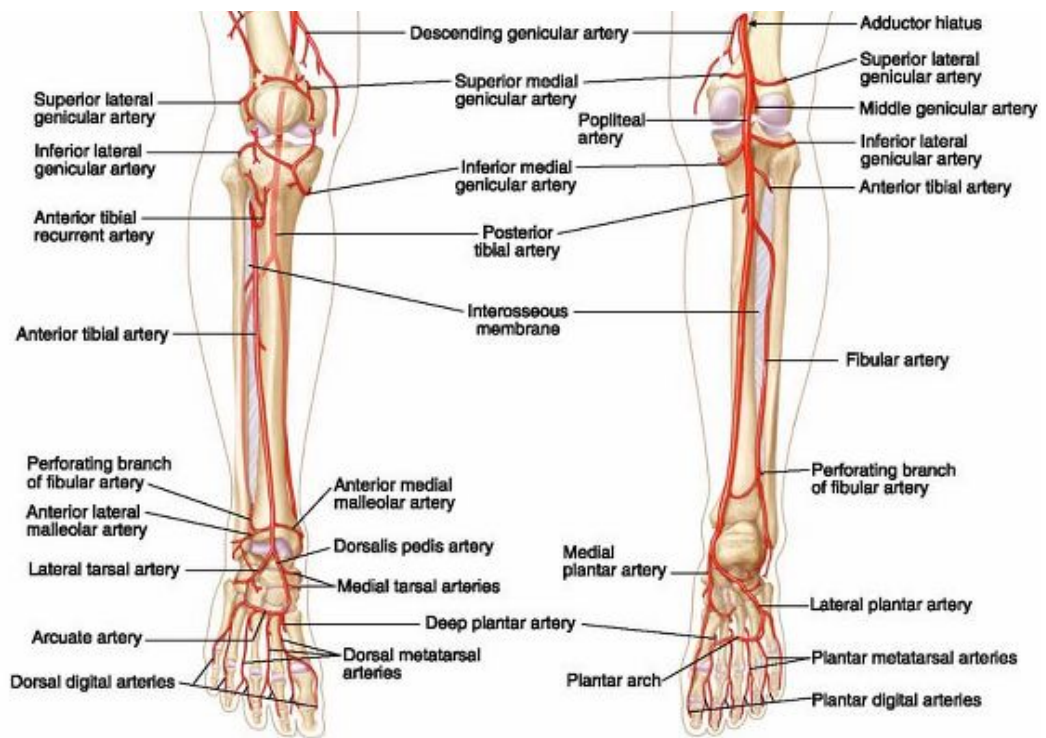
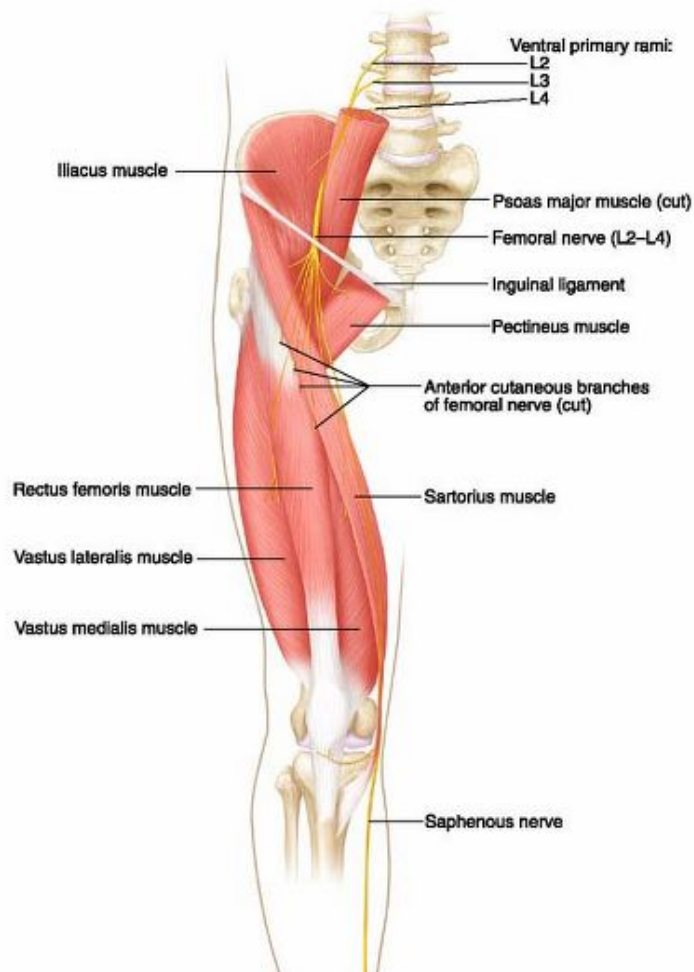


Plate 3-62 Arteries of the Lower Limb

A. Anterior view



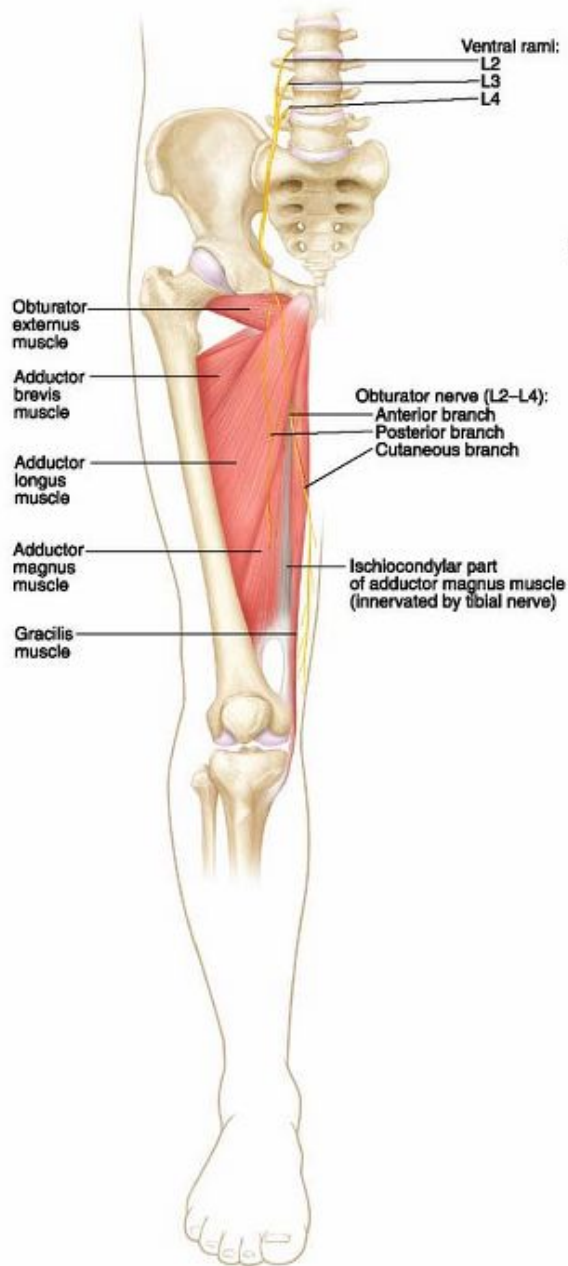
B. Cutaneous distribution, anterior view



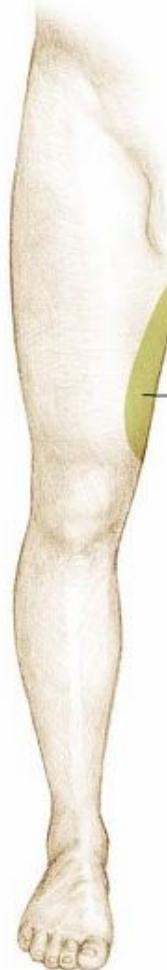

Plate 3-63 Femoral Nerve

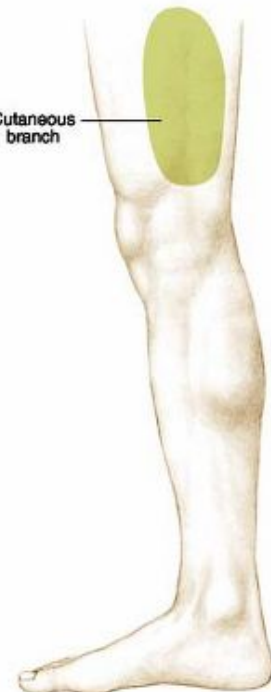A. Anterior view



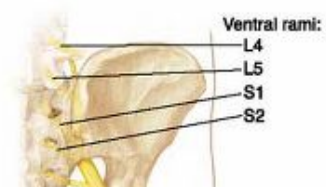B. Cutaneous distribution, anterior view



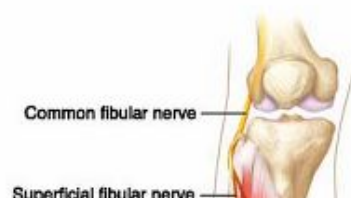C. Cutaneous distribution, medial view

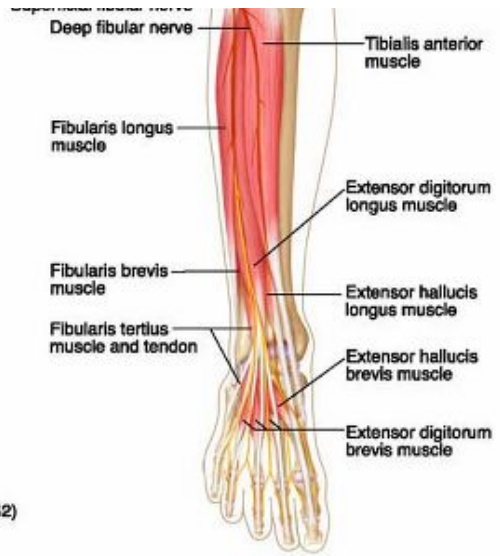
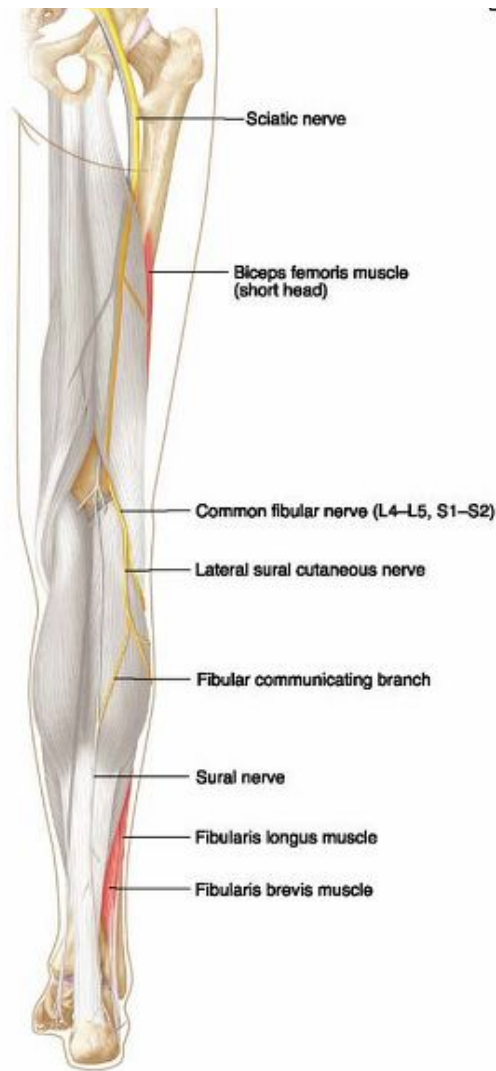


A. Posterior view



B. Anterior view





C. Cutaneous distribution, anterior view

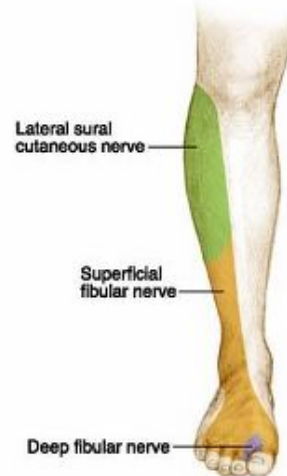
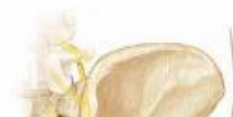

Plate 3-65 Common Fibular Nerve

A. Superficial view



B. Deep view



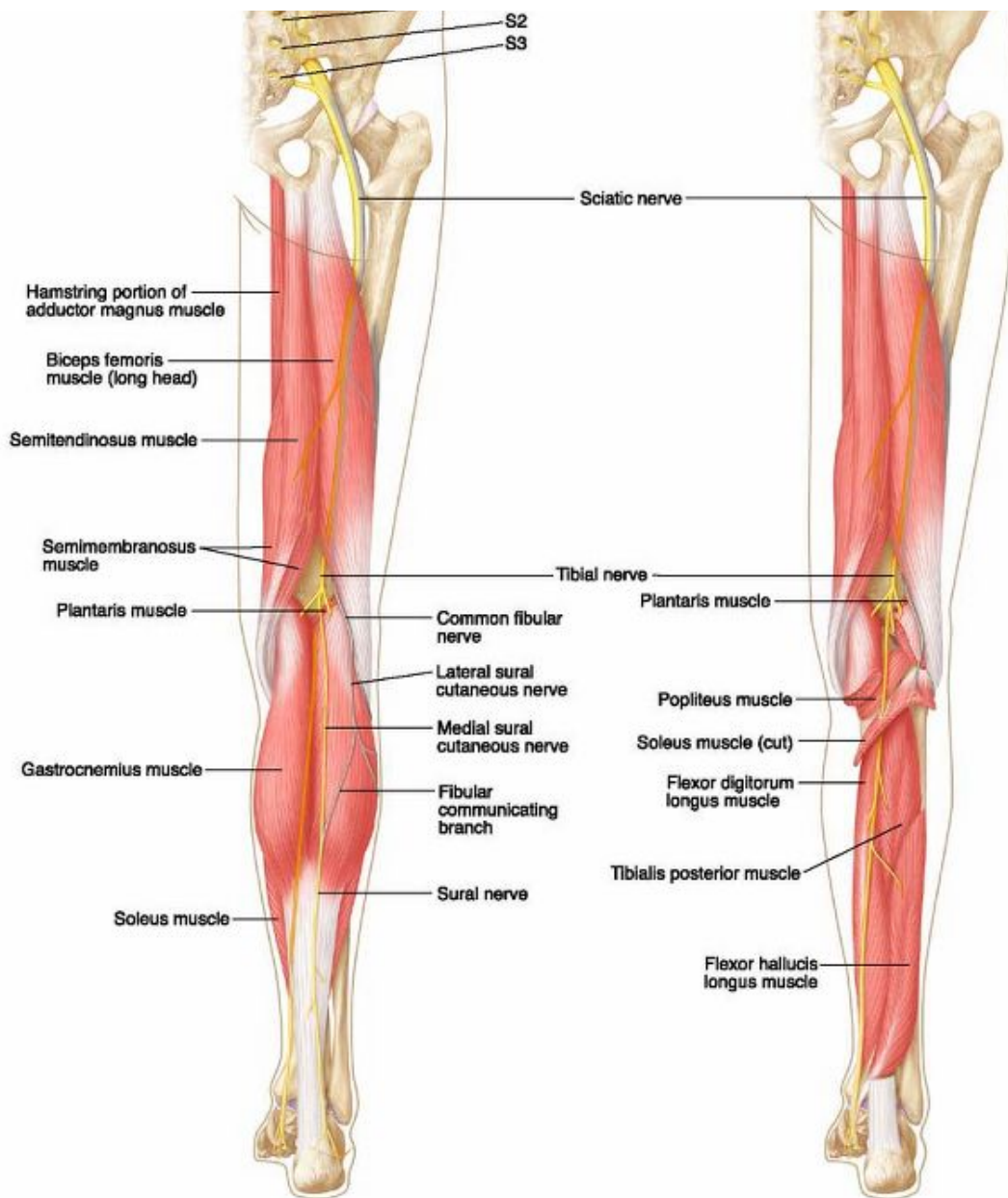
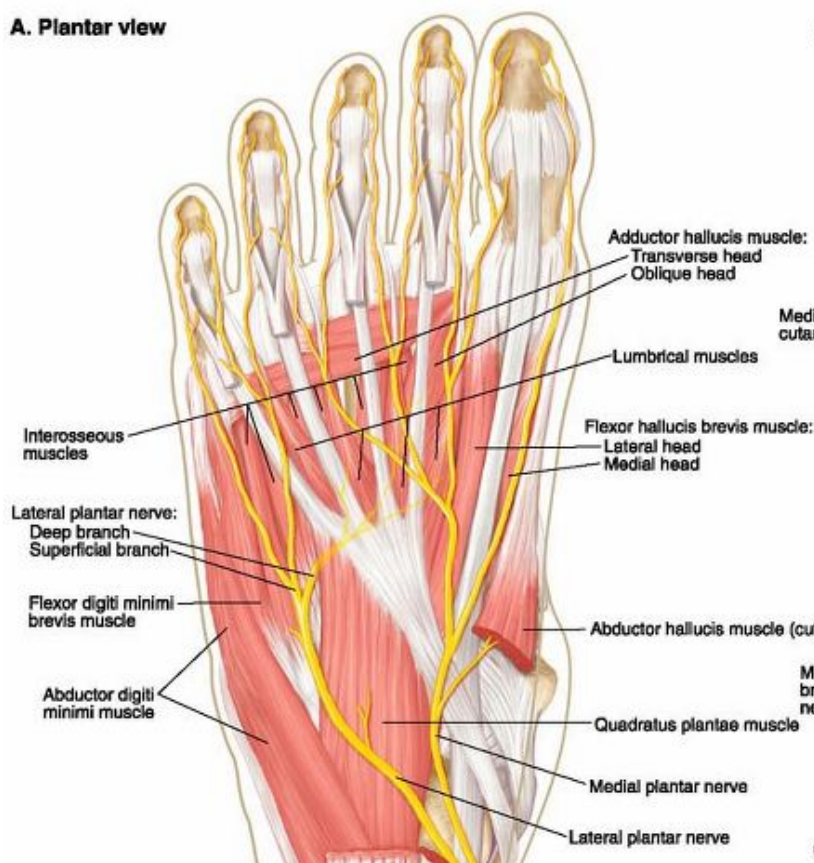
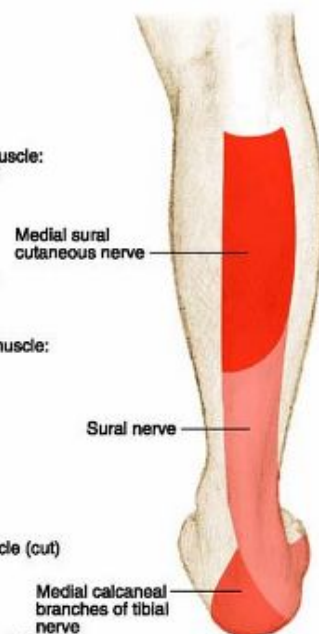


Plate 3-66 Tibial Division of Sciatic Nerve, Superficial and Deep Views

A. Plantar view



B. Cutaneous distribution, posterior view



C. Cutaneous distribution,

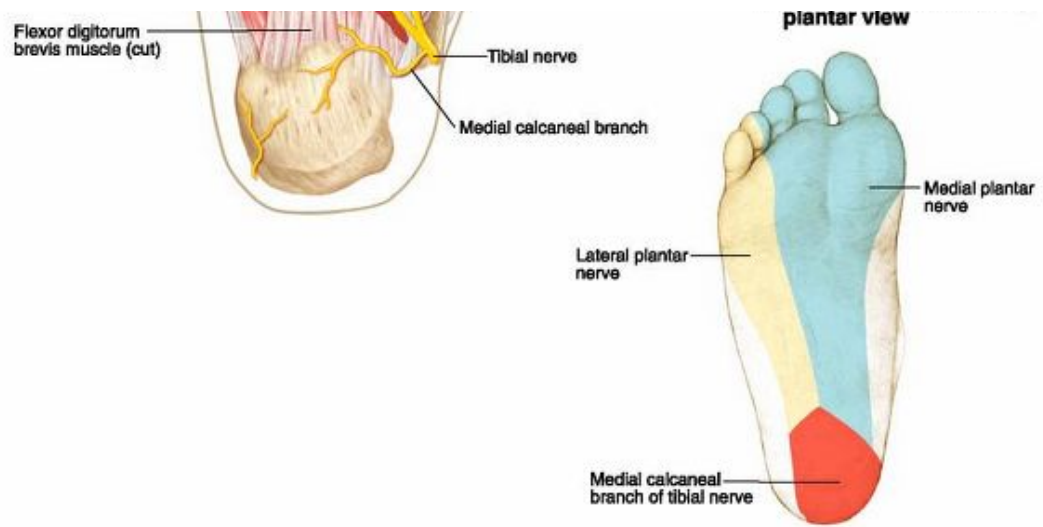
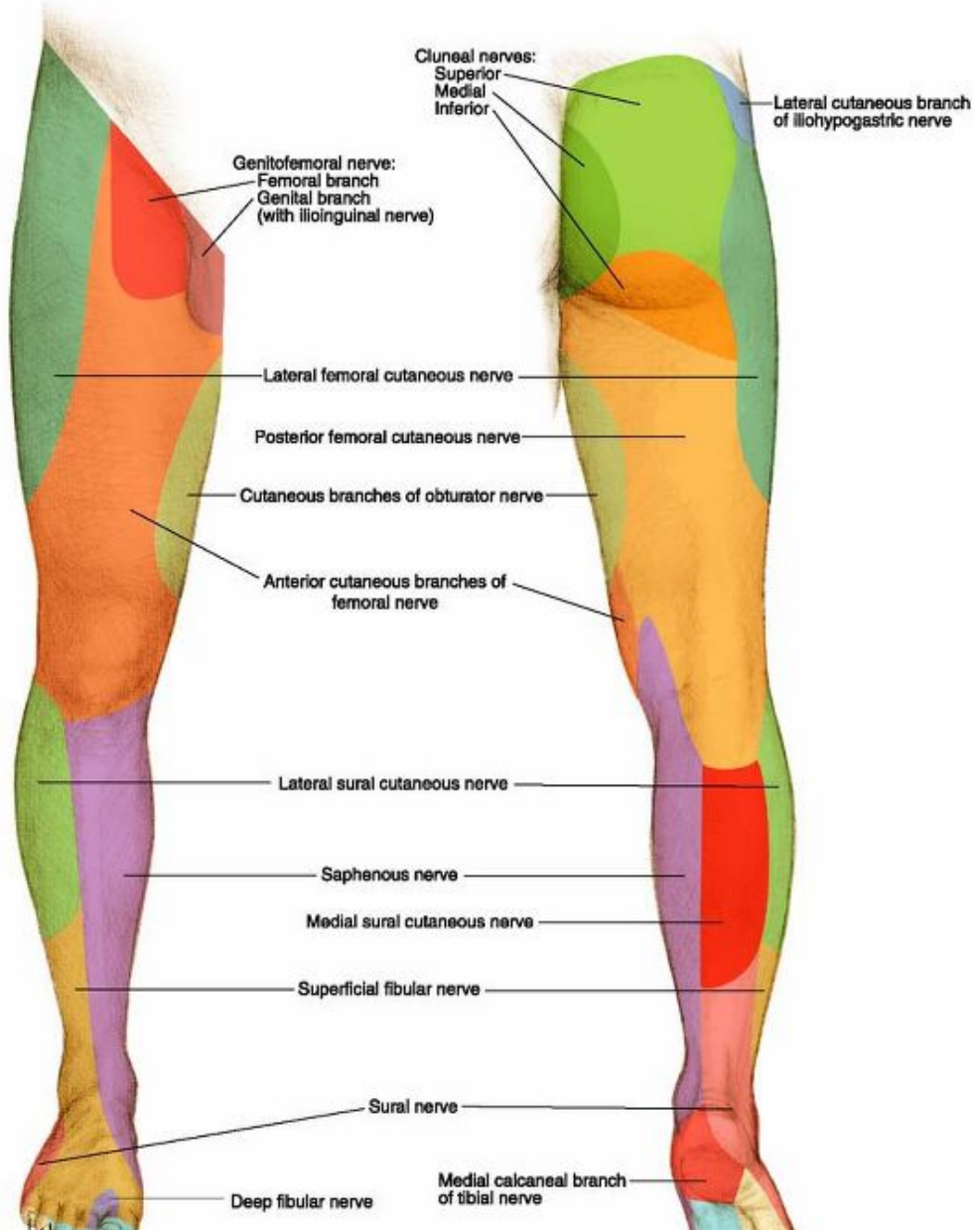


Plate 3-67 Tibial Division of Sciatic Nerve, Plantar View and Cutaneous Distribution

A. Anterior view

B. Posterior view



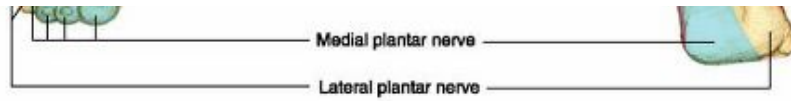
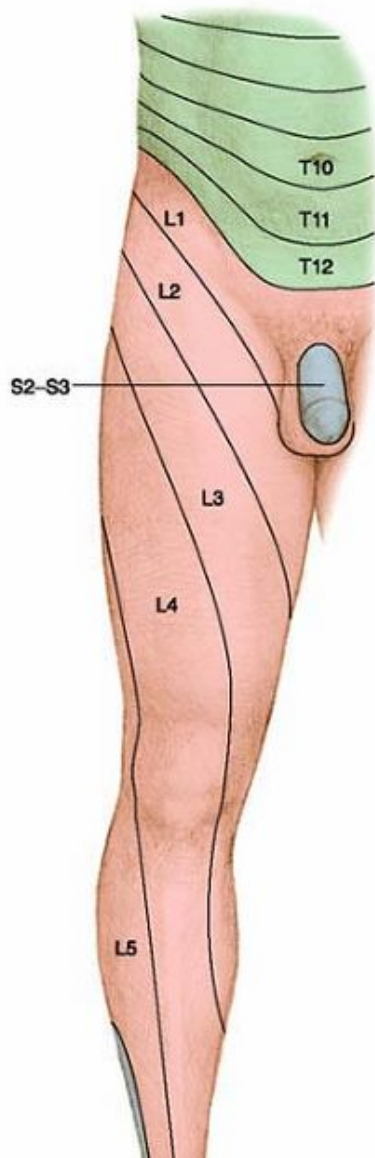


Plate 3-68 Cutaneous Innervation of the Lower Limb

A. Anterior view



B. Posterior view

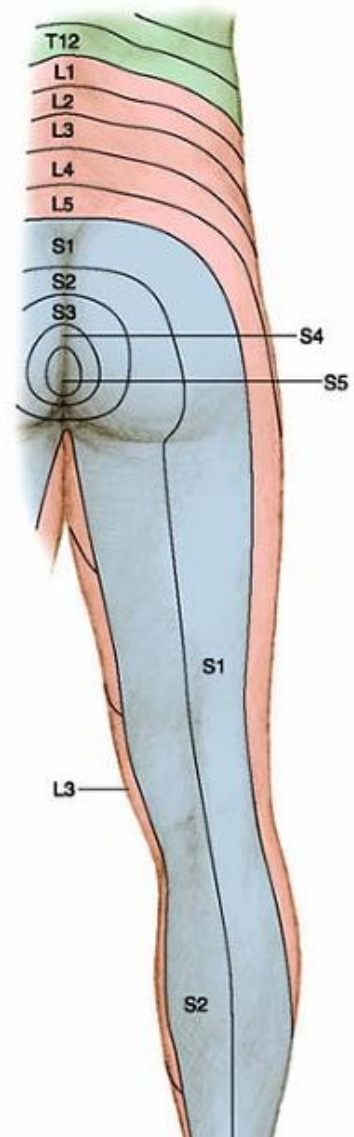
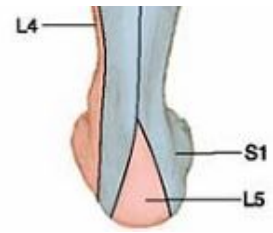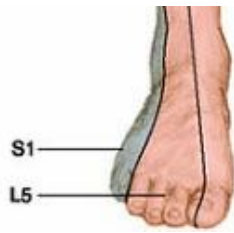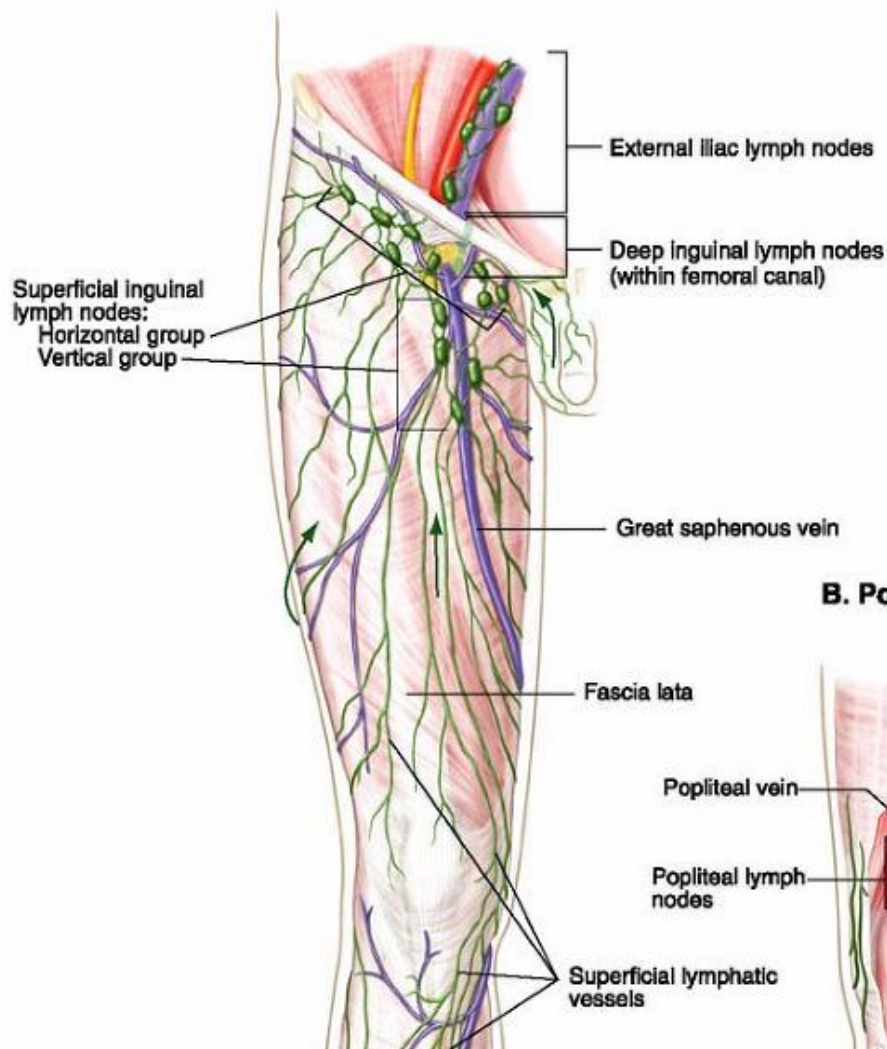


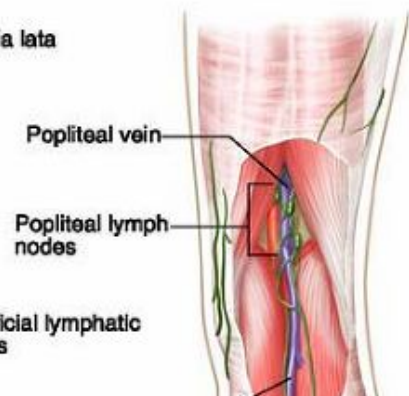


Plate 3-69 Dermatomes of the Lower Limb

A. Anterior view



B. Posterior view



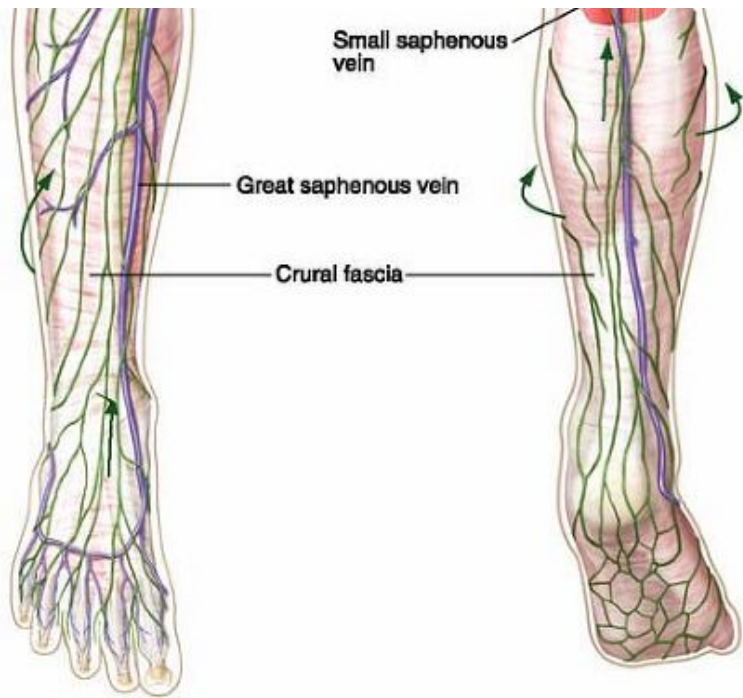


Plate 3-70 Lymphatics of the Lower Limb

Authors: Tank, Patrick W.; Gest, Thomas R.

Title: *Lippincott Williams & Wilkins Atlas of Anatomy, 1st Edition*

Copyright ©2009 Lippincott Williams & Wilkins

> Table of Contents > Chapter 4 - The Thorax

Chapter 4


The Thorax

P.159

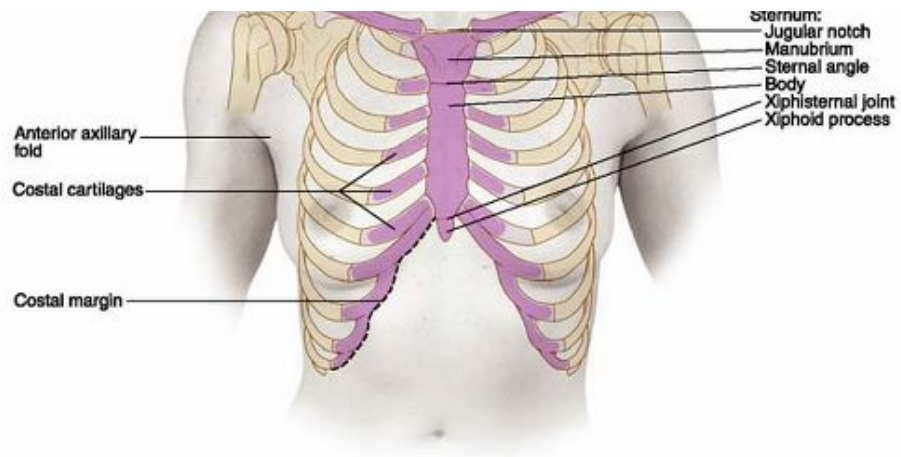
P.160

A. Anterior view

Clavicle

 Palpable bony structures





B. Landmarks, anterior view

C. Landmarks, lateral view

D. Landmarks, posterior view

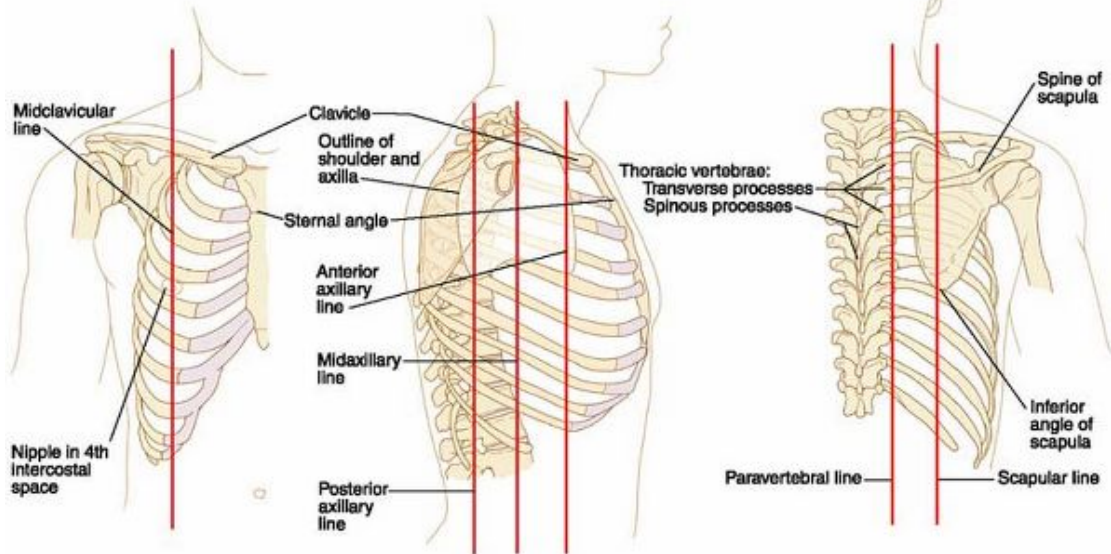
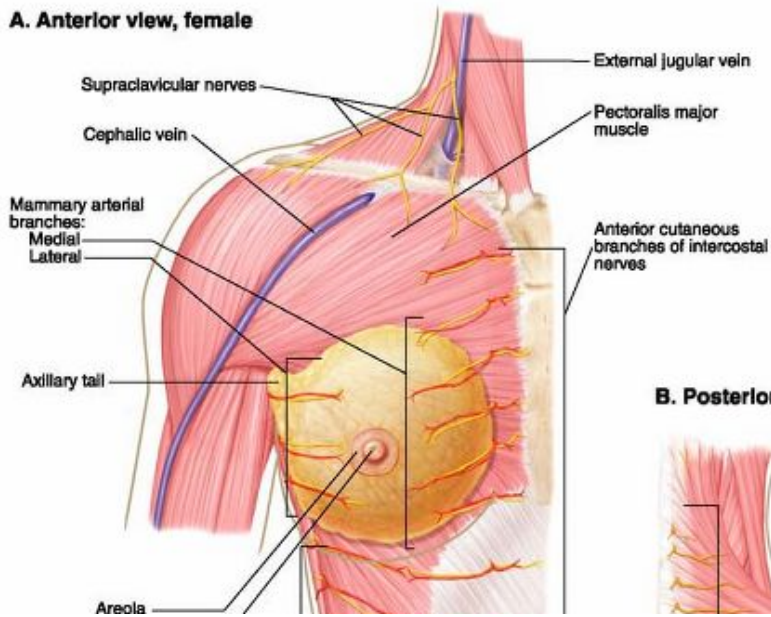
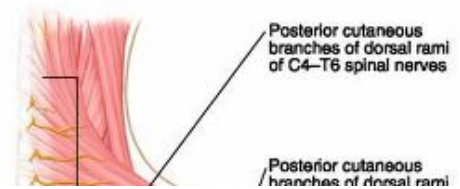


Plate 4-01 Palpable Features and Landmarks of the Thorax

A. Anterior view, female



B. Posterior view



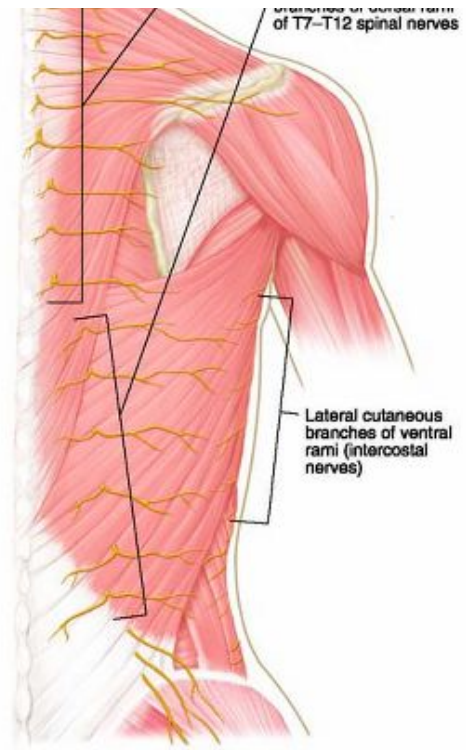
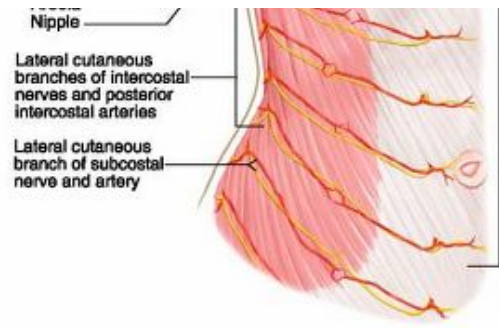
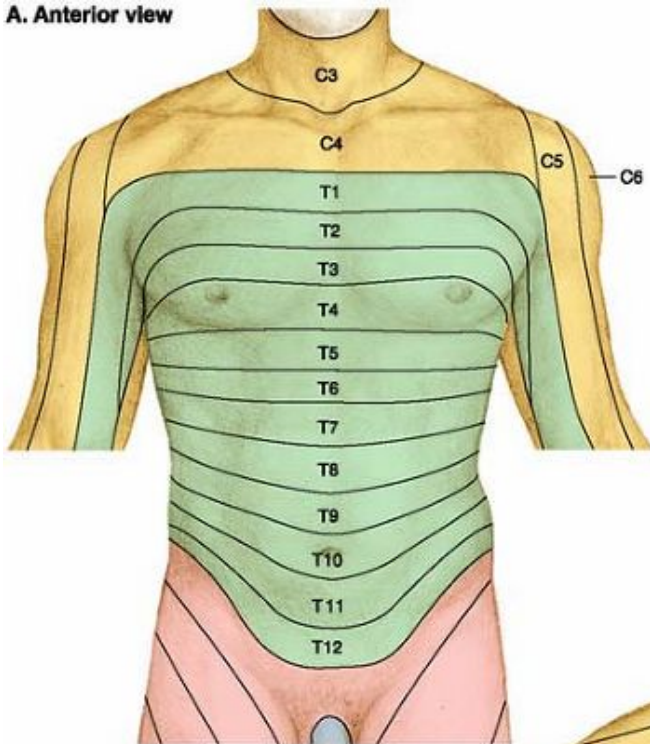
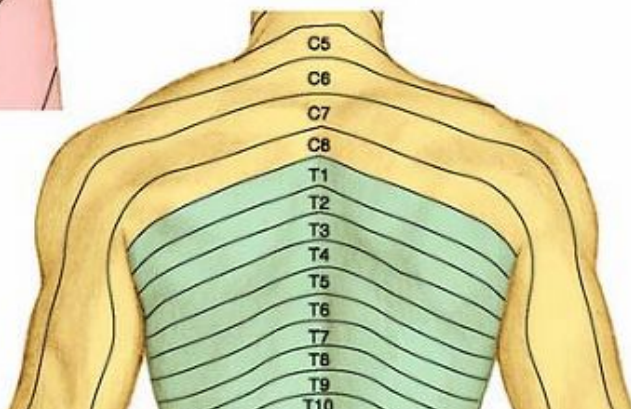


Plate 4-02 Cutaneous Nerves and Superficial Vessels of the Thorax

A. Anterior view



B. Posterior view



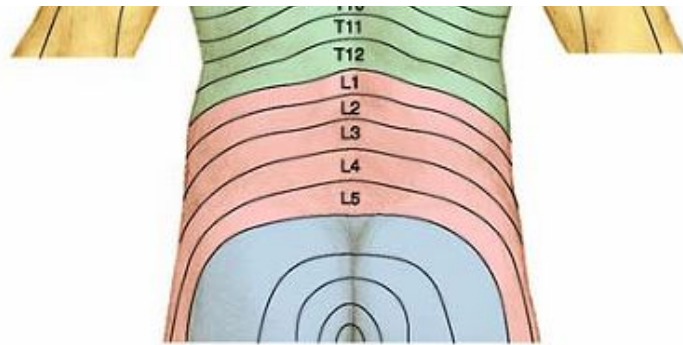
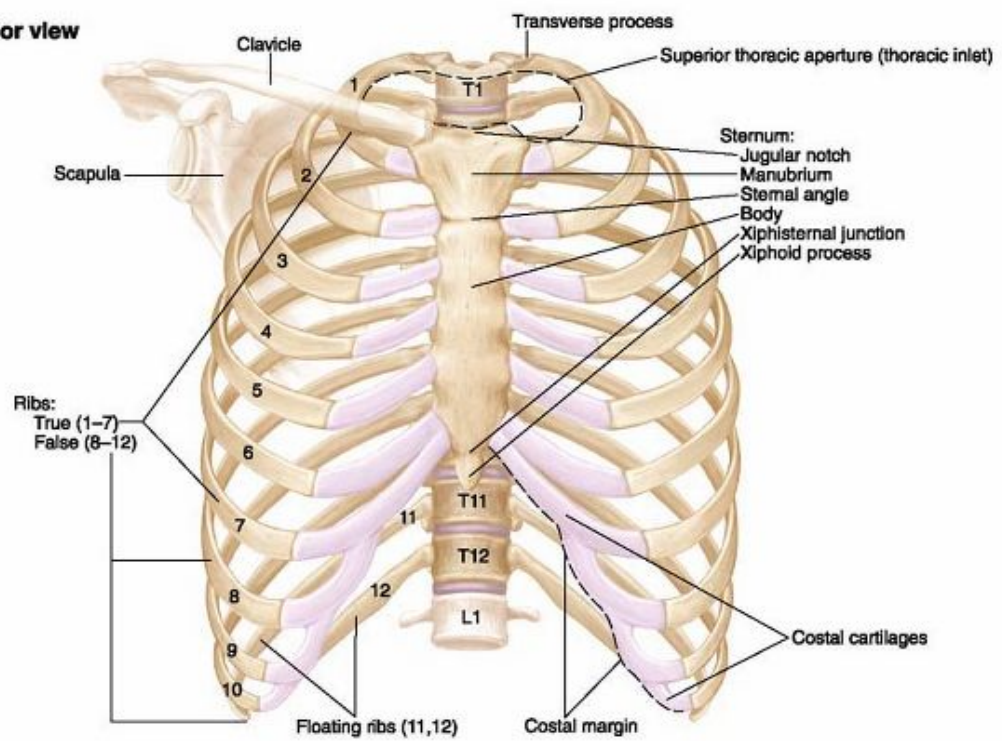
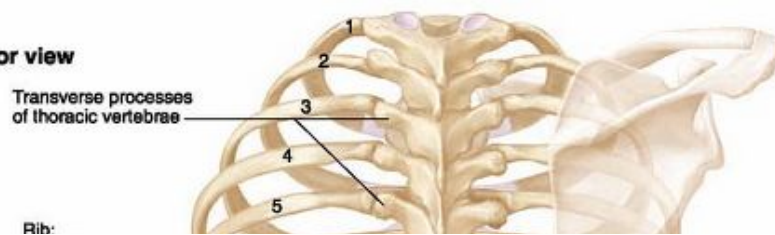


Plate 4-03 Dermatomes of the Thorax

A. Anterior view



B. Posterior view



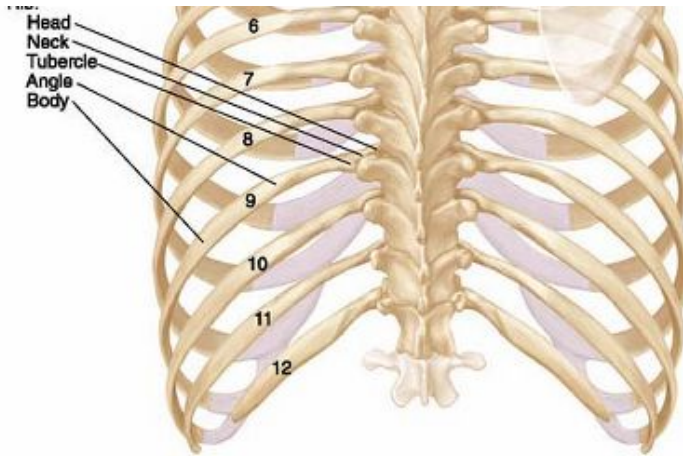
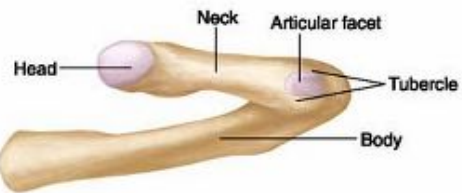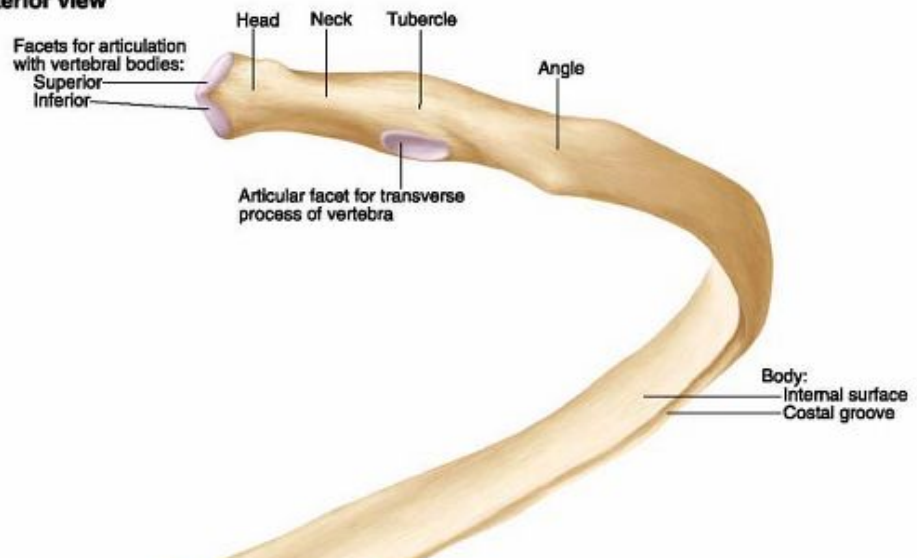


Plate 4-04 Skeleton of the Thoracic Wall

A. First rib, posterior view



B. Sixth rib, posterior view



Site of articulation
with costal cartilage



C. Twelfth rib, posterior view

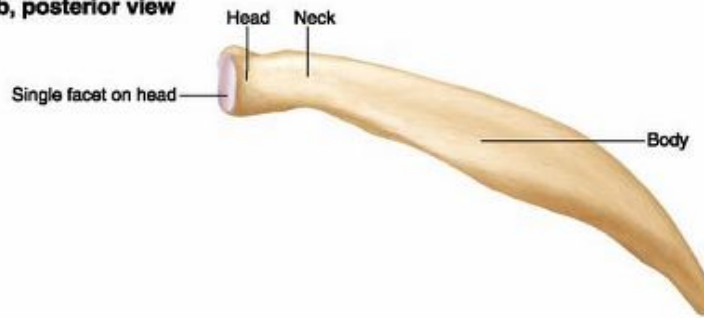
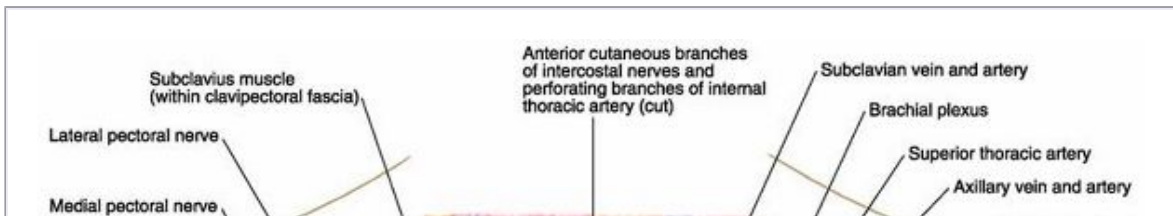
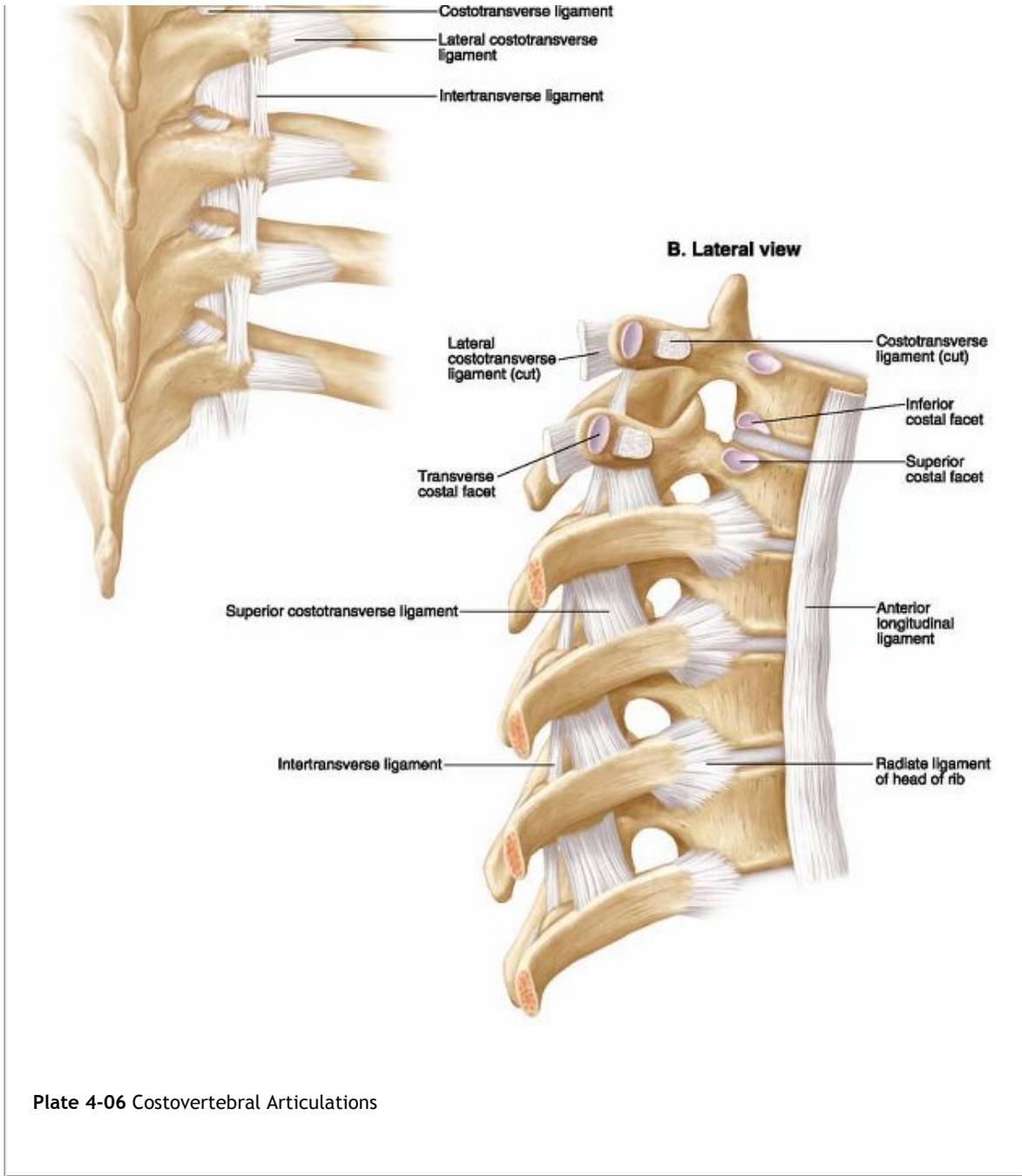
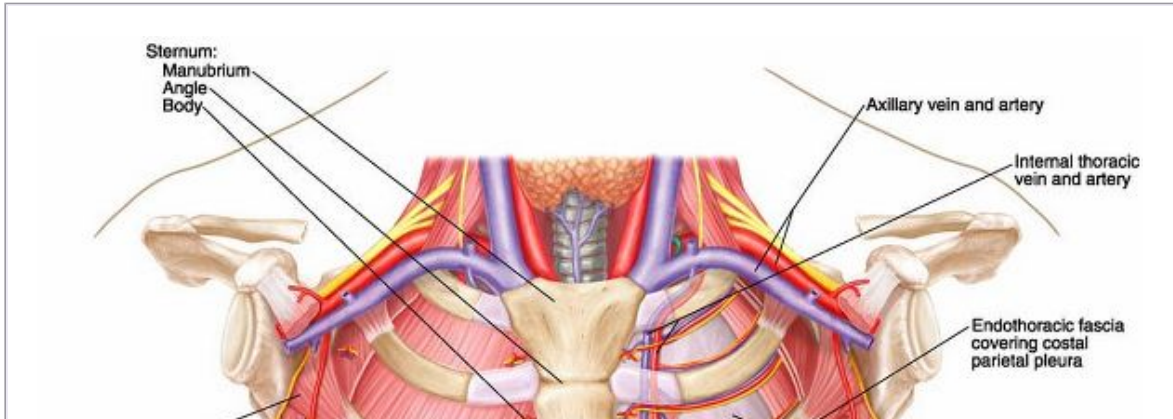
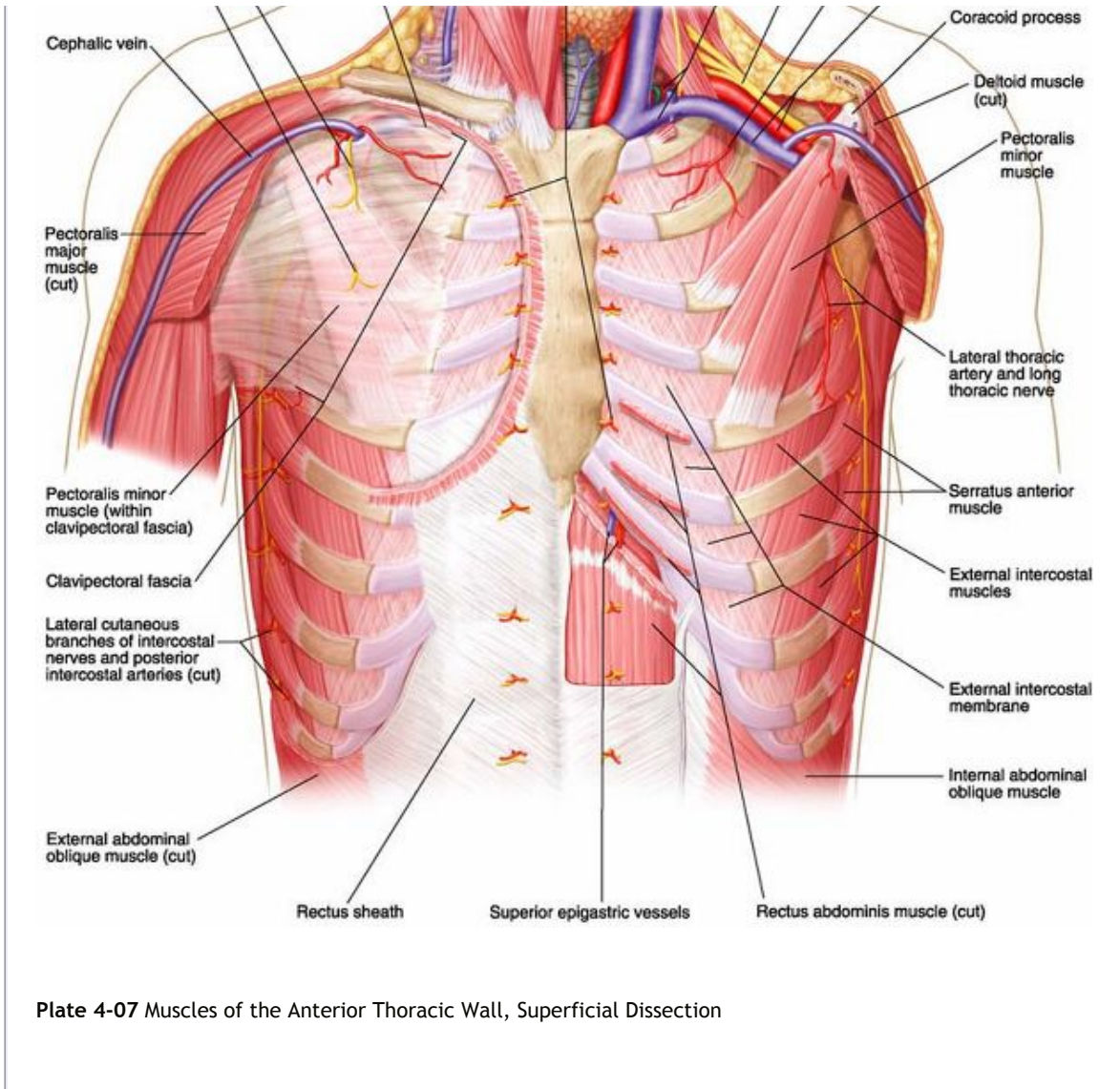


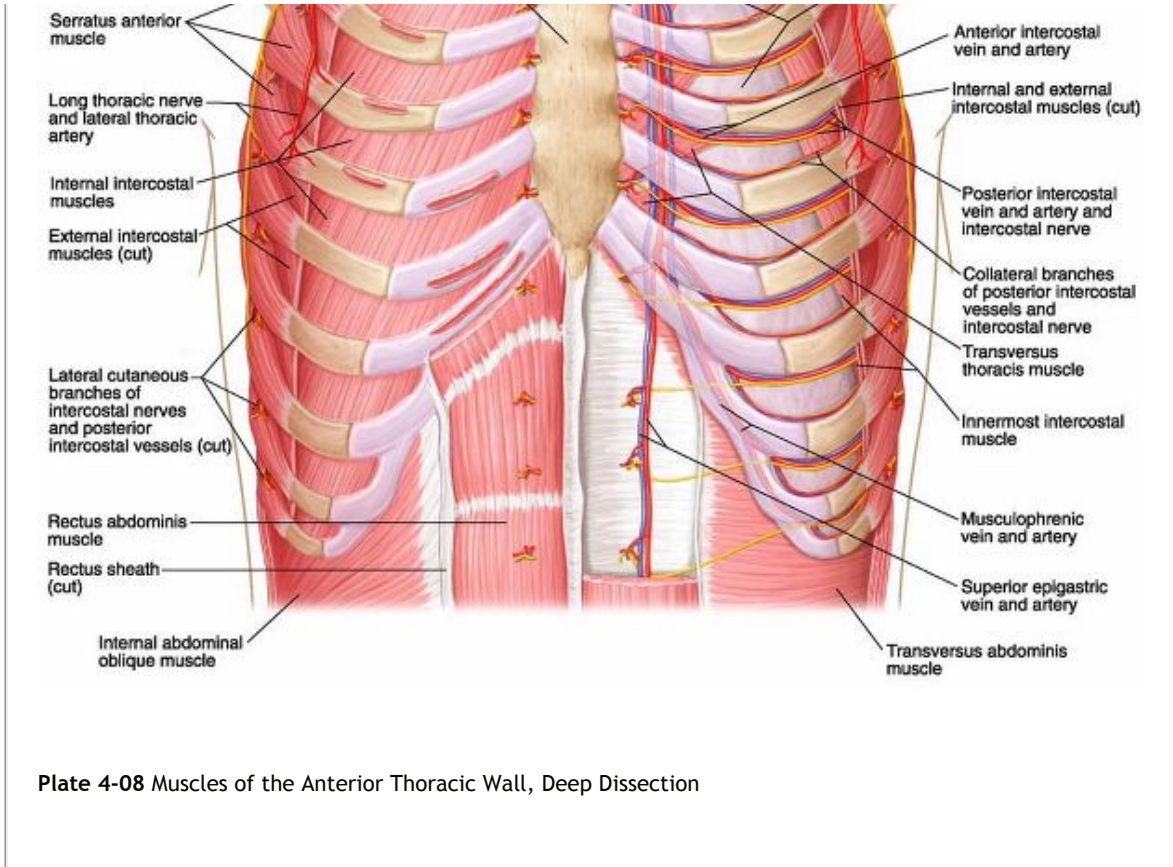
Plate 4-05 Ribs

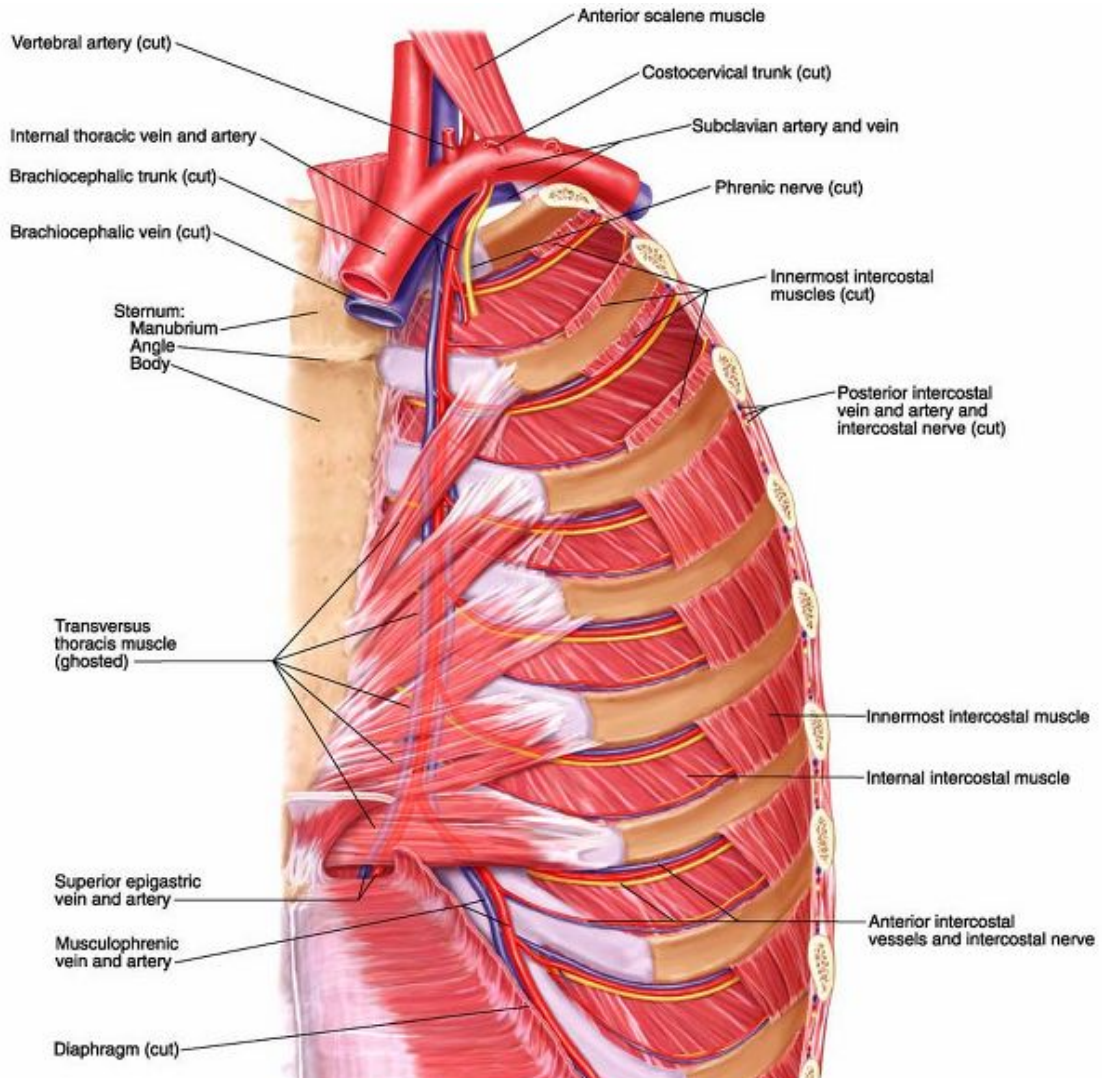
A. Posterior view











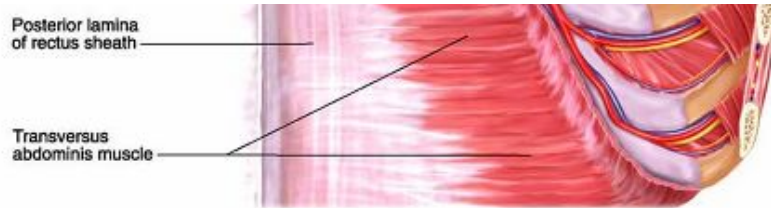


Plate 4-09 Muscles of the Anterior Thoracic Wall, Internal View with Pleura Removed

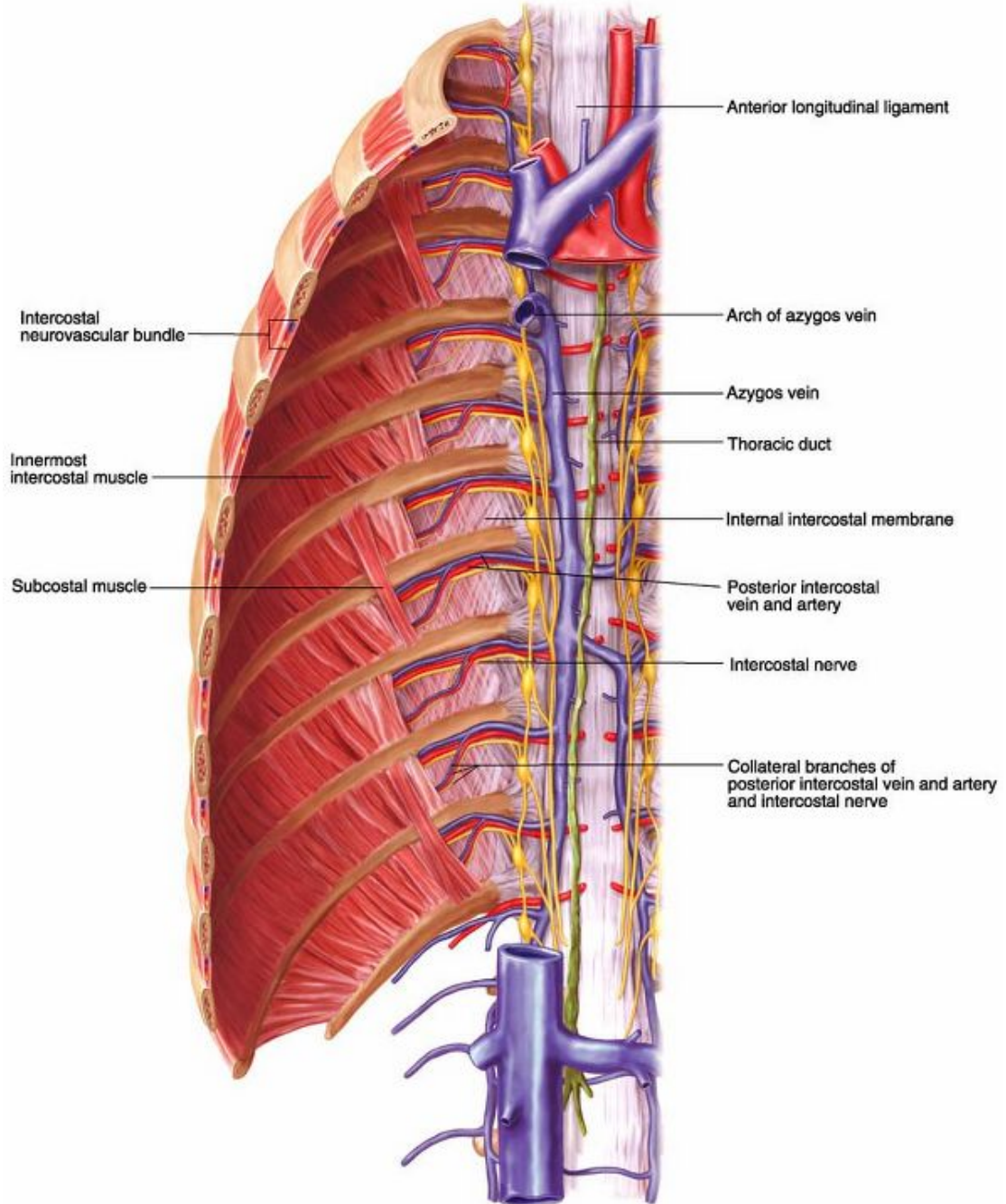
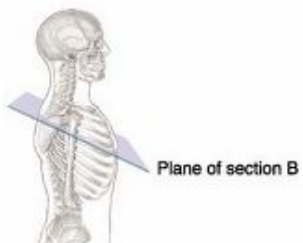


Plate 4-10 Muscles of the Posterior Thoracic Wall, Internal View with Pleura Removed

A. Orientation



B. Oblique section through 4th intercostal space

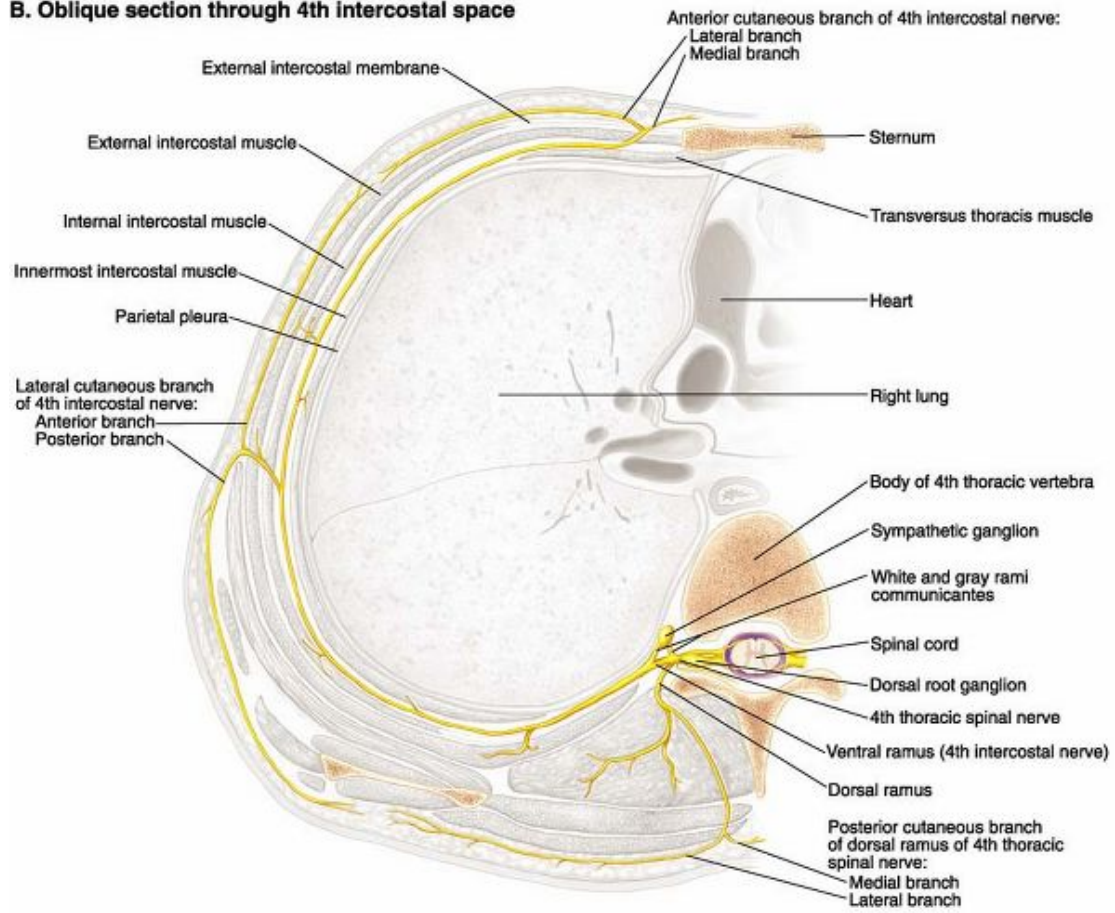
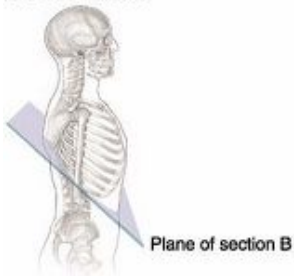
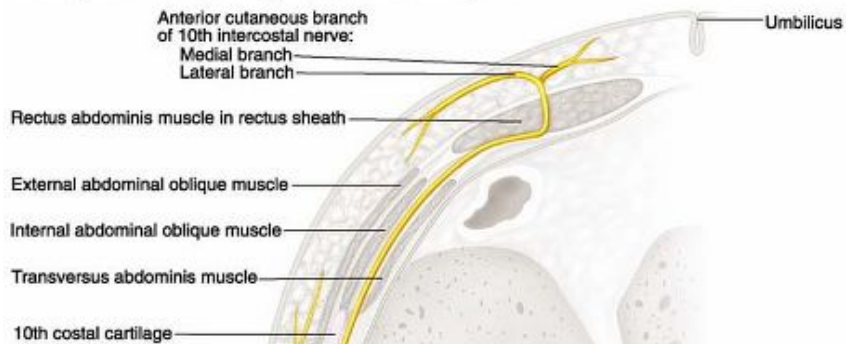


Plate 4-11 Pattern of the 4th Intercostal Nerve

A. Orientation



B. Oblique section through 10th intercostal space



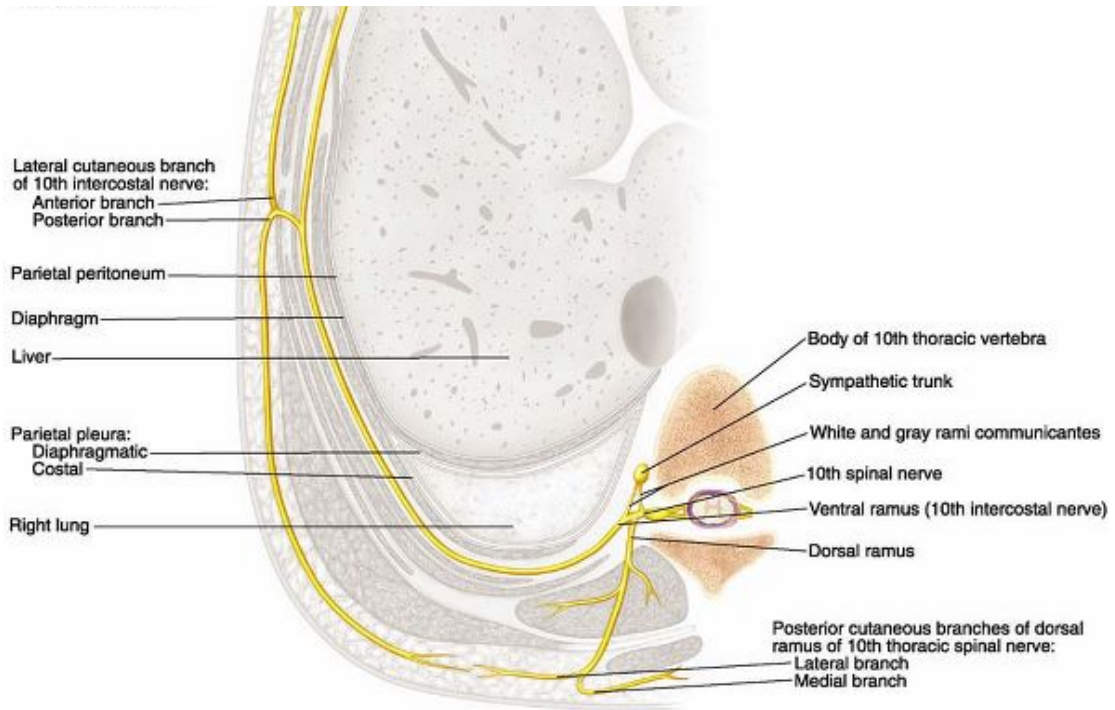
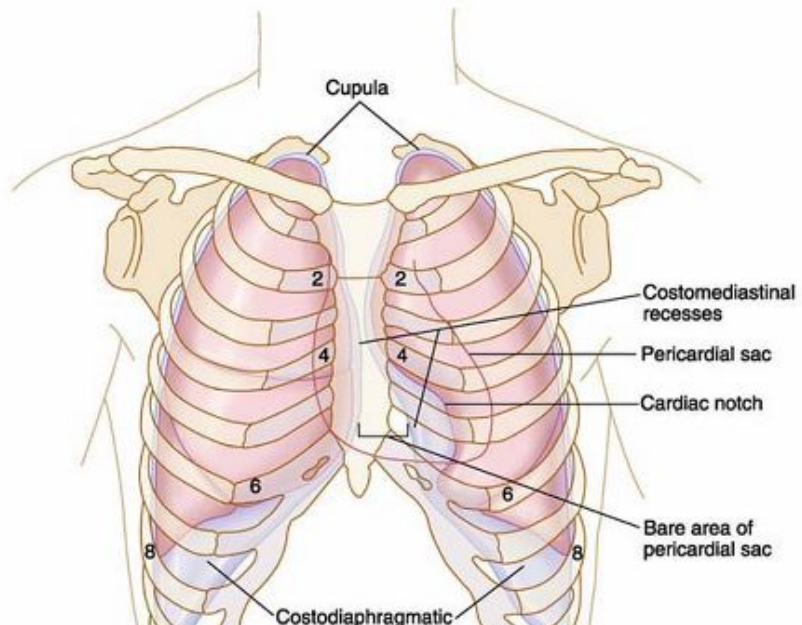


Plate 4-12 Pattern of the 10th Intercostal Nerve

A. Anterior view



10 recesses 10

B. Posterior view

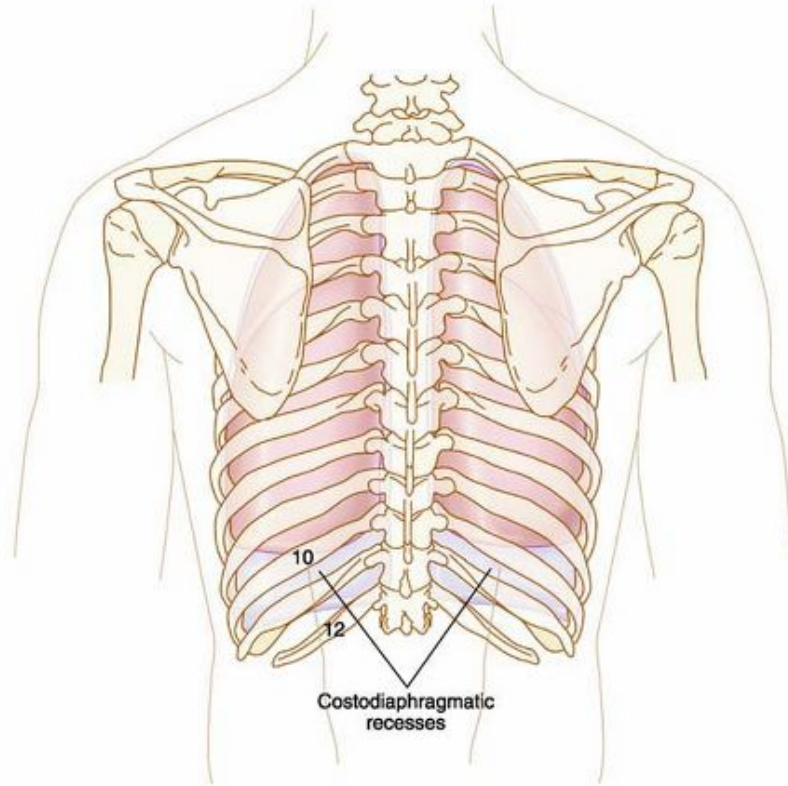
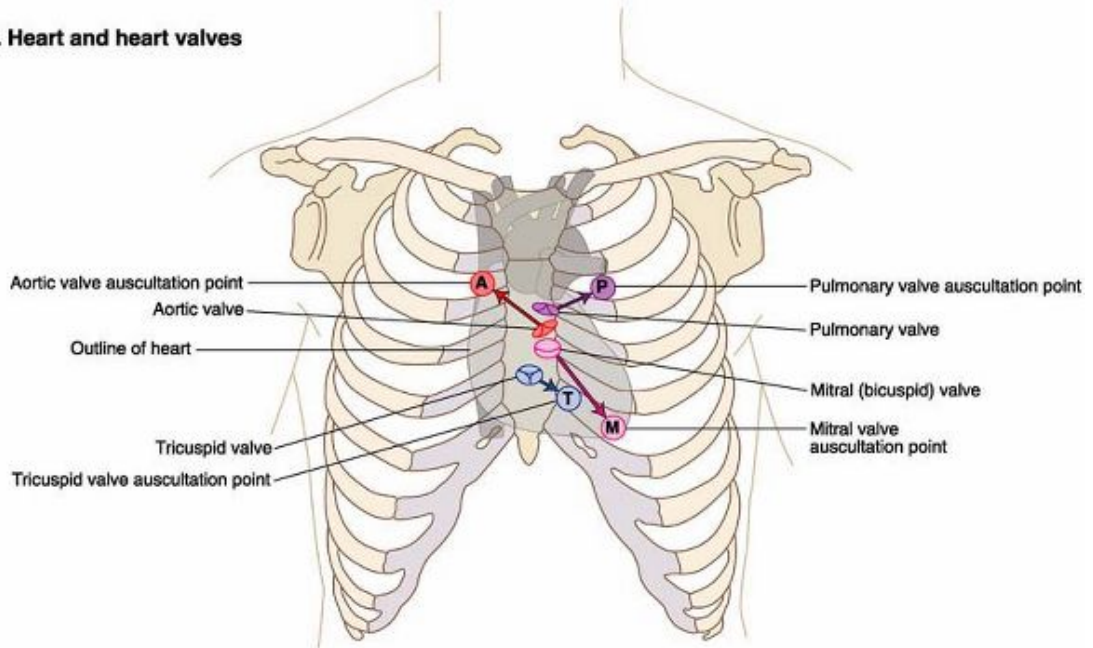
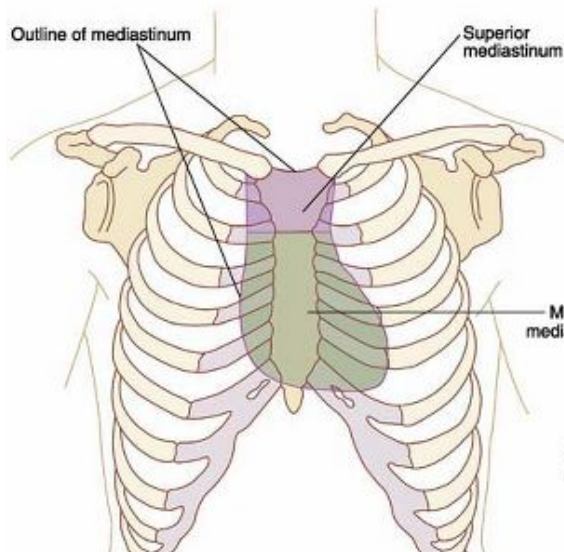


Plate 4-13 Surface Projection of the Lungs and Pleurae

A. Heart and heart valves



B. Mediastinum, anterior view



C. Mediastinum, right lateral view

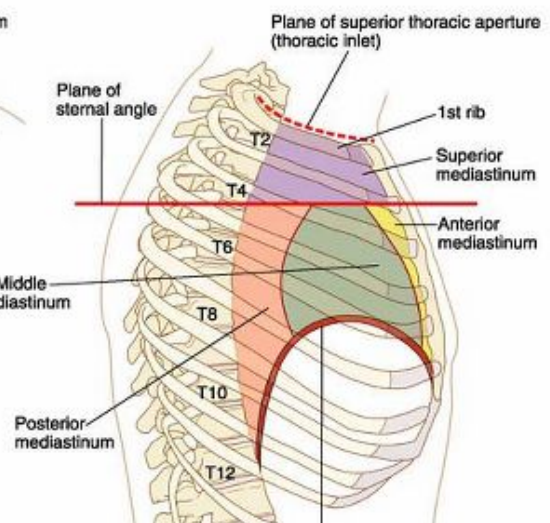




Plate 4-14 Surface Projection of the Heart and Mediastinum

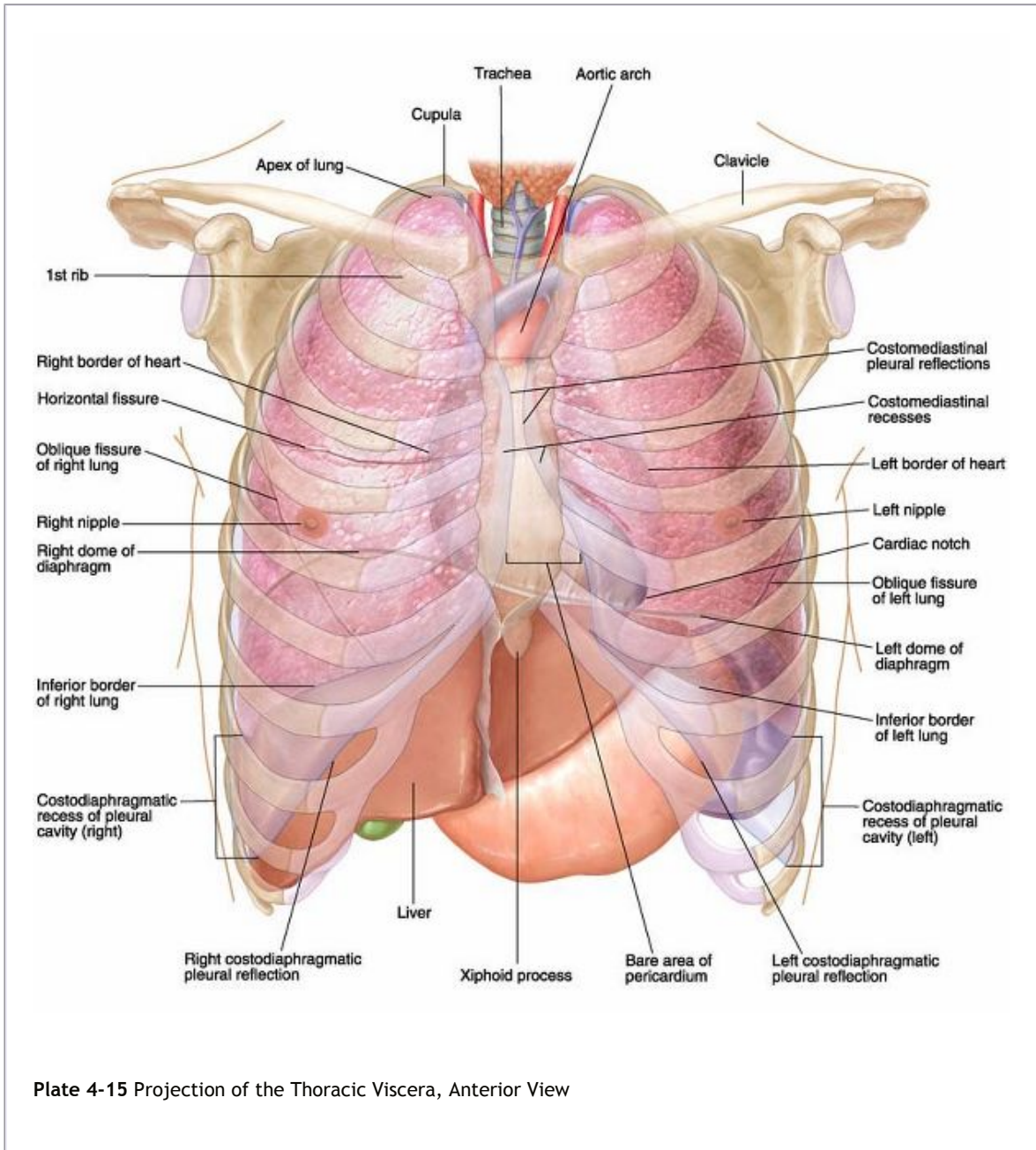

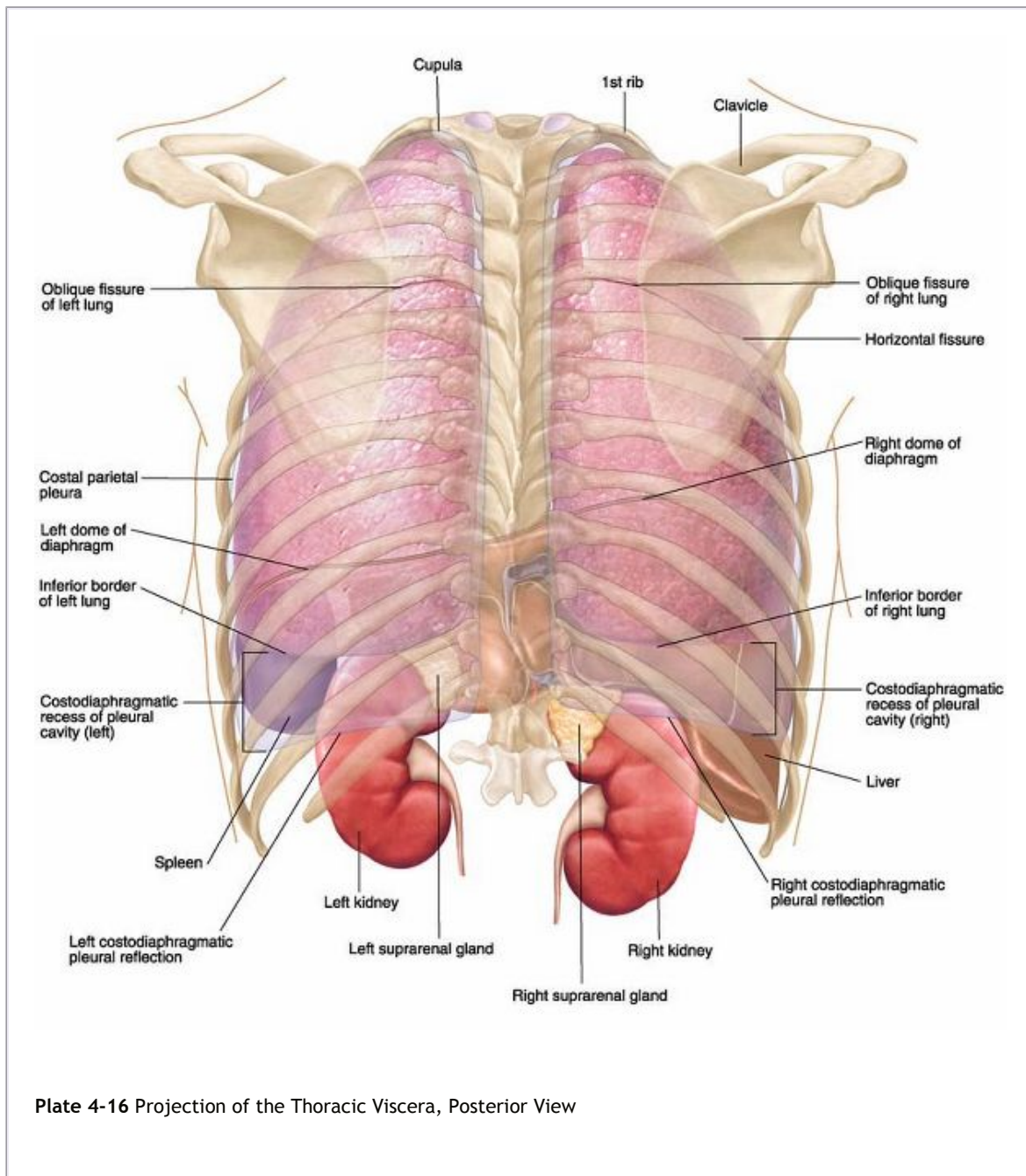


Plate 4-15 Projection of the Thoracic Viscera, Anterior View



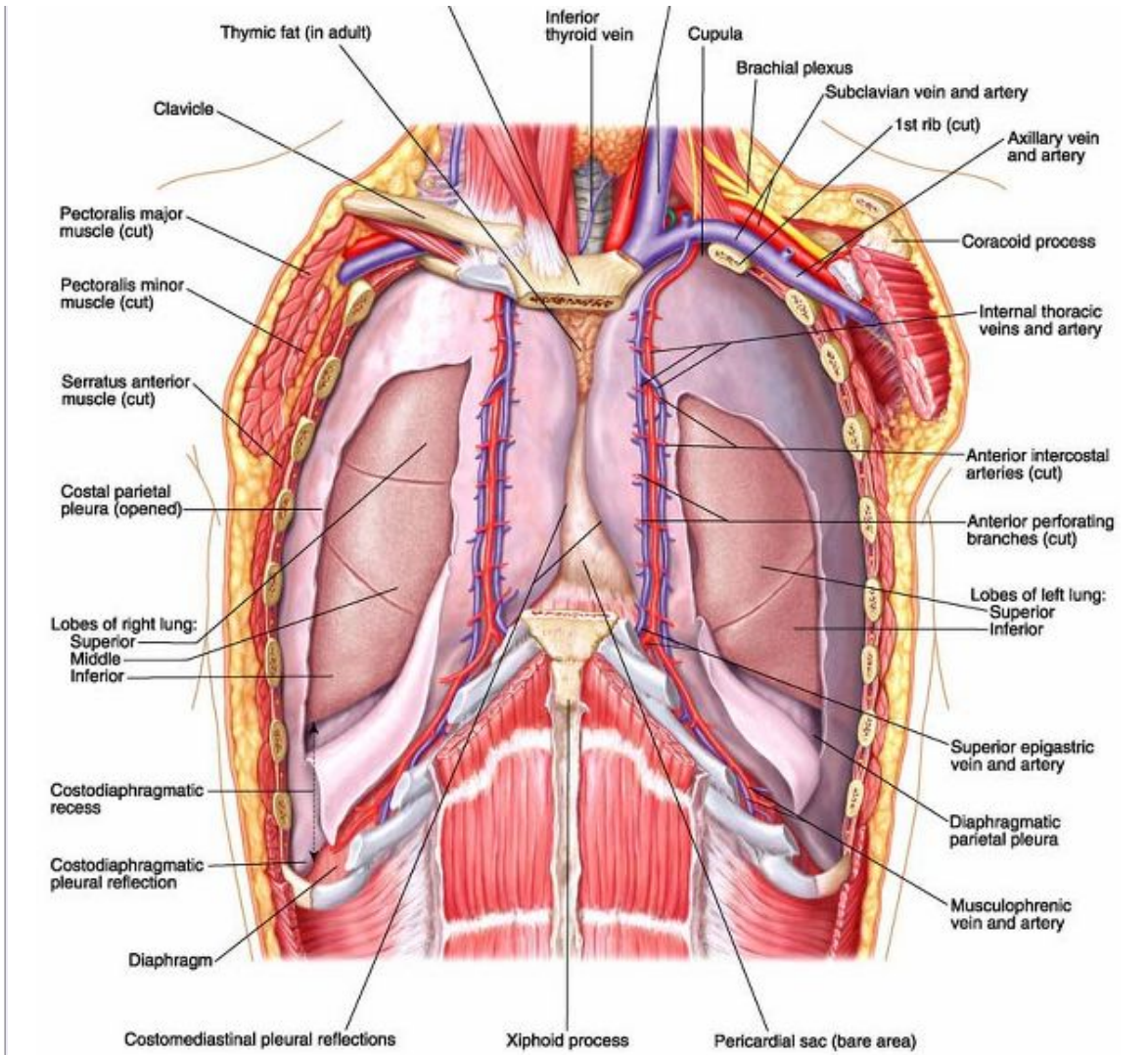
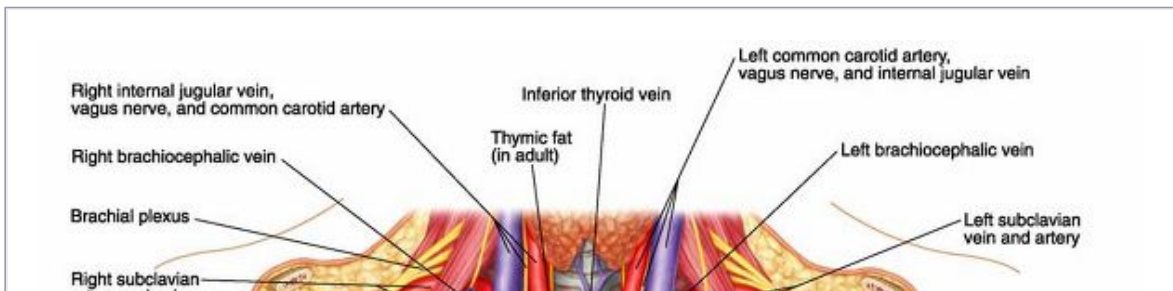
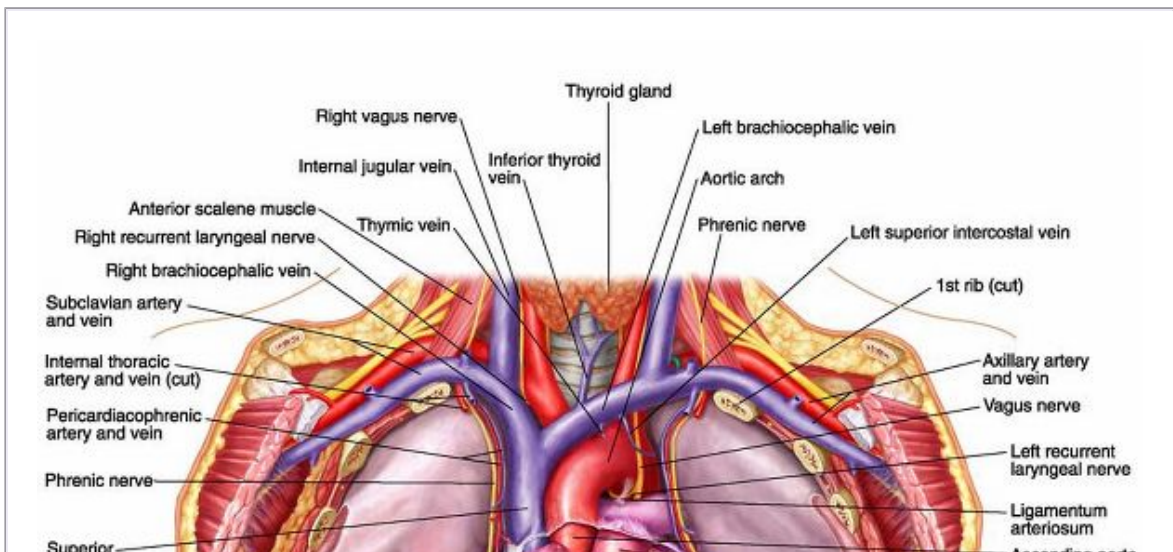
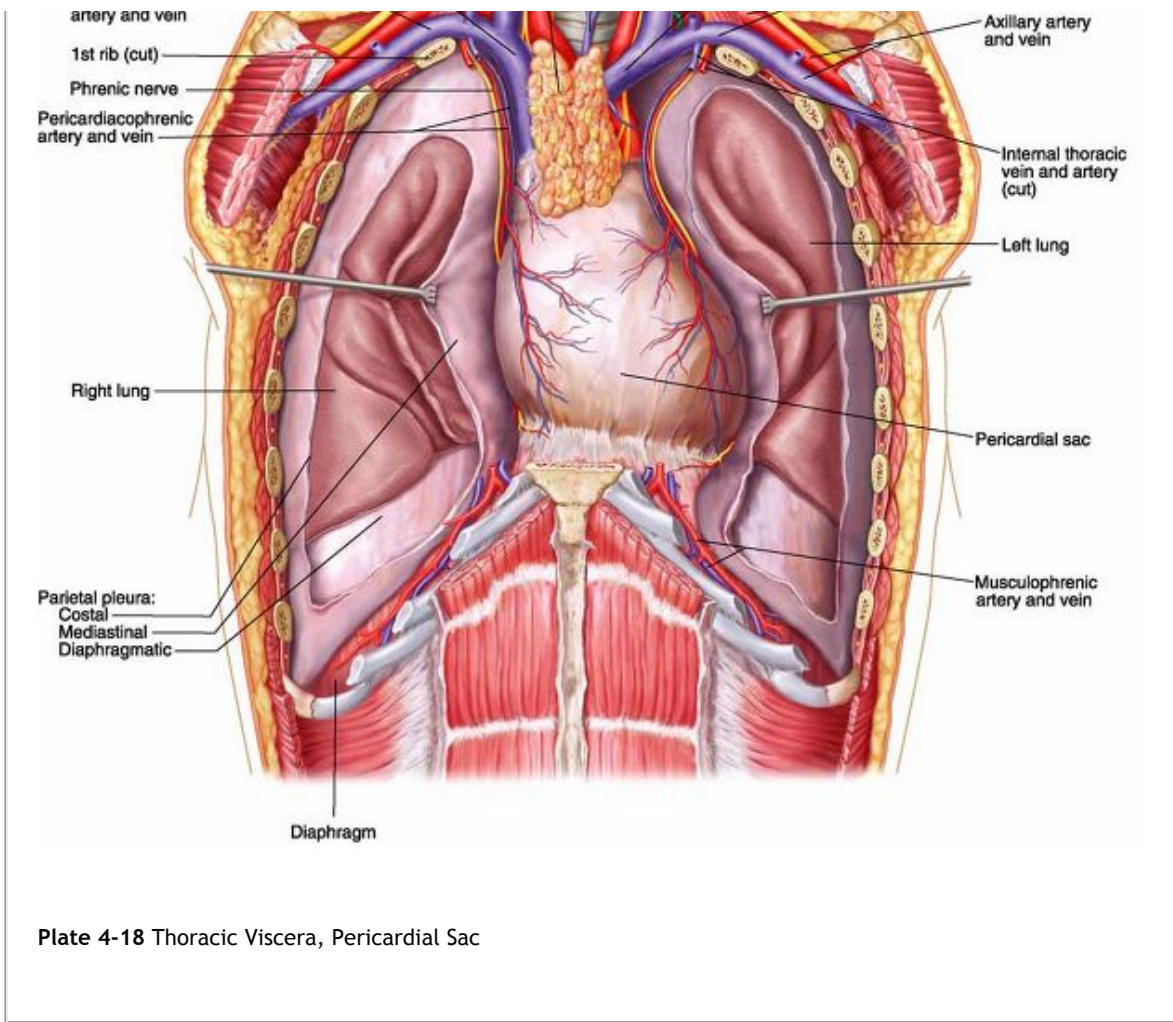
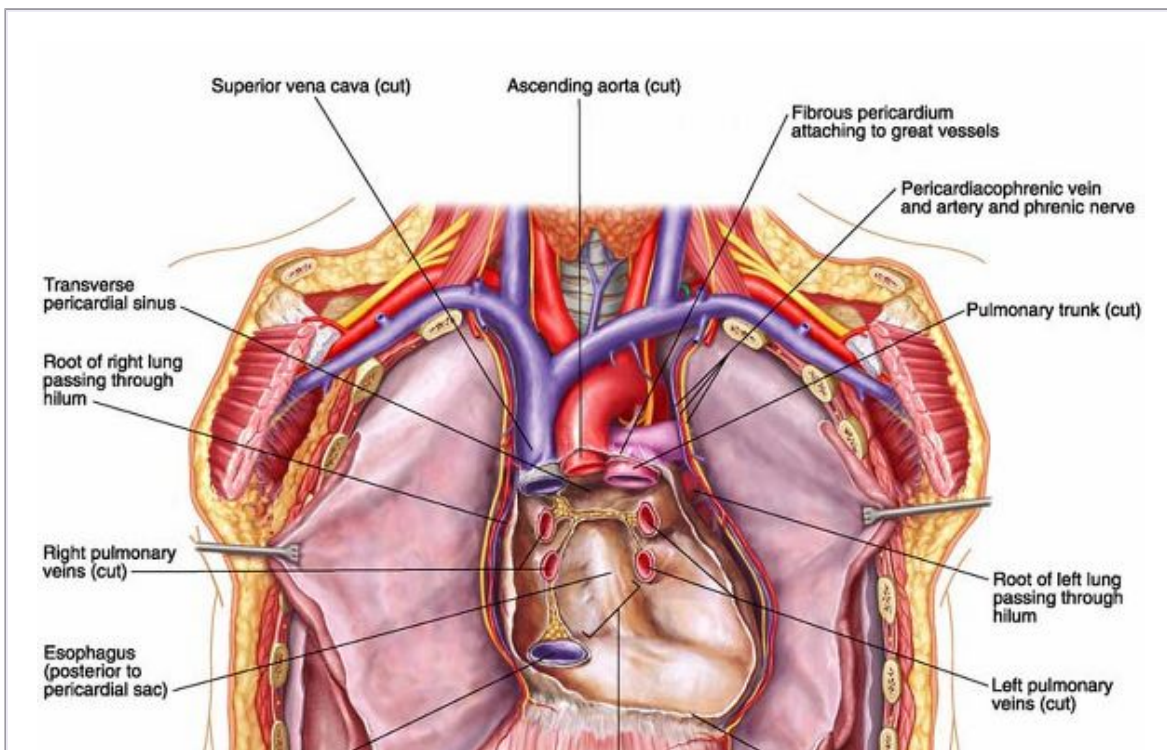
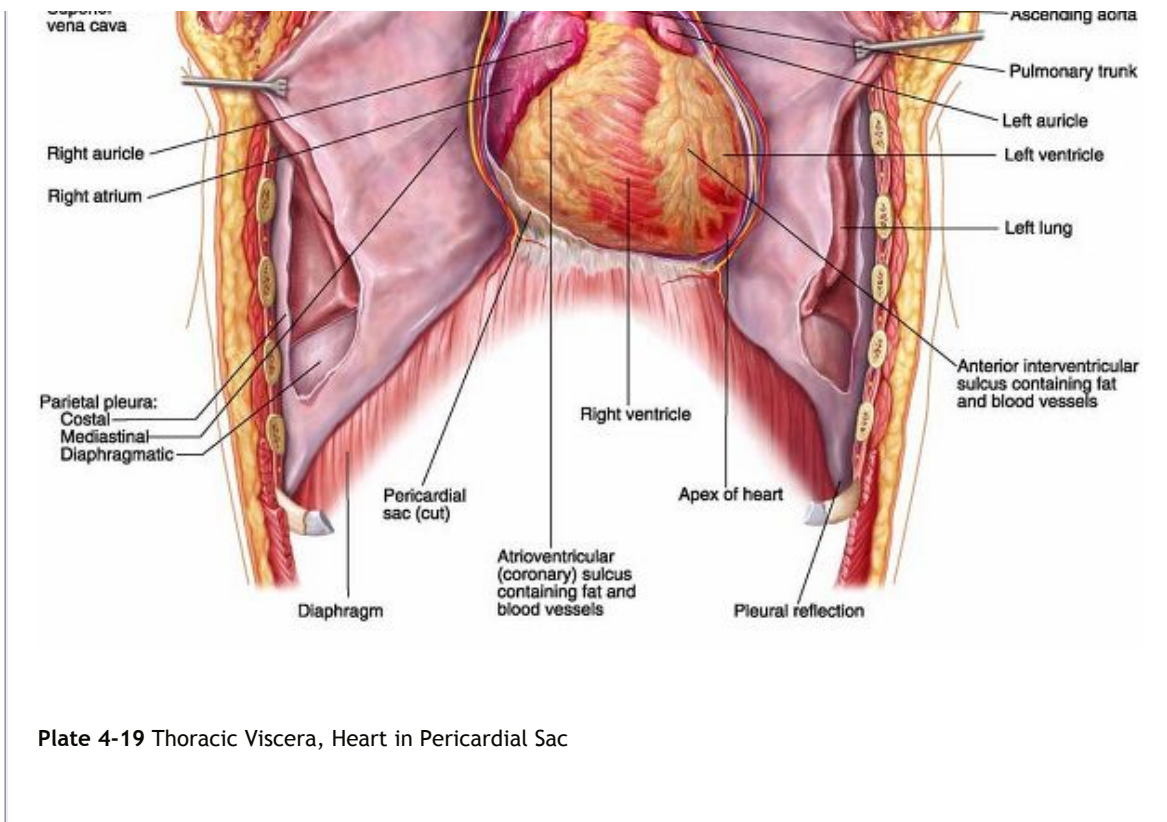


Plate 4-17 Thoracic Viscera, Pleural Cavities







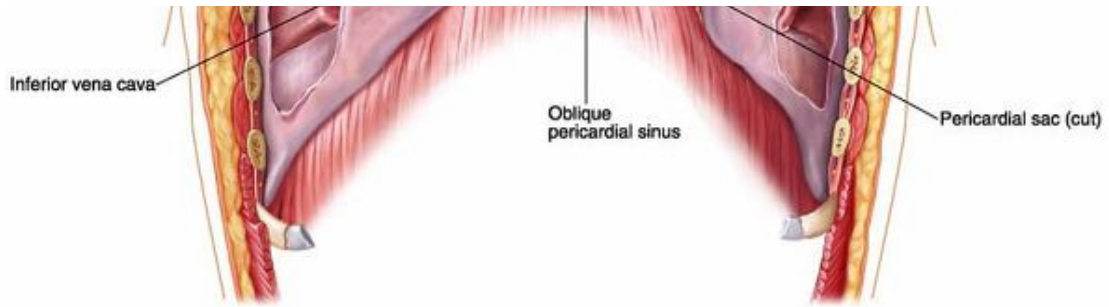
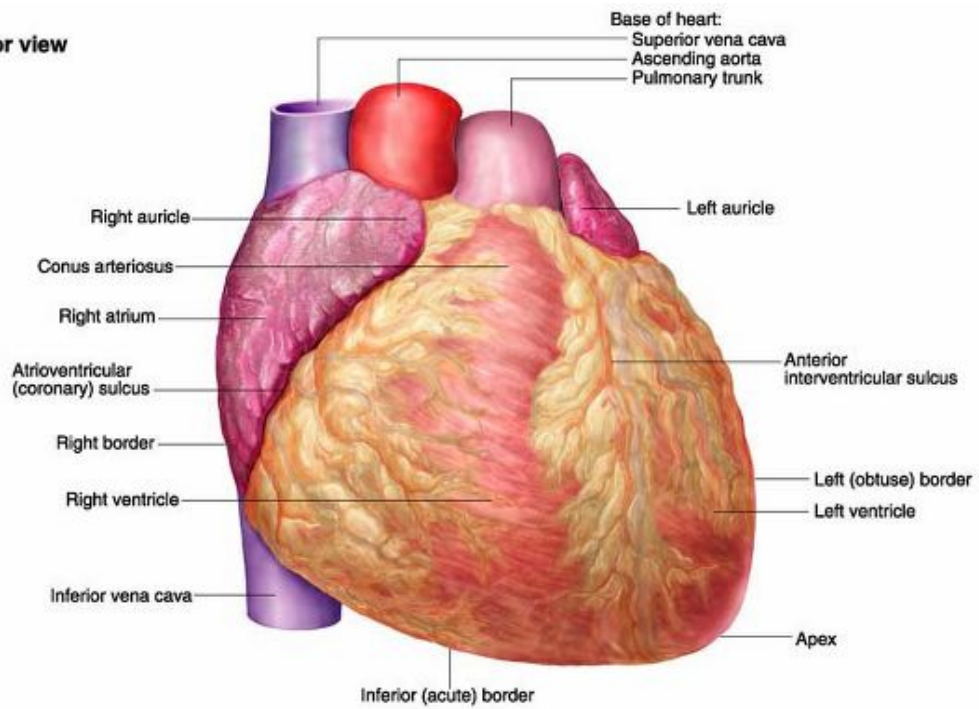
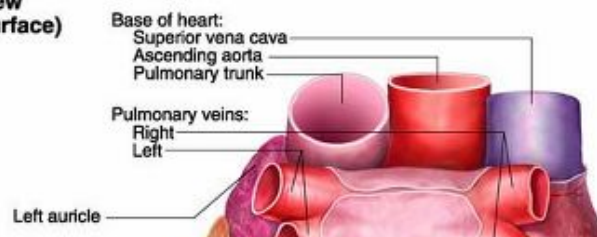


Plate 4-20 Thoracic Viscera with Heart Removed

A. Anterior view



B. Posteroinferior view (diaphragmatic surface)



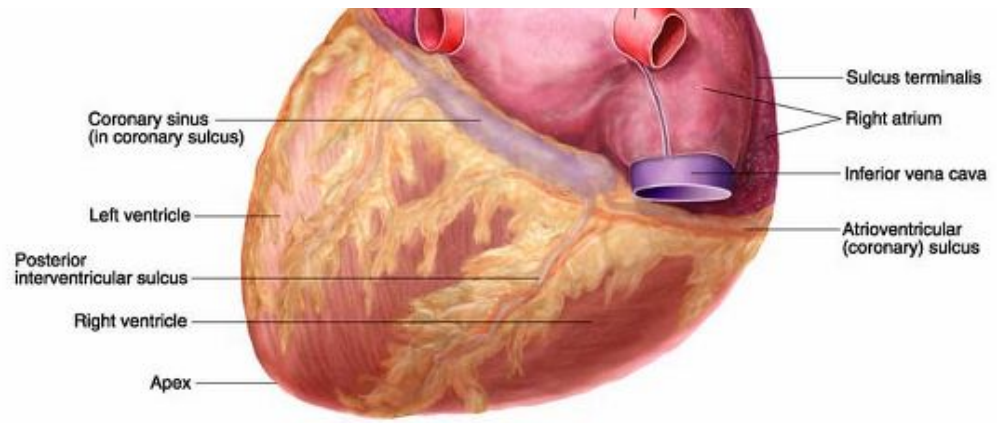
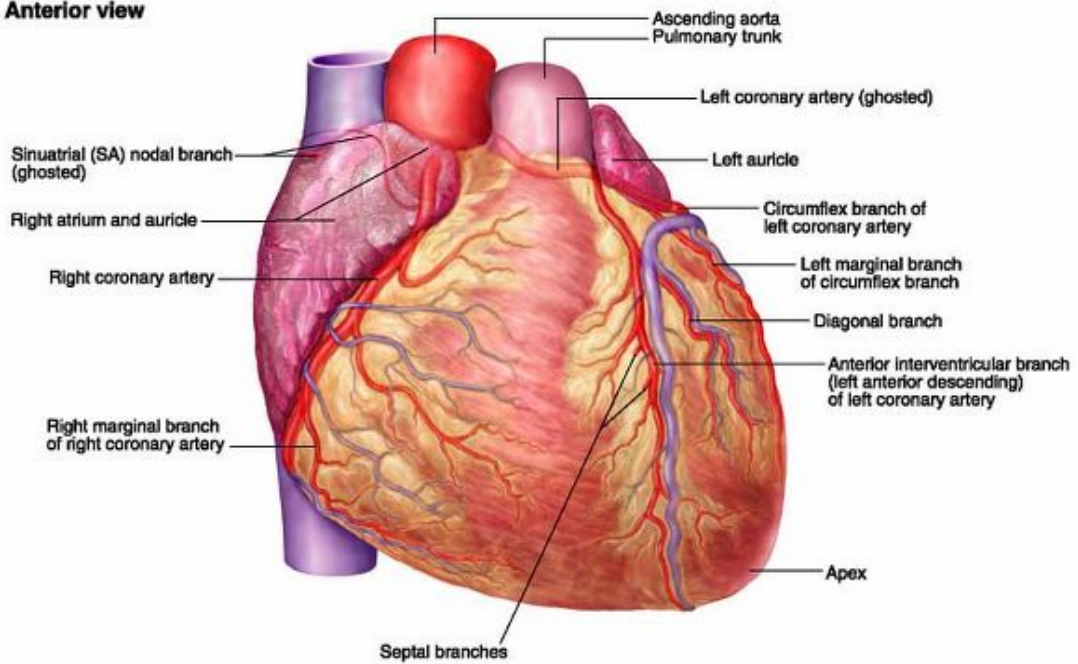


Plate 4-21 Heart, External Features

A. Anterior view



B. Posteroinferior view

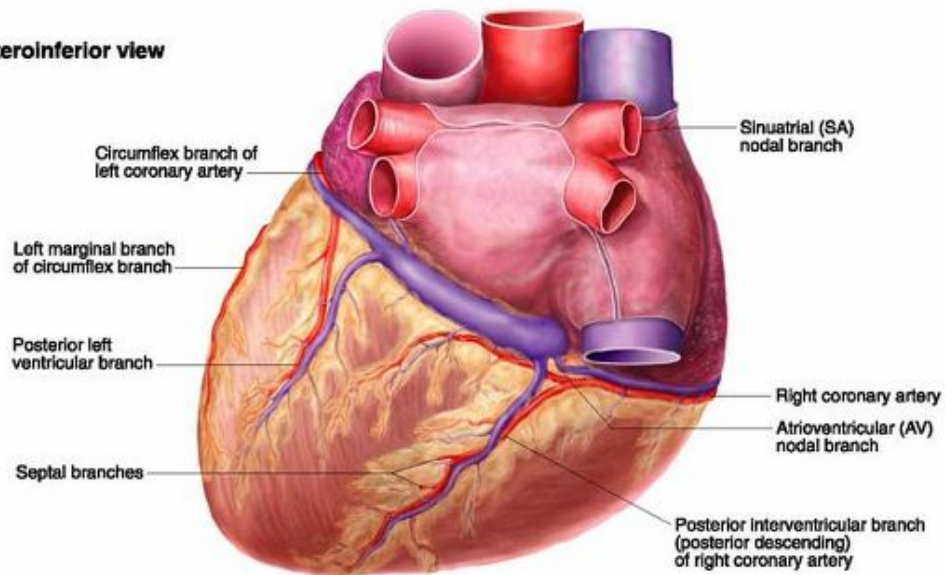
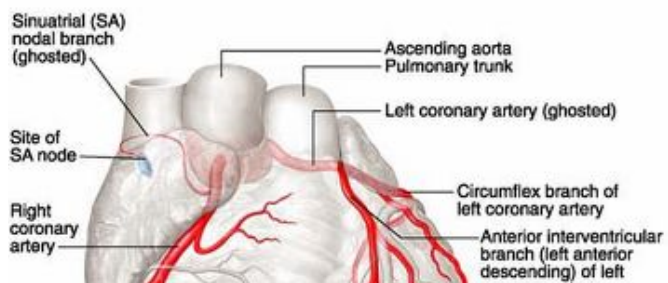
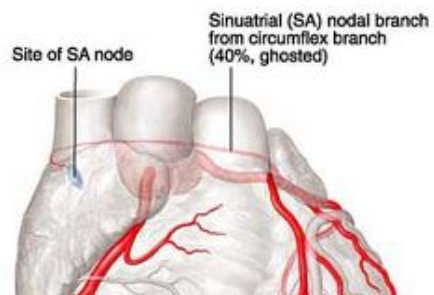


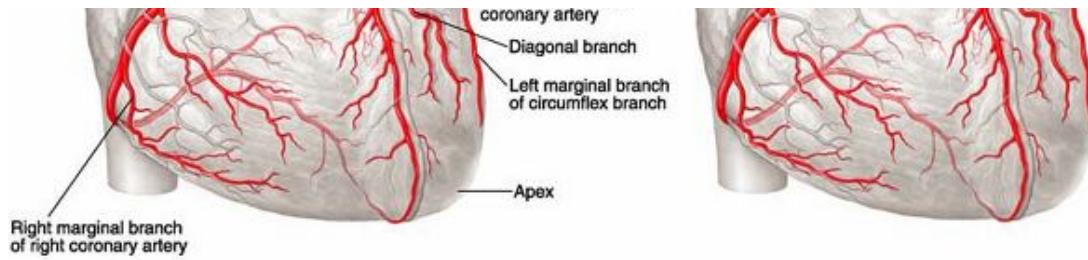
Plate 4-22 Coronary Arteries

A. Normal arterial pattern, anterior view

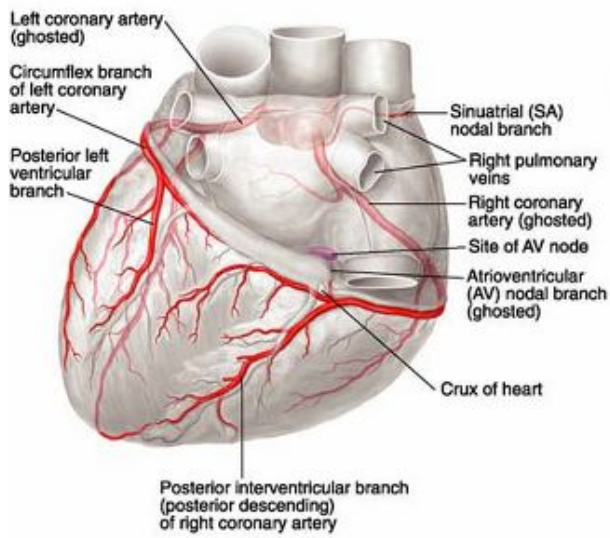


B. Variation, anterior view





C. Normal arterial pattern, posteroinferior view



D. Variation, posteroinferior view

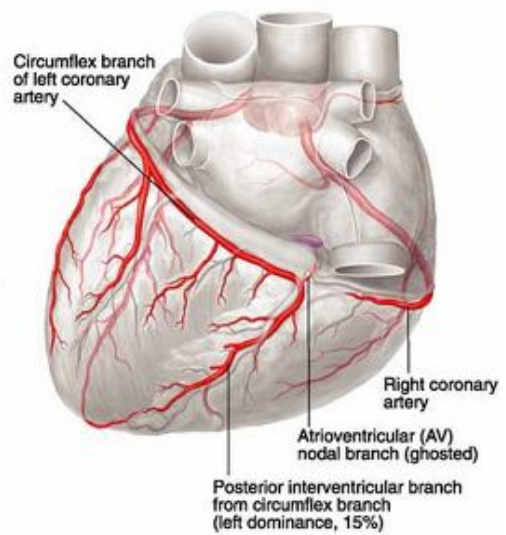
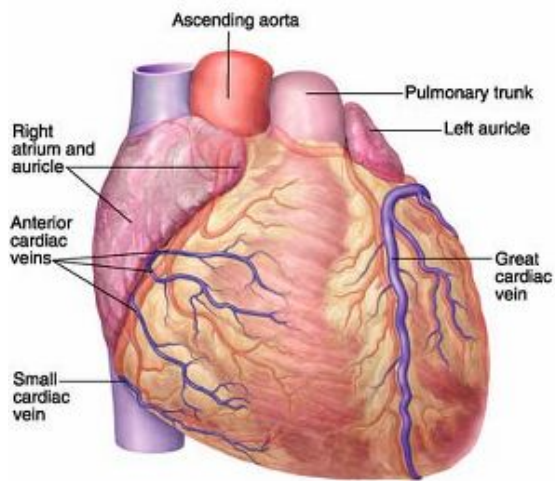
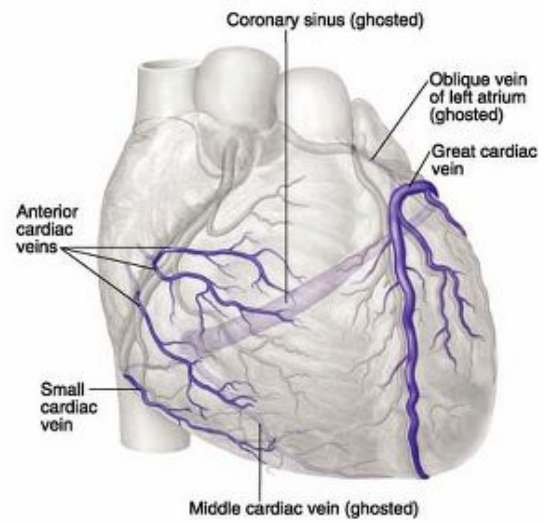


Plate 4-23 Coronary Arteries, Normal Patterns and Variations

A. Anterior view



B. Normal venous pattern, anterior view



C. Posteroinferior view

D. Normal venous pattern, posteroinferior view

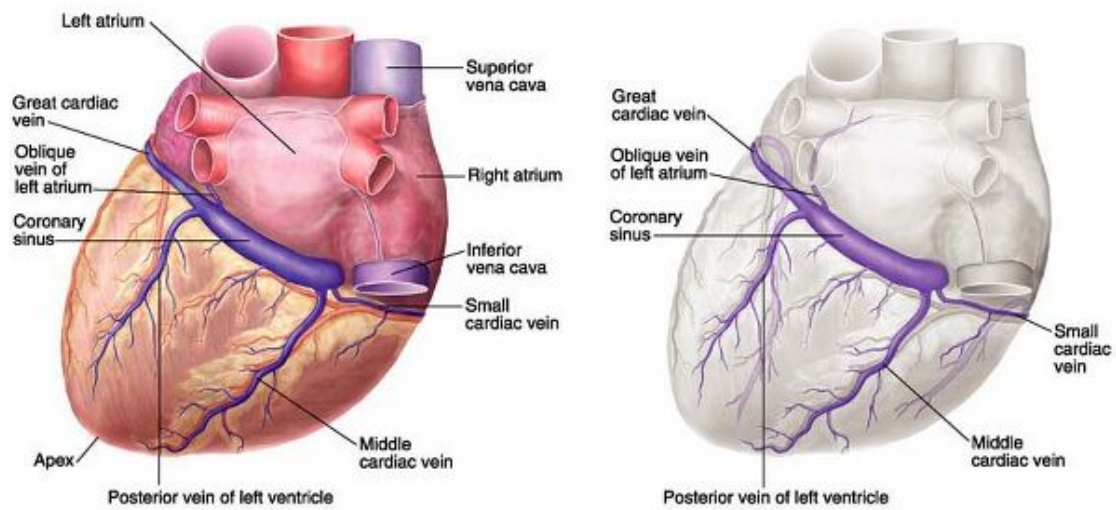
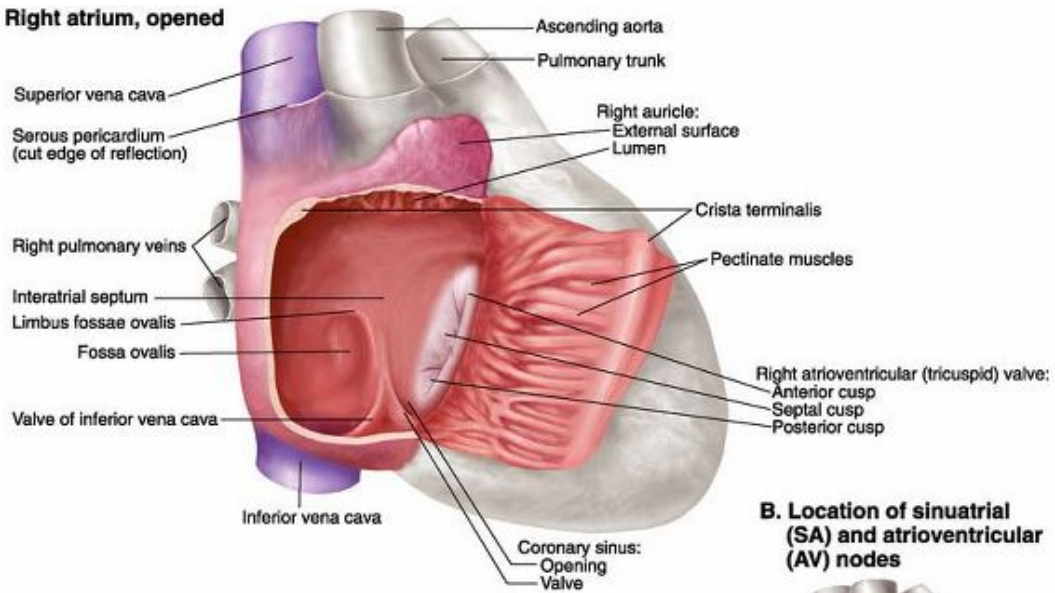
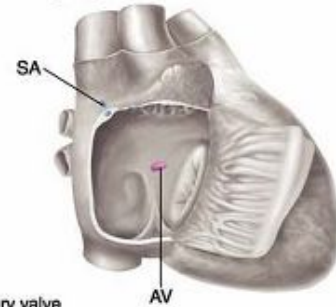


Plate 4-24 Cardiac Veins

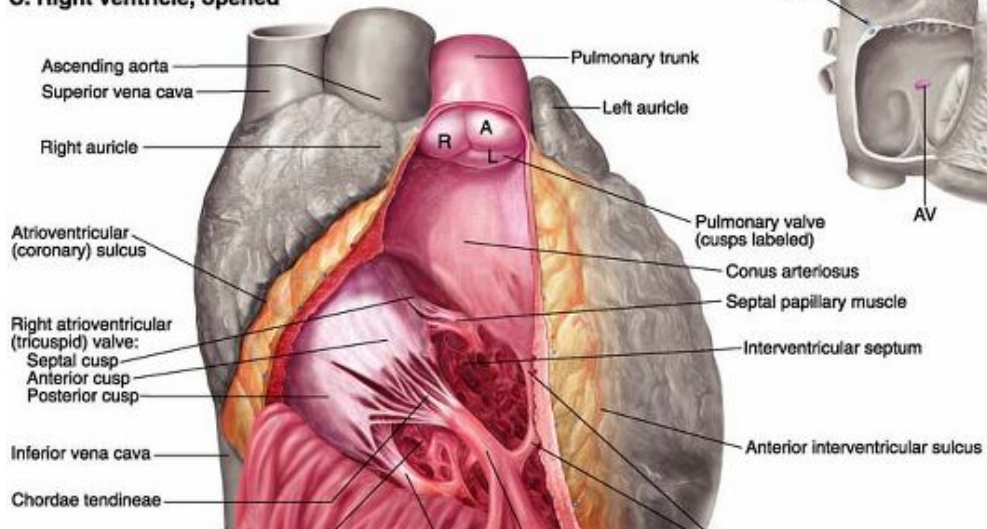
A. Right atrium, opened



B. Location of sinoatrial (SA) and atrioventricular (AV) nodes



C. Right ventricle, opened



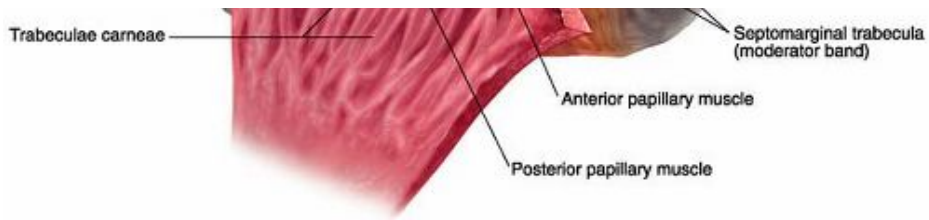
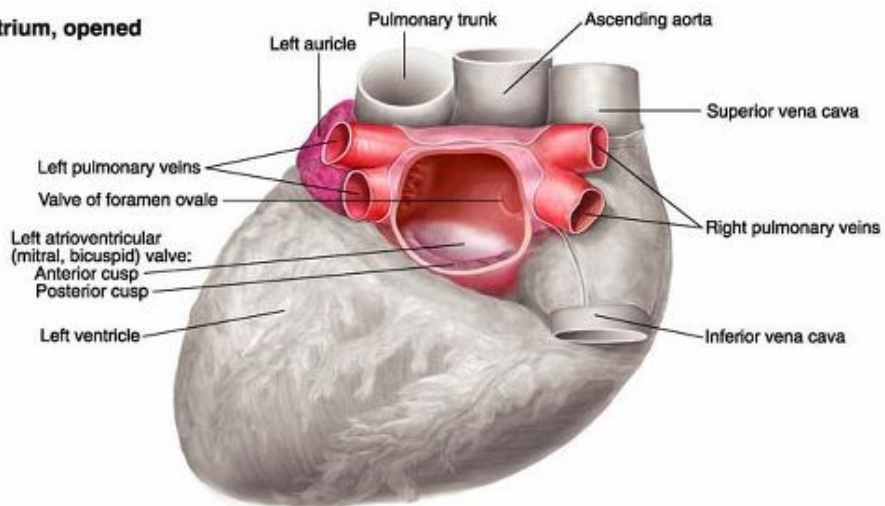


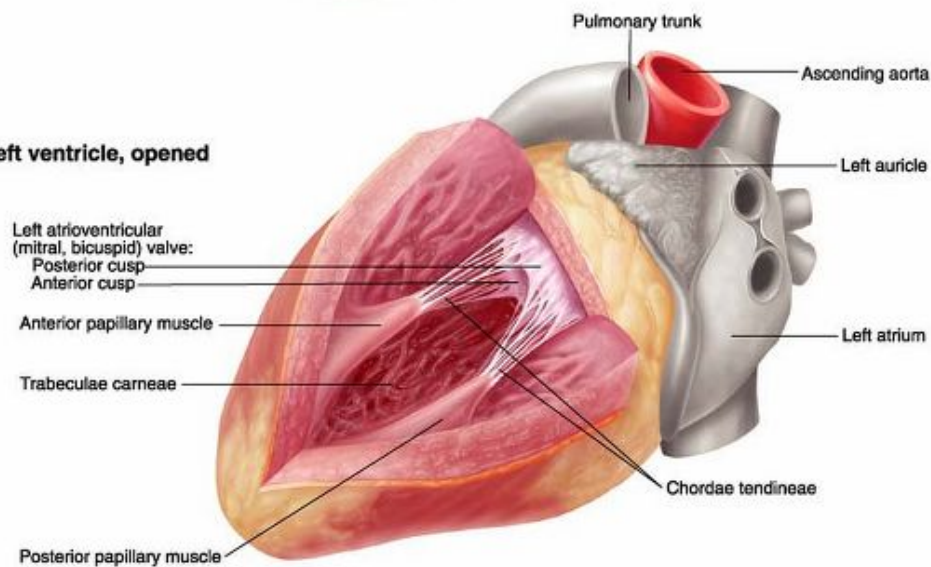
Plate 4-25 Heart, Internal Features, Right Chambers

P.185

A. Left atrium, opened



B. Left ventricle, opened



C. Aortic valve seen through the mitral valve

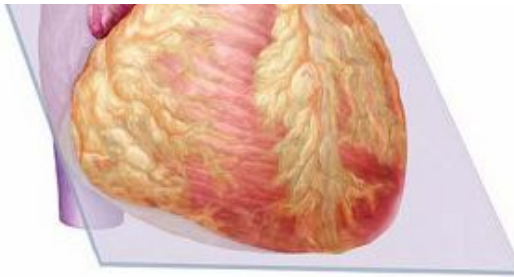
Aortic valve:
Right cusp
Left cusp
Posterior cusp

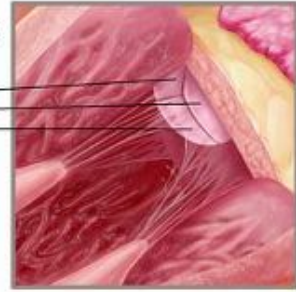
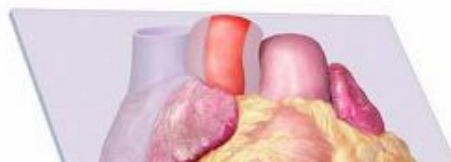
Plate 4-26 Heart, Internal Features, Left Chambers

A. Plane of section





B. Section through the heart showing the posteroinferior portion

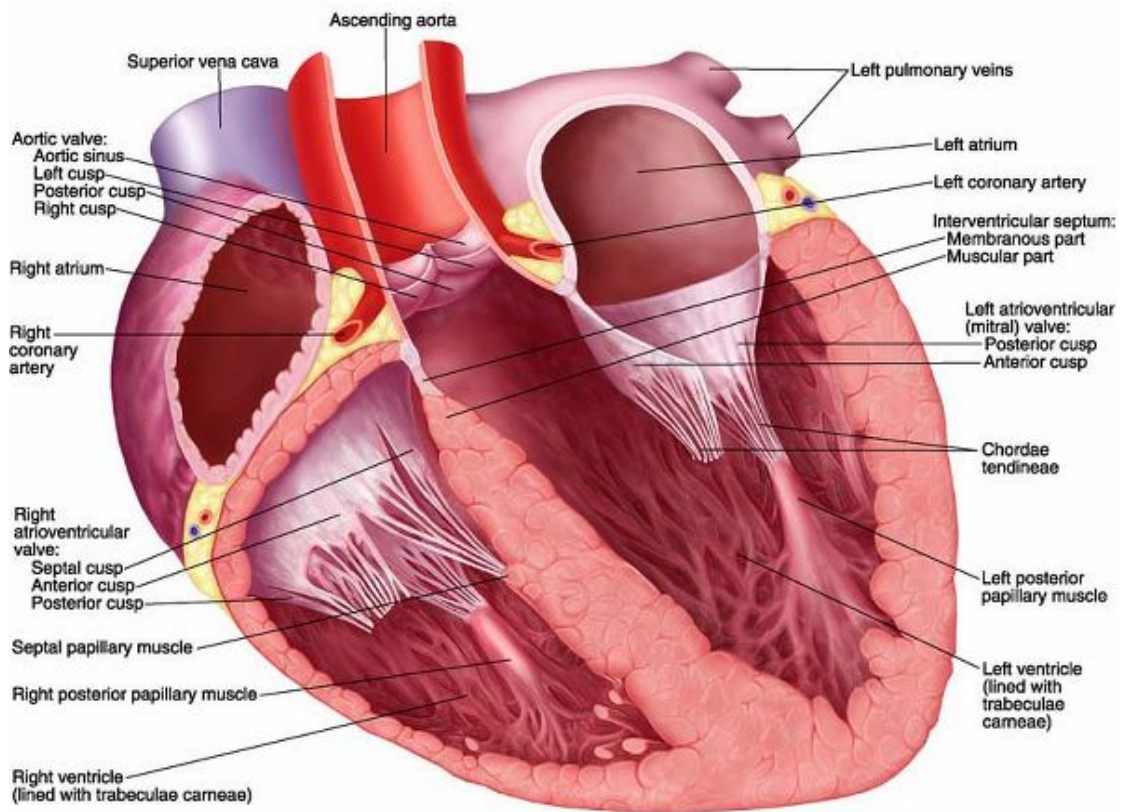
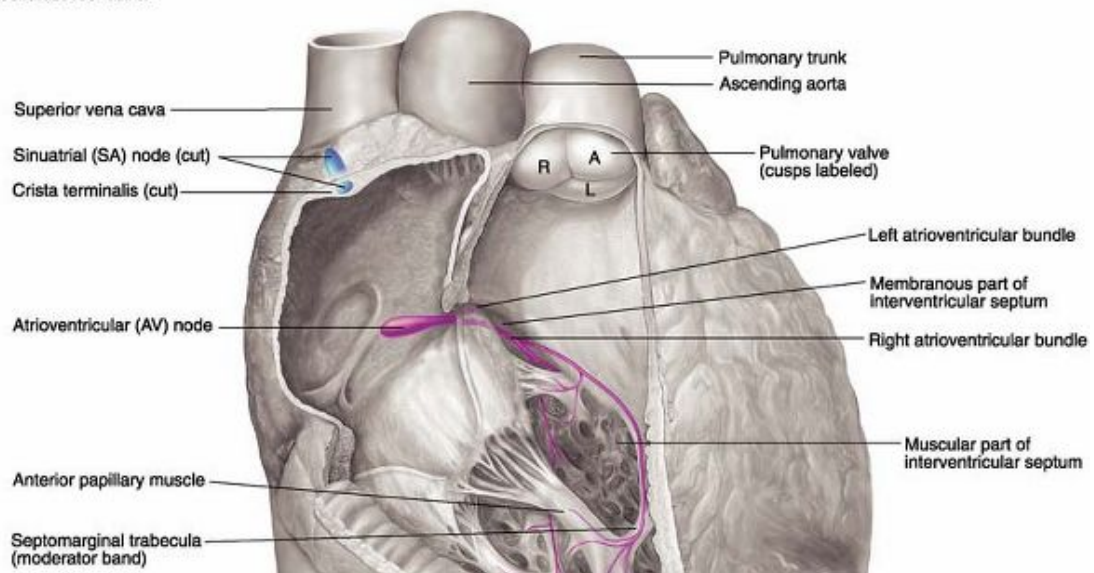
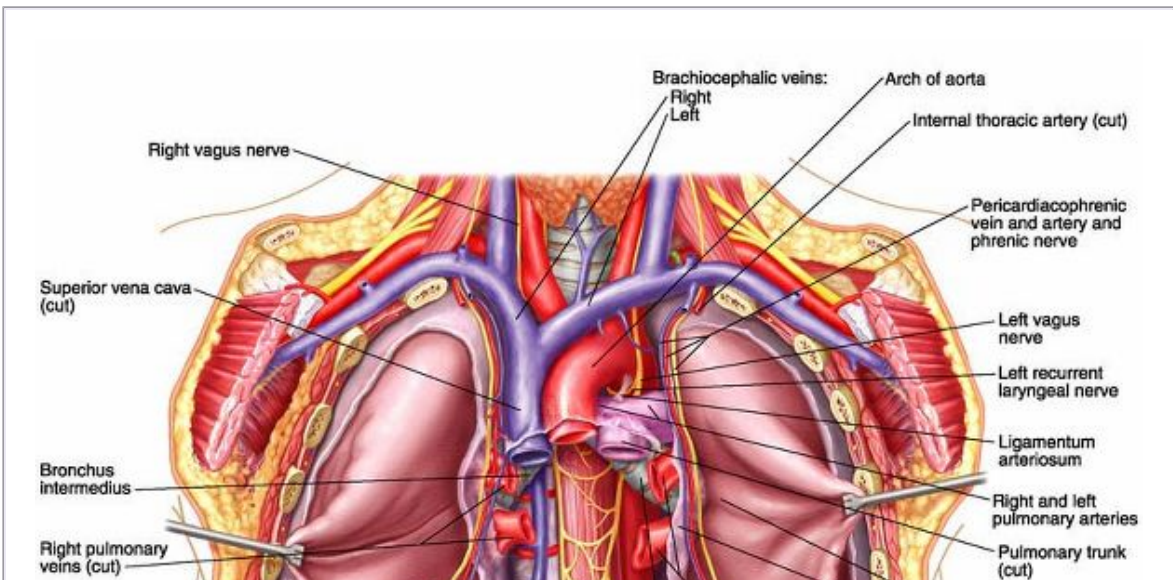
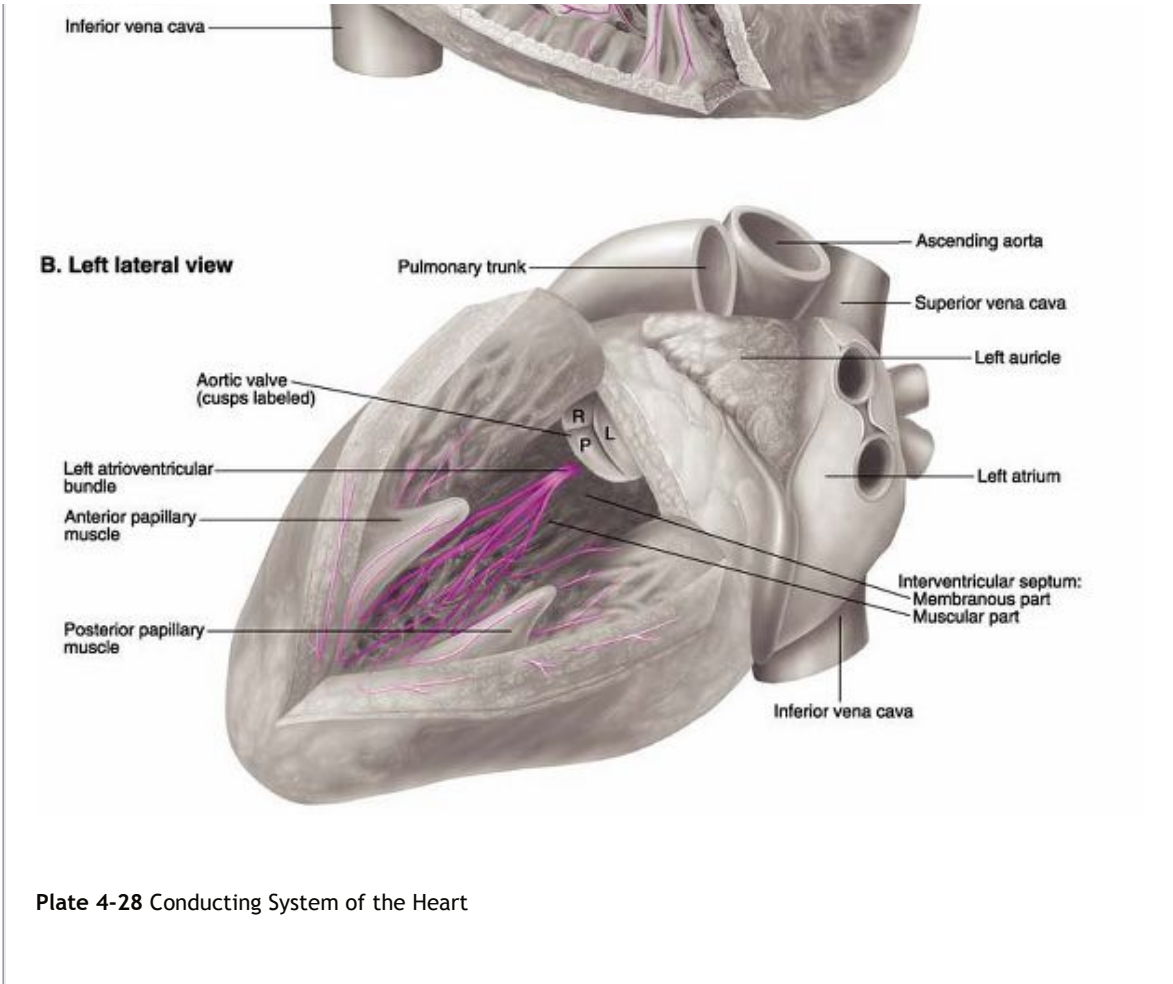
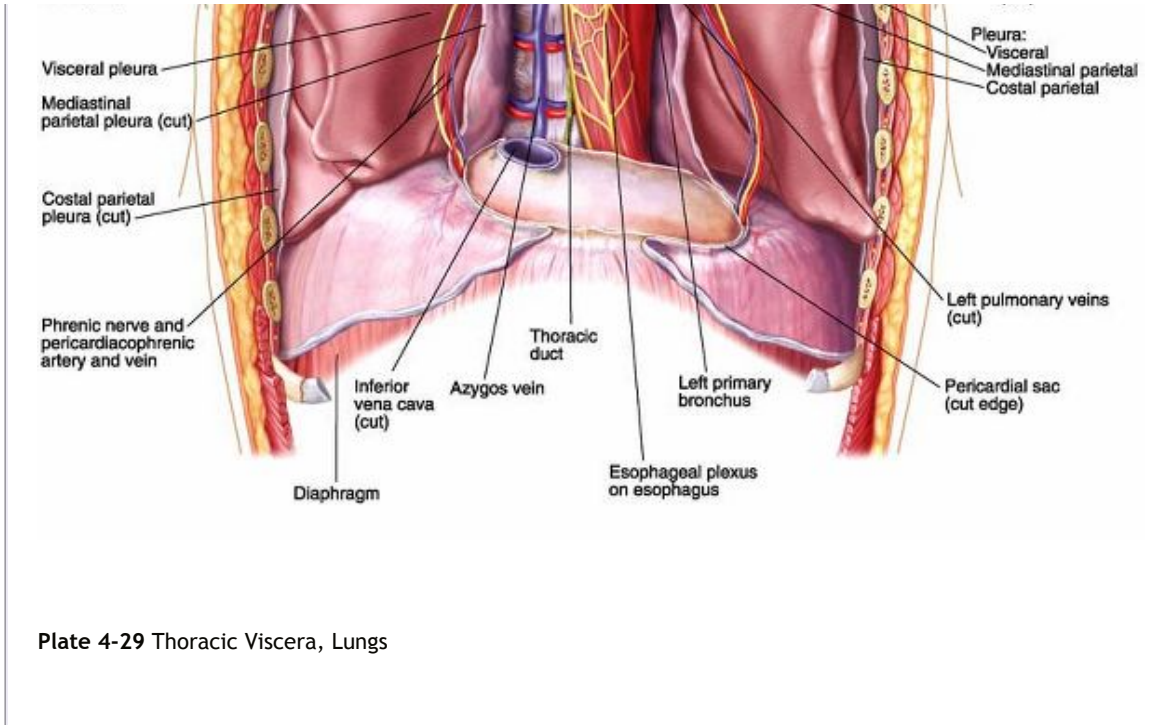


Plate 4-27 Sectional View of the Heart

A. Anterior view

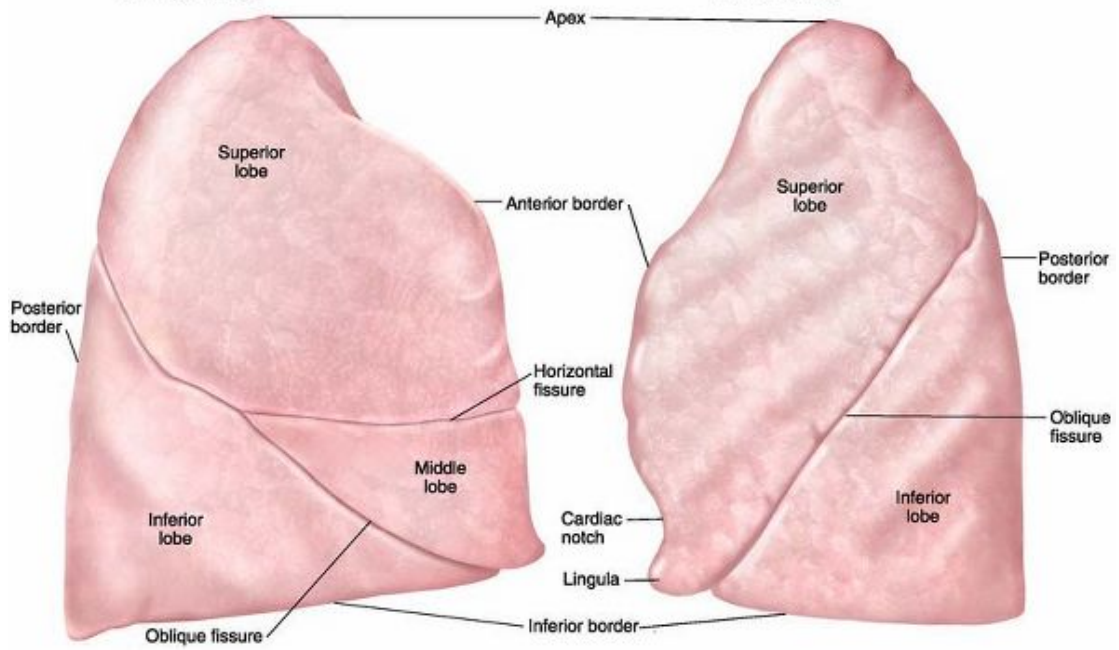






A. Right lung

B. Left lung



C. Radiograph, anterior view

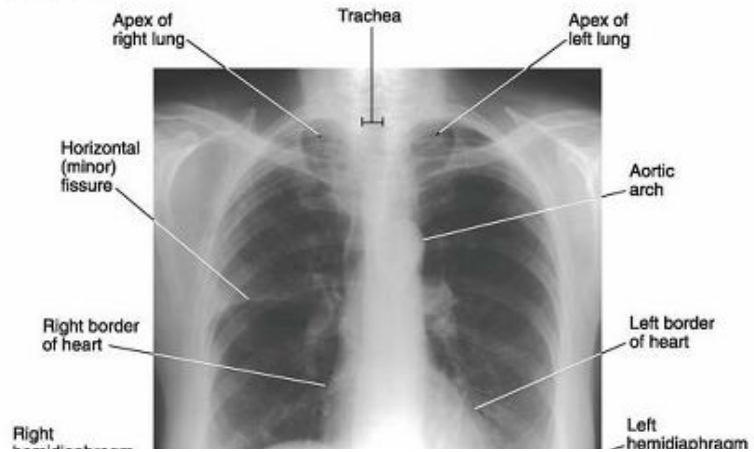
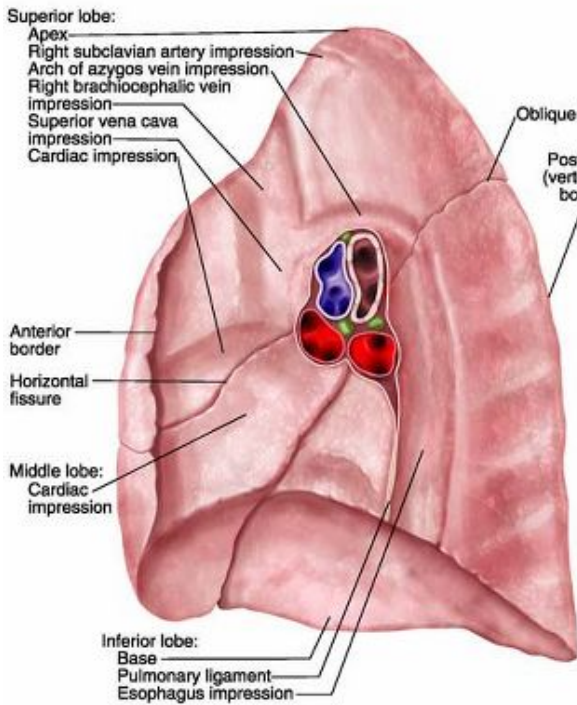


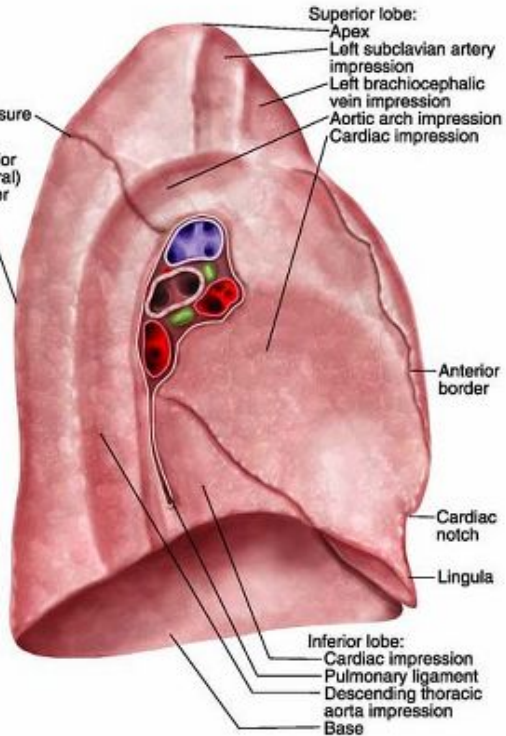


Plate 4-30 Lungs, Lateral and Radiographic Views

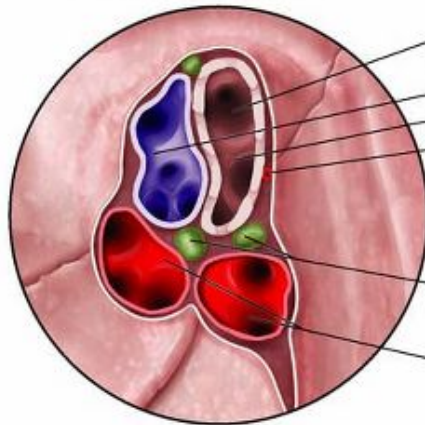
A. Right lung



B. Left lung



C. Structures in right hilum



D. Structures in left hilum

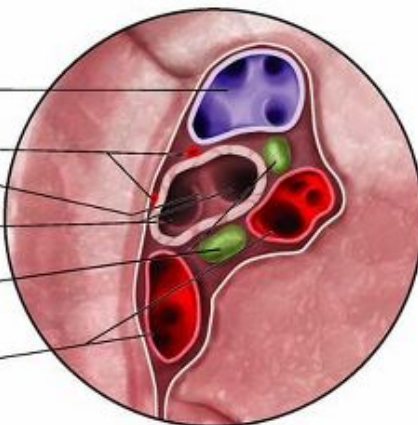
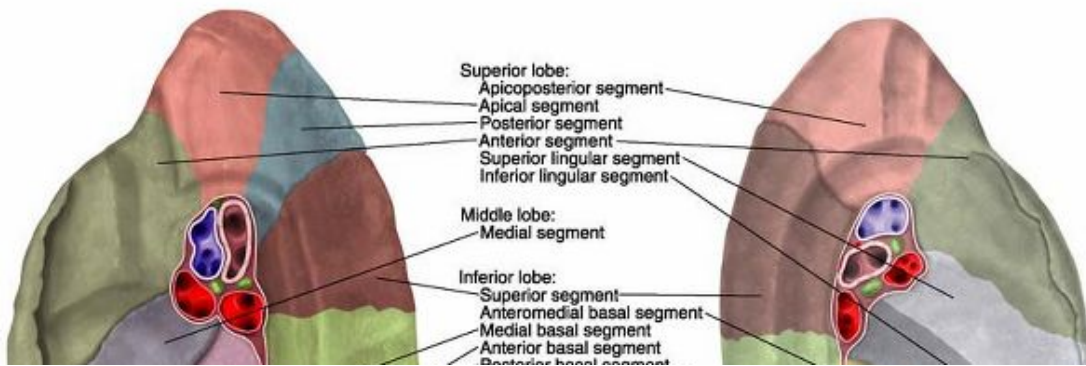
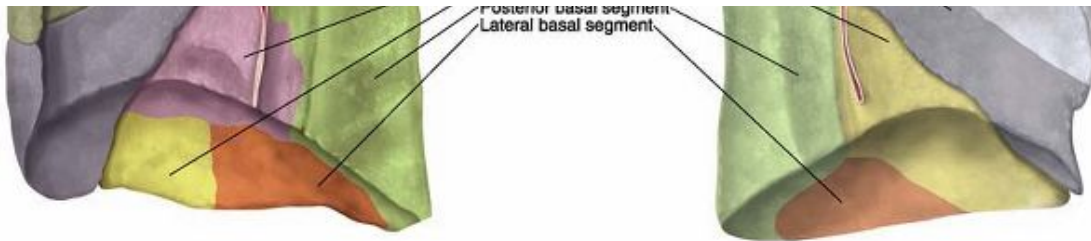


Plate 4-31 Lungs, Medial View

A. Right lung, medial view

B. Left lung, medial view





C. Right lung, lateral view

D. Left lung, lateral view

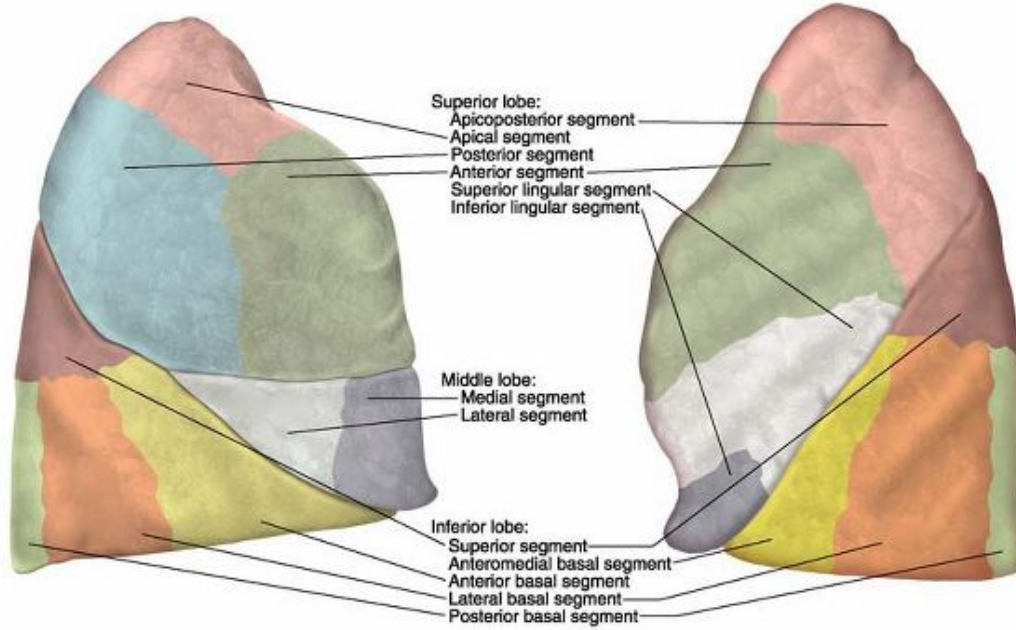
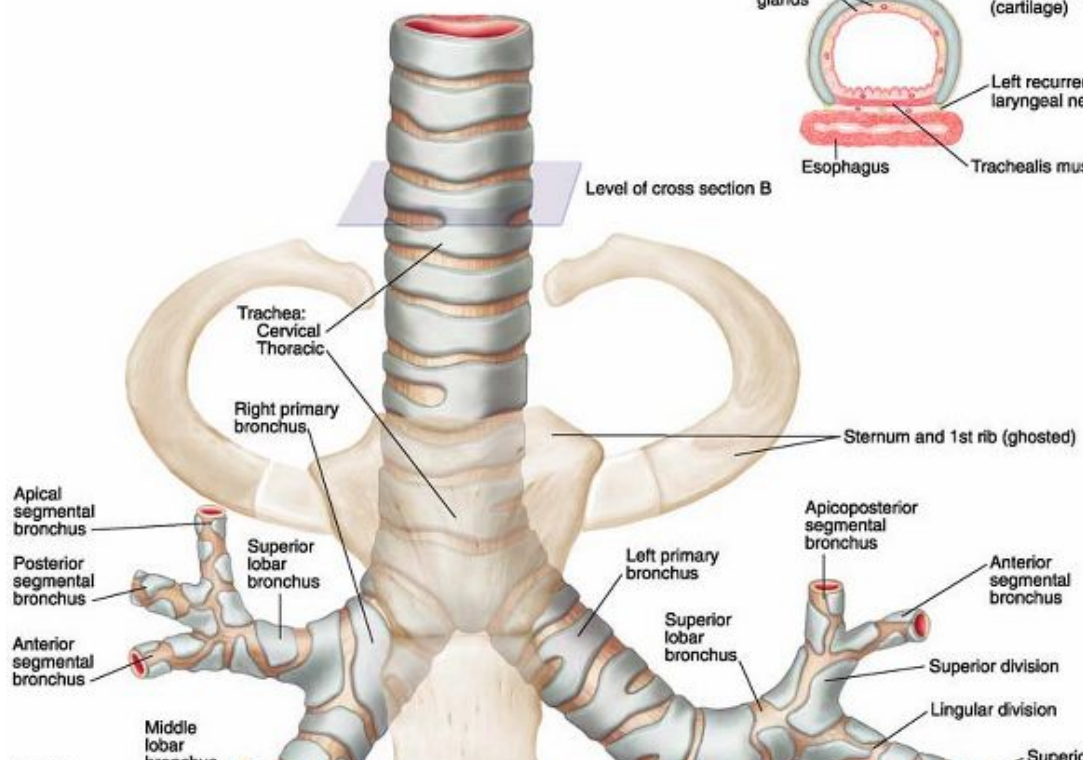
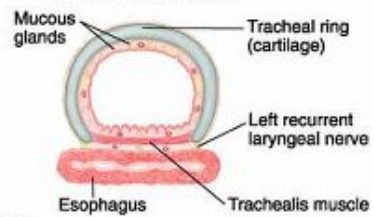


Plate 4-32 Lungs, Bronchopulmonary Segments

A. Anterior view



B. Cross section



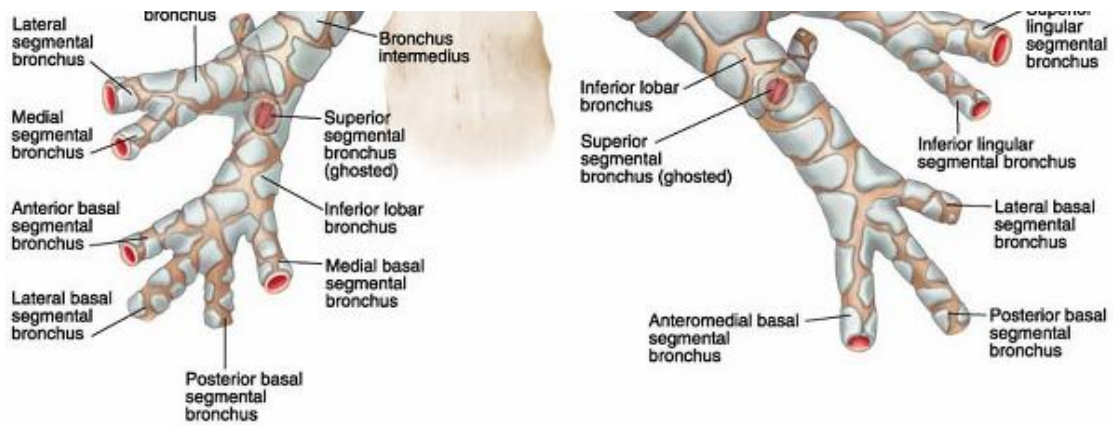
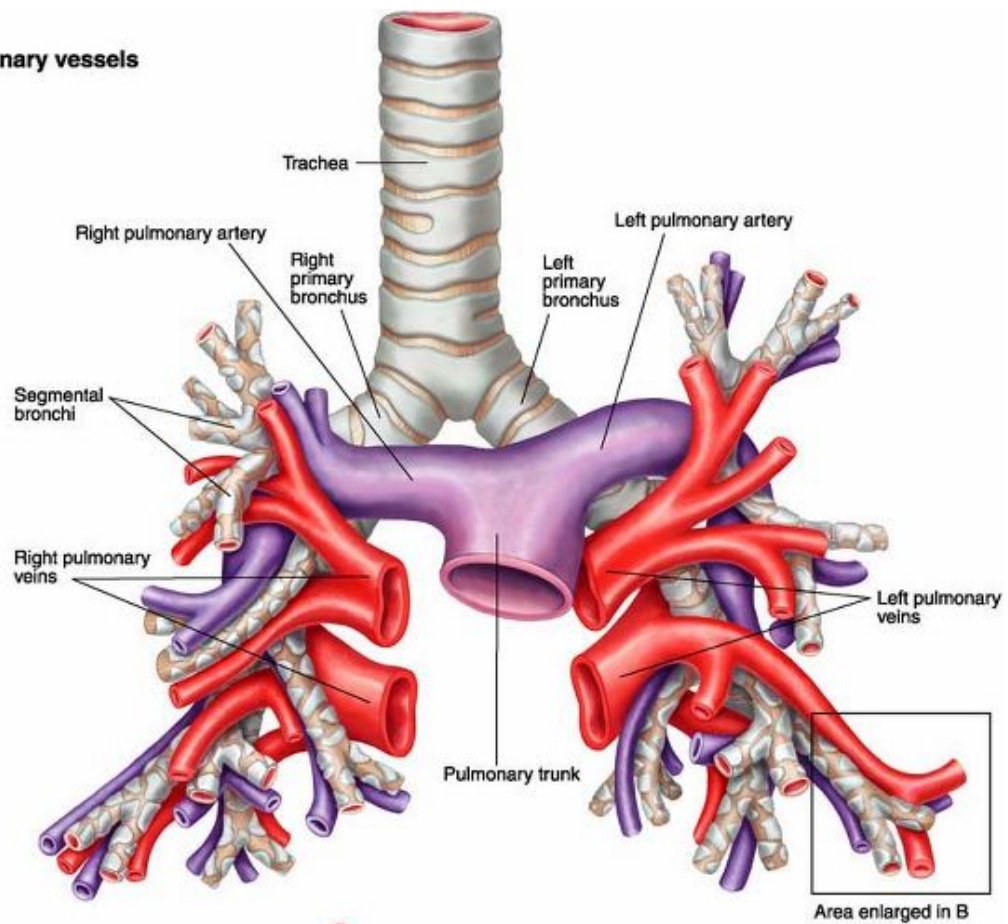


Plate 4-33 Trachea and Bronchial Tree

A. Pulmonary vessels



B. Segmental vessels

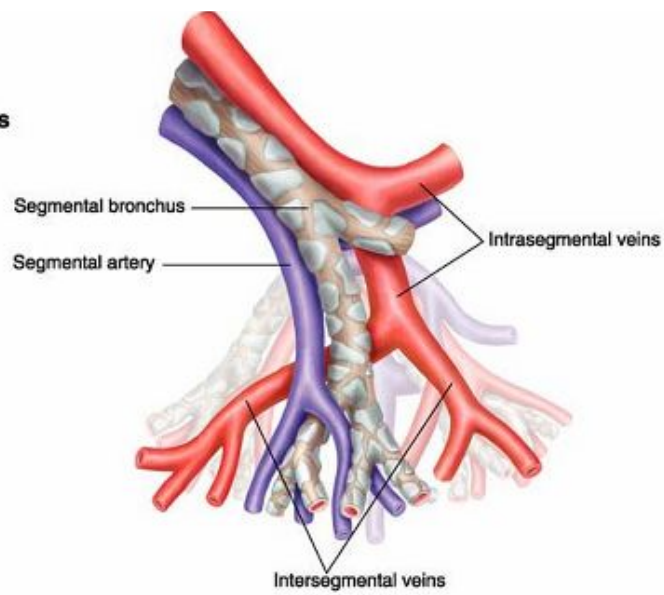
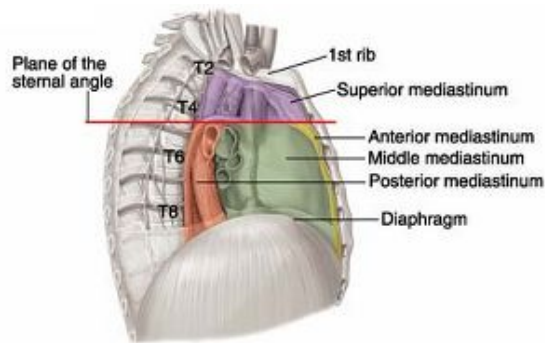
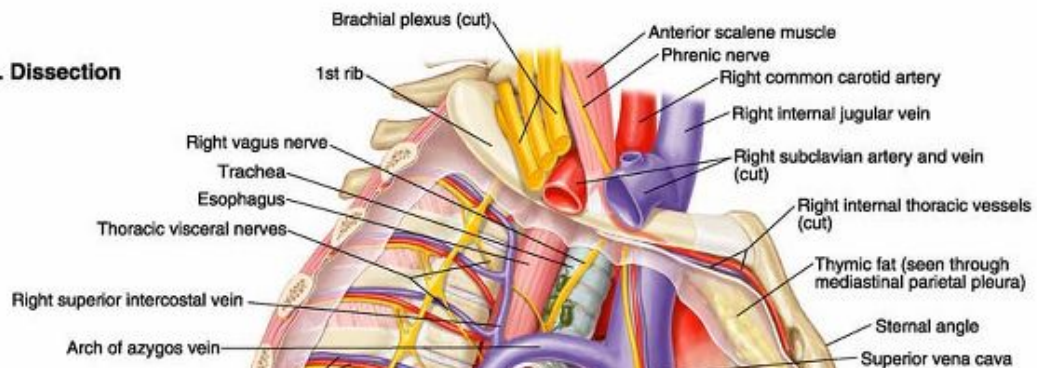


Plate 4-34 Blood Supply to the Lungs

A. Parts of the mediastinum



B. Dissection



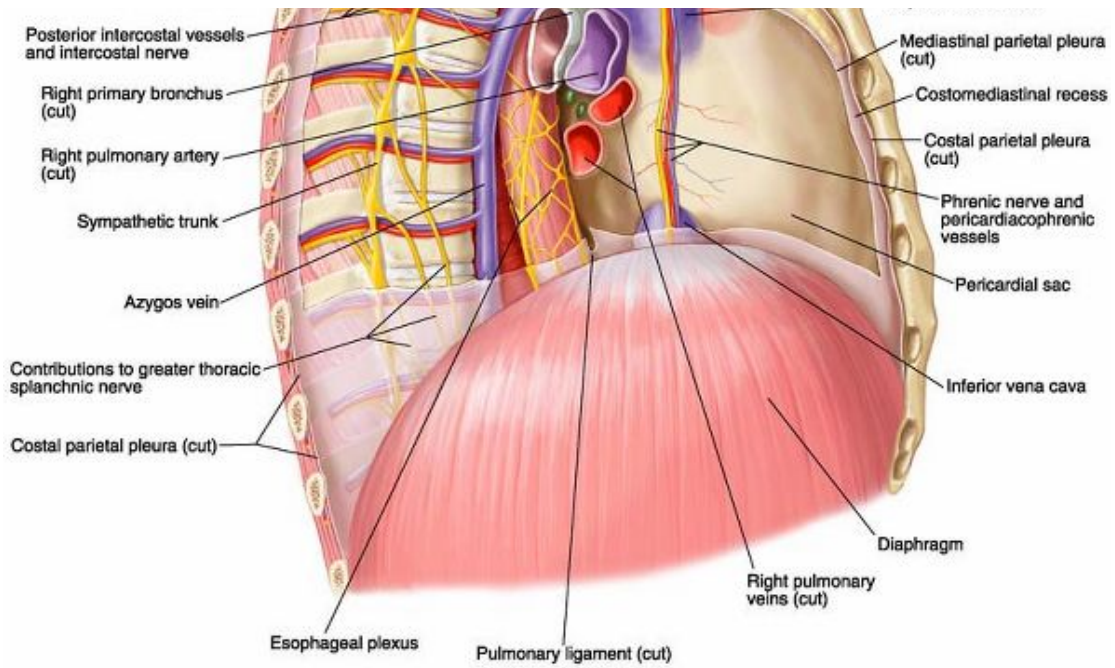
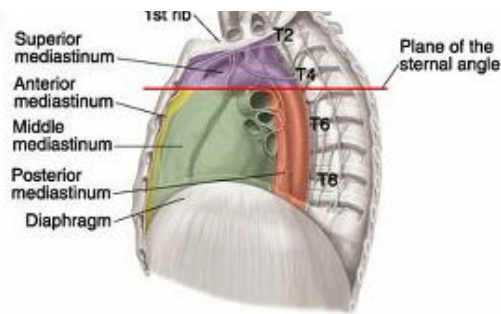


Plate 4-35 Mediastinum, Right Lateral View

A. Parts of the mediastinum



B. Dissection

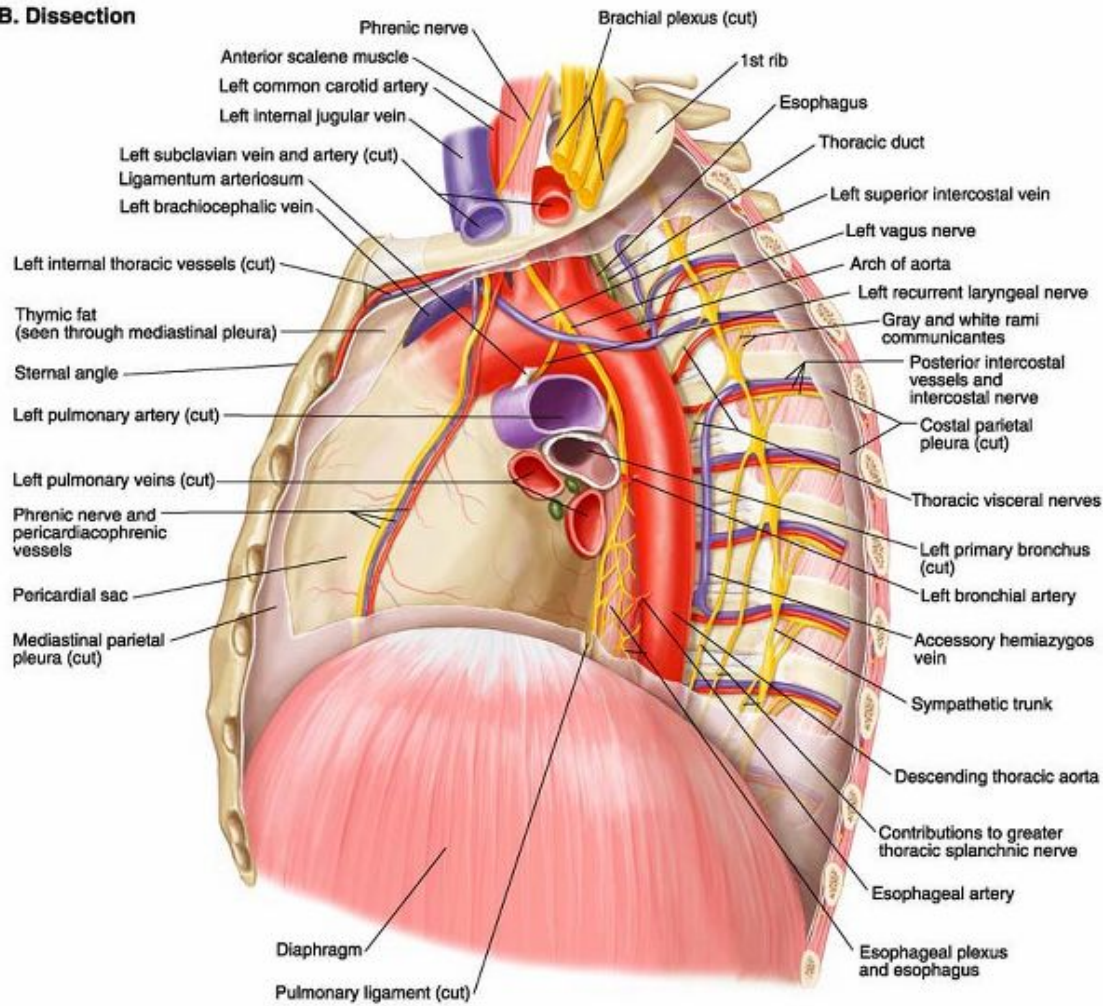
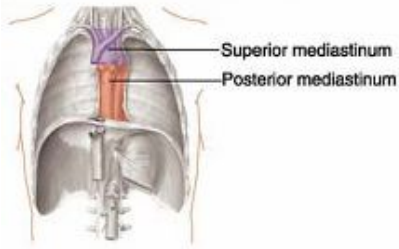


Plate 4-36 Mediastinum, Left Lateral View

A. Parts of the mediastinum



B. Dissection

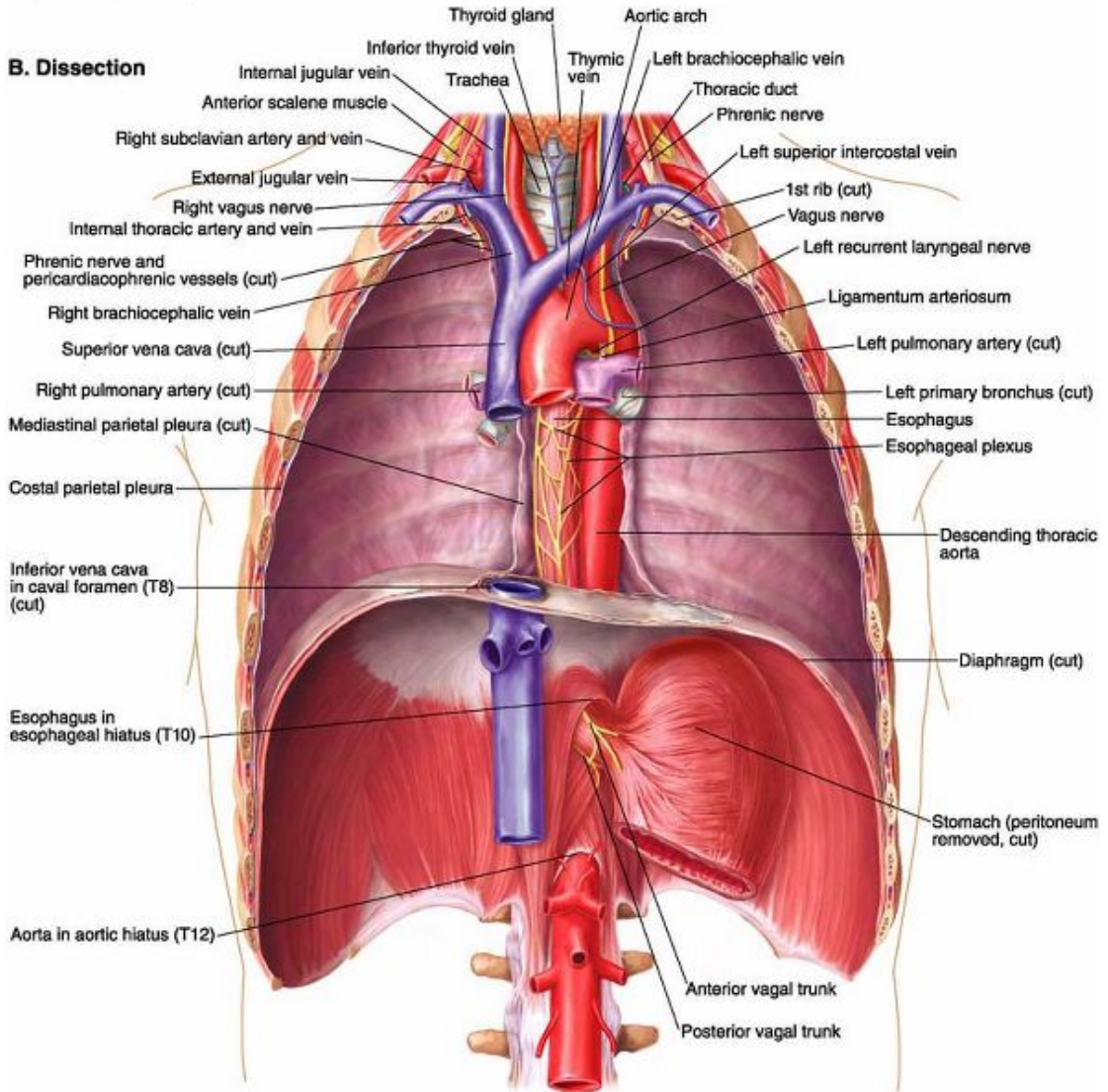


Plate 4-37 Mediastinum, Anterior View

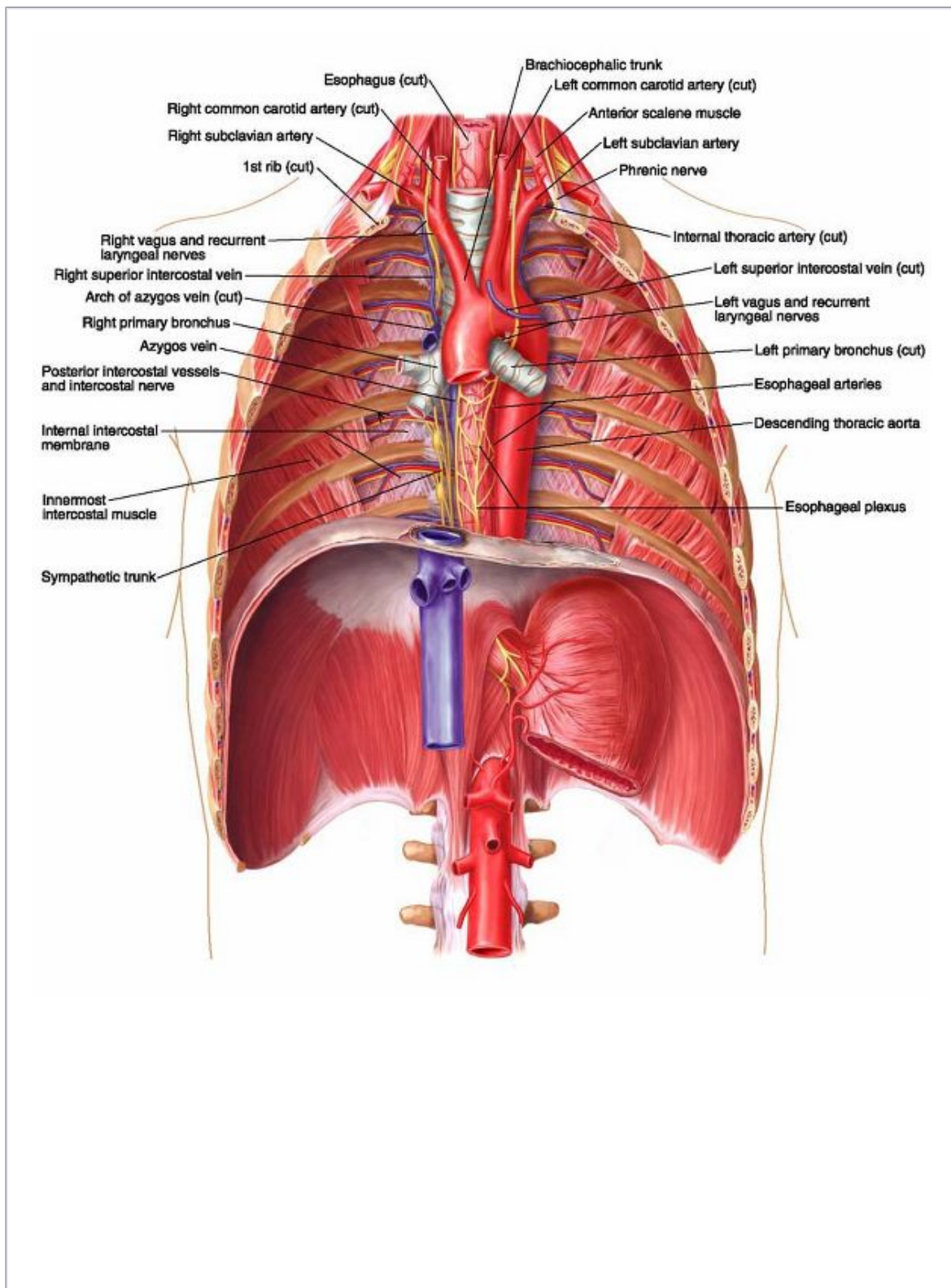
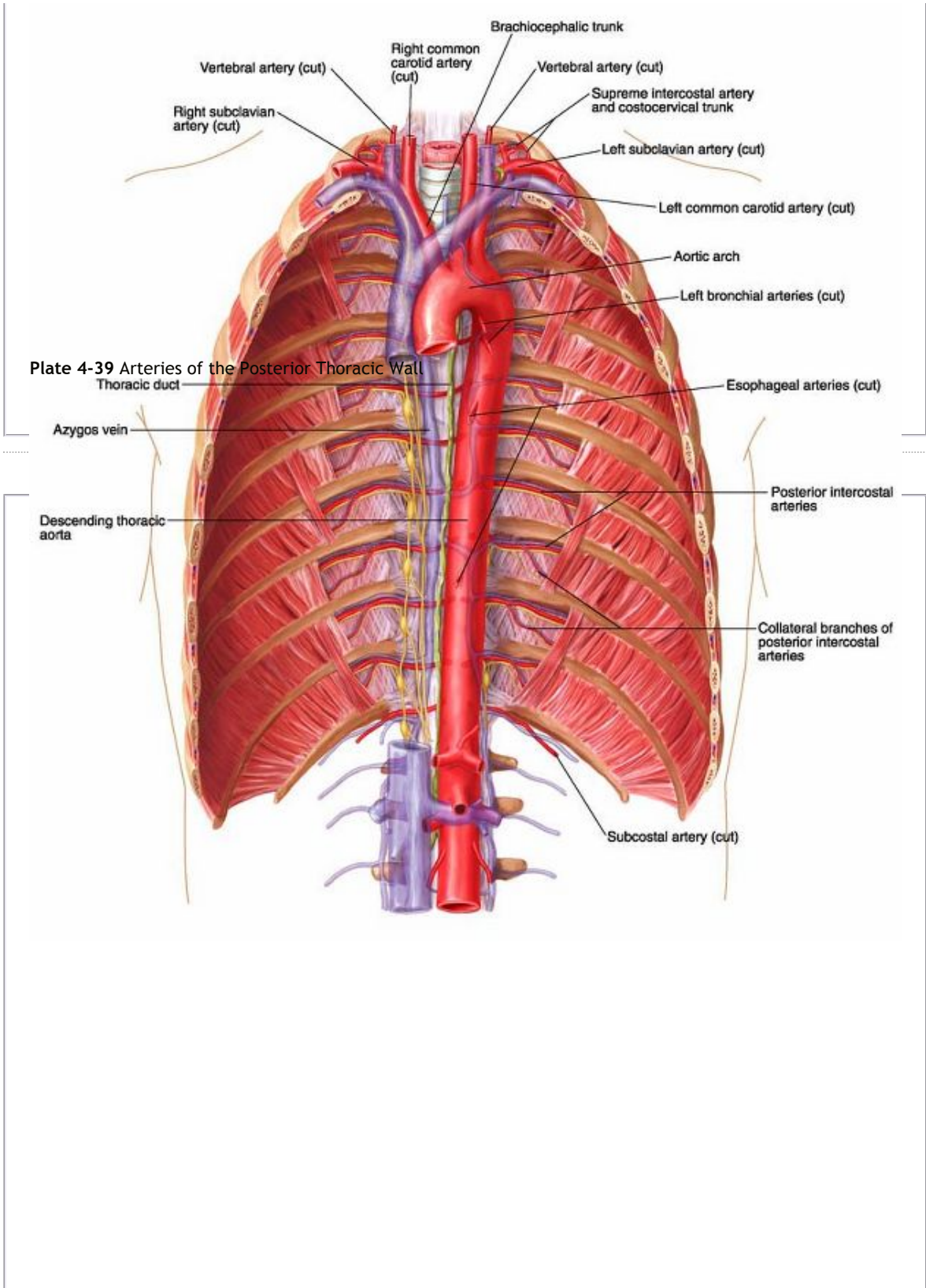
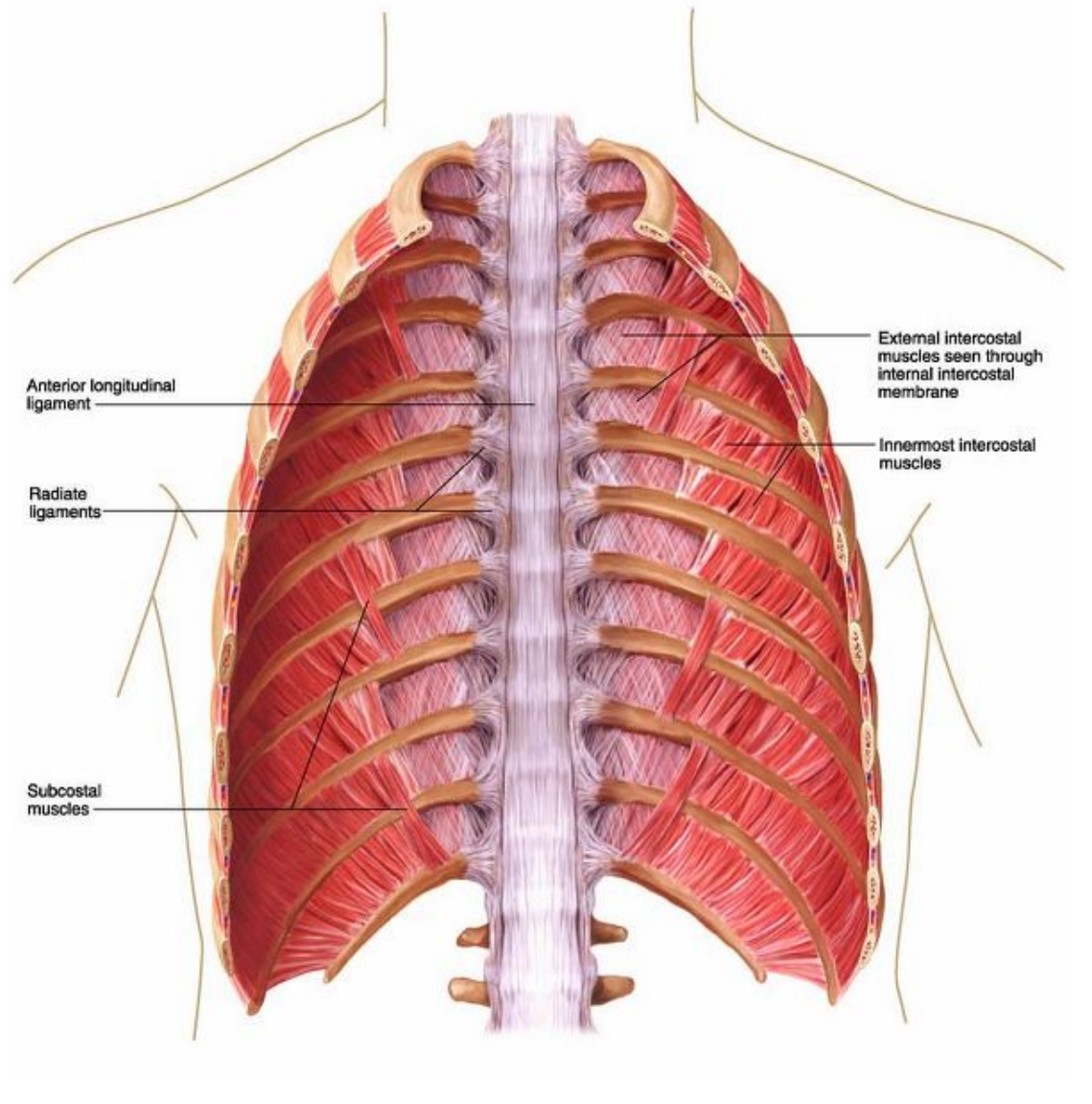
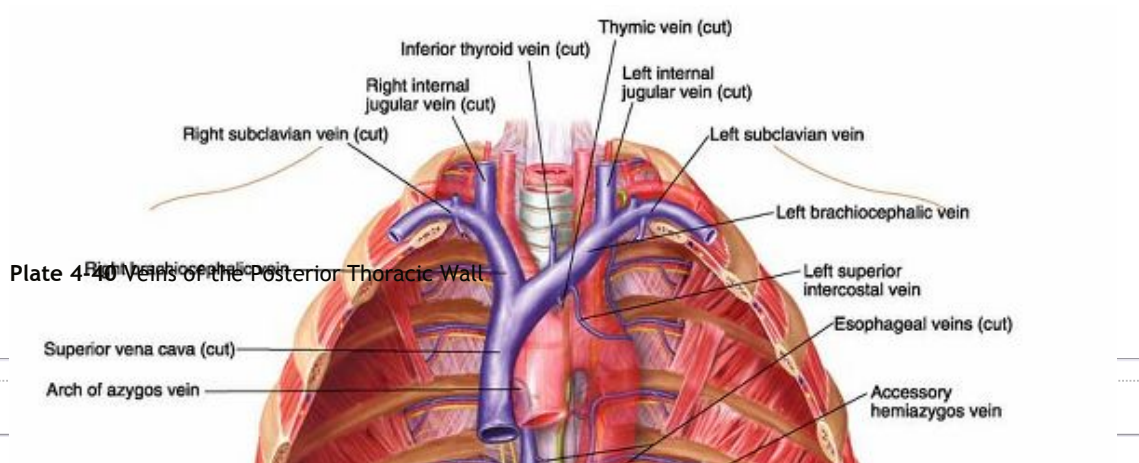


Plate 4-38 Mediastinum, Deep Dissection





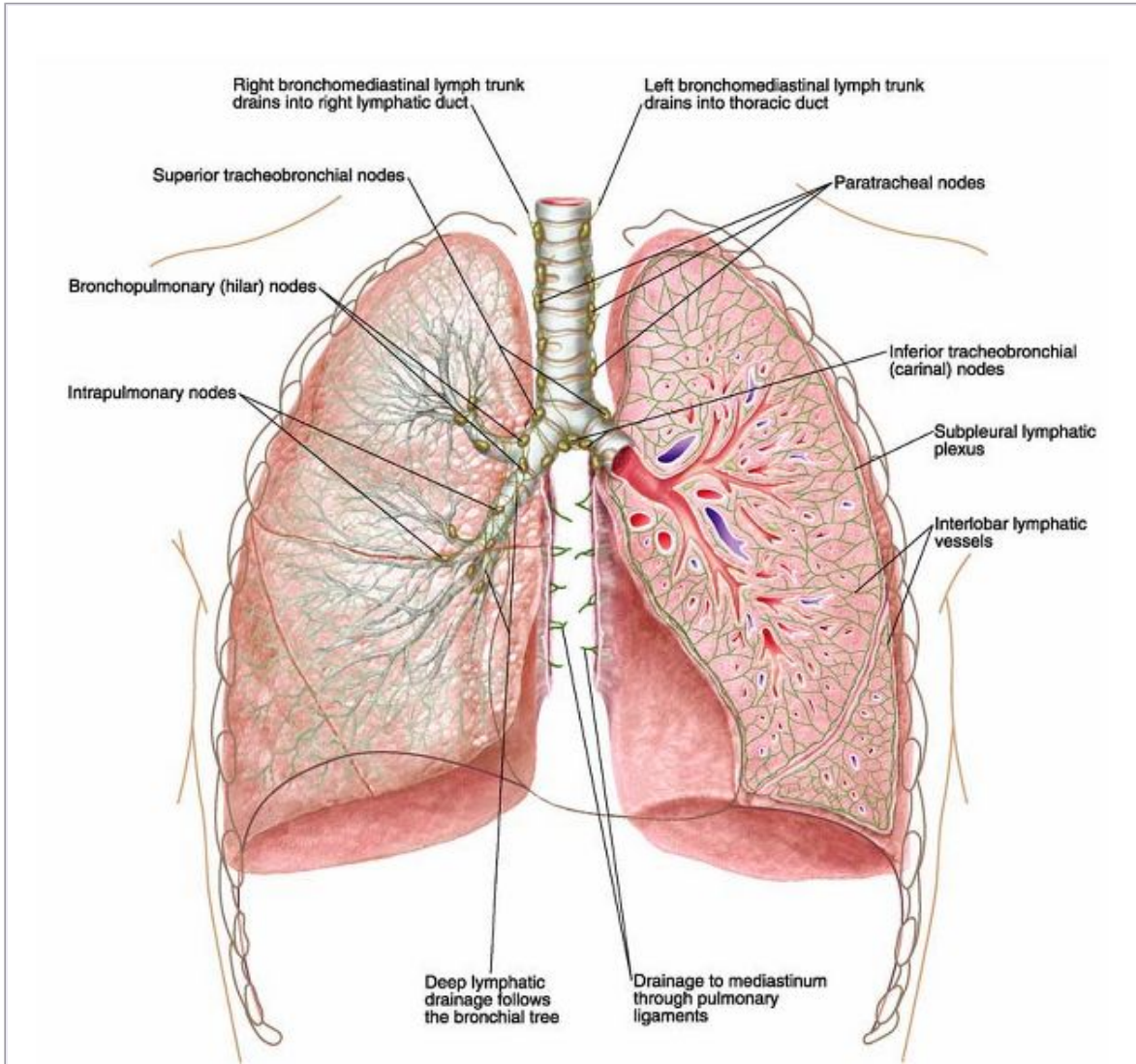


Plate 4-42 Lymphatics of the Lungs

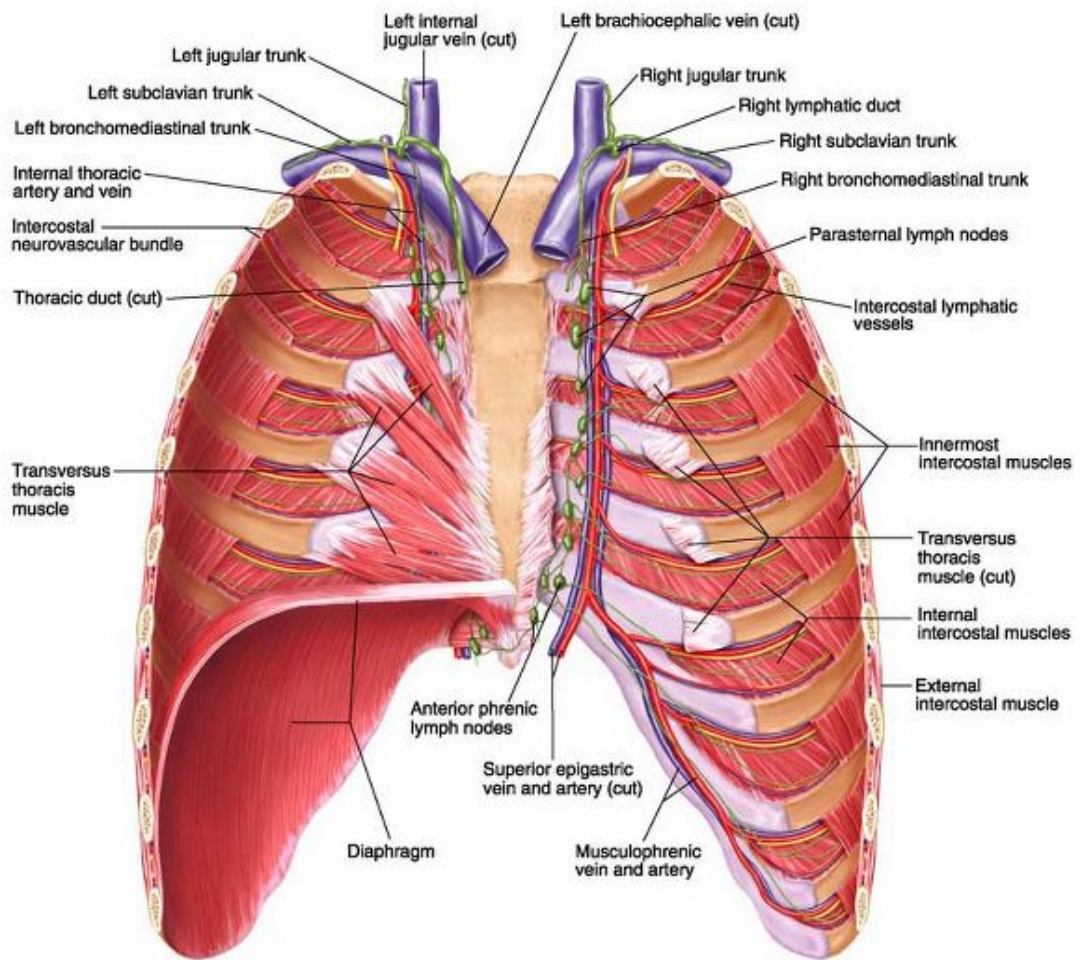
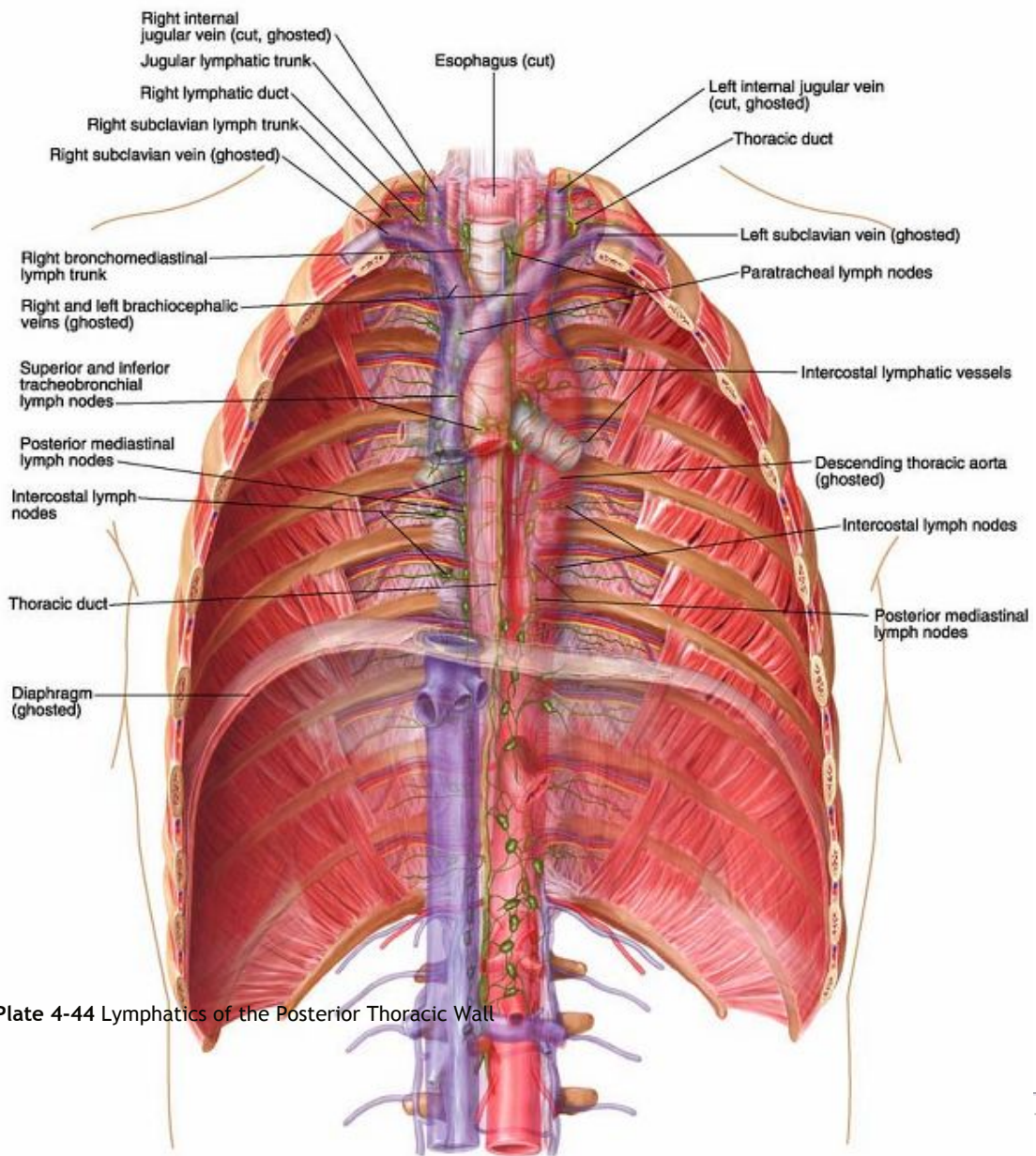


Plate 4-43 Lymphatics of the Anterior Thoracic Wall



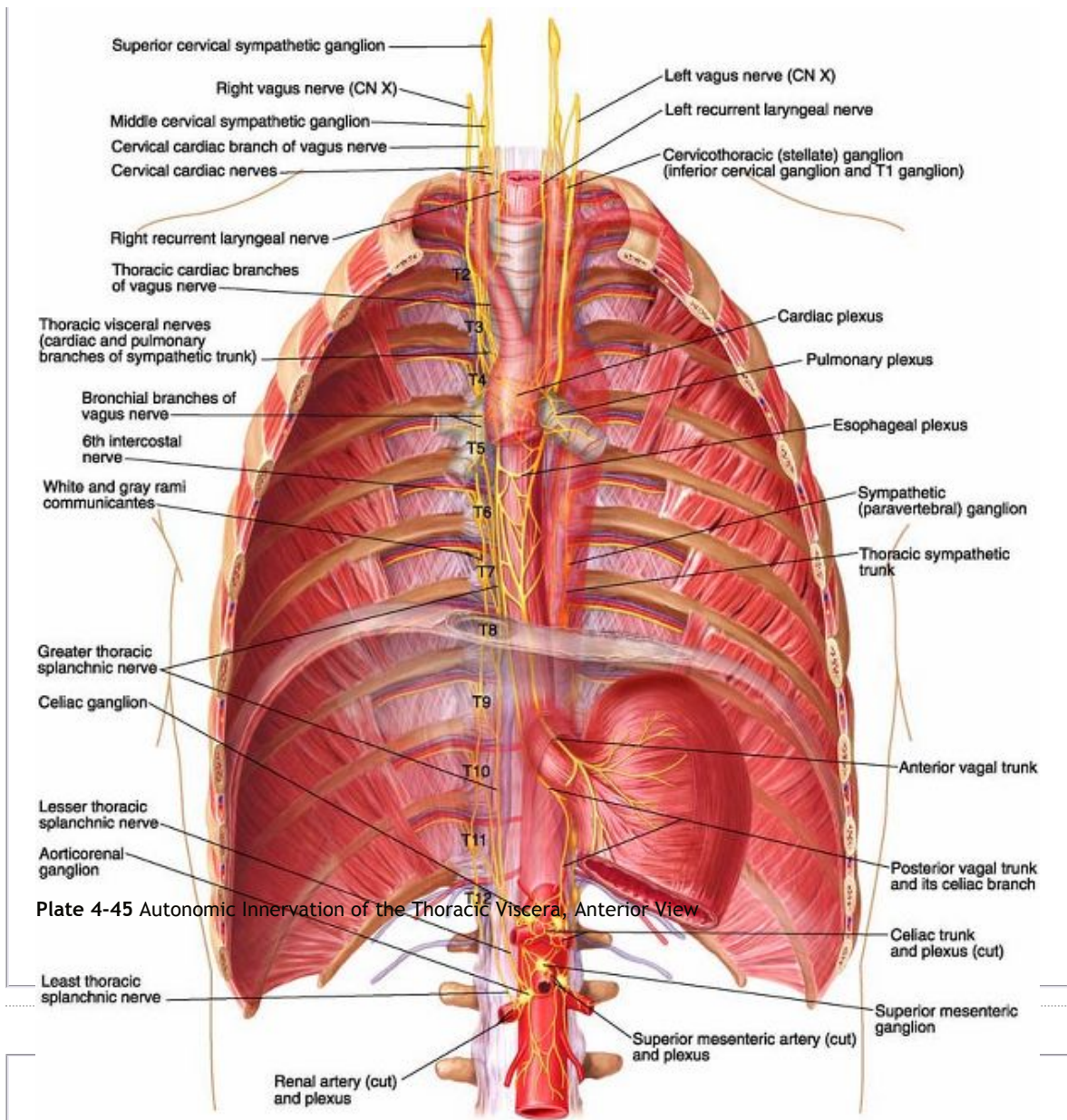


Plate 4-45 Autonomic Innervation of the Thoracic Viscera, Anterior View

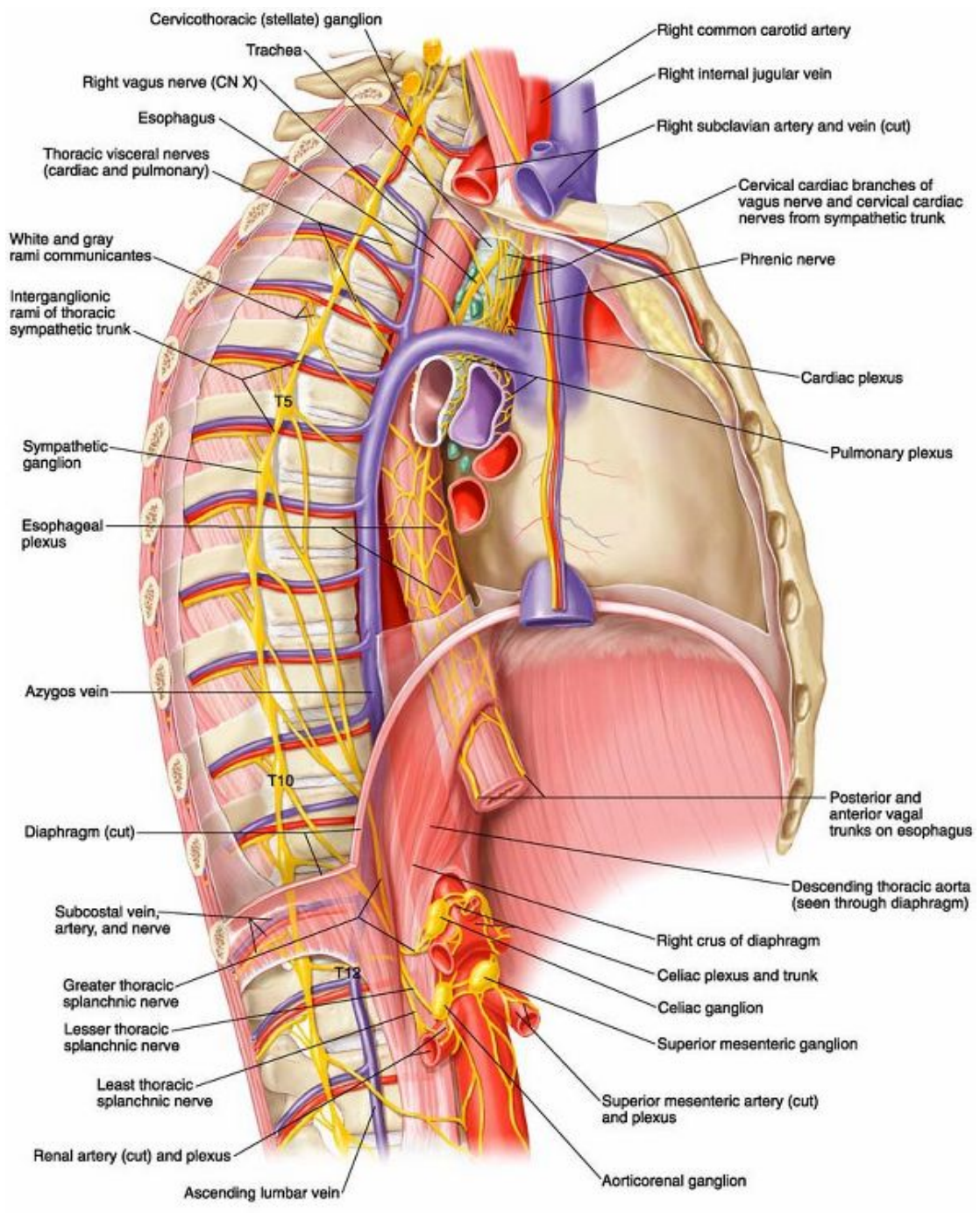
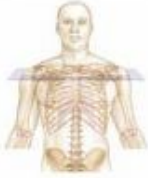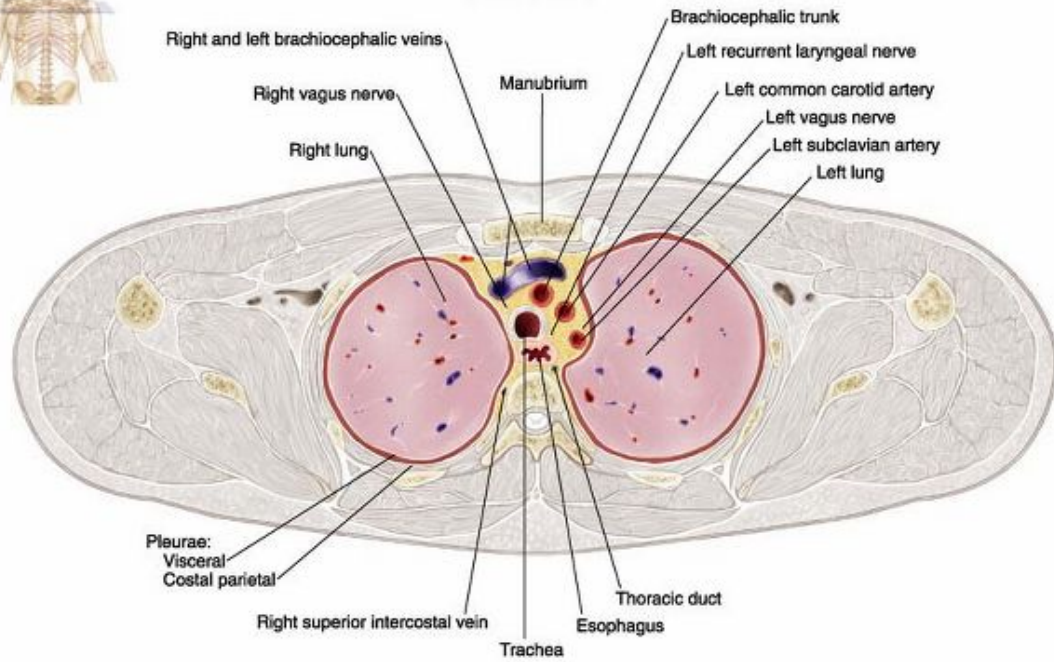


Plate 4-46 Autonomic Innervation of the Thoracic Viscera, Lateral View

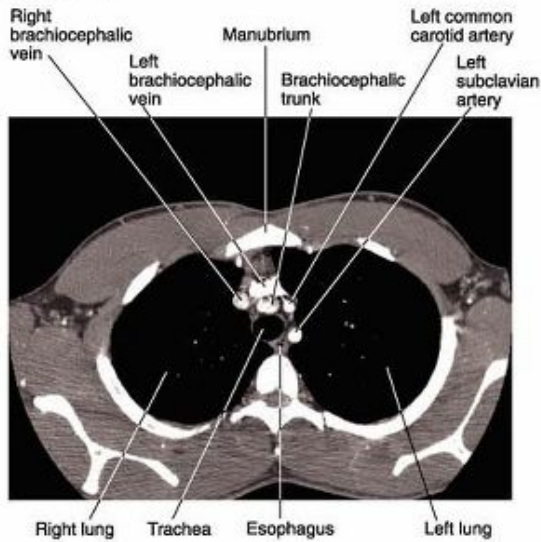
A. Orientation



B. Cross section



C. CT view



D. CT view with lung window

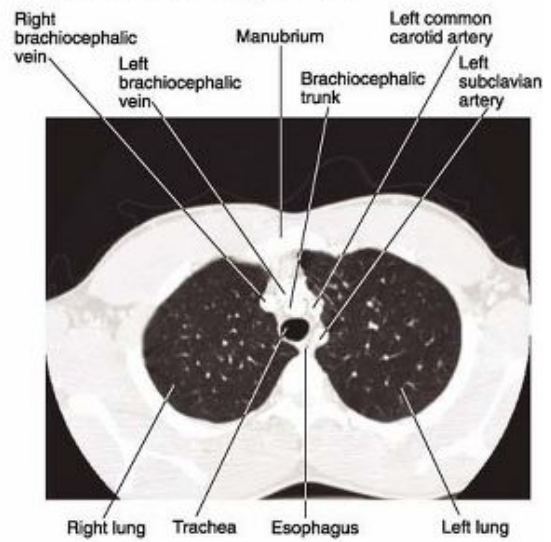
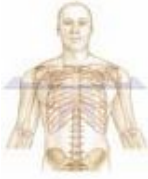

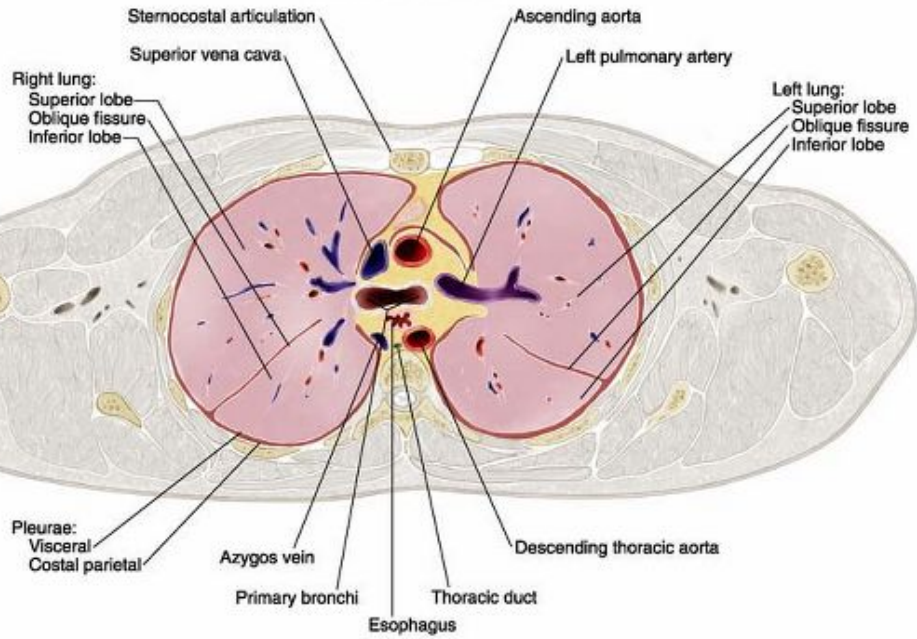
Plate 4-47 Cross Section of the Thorax at the T2 Vertebral Level



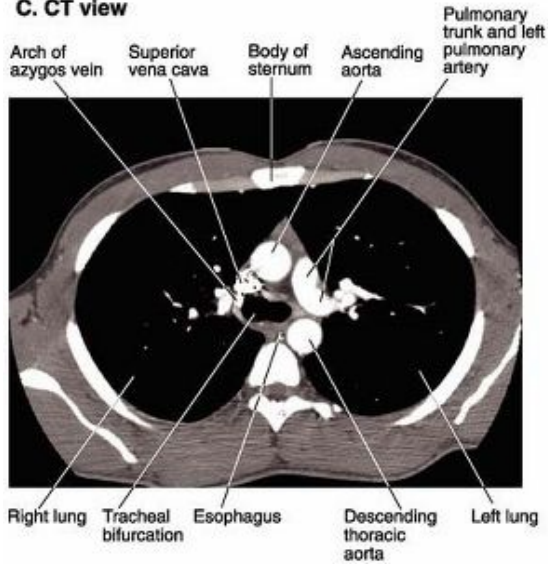
A. Orientation



B. Cross section



C. CT view



D. CT view with lung window

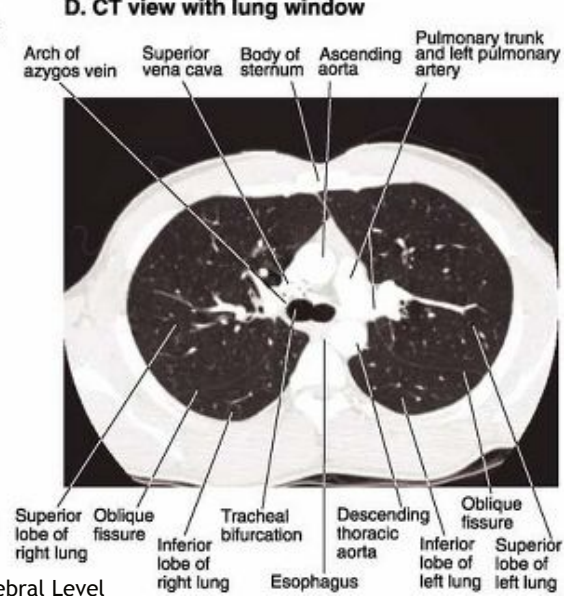
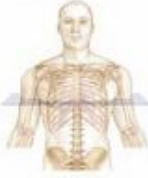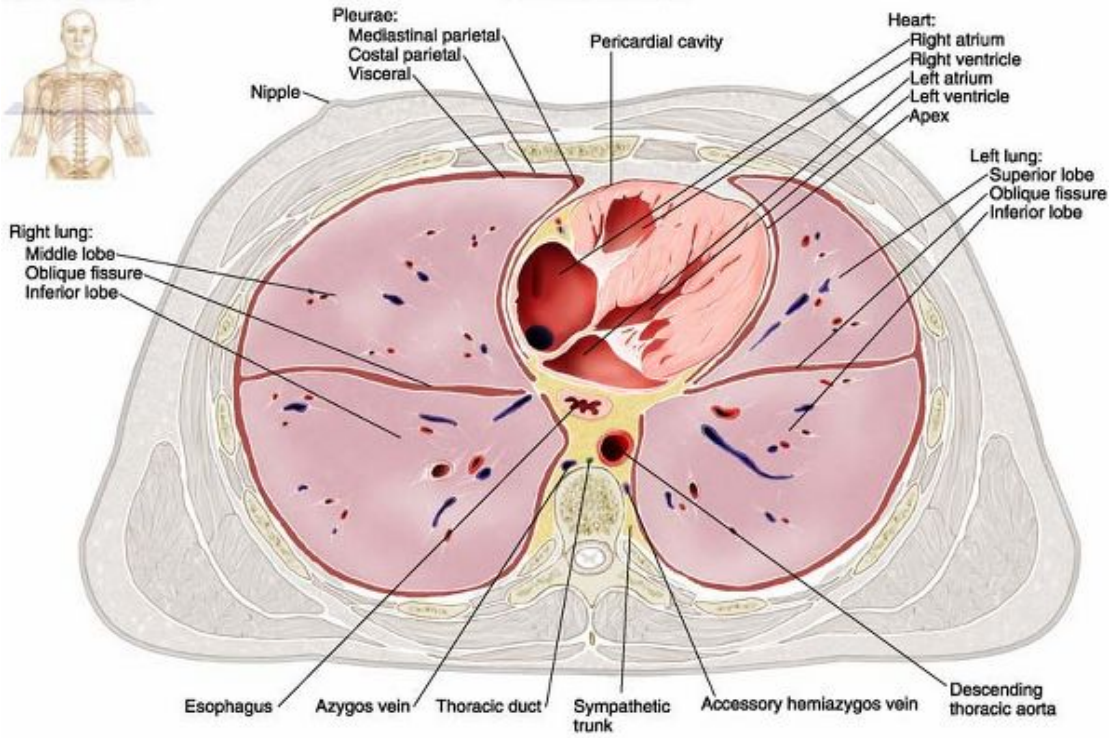


Plate 4-48 Cross Section of the Thorax at the T5 Vertebral Level

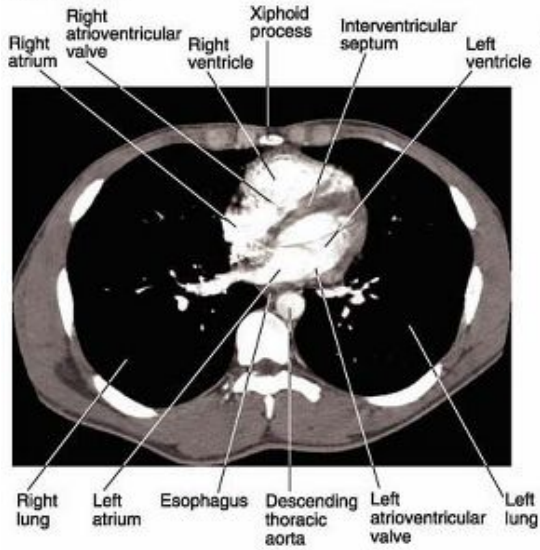
A. Orientation



B. Cross section



C. CT view



D. CT view with lung window

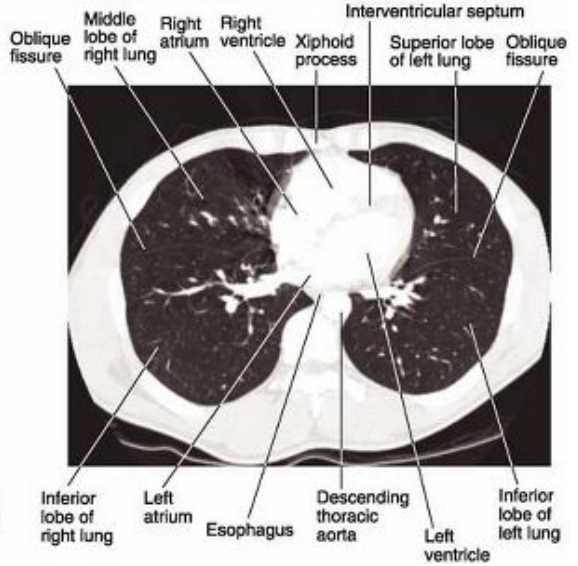


Plate 4-49 Cross Section of the Thorax at the T7 Vertebral Level

Authors: Tank, Patrick W.; Gest, Thomas R.

Title: *Lippincott Williams & Wilkins Atlas of Anatomy, 1st Edition*

Copyright ©2009 Lippincott Williams & Wilkins

> Table of Contents > Chapter 5 - The Abdomen

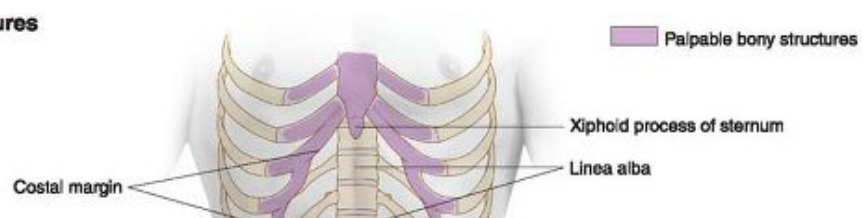Chapter 5

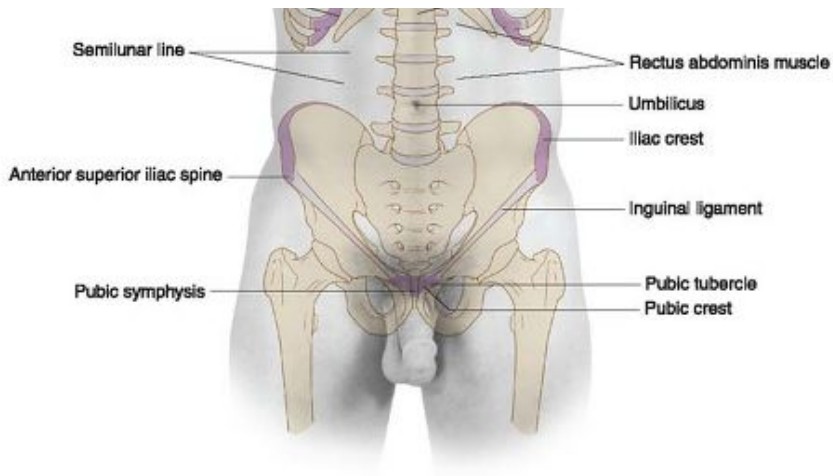
The Abdomen

P.212

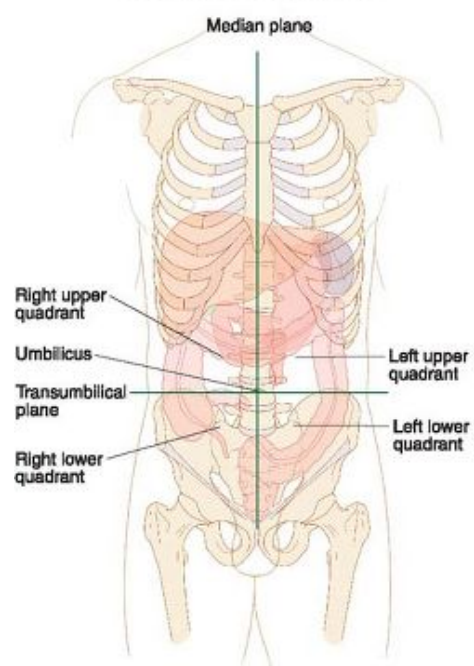
P.213

A. Palpable structures





B. Abdominal quadrants



C. Abdominal regions

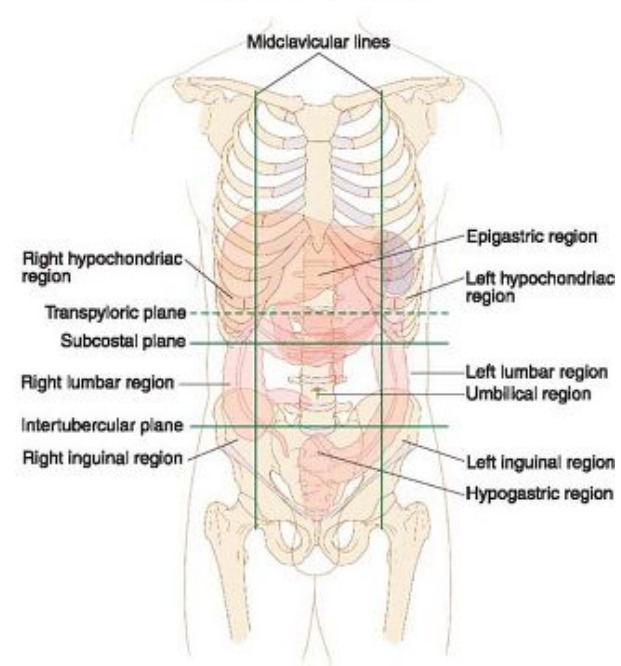
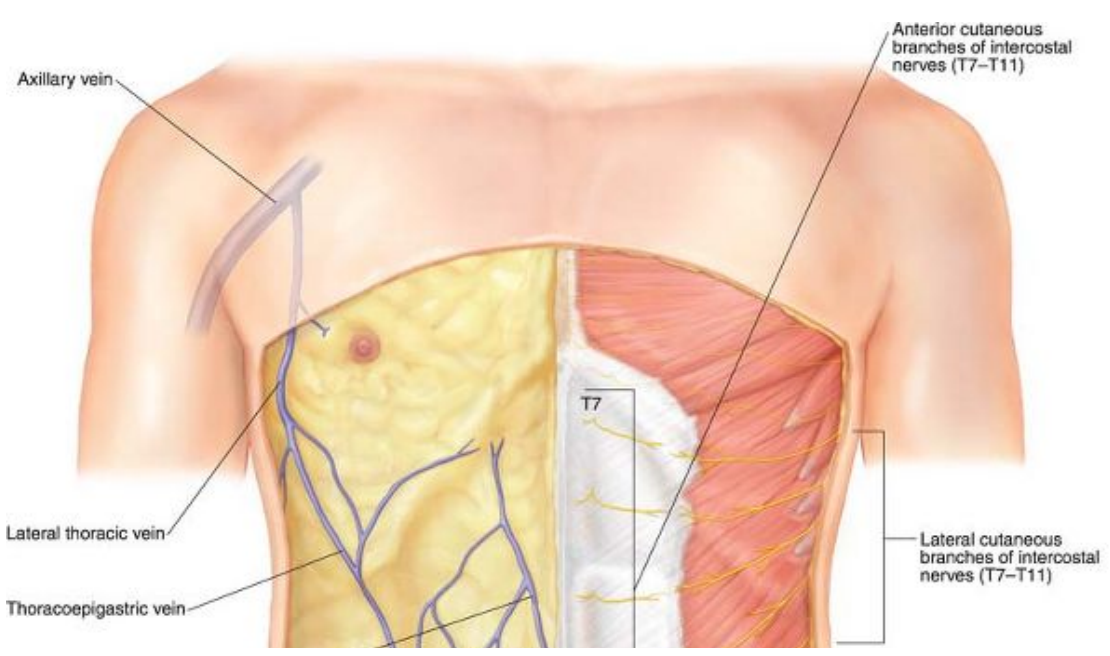
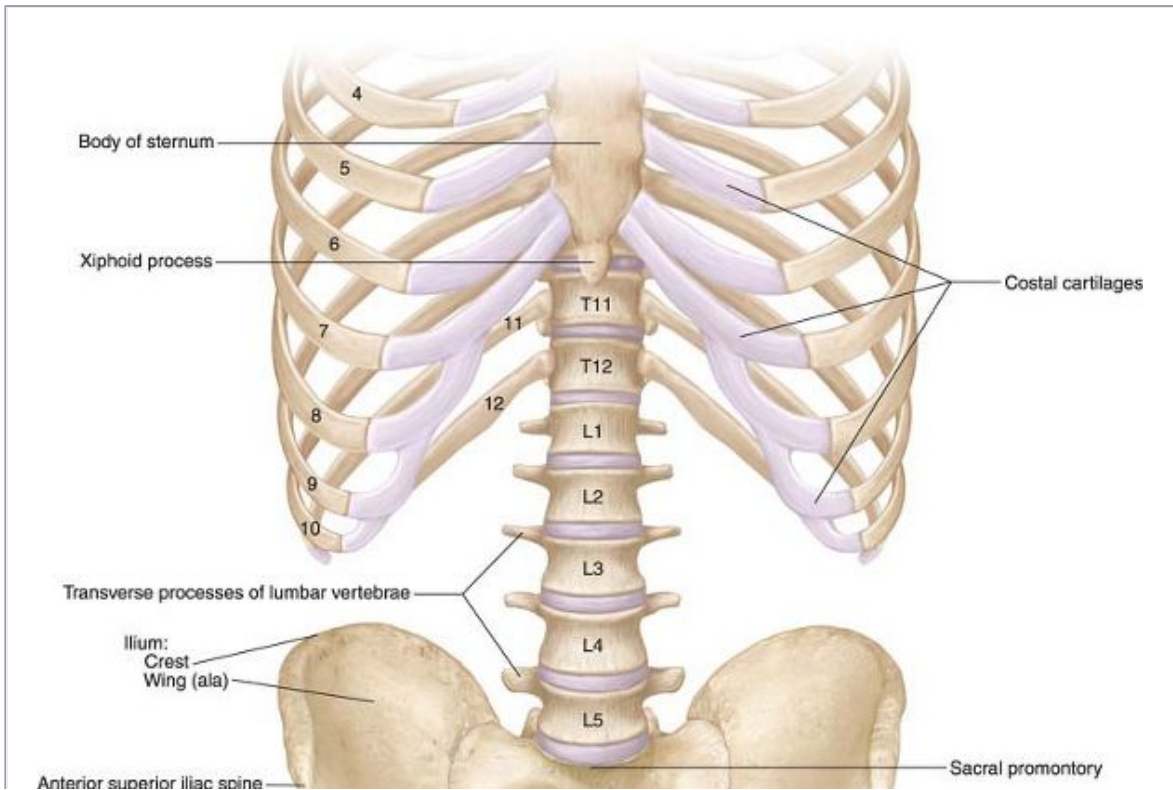
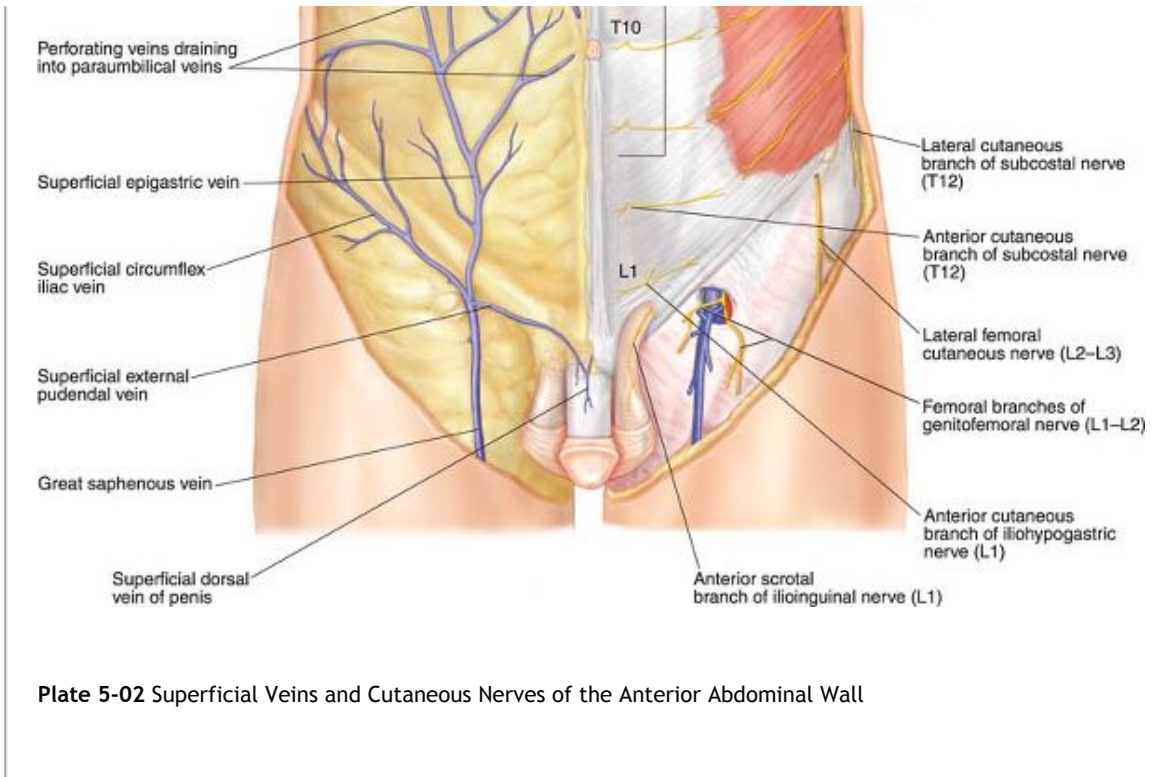
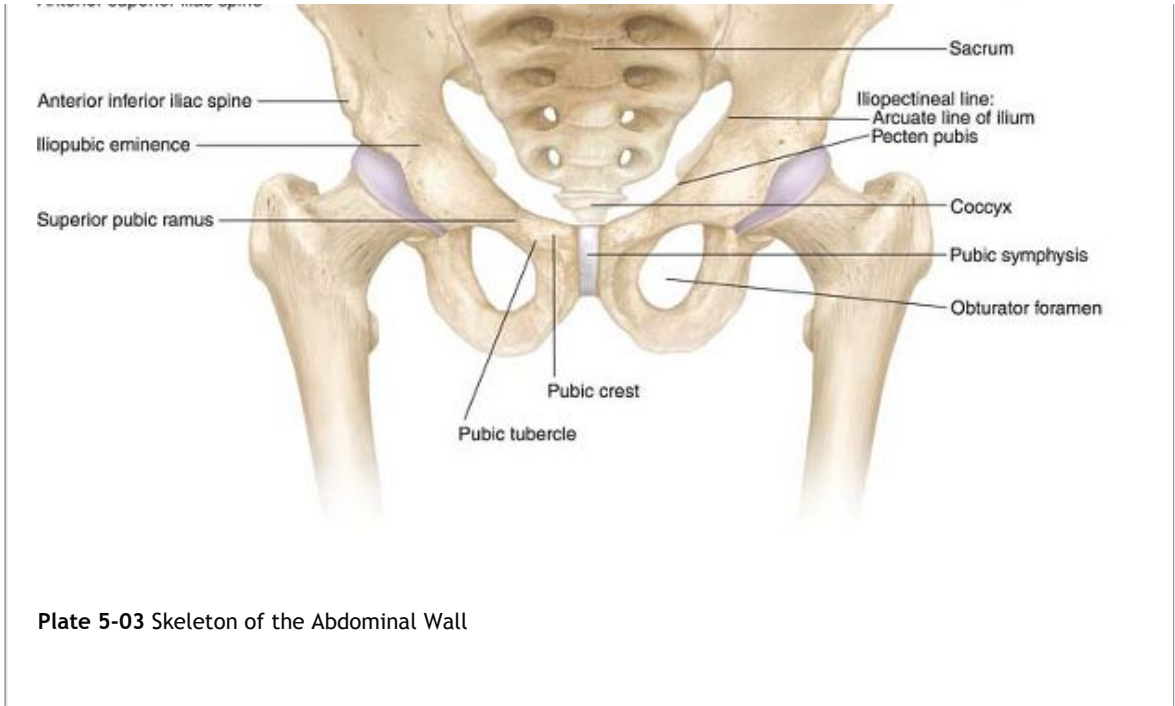


Plate 5-01 Palpable Features and Landmarks of the Abdomen







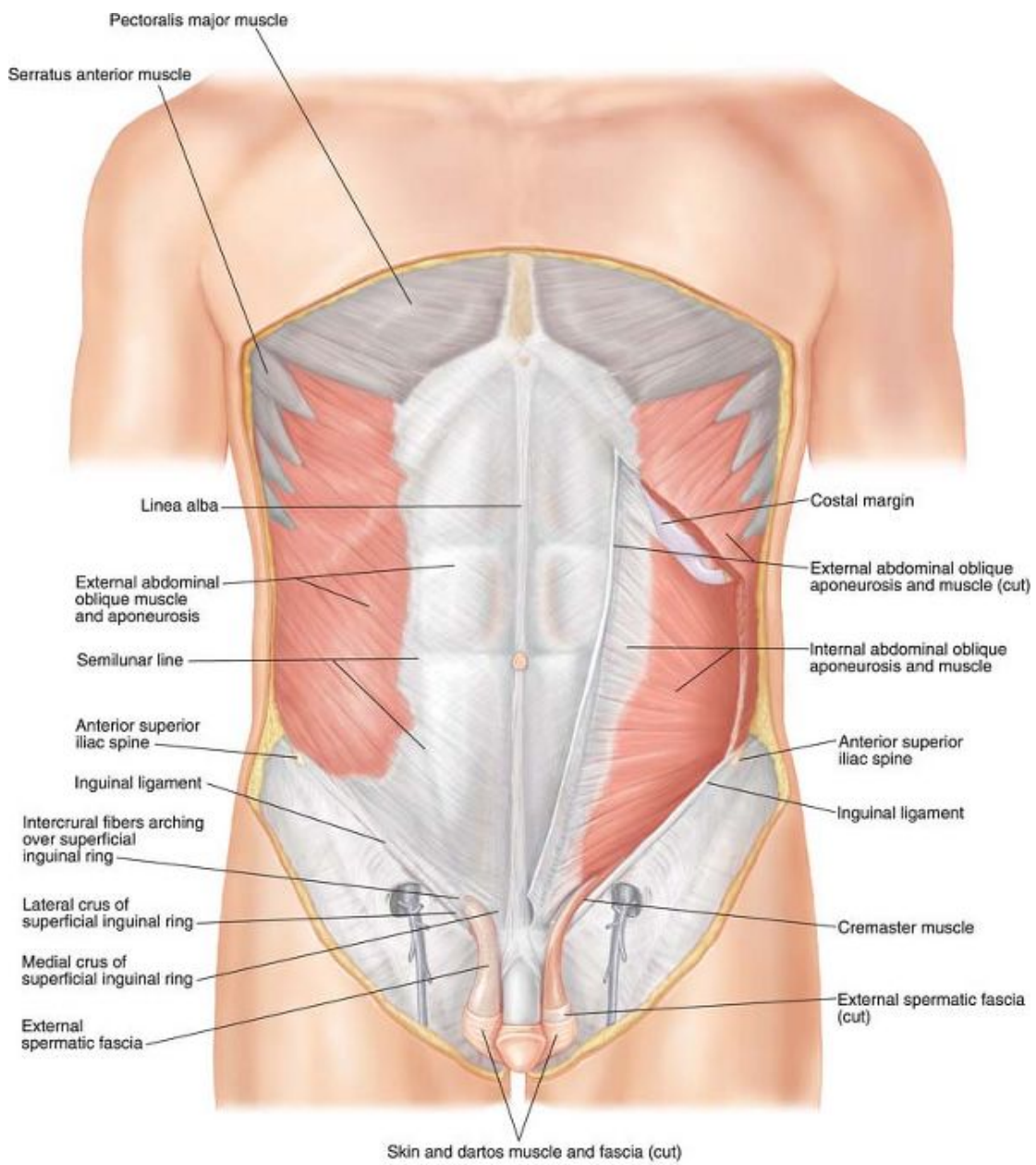


Plate 5-04 Muscles of the Anterior Abdominal Wall, Superficial Dissection

P.217

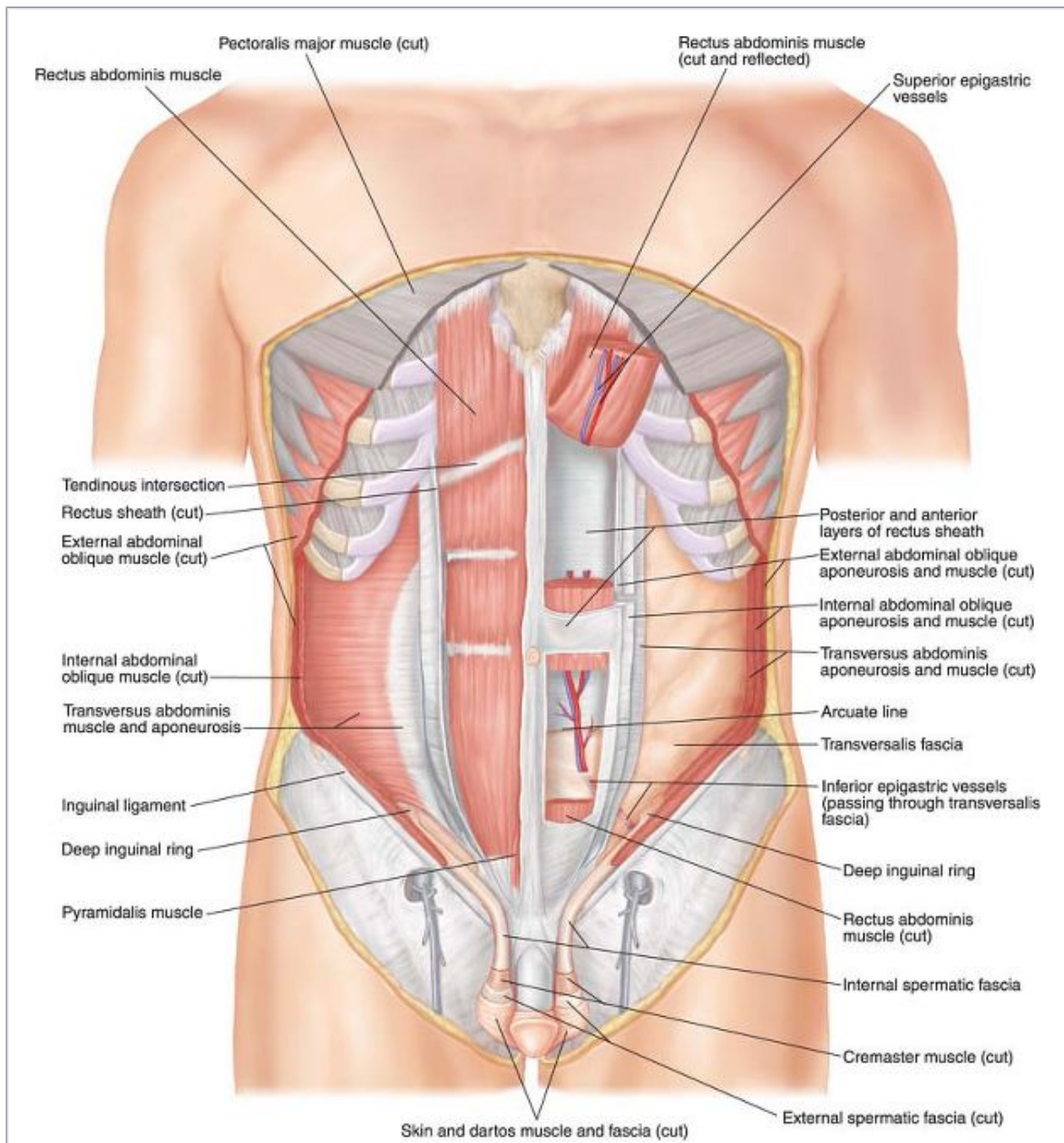
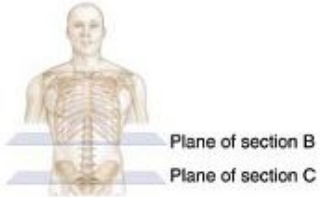
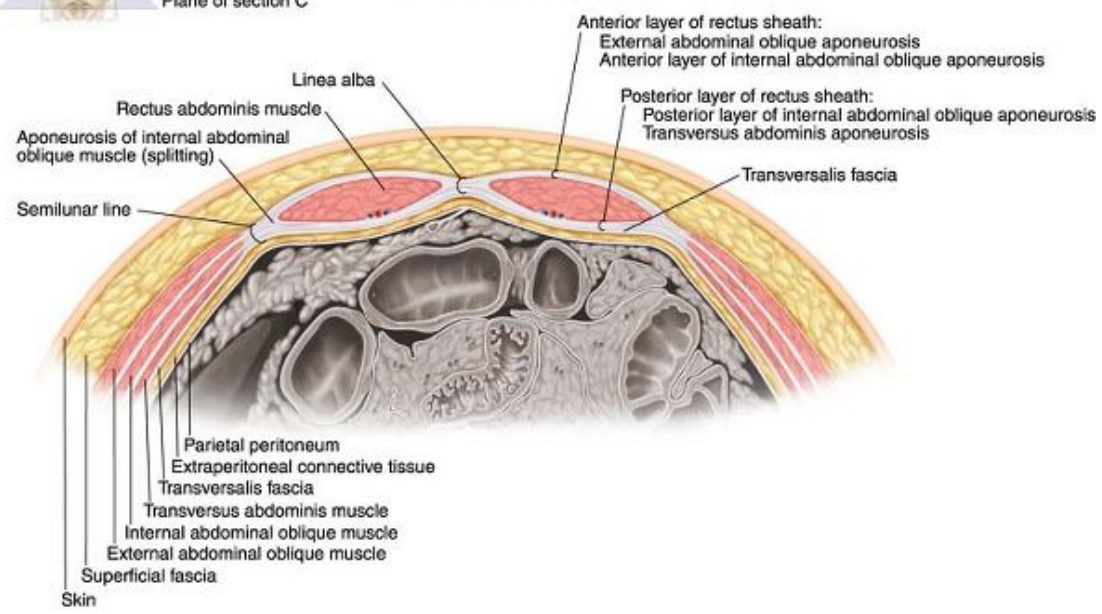


Plate 5-05 Muscles of the Anterior Abdominal Wall, Deep Dissection

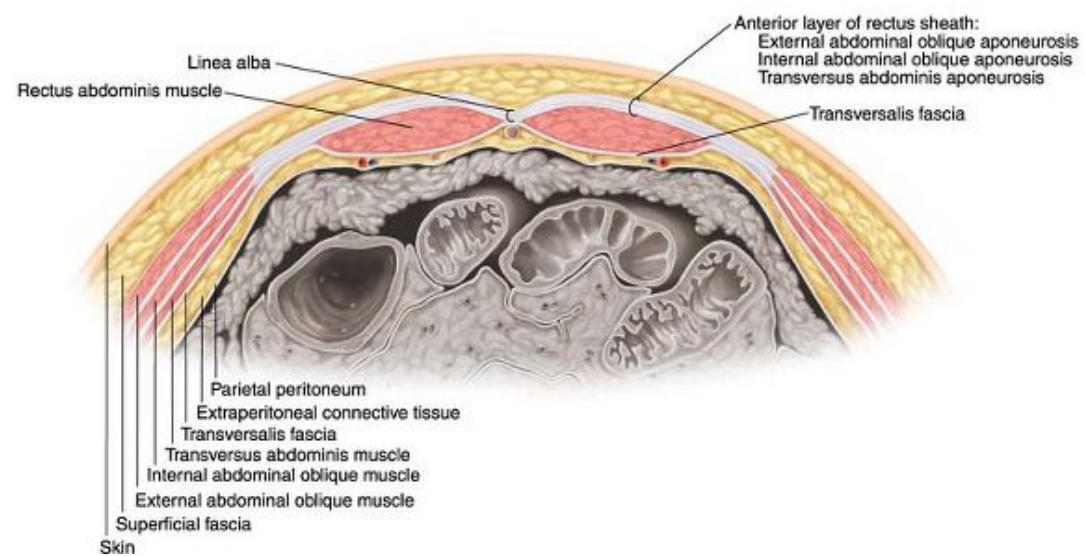
A. Orientation



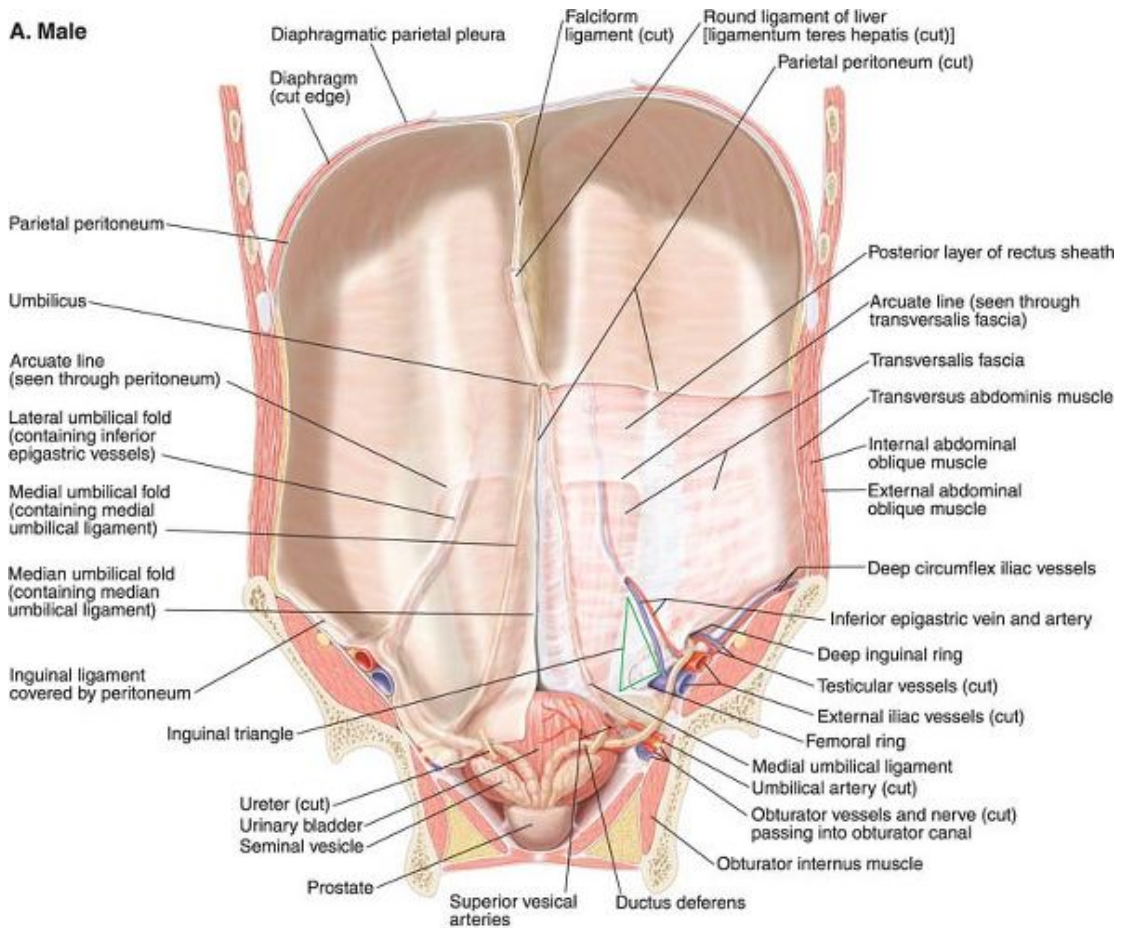
B. Cross section superior to arcuate line



C. Cross section inferior to arcuate line



A. Male



B. Female

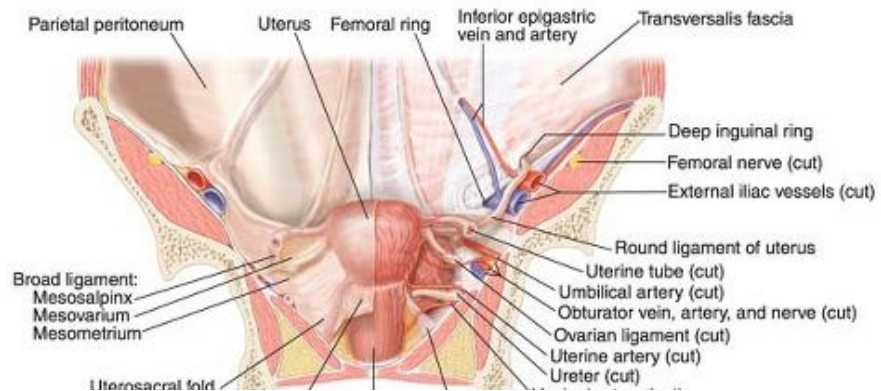
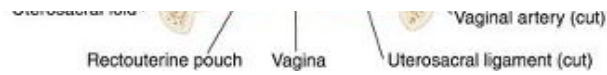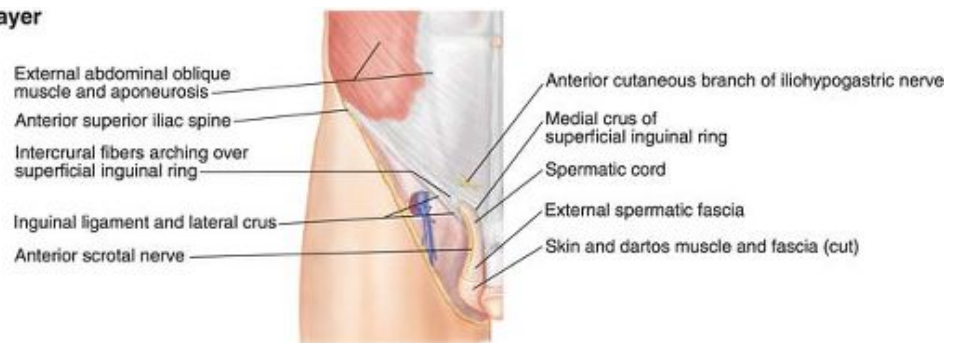


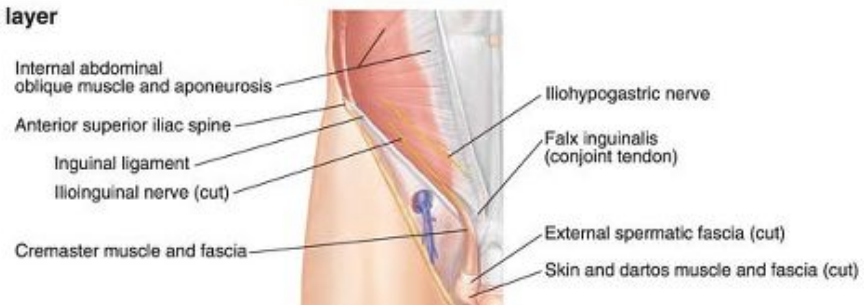


Plate 5-07 Anterior Abdominal Wall, Internal Features

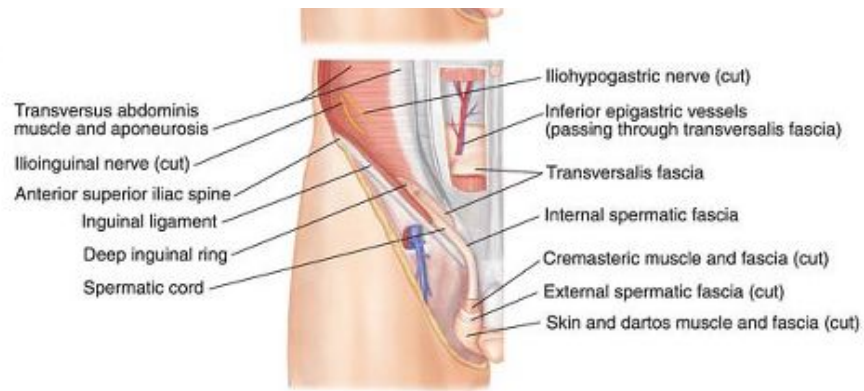
A. Superficial layer



B. Intermediate layer



C. Deep layer



D. Internal view

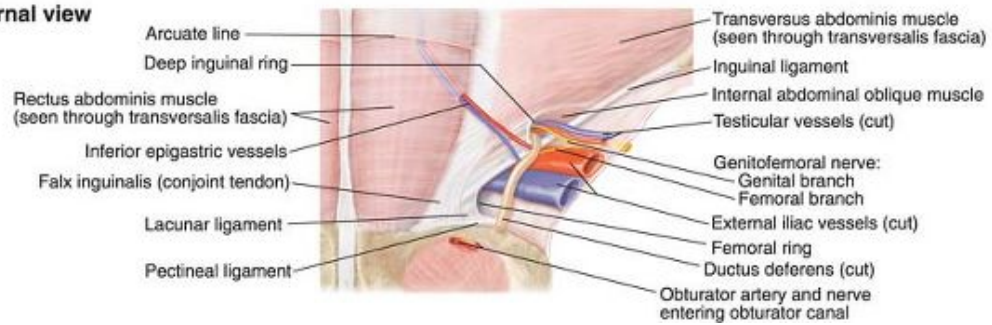
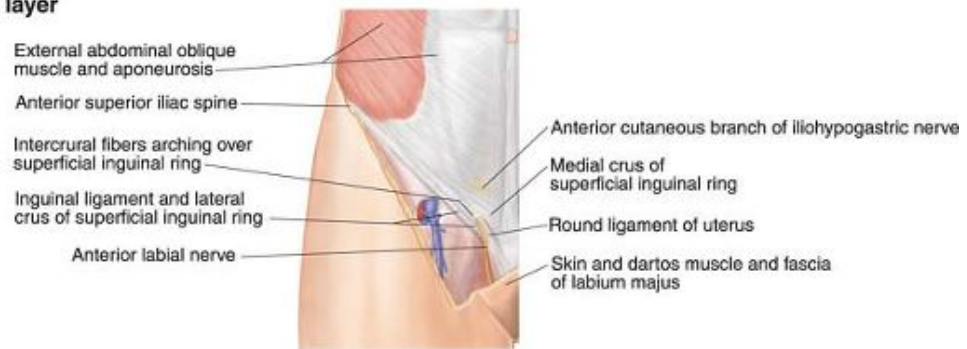
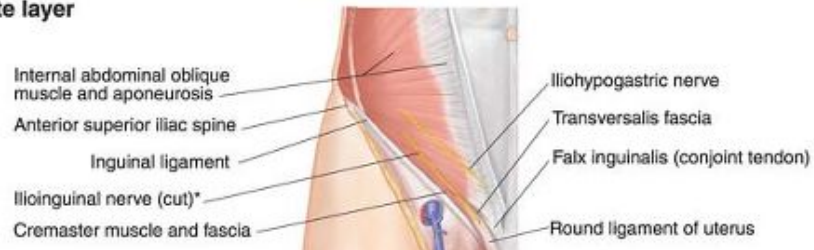


Plate 5-08 Inguinal Region, Male I

A. Superficial layer



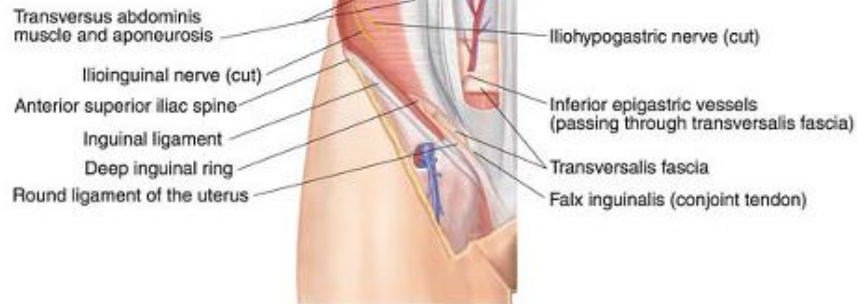
B. Intermediate layer



*Ilioinguinal nerve unites with genitofemoral nerve in 35% of cases



C. Deep layer



D. Internal view

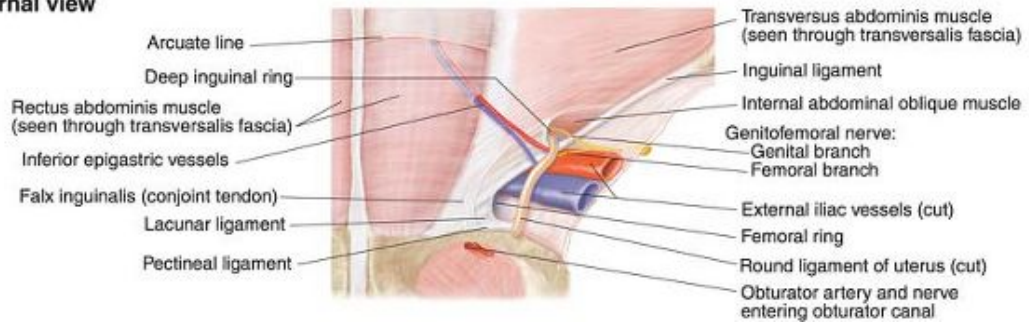
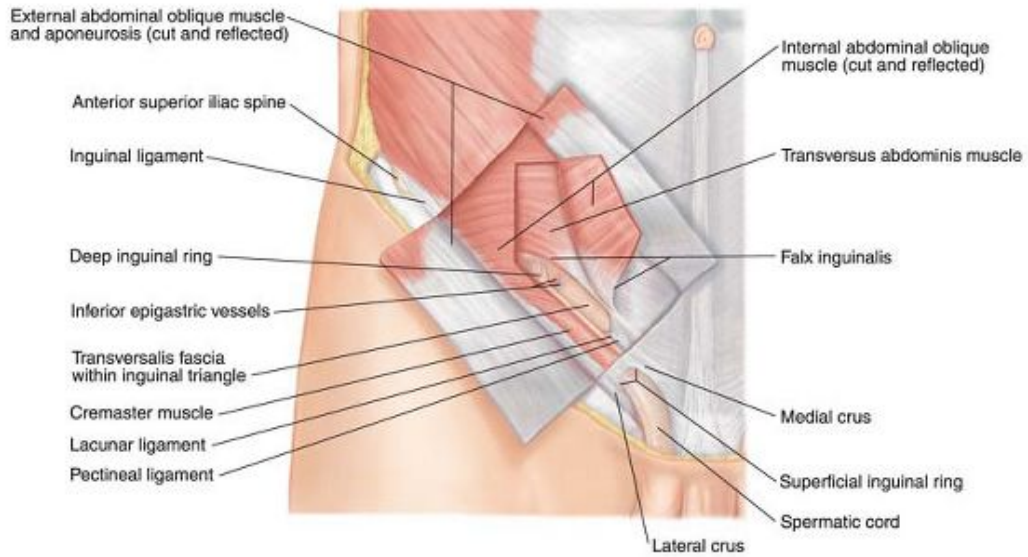
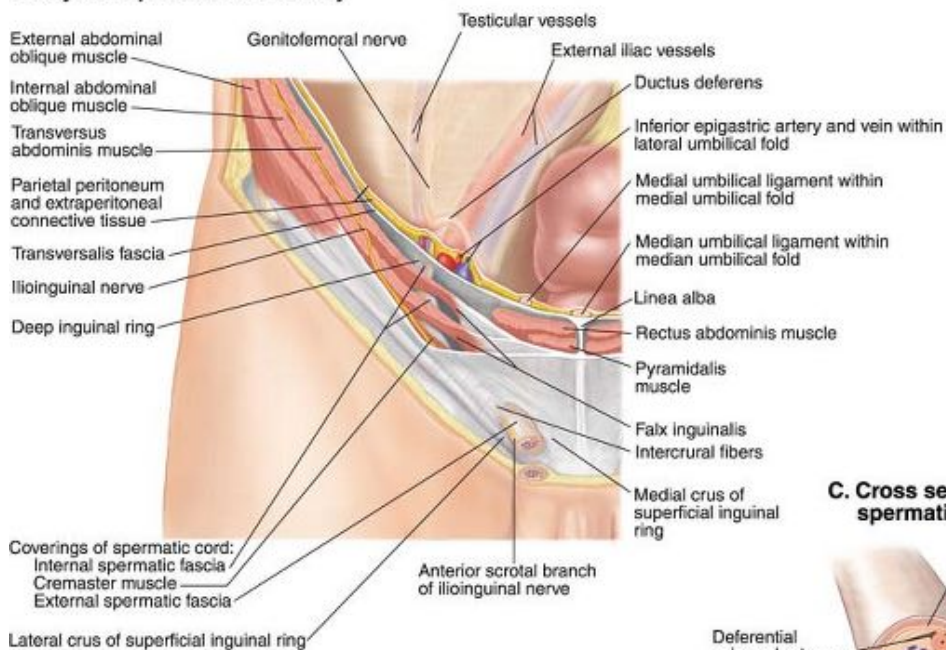


Plate 5-09 Inguinal Region, Female

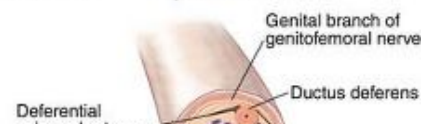A. Dissection



B. Layers separated for visibility



C. Cross section through spermatic cord



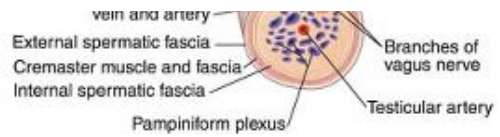
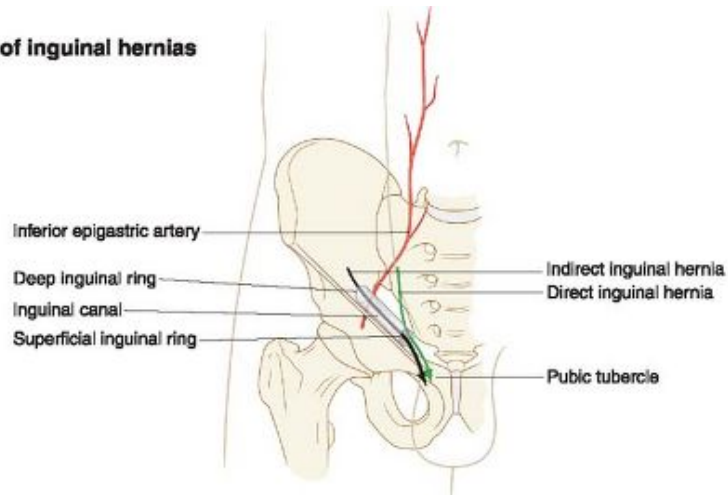
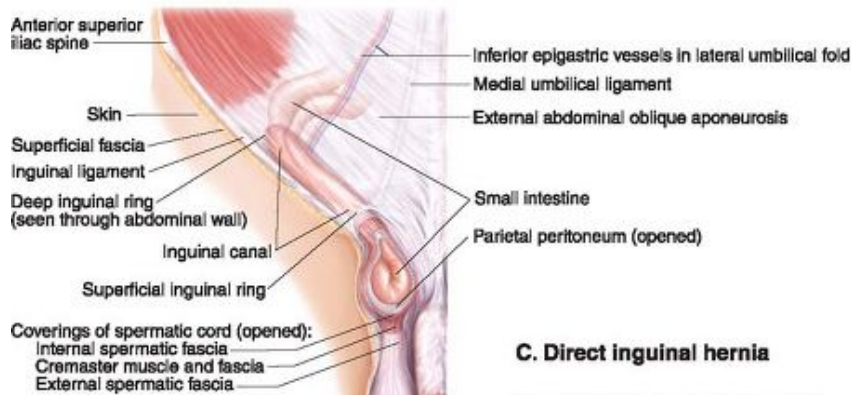


Plate 5-10 Inguinal Region, Male II

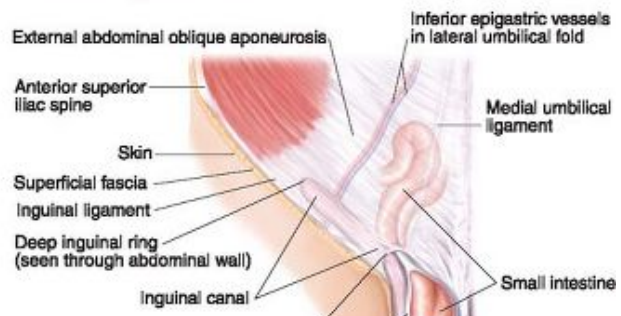
A. Surface projection of inguinal hernias



B. Indirect inguinal hernia



C. Direct inguinal hernia



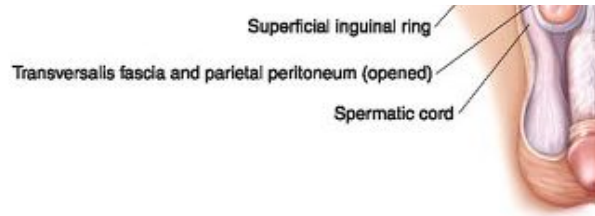
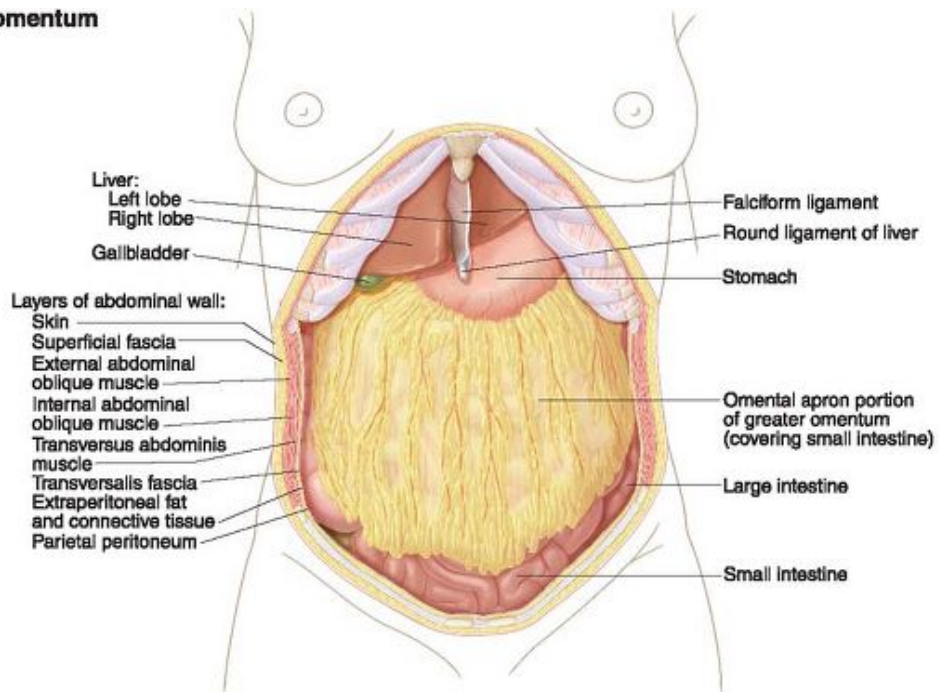
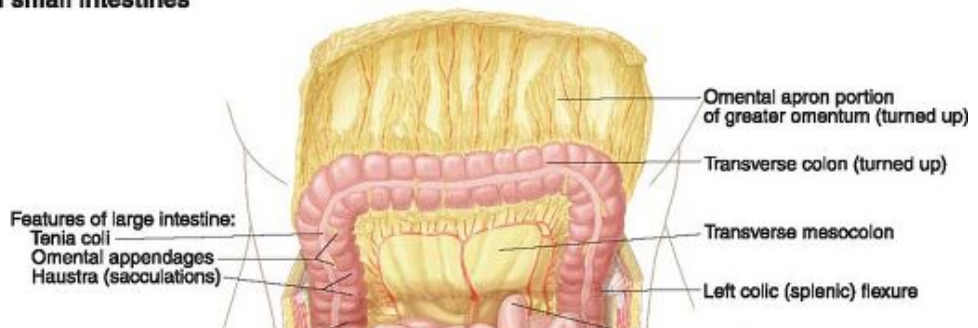


Plate 5-11 Inguinal Hernias

A. Greater omentum



B. Large and small intestines



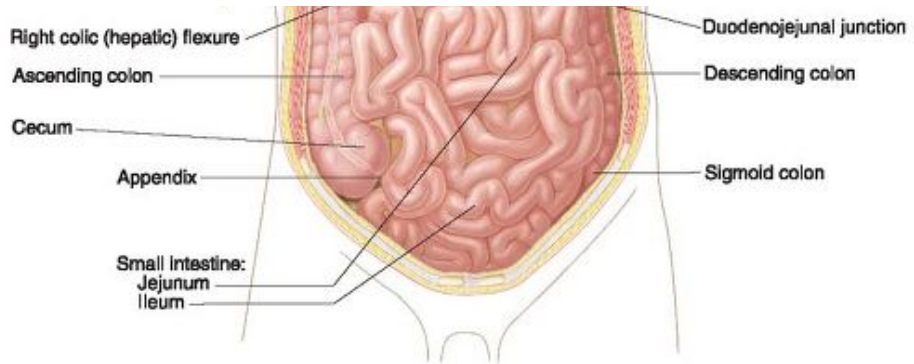
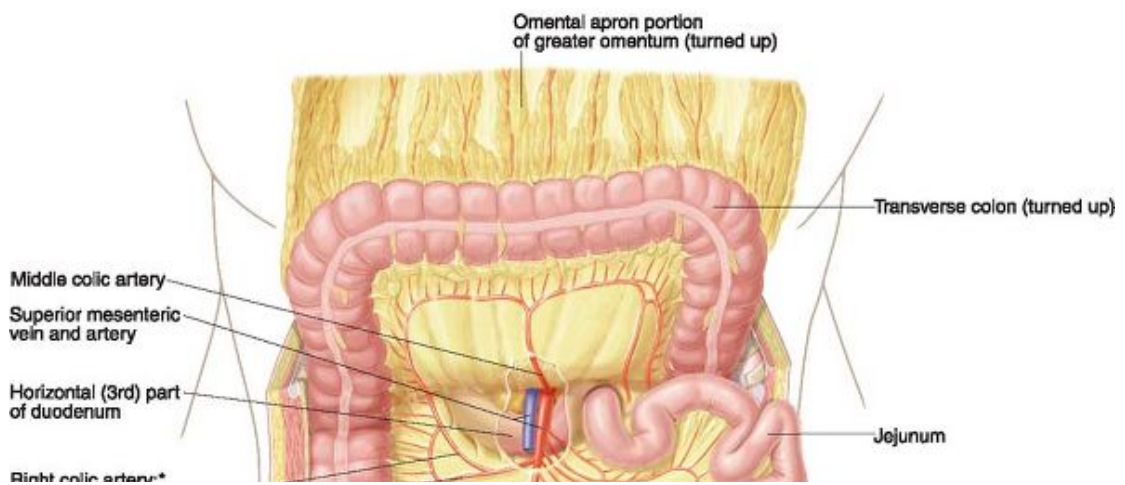
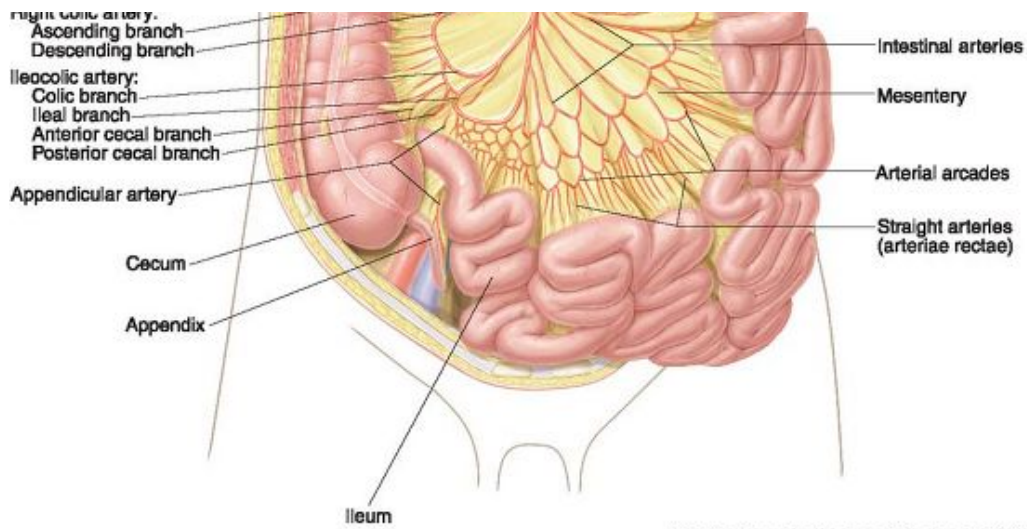


Plate 5-12 Peritoneum and Peritoneal Cavity

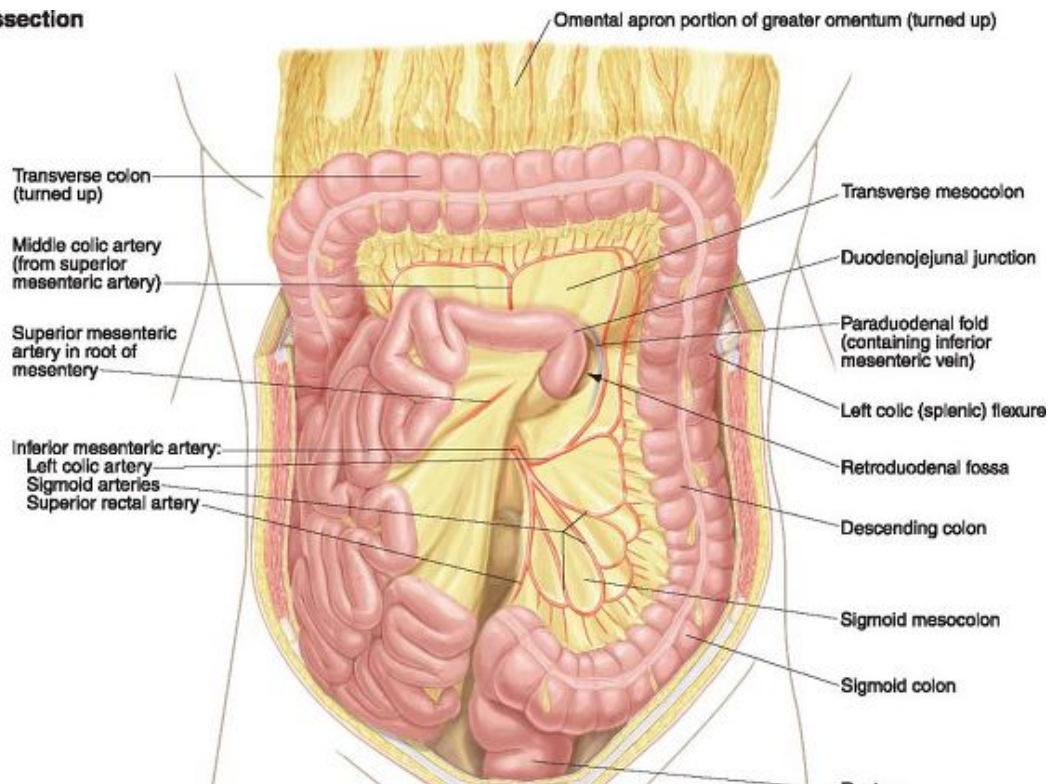




*Right colic artery is absent in about 13% of cases and arises from either the ileocolic artery or middle colic artery in 50% of cases

Plate 5-13 Superior Mesenteric Artery

A. Dissection



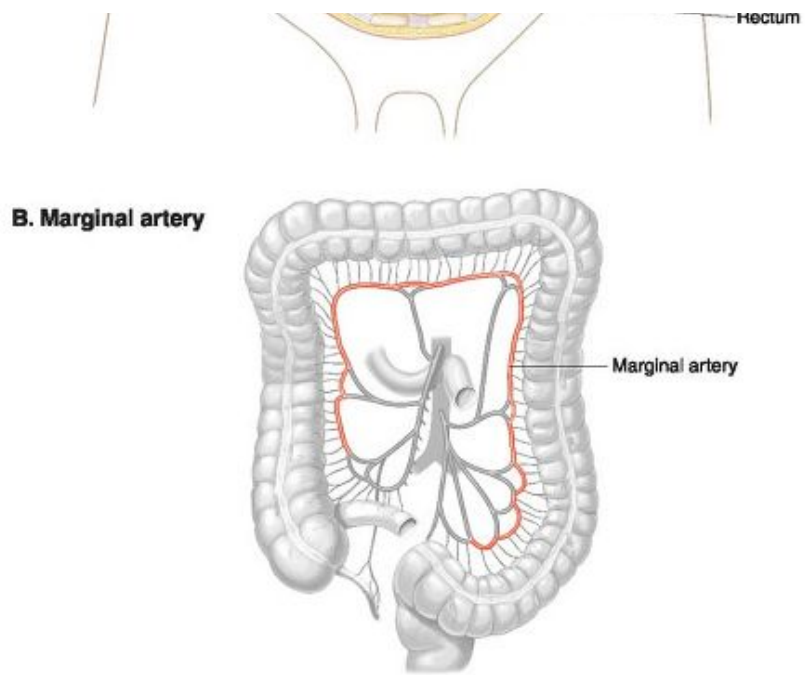
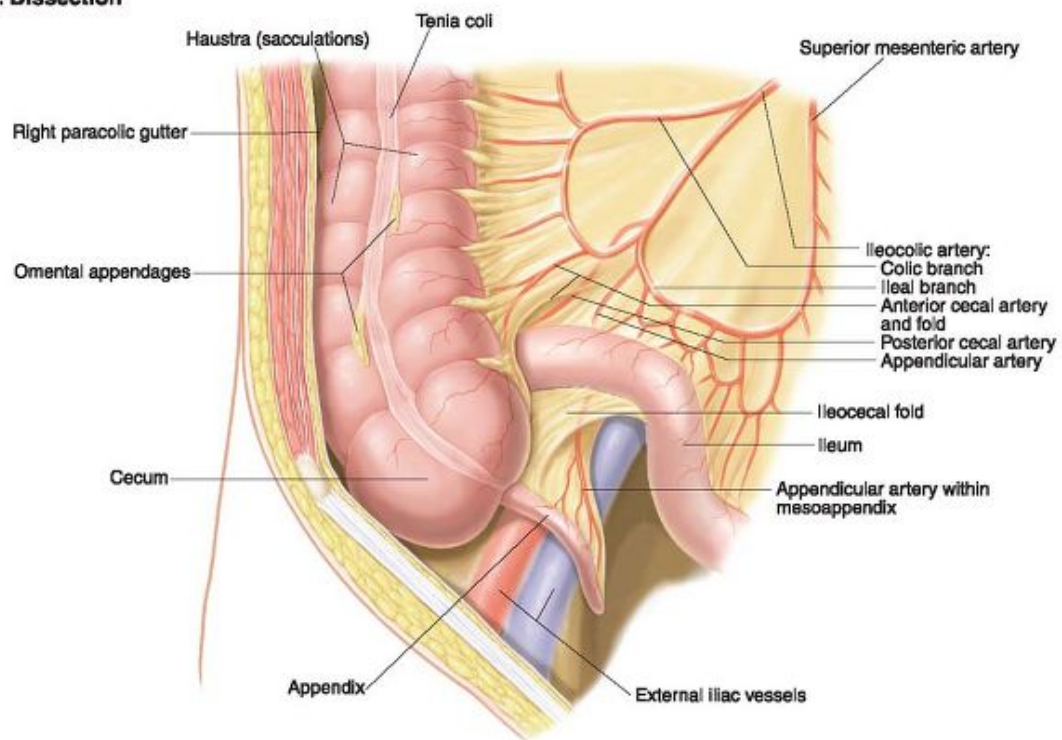
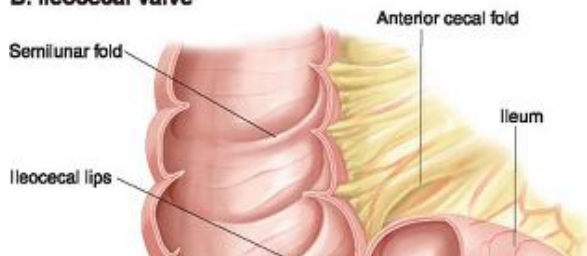

Plate 5-14 Inferior Mesenteric Artery

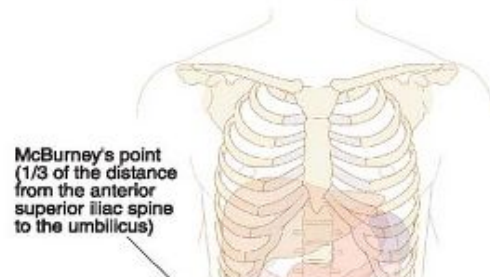
A. Dissection



B. Ileocecal valve



C. Location of appendix



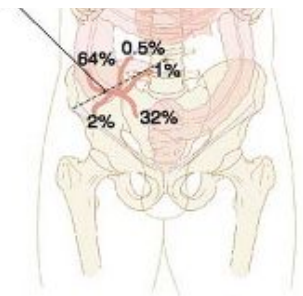
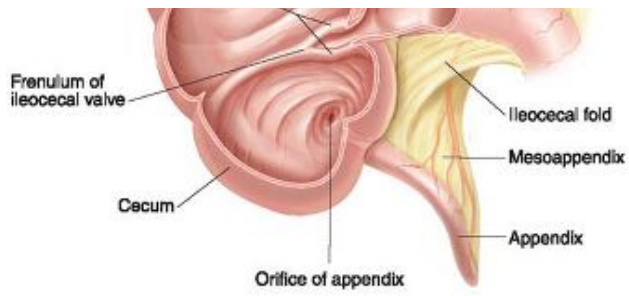
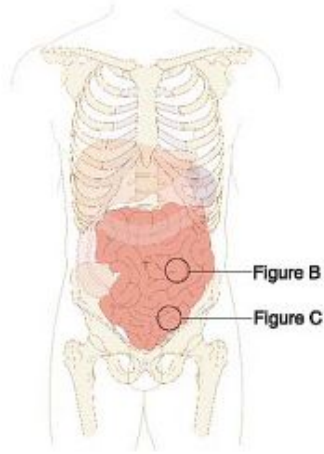
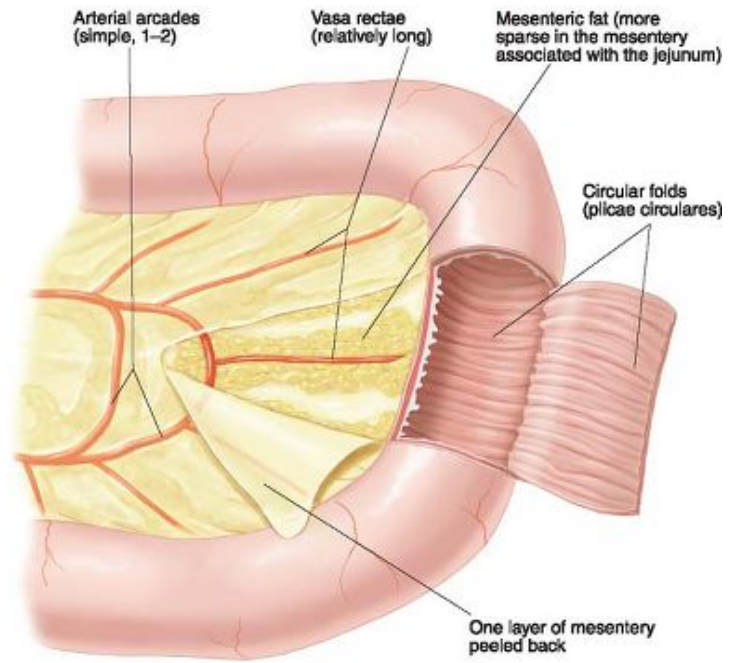


Plate 5-15 Cecum and Appendix

A. Orientation



B. Jejunum



C. Ileum

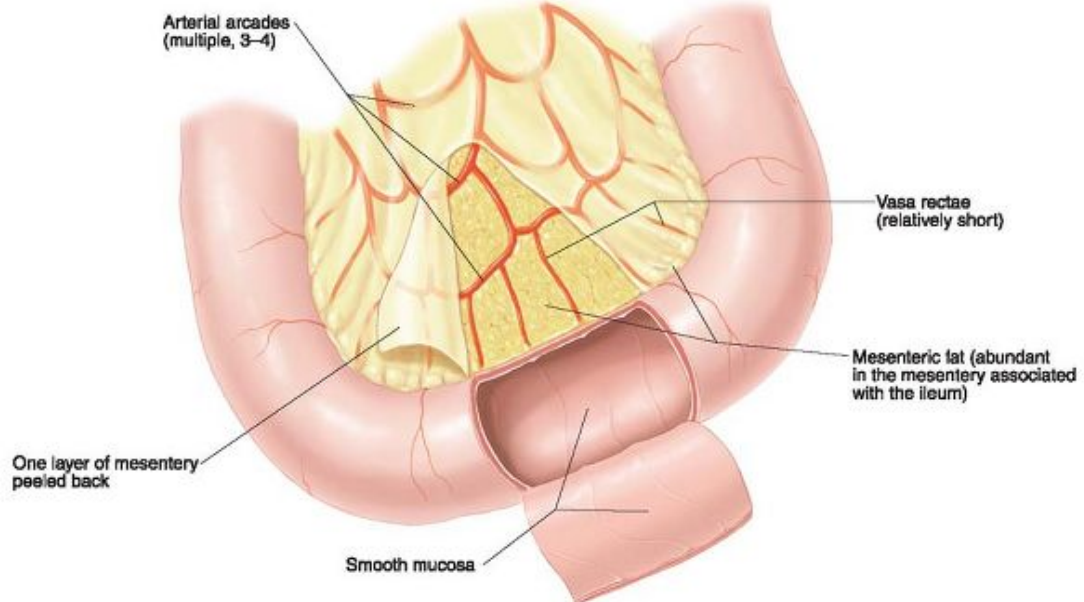
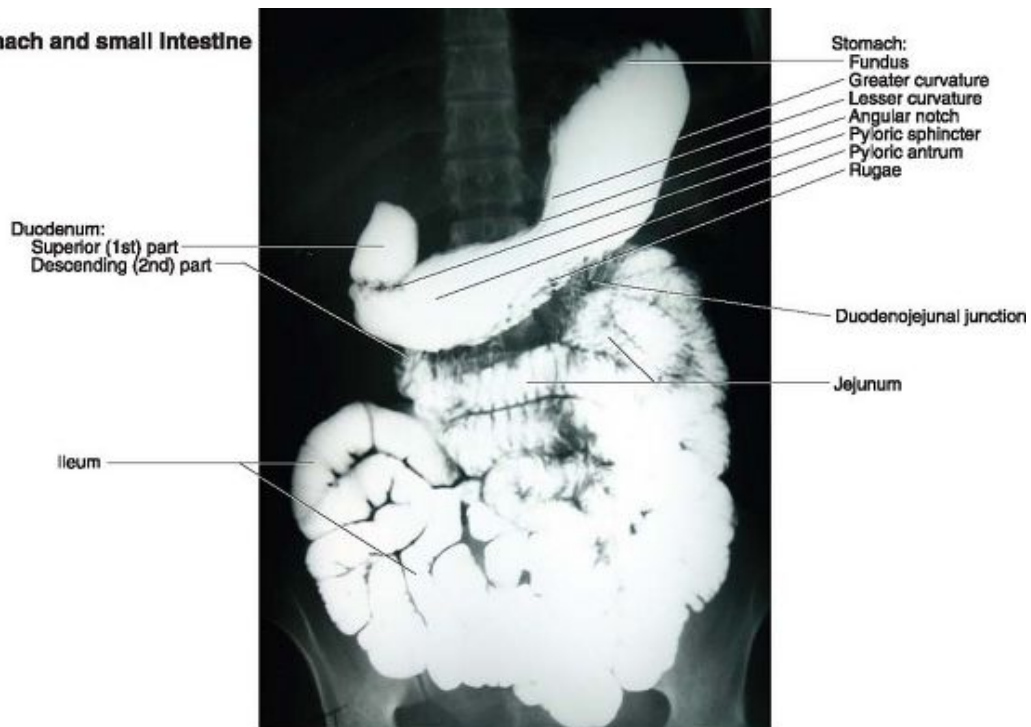
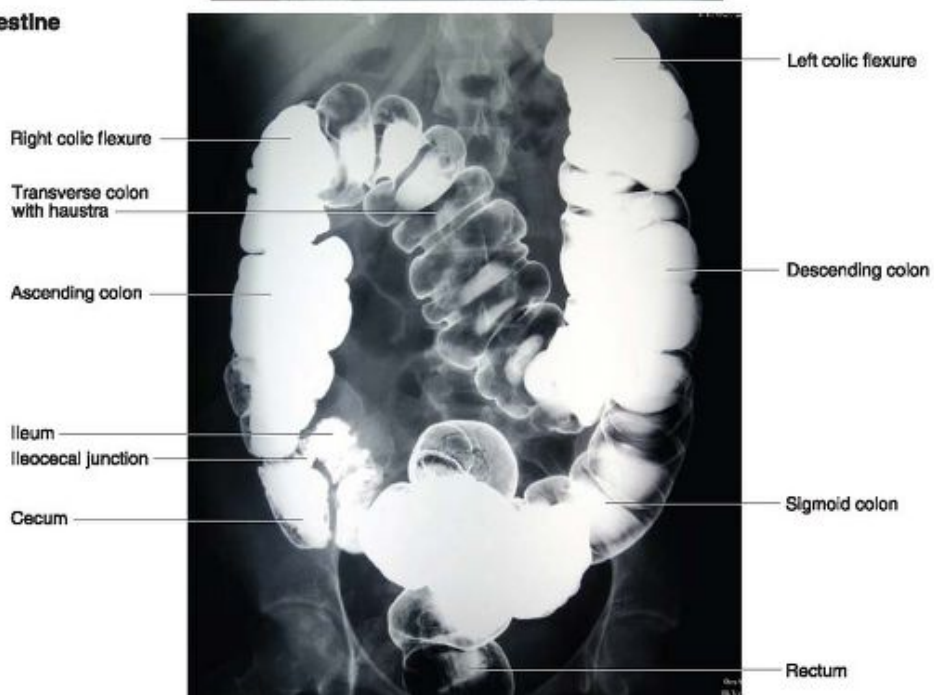


Plate 5-16 Jejunum and Ileum

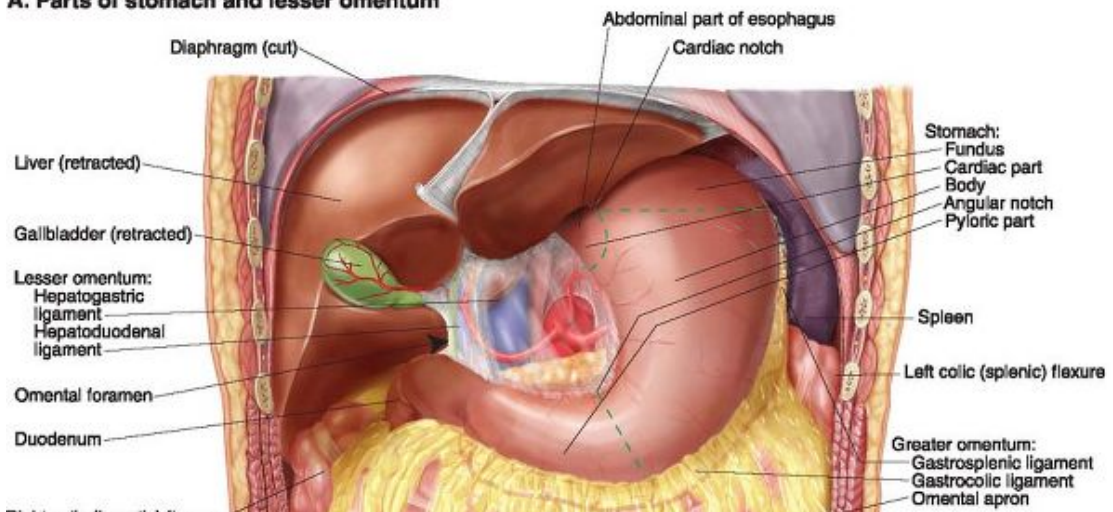
A. Stomach and small Intestine



B. Large Intestine



A. Parts of stomach and lesser omentum



Right colic (hepatic) flexure



B. Omental bursa (lesser peritoneal sac)

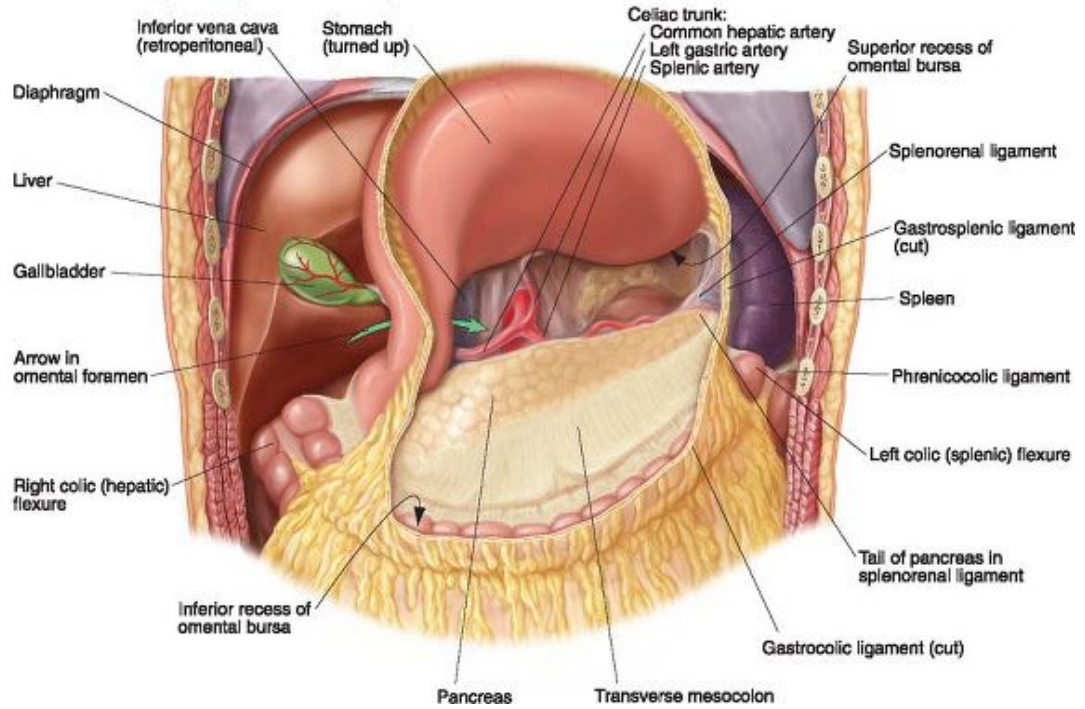
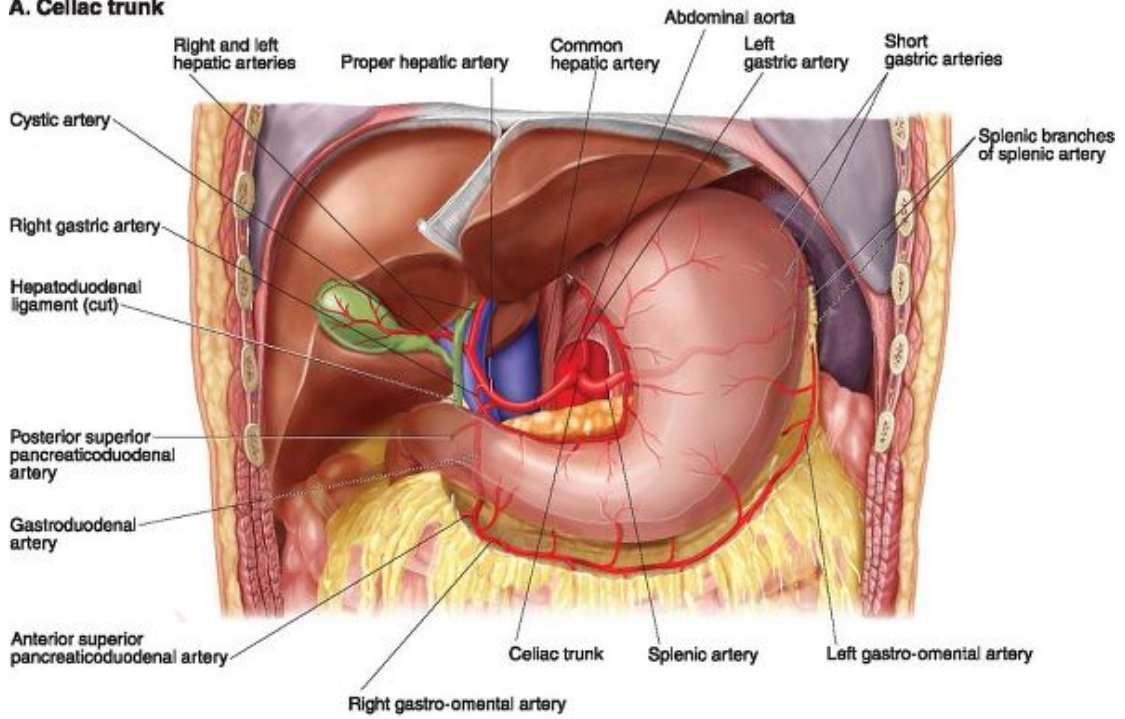
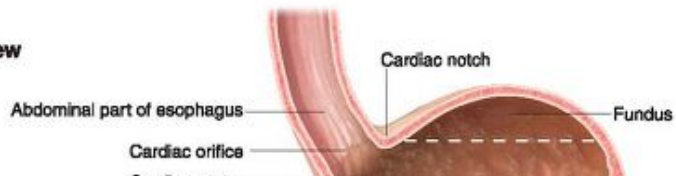

Plate 5-18 Stomach and Lesser Omentum

A. Celiac trunk



B. Stomach, internal view



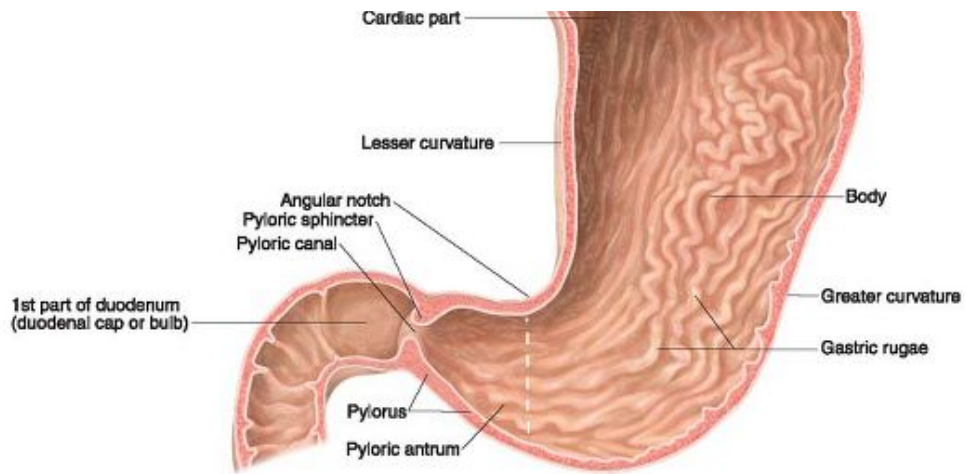
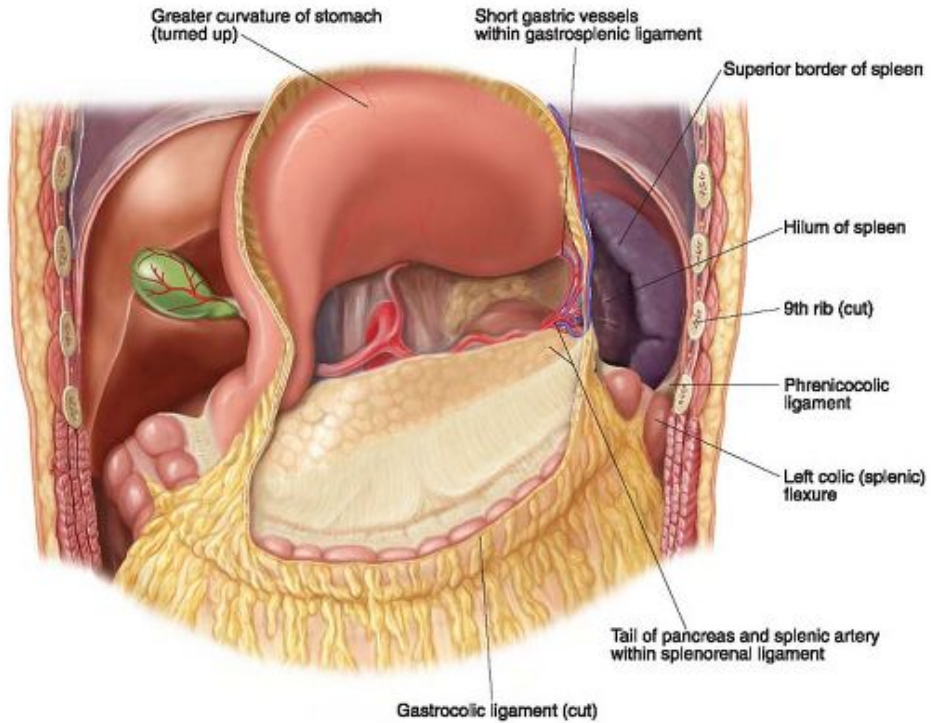
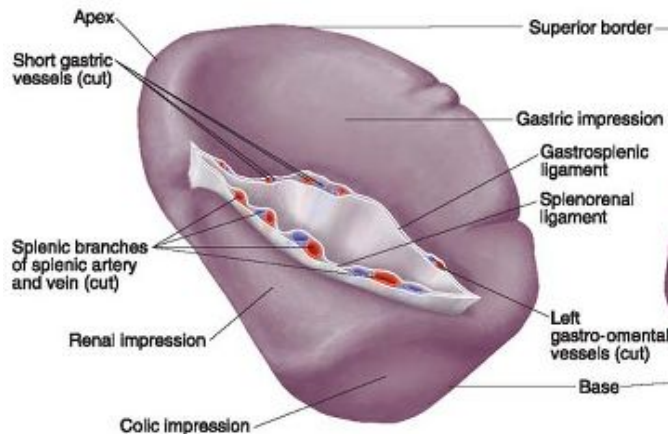


Plate 5-19 Celiac Trunk and Stomach

A. Dissection



B. Visceral surface



C. Diaphragmatic surface

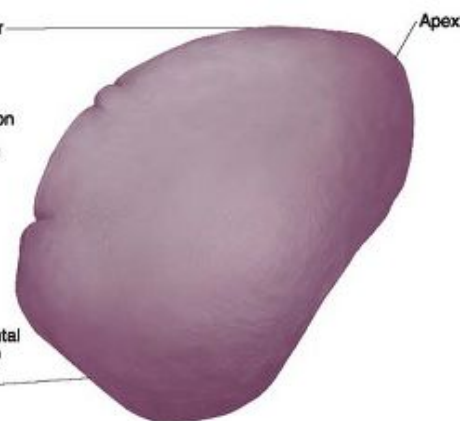
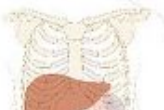
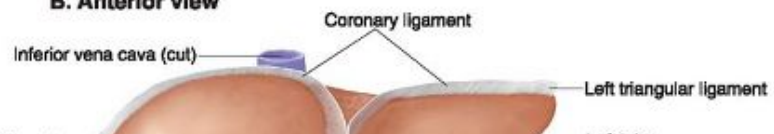
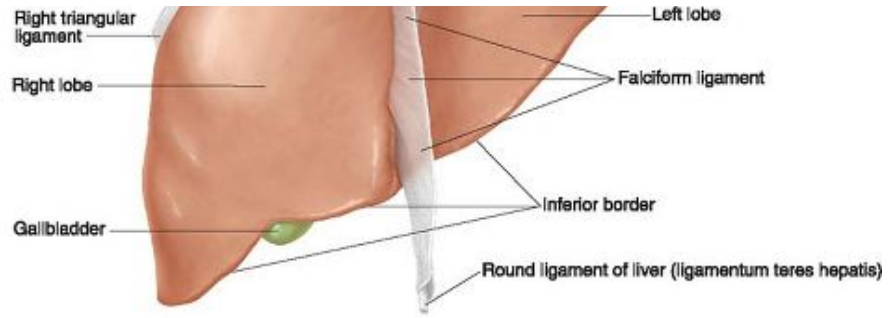
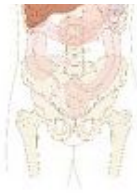Plate 5-20 Spleen

A. Orientation

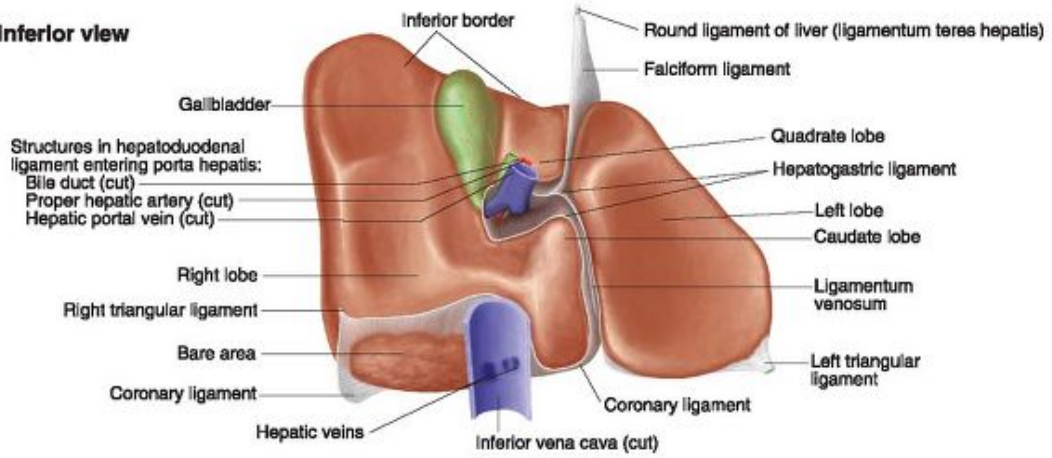


B. Anterior view





C. Inferior view



D. Superior view

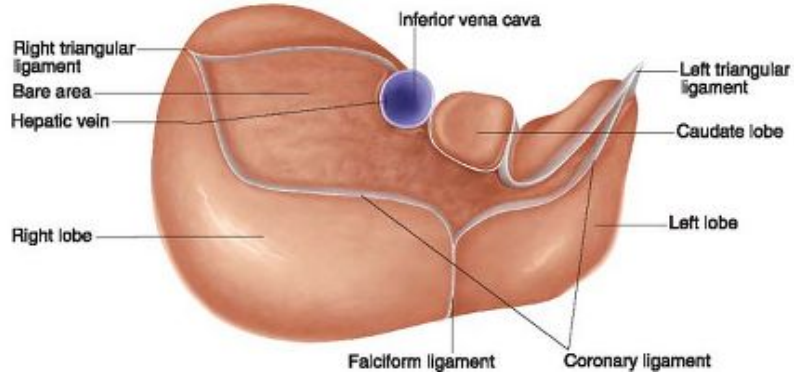
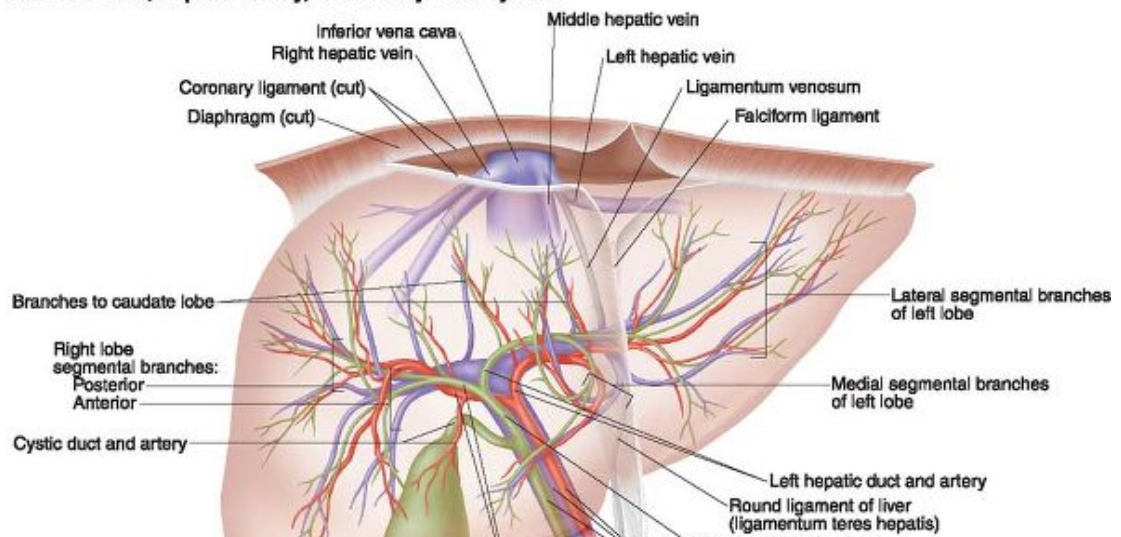
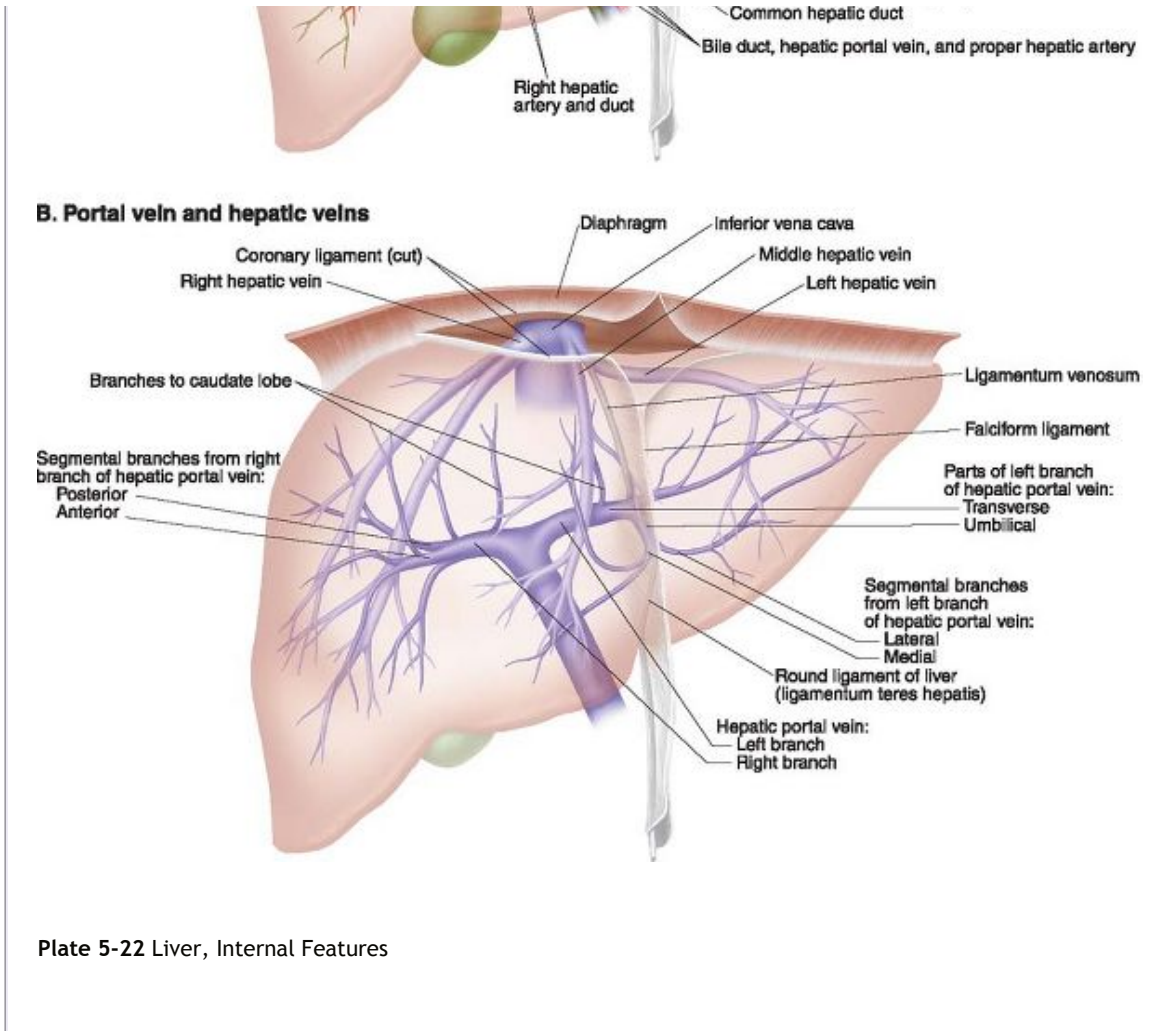


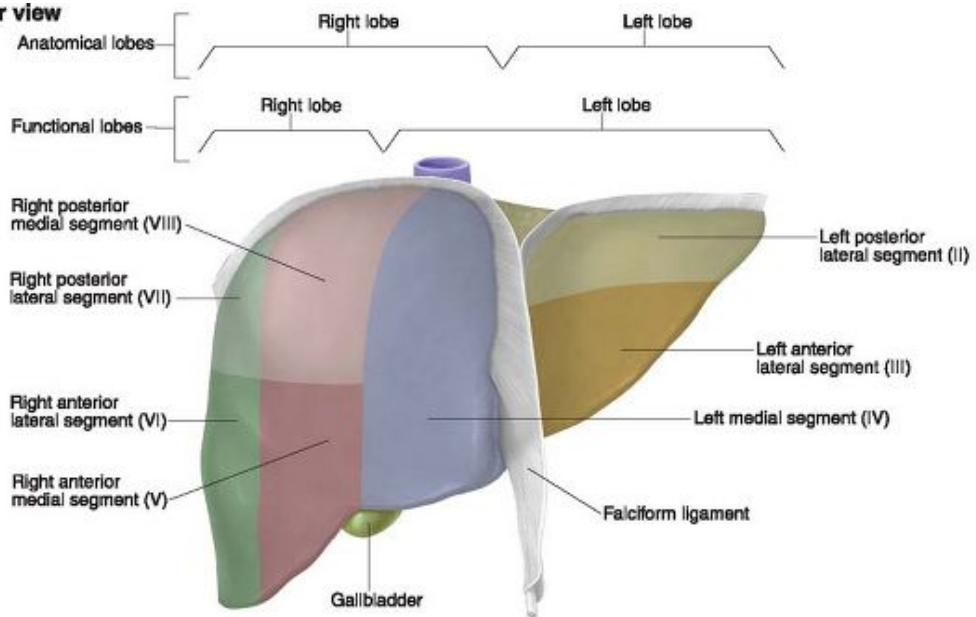
Plate 5-21 Liver

A. Portal vein, hepatic artery, and biliary duct system

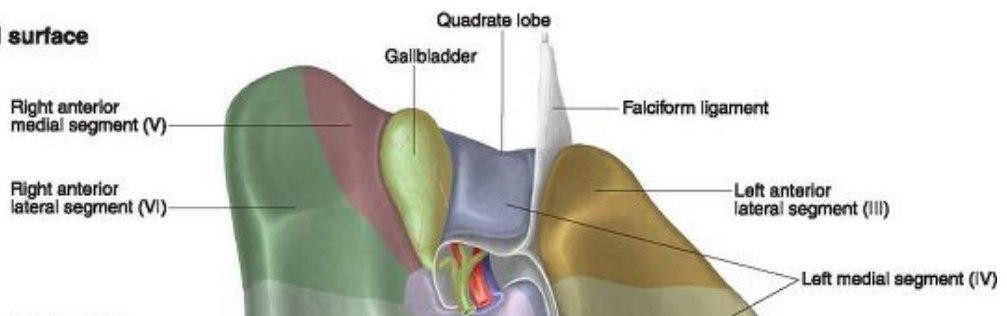




A. Anterior view



B. Visceral surface



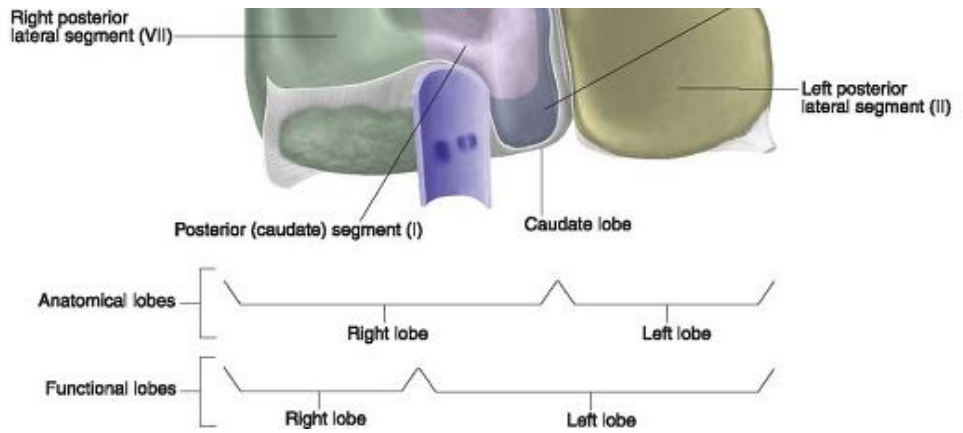
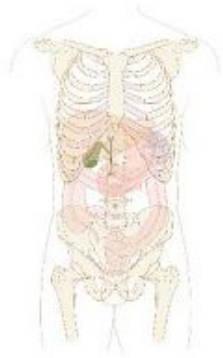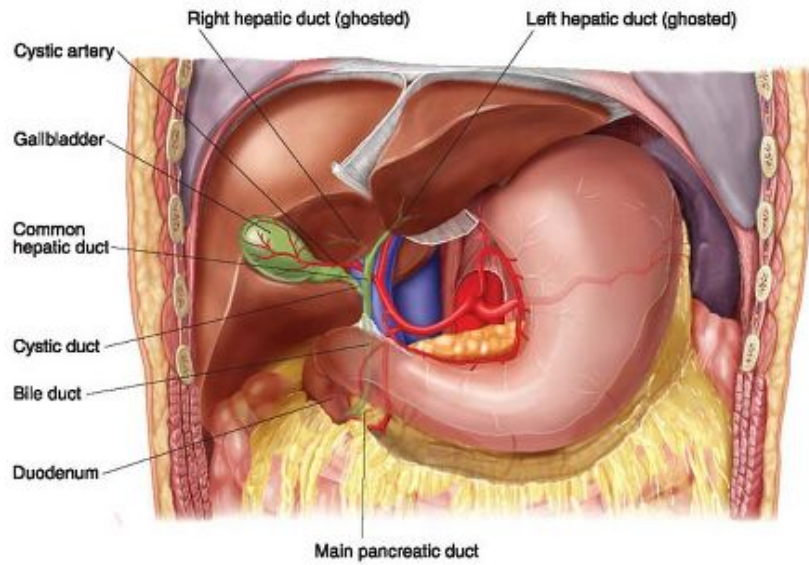


Plate 5-23 Liver Lobes and Segments

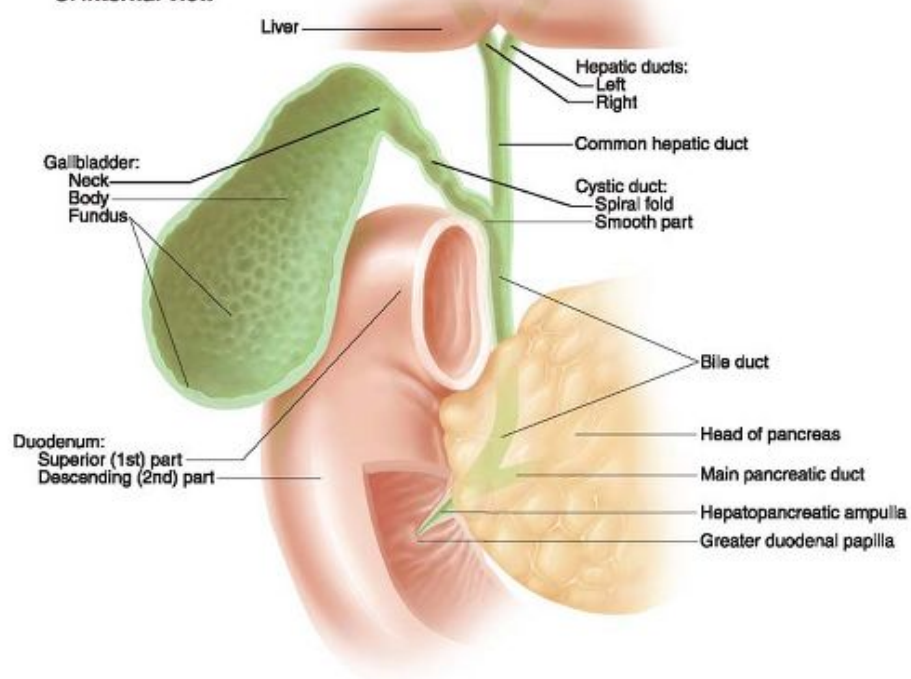
A. Orientation



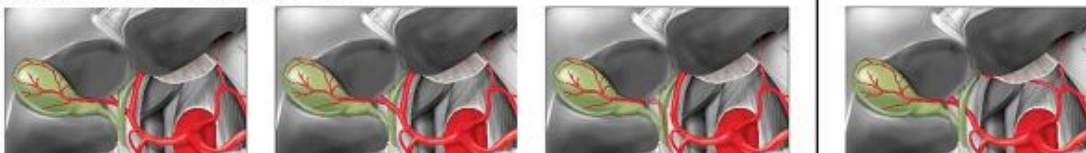
B. Dissection



C. Internal view



A. Variations in the hepatic arteries

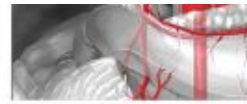



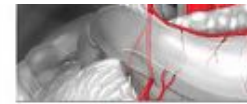
Right and left hepatic arteries arising from proper hepatic artery; right hepatic artery passing posterior to common hepatic duct (64%)



Right hepatic artery passing anterior to common hepatic duct (24%)

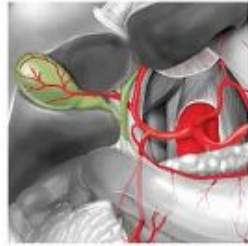

Right hepatic artery arising from superior mesenteric artery (12%)

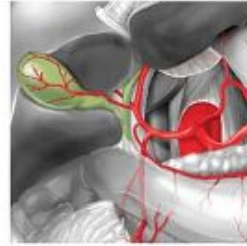


Left hepatic artery arising from left gastric artery (11%)

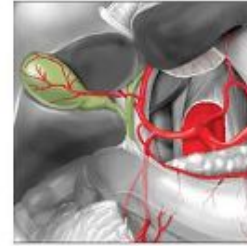B. Variations in the cystic artery



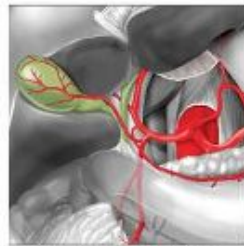Cystic artery arising from right hepatic artery and passing posterior to common hepatic duct (76%)



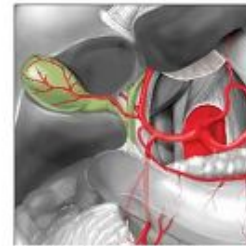
Cystic artery arising from right hepatic artery and passing anterior to common hepatic duct (13%)



Cystic artery arising from left hepatic artery and passing anterior to common hepatic duct (6%)



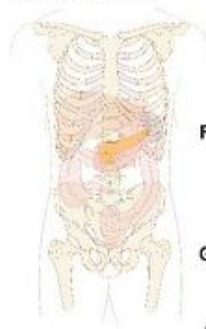Cystic artery arising from gastroduodenal artery and passing anterior to common hepatic duct (3%)



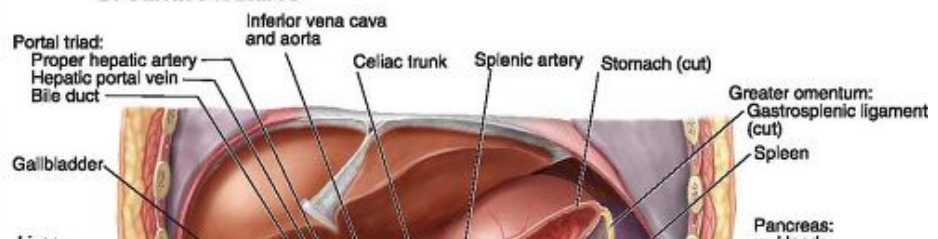
Cystic artery arising from proper hepatic artery and passing anterior to common hepatic duct (2%)

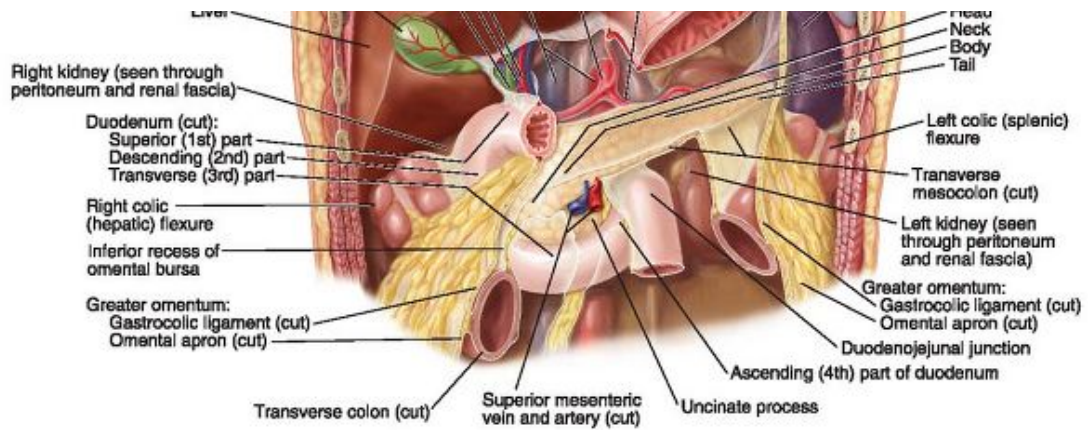
Plate 5-25 Variations in Blood Supply to the Liver and Gallbladder

A. Orientation



B. Surface features





C. Dissection

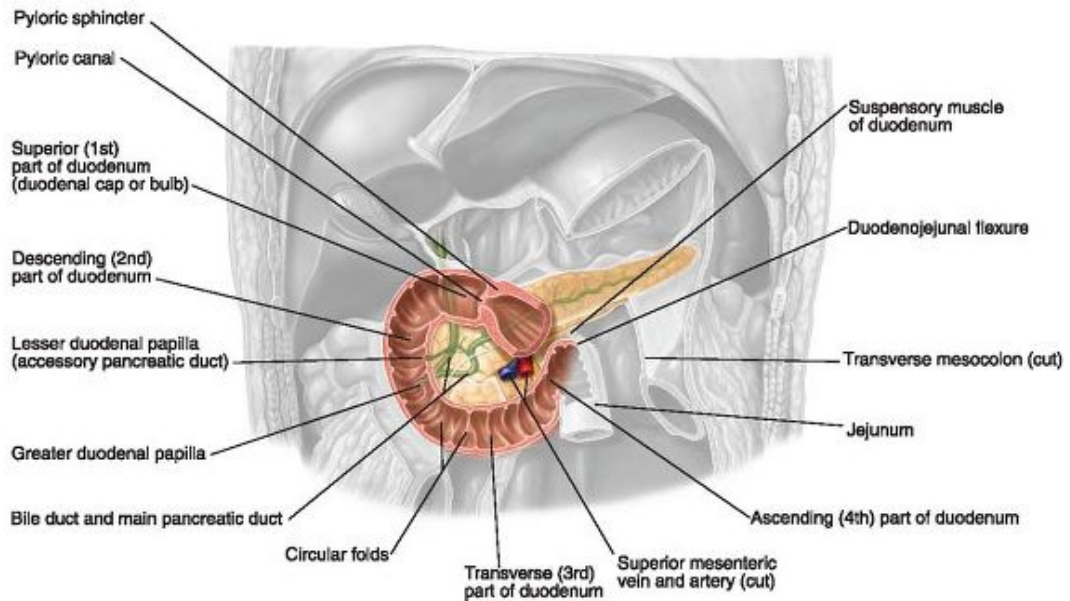
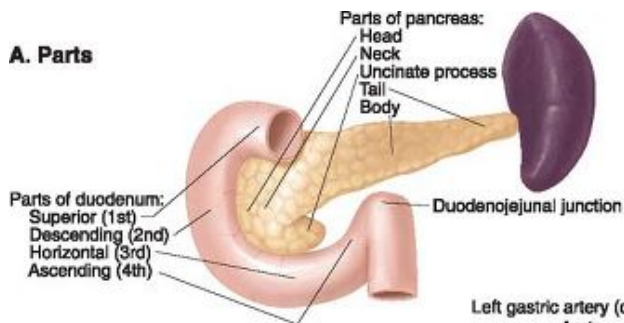
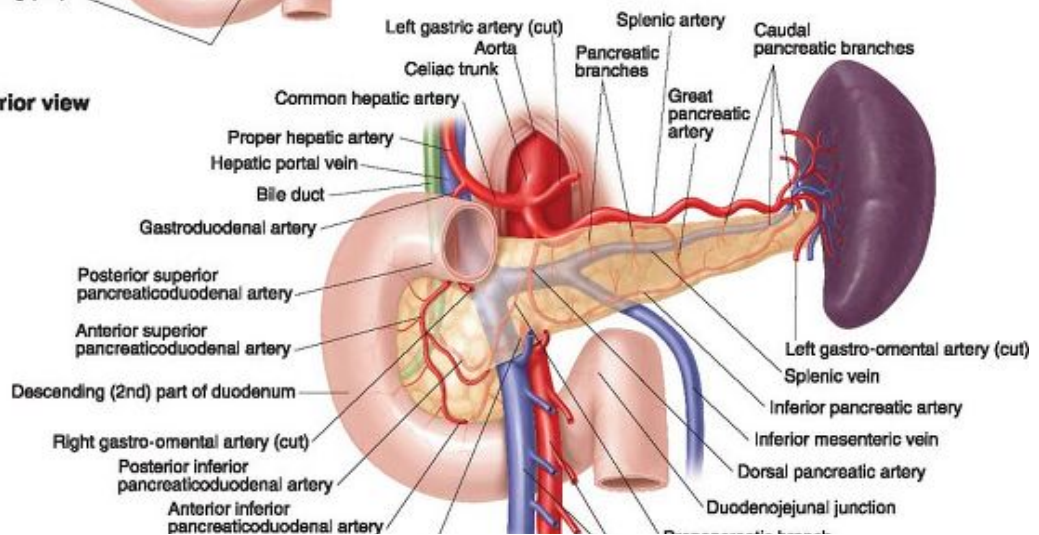


Plate 5-26 Duodenum and Pancreas I

A. Parts



B. Anterior view



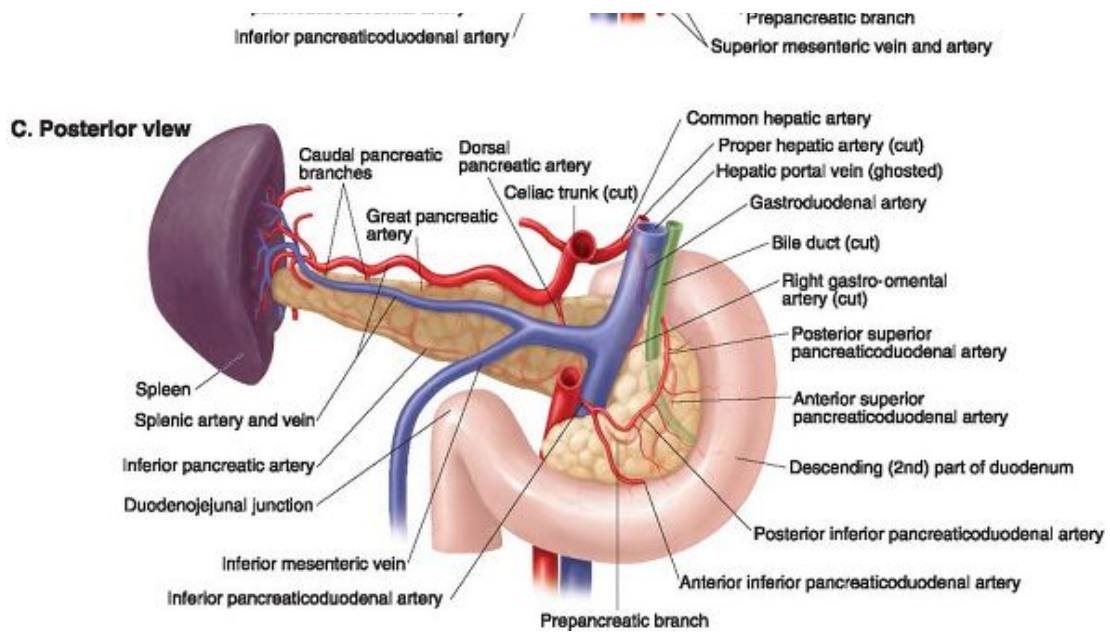
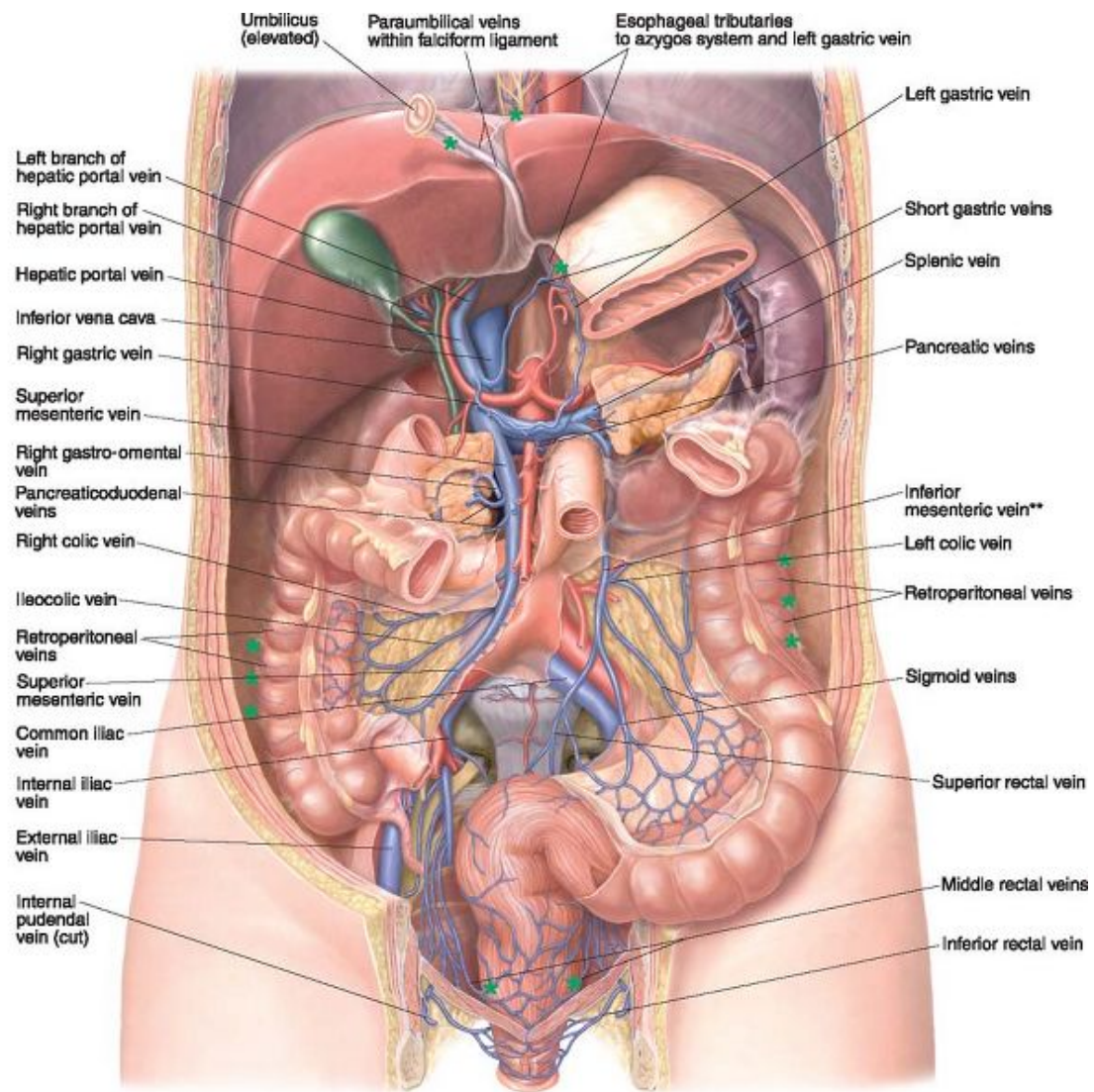


Plate 5-27 Duodenum and Pancreas II



*Denotes sites of portal-caval anastomosis in cases of portal hypertension:

1. Esophageal tributaries of left gastric vein to esophageal tributaries of azygos system of veins
 2. Superior rectal vein to middle and inferior rectal veins
 3. Paraumbilical tributaries of left hepatic portal vein to superficial veins of anterior body wall
 4. Retroperitoneal veins to veins of posterior body wall
- **Inferior mesenteric vein can join the splenic vein (34%), the superior mesenteric vein (33%), or the junction of the splenic and superior mesenteric veins (32%)

Plate 5-28 Hepatic Portal Vein

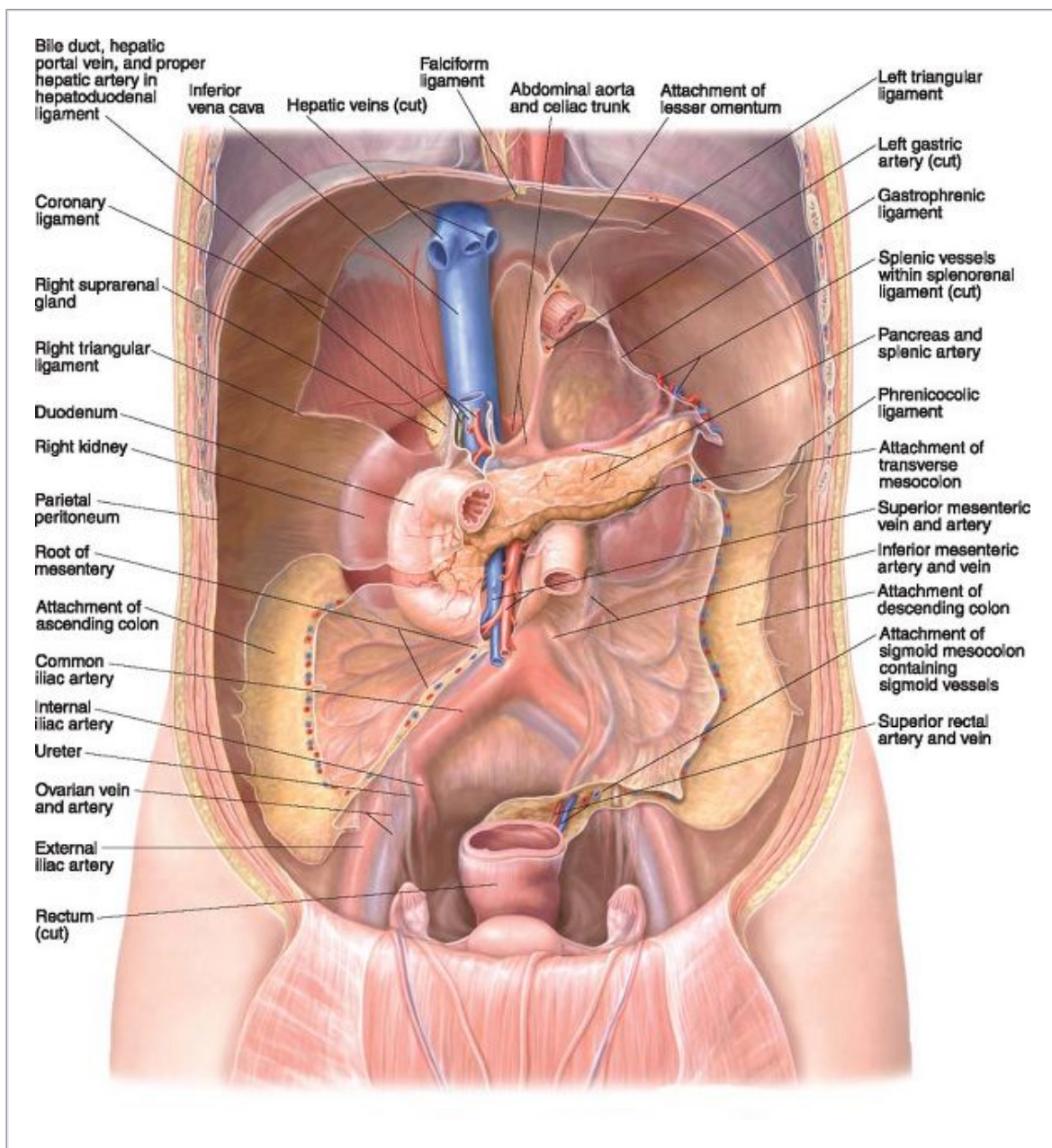
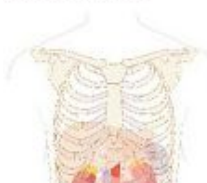
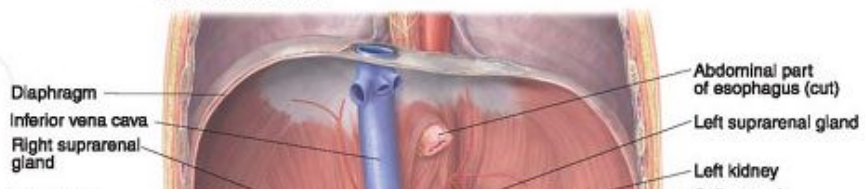
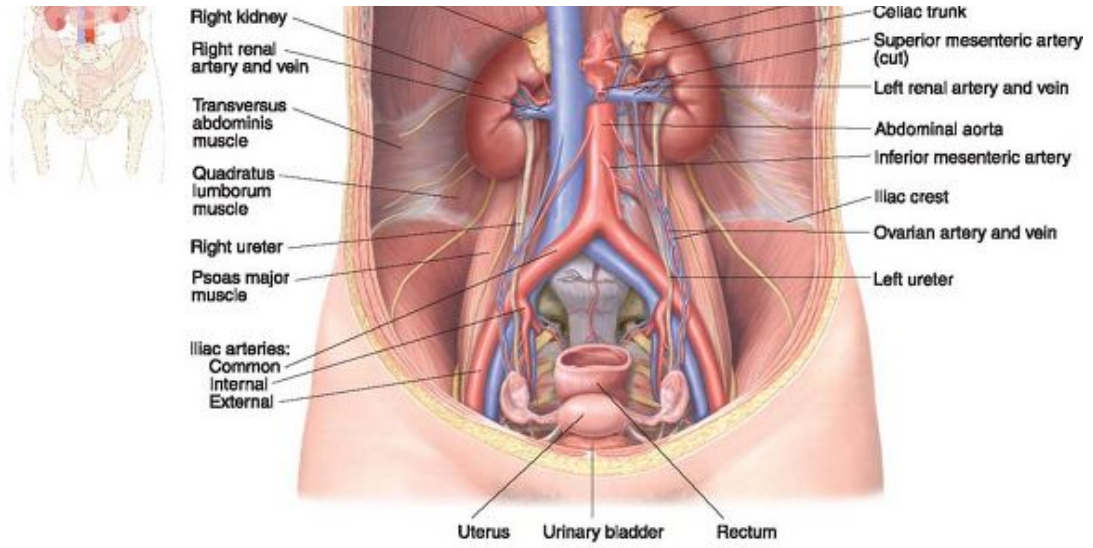
Plate 5-29 Peritoneal Attachments on the Posterior Abdominal Wall

A. Orientation



B. Anterior view





C. Posterior view

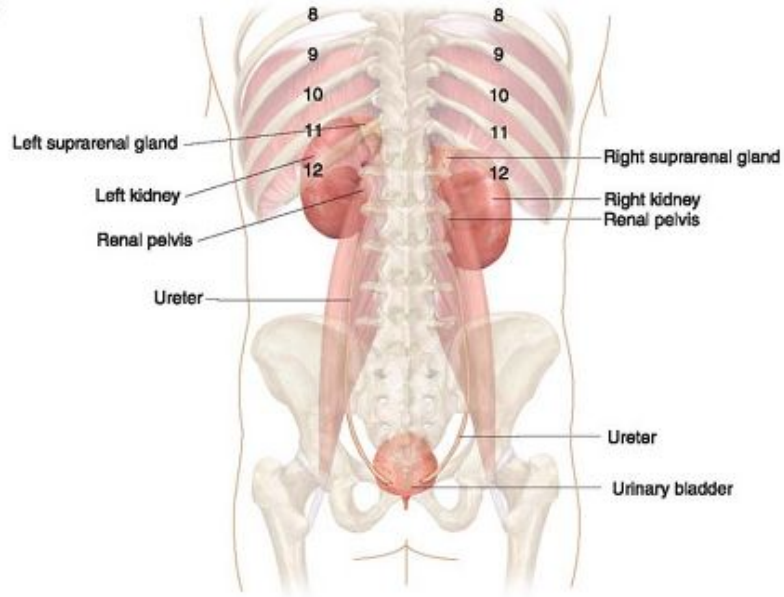
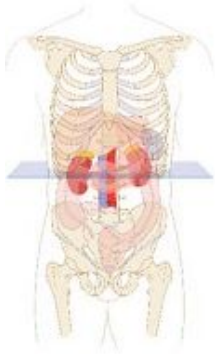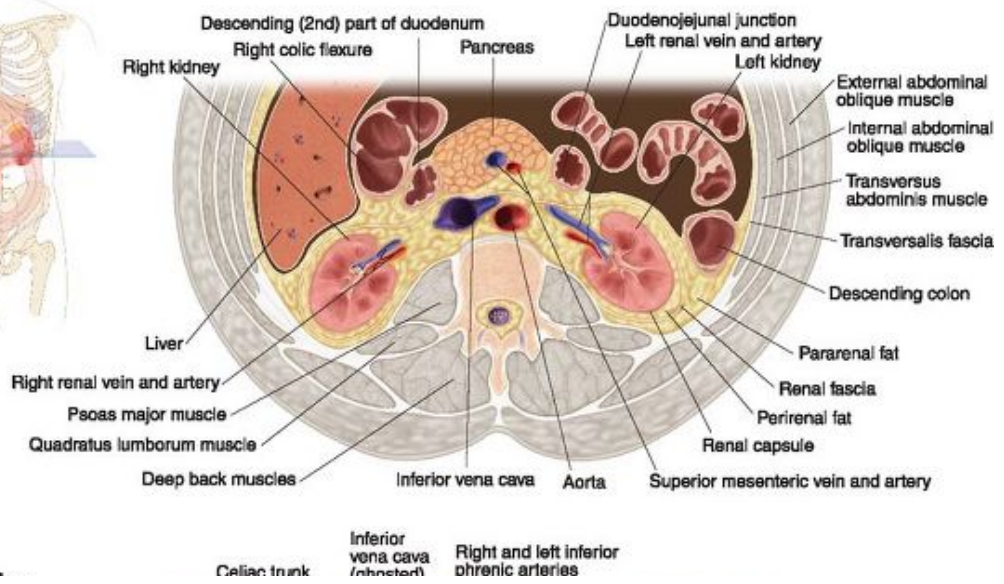


Plate 5-30 Kidneys and Retroperitoneum

A. Orientation



B. Cross section through the L2 vertebra



C. Dissection

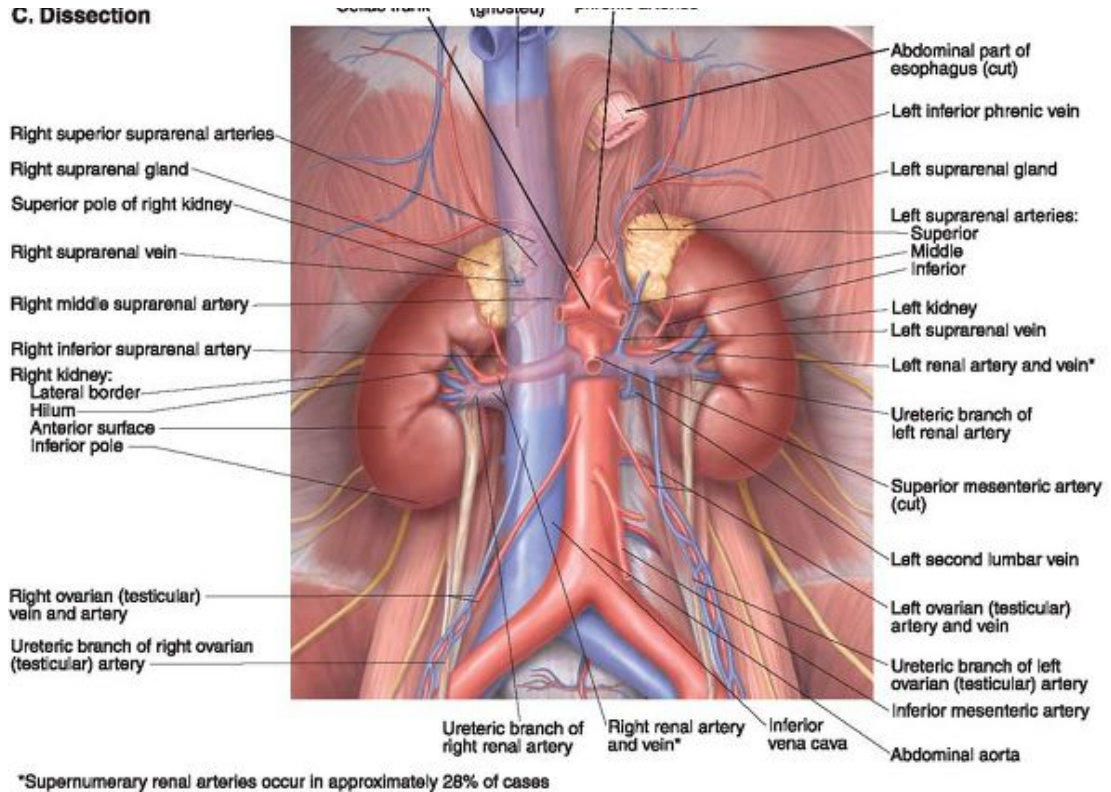
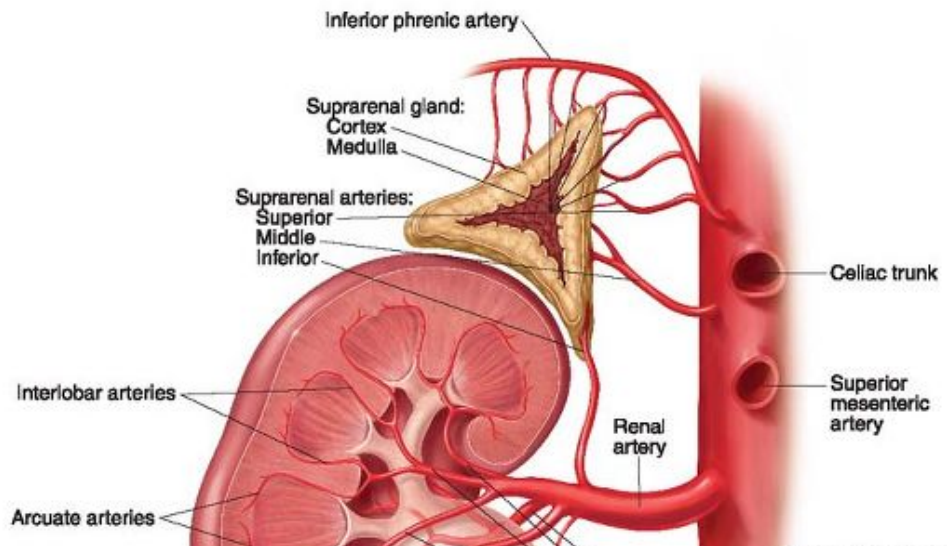
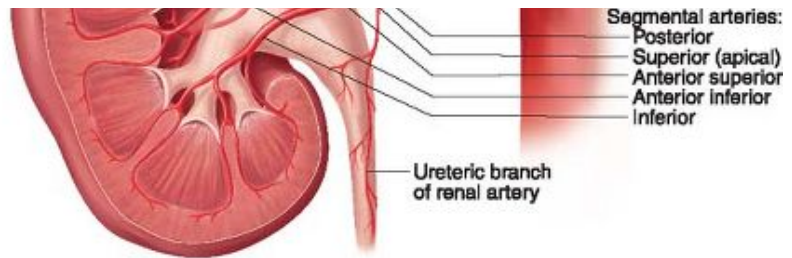


Plate 5-31 Kidneys and Suprarenal Glands

A. Arteries





B. Renal collecting system

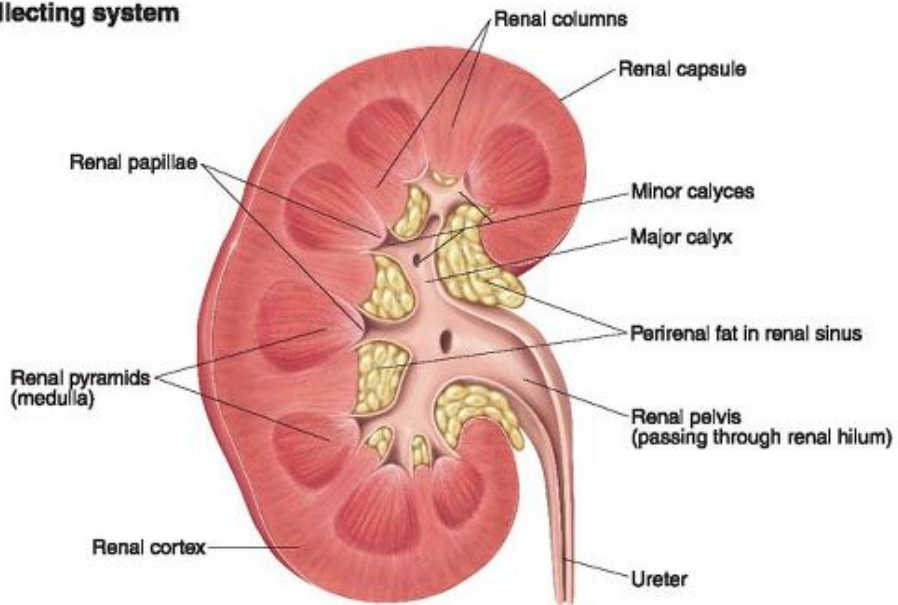
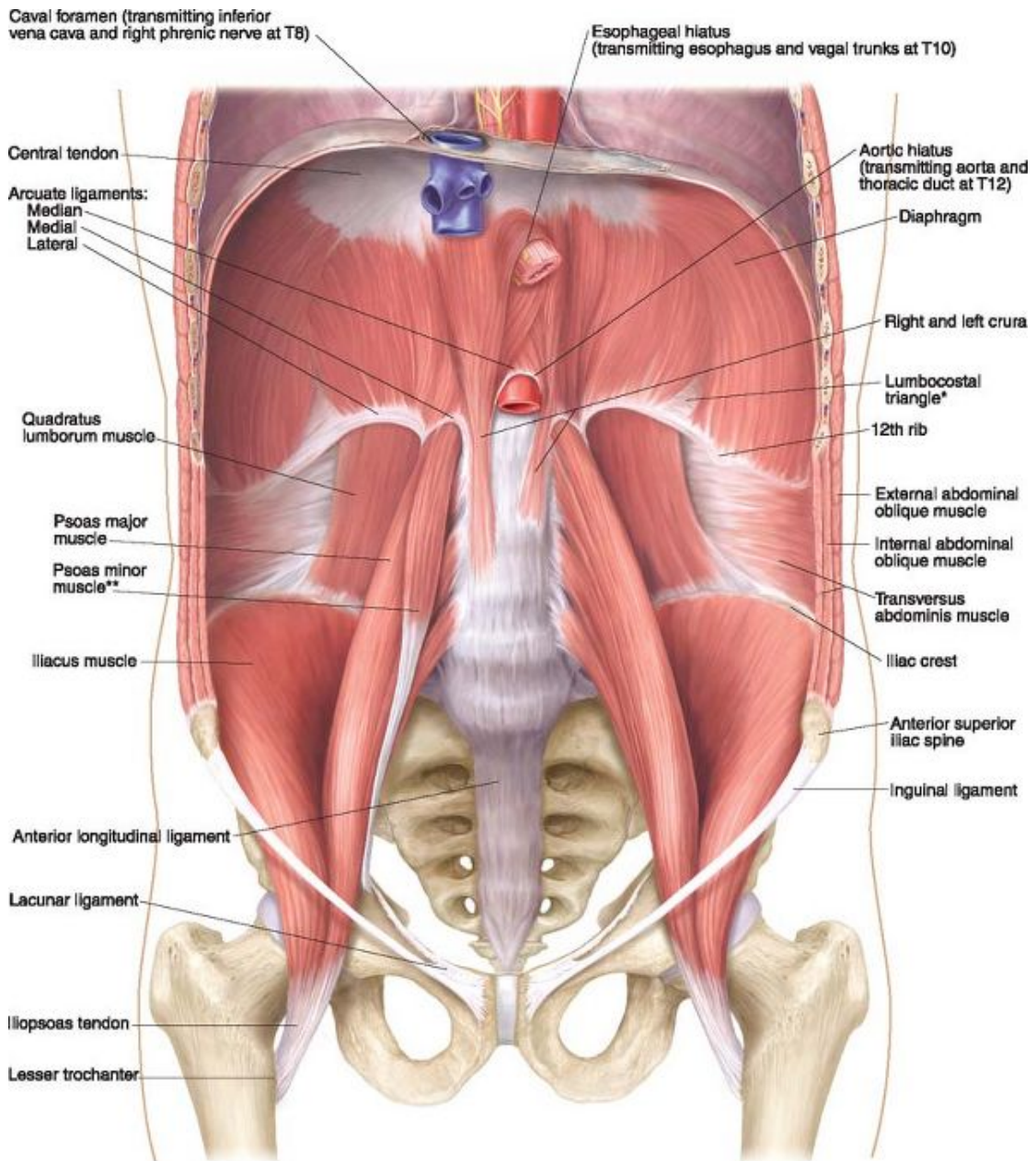
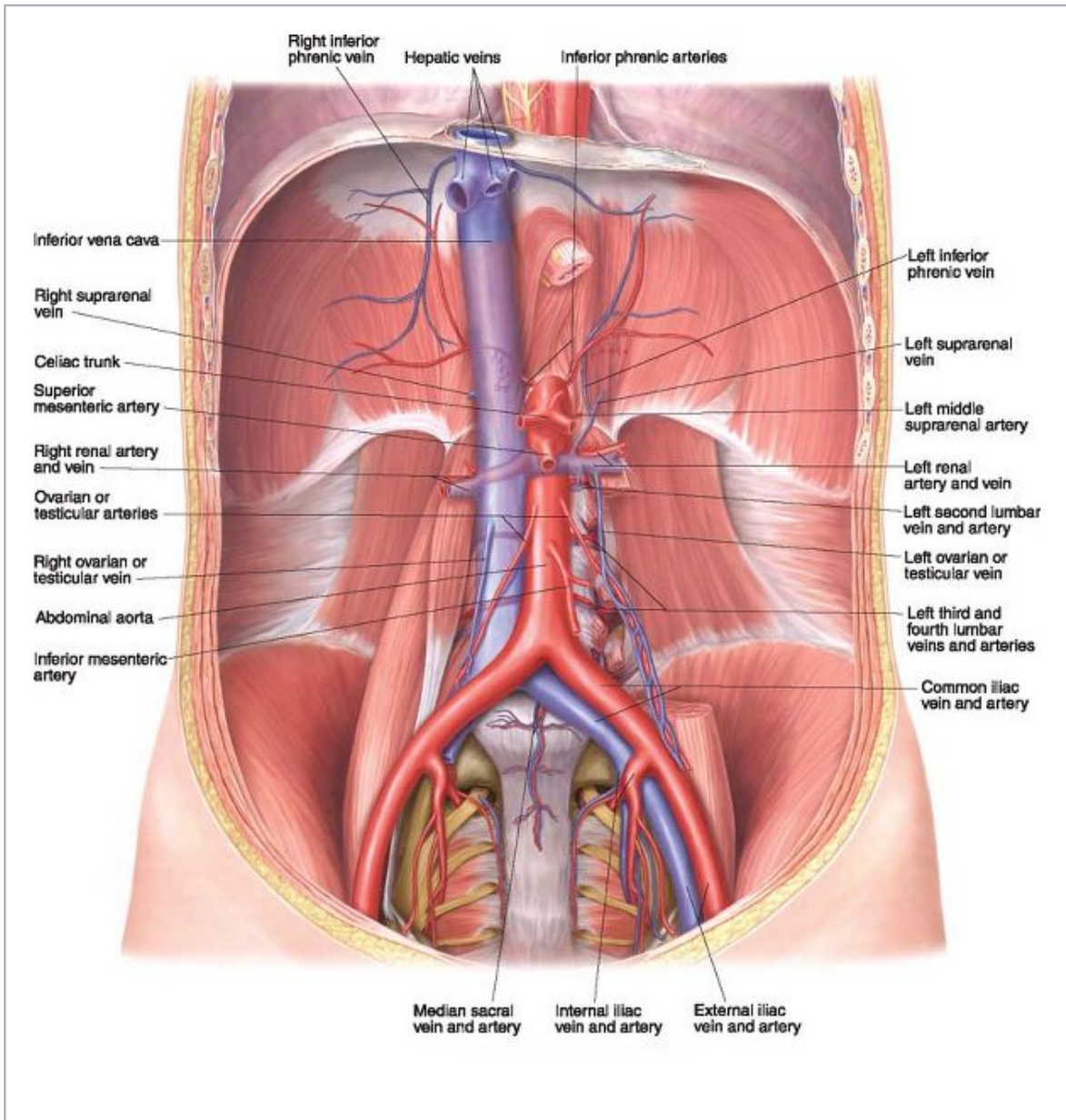


Plate 5-32 Kidney and Suprarenal Gland, Internal Features

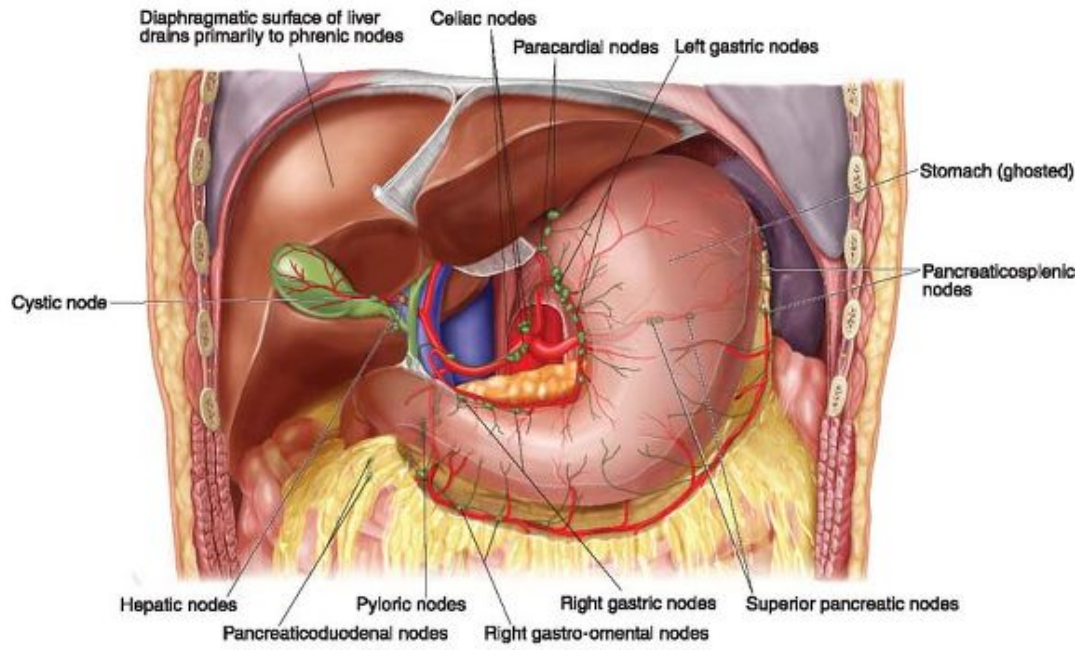


* Lumbocostal triangle is present in 80% of cases
 ** Psoas minor muscle is present in 50% of cases

Plate 5-33 Diaphragm and Muscles of the Posterior Abdominal Wall



A. Superficial dissection



B. Deep dissection

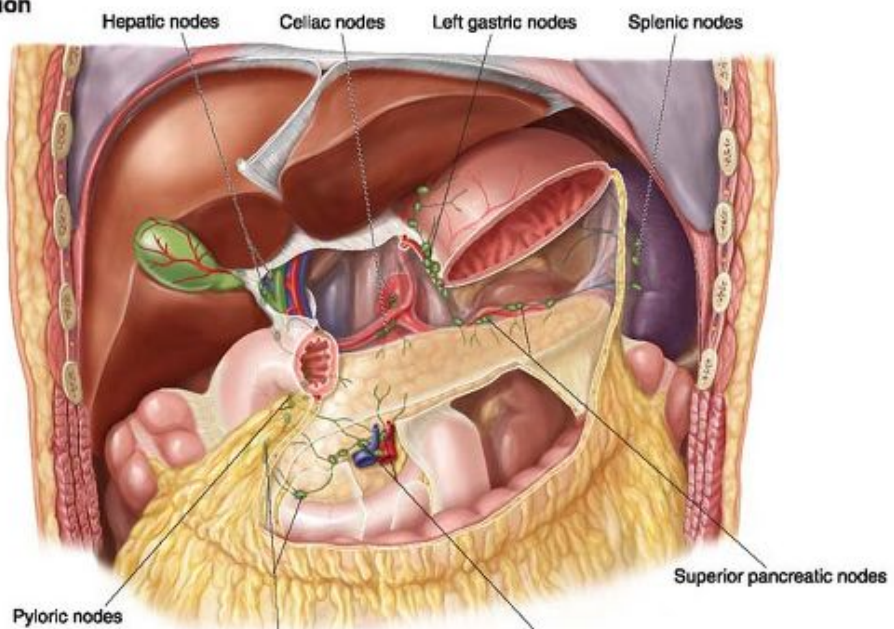
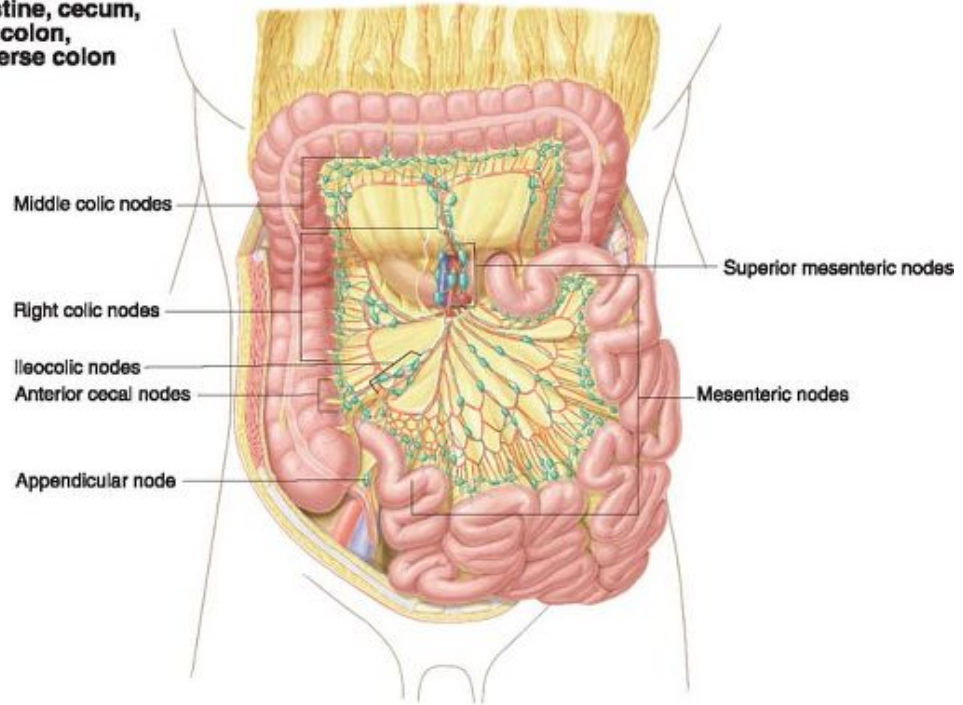


Plate 5-35 Lymphatic Drainage of Liver, Stomach, Spleen, and Pancreas

A. Small intestine, cecum, ascending colon, and transverse colon



B. Descending colon, sigmoid colon, and rectum

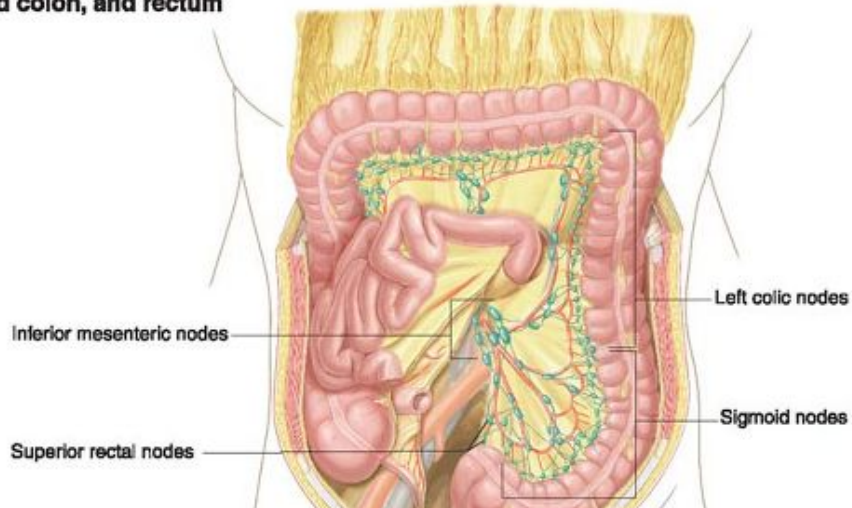
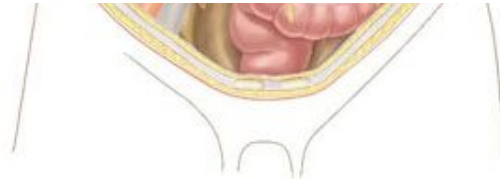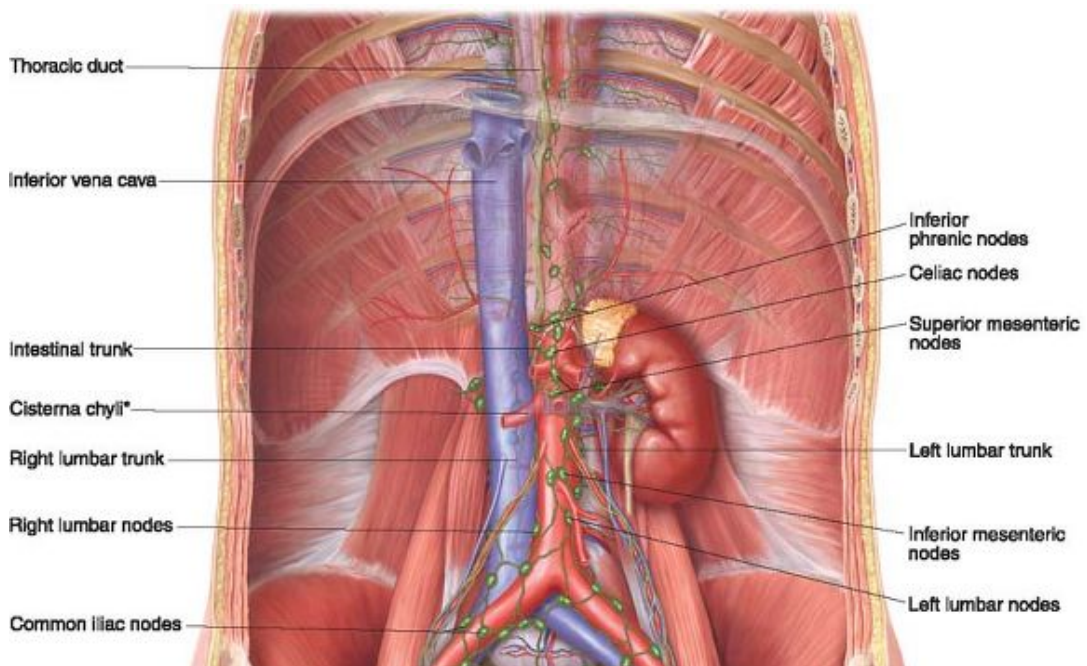
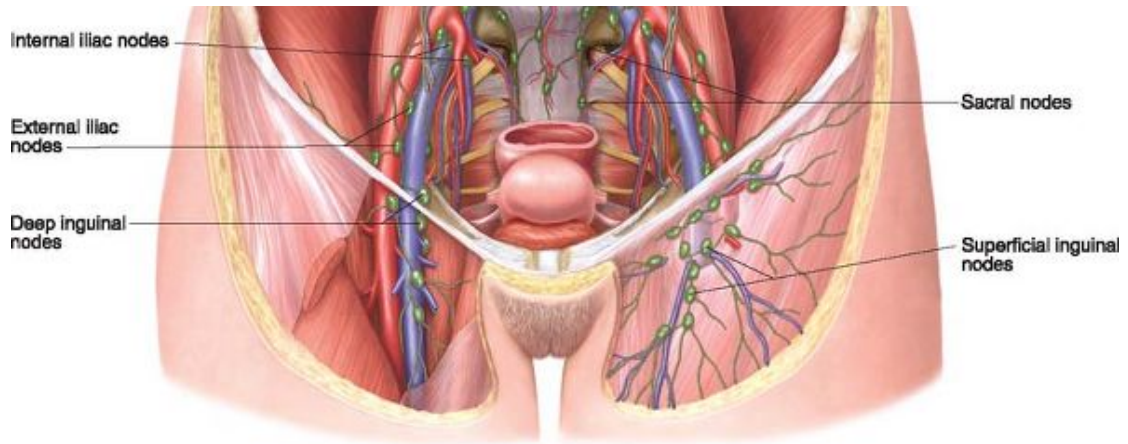




Plate 5-36 Lymphatic Drainage of the Small and Large Intestines

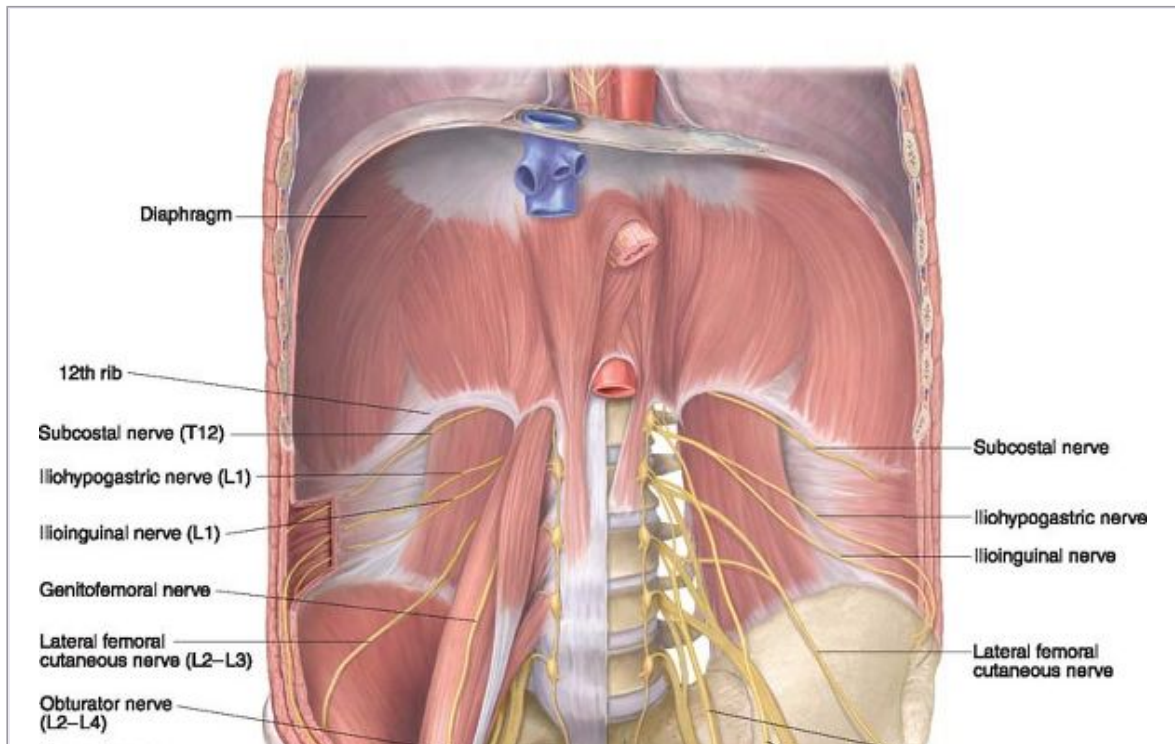


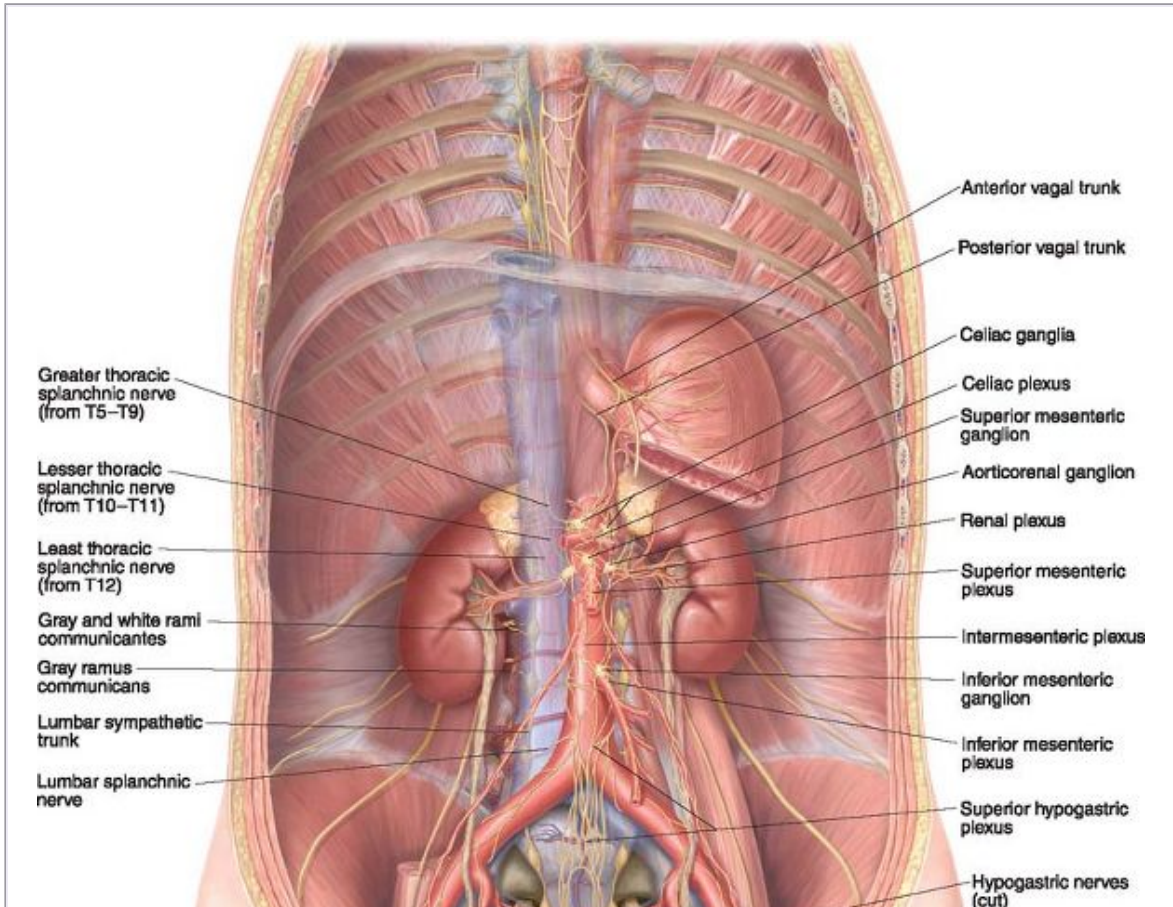
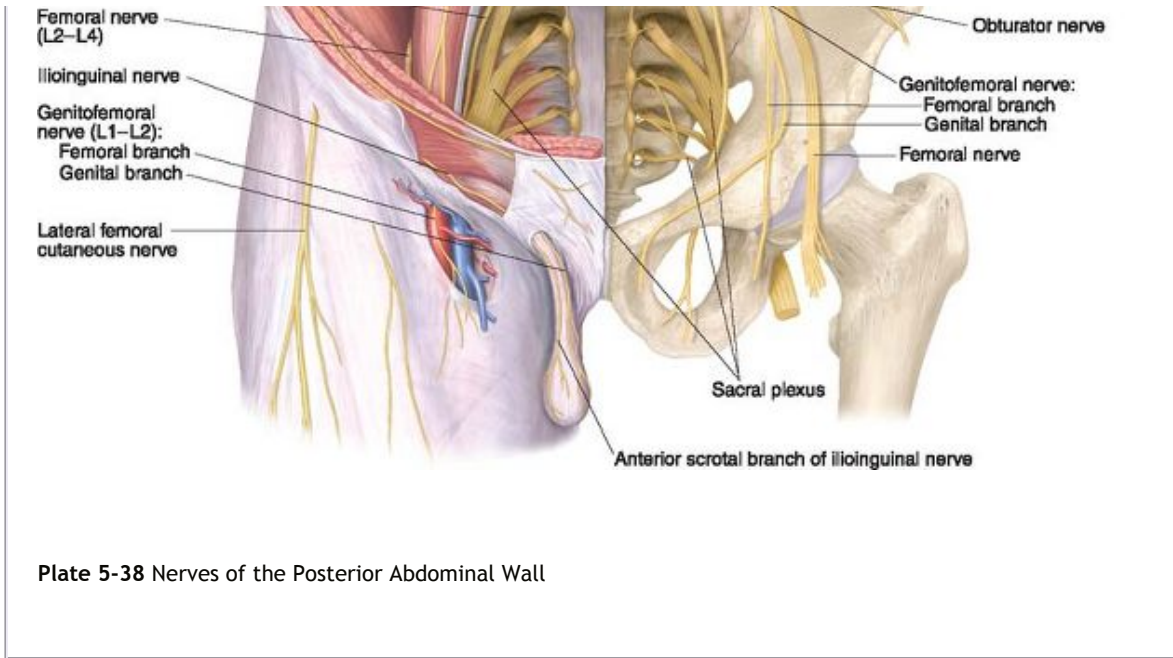


*Cisterna chyli is present in approximately 25% of cases

Plate 5-37 Lymphatic Drainage of the Posterior Abdominal Wall and Abdominal Viscera

P.250





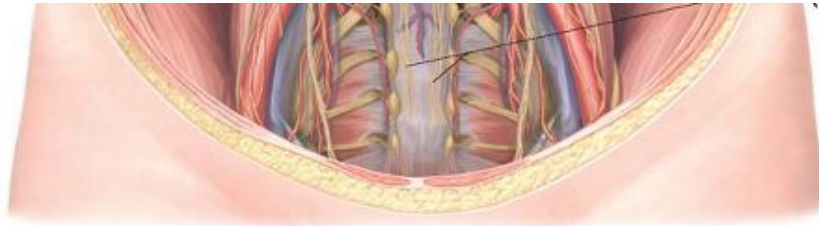
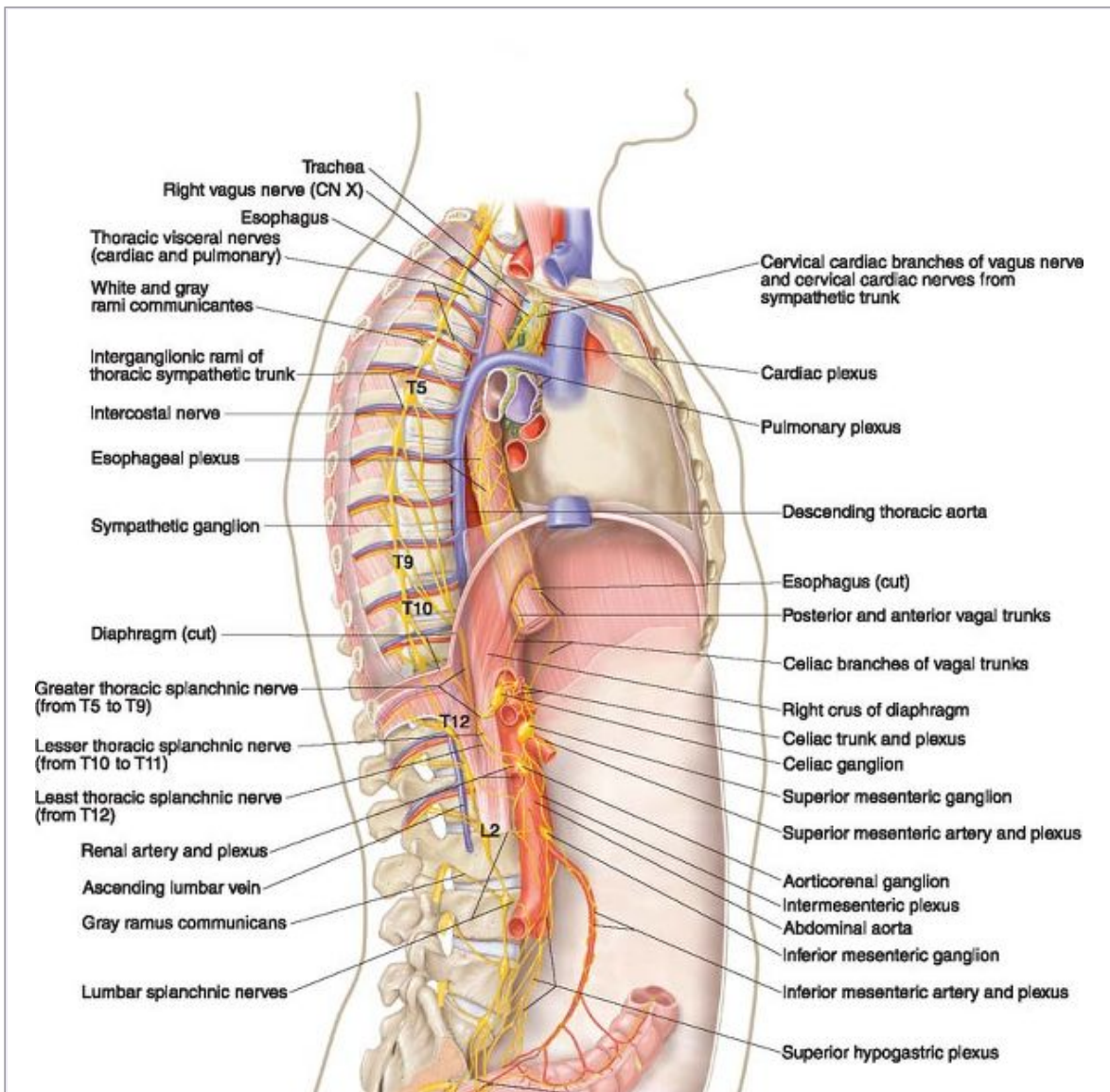


Plate 5-39 Autonomic Nerves of the Abdomen, Anterior View



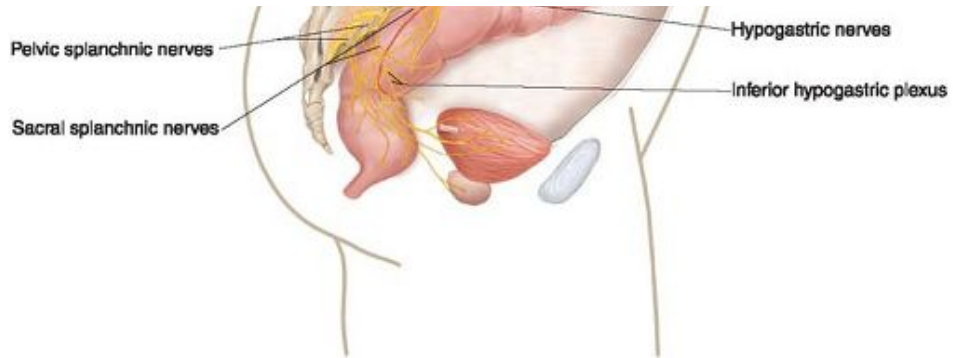
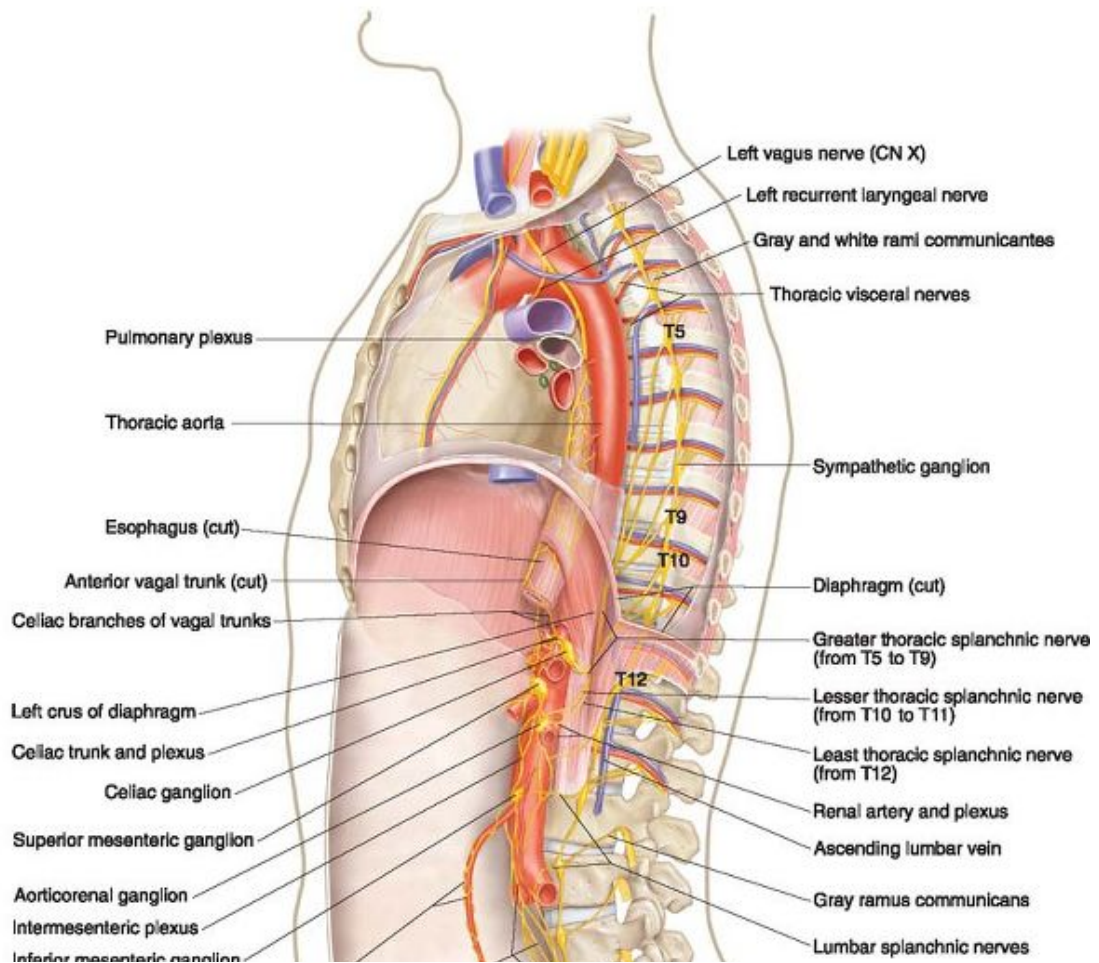


Plate 5-40 Autonomic Nerves of the Abdomen, Right Lateral View



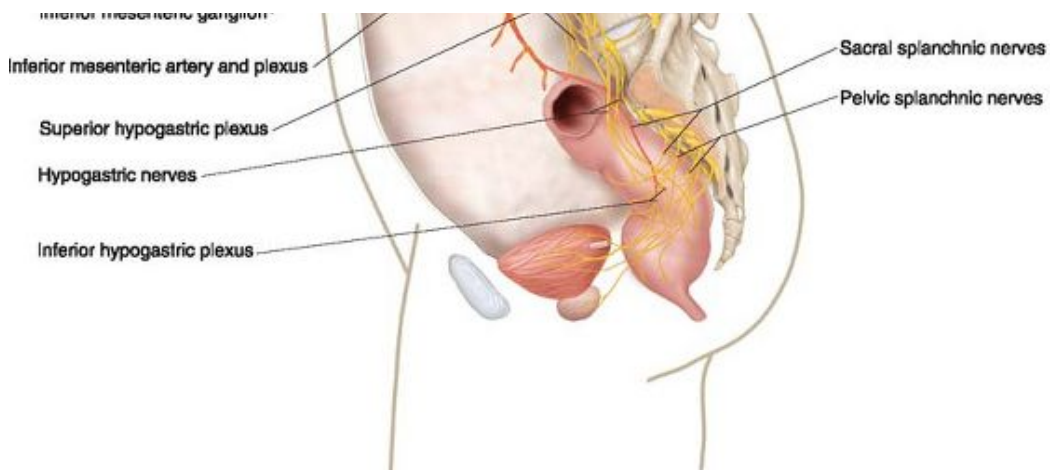
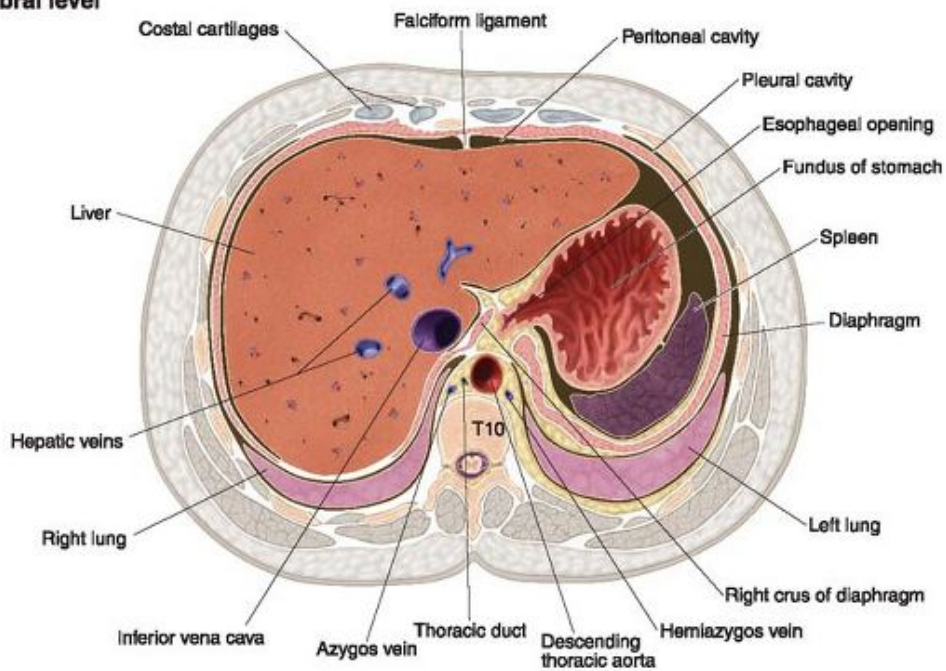
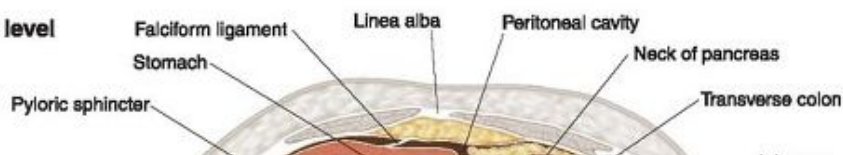


Plate 5-41 Autonomic Nerves of the Abdomen, Left Lateral View

A. T10 vertebral level



B. L1 vertebral level



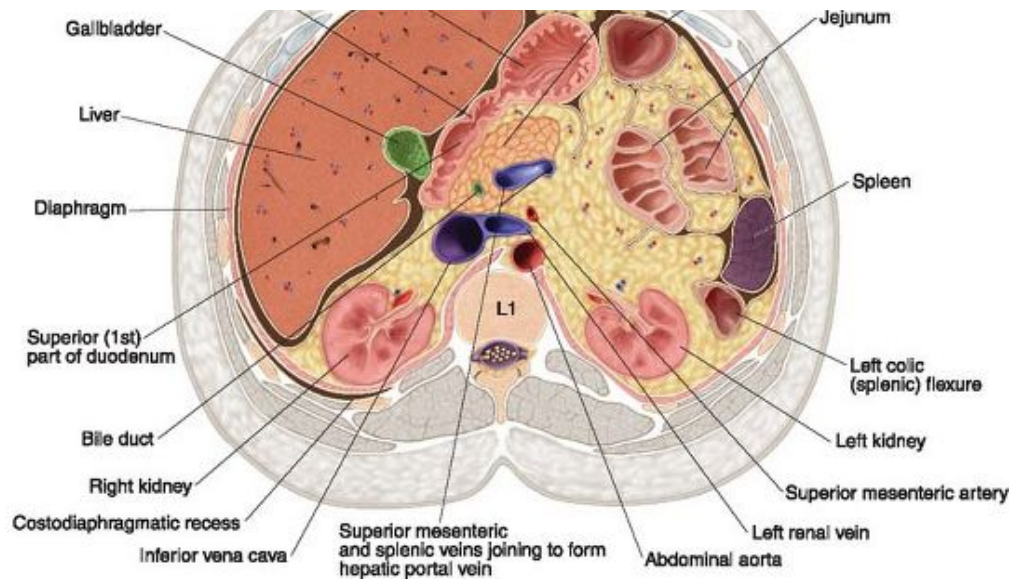
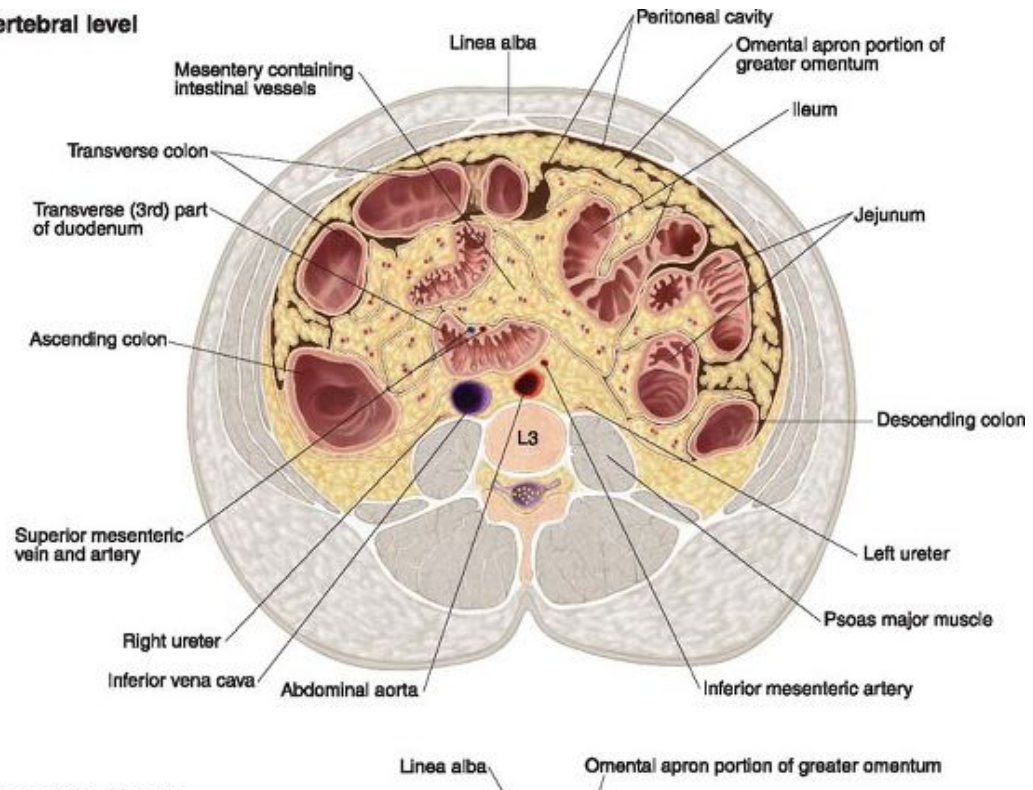


Plate 5-42 Cross Sections Through Vertebral Levels T10 and L1

P.255

A. L3 vertebral level



B. L5/S1 vertebral level

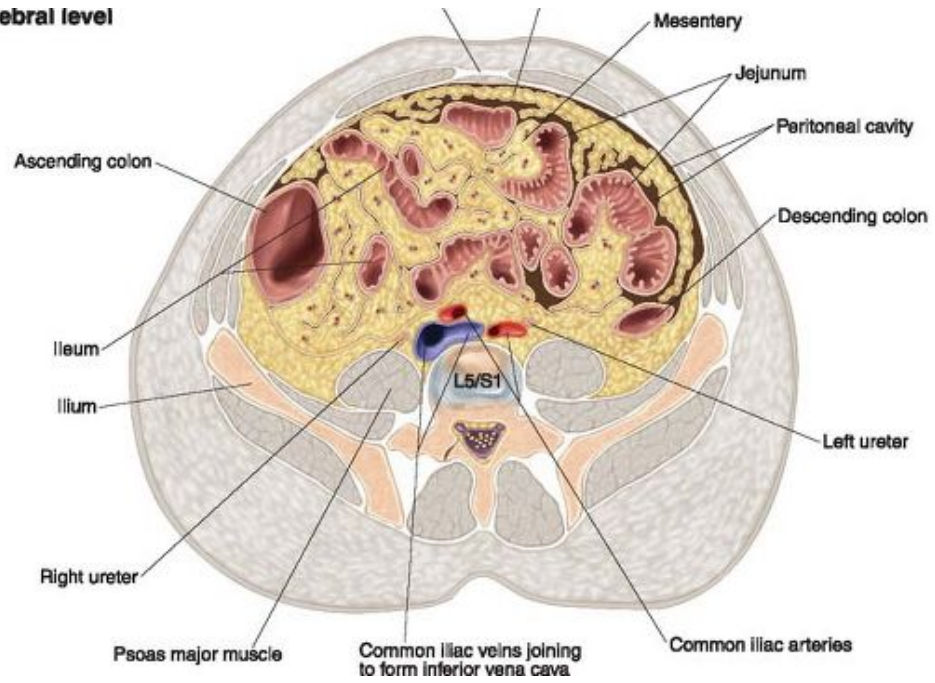


Plate 5-43 Cross Sections Through Vertebral Levels L3 and L5/S1

Authors: Tank, Patrick W.; Gest, Thomas R.

Title: *Lippincott Williams & Wilkins Atlas of Anatomy, 1st Edition*

Copyright ©2009 Lippincott Williams & Wilkins

> Table of Contents > Chapter 6 - The Pelvis and Perineum

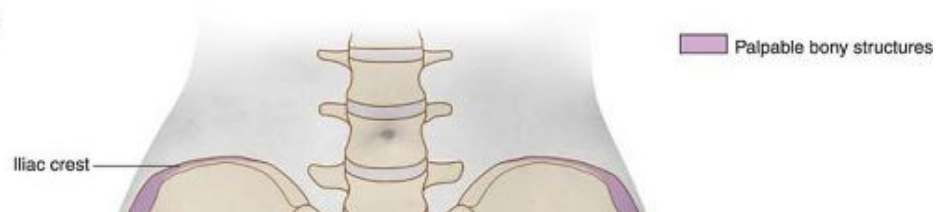Chapter 6

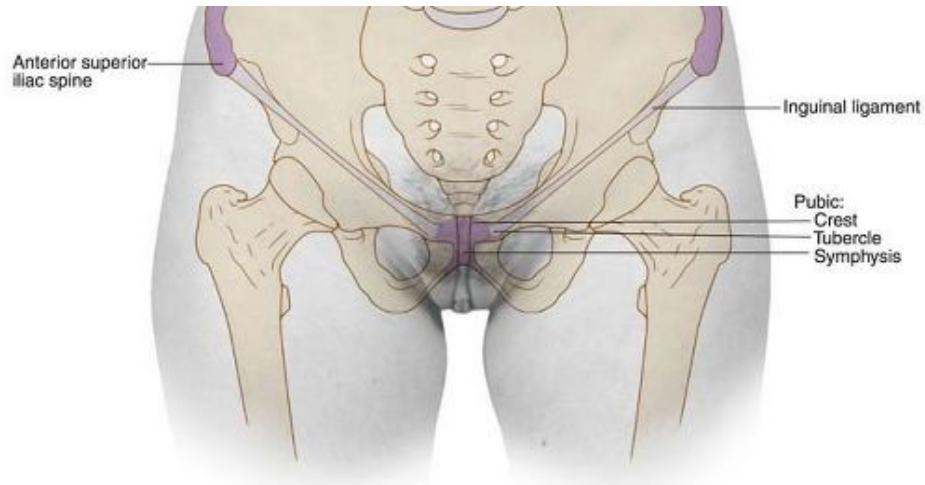
The Pelvis and Perineum

P.257

P.258

A. Anterior view





B. Posterior view

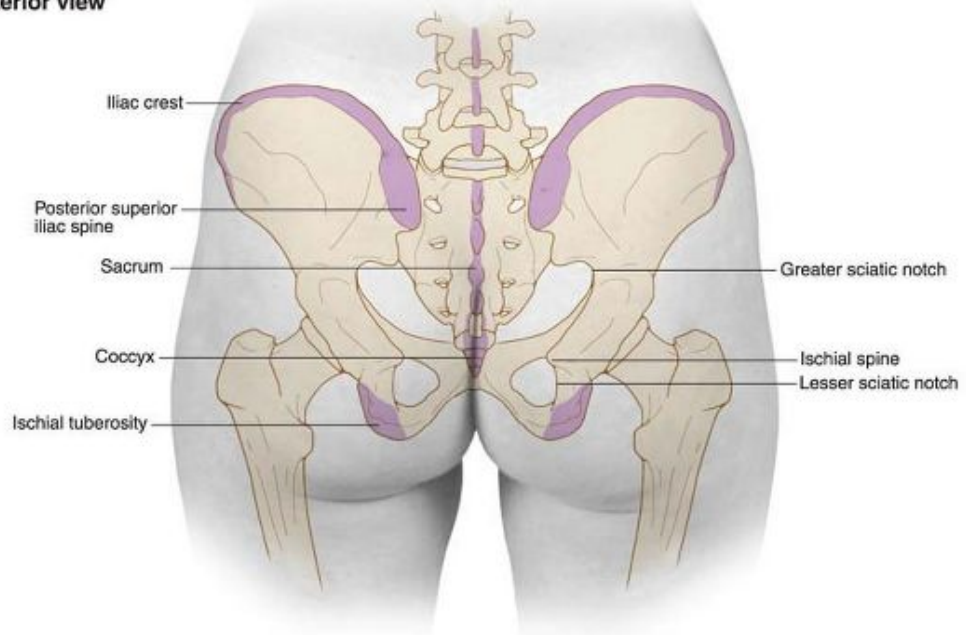
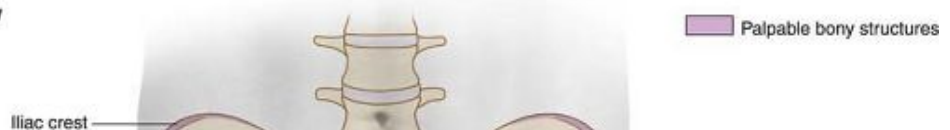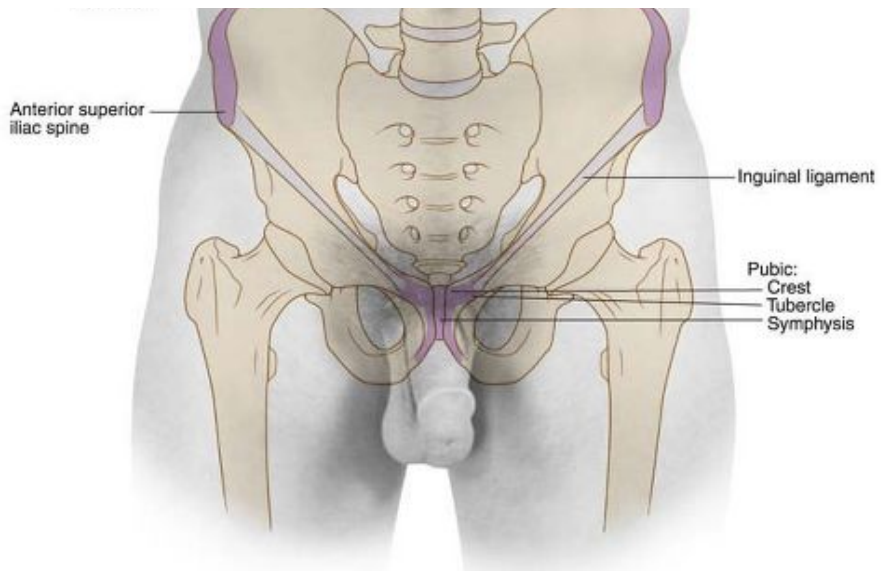


Plate 6-01 Palpable Features of the Female Pelvis and Perineum

A. Anterior view





B. Posterior view

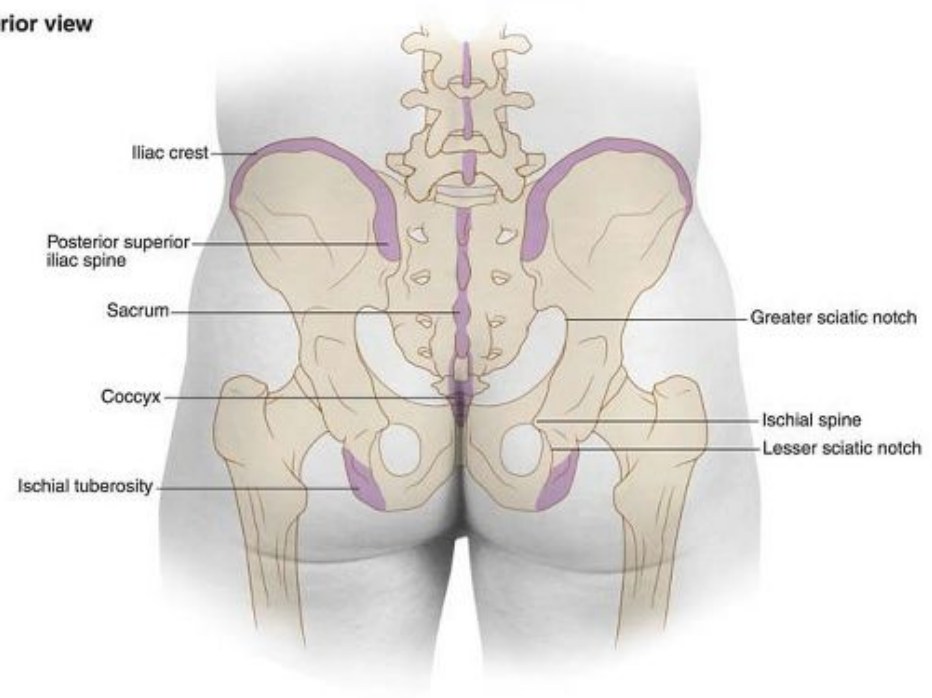
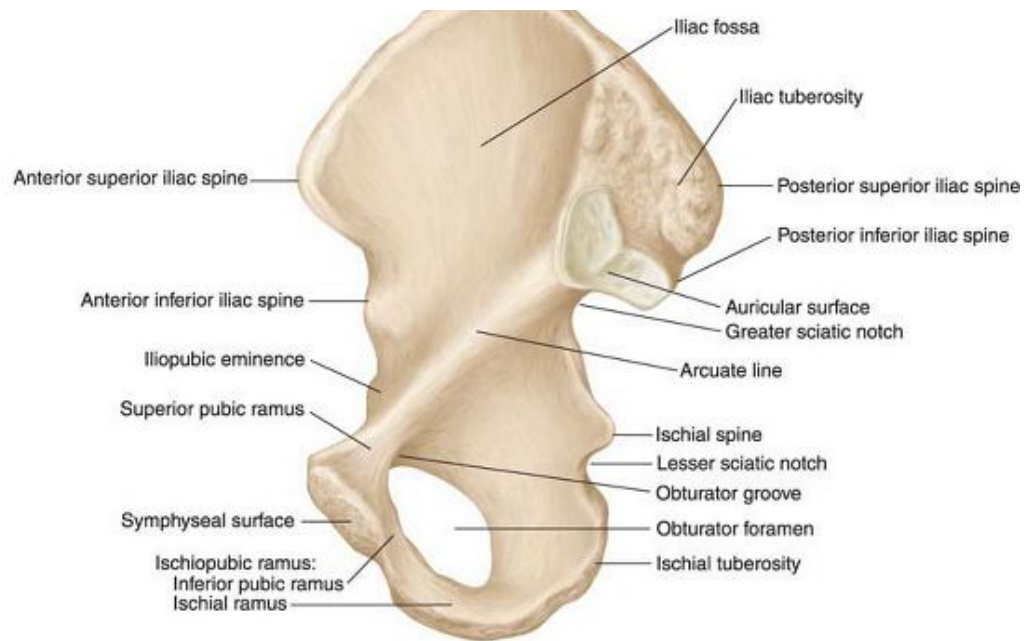


Plate 6-02 Palpable Features of the Male Pelvis and Perineum

A. Medial view





B. Lateral view

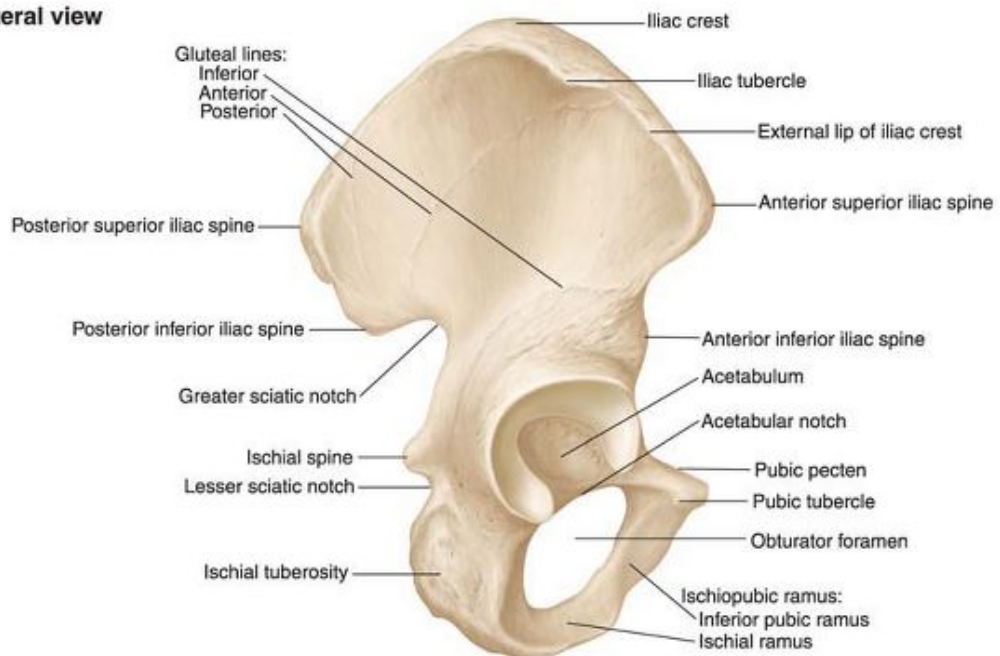
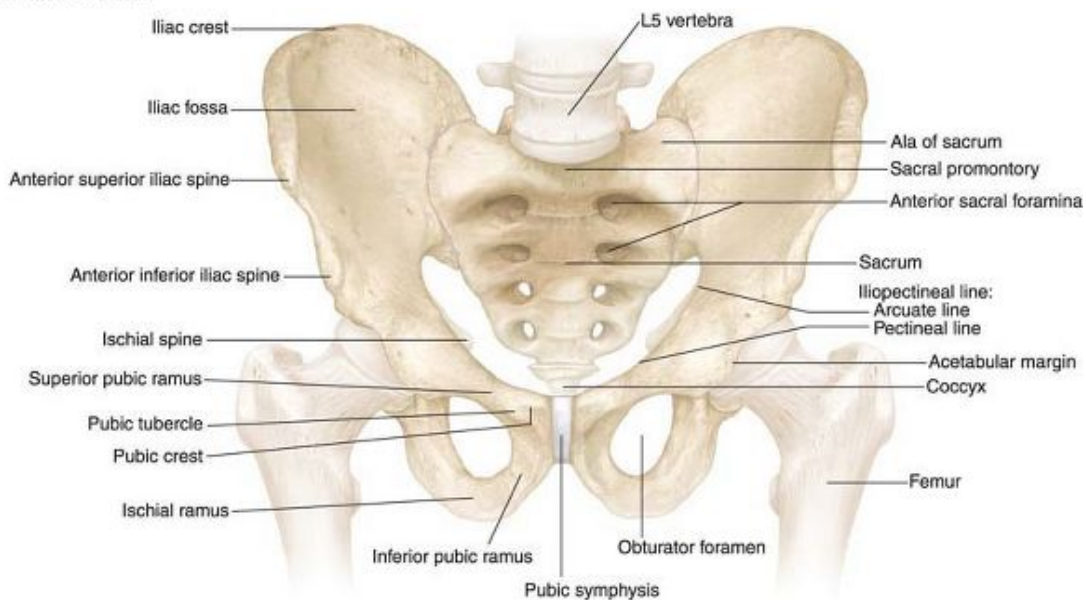


Plate 6-03 Skeleton of the Hip (Os Coxae)

A. Anterior view



B. Posterior view

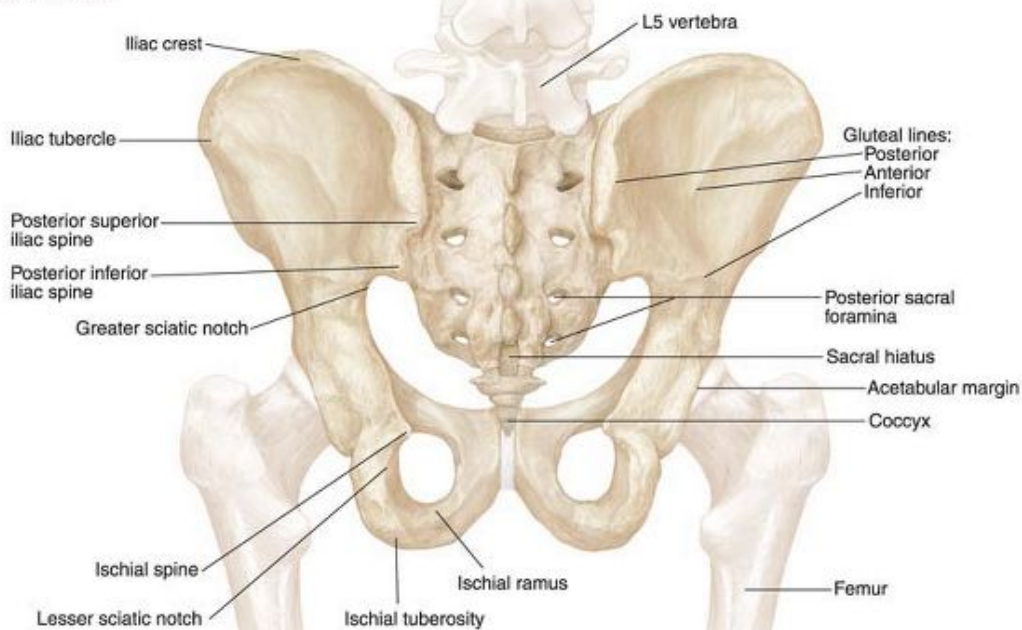
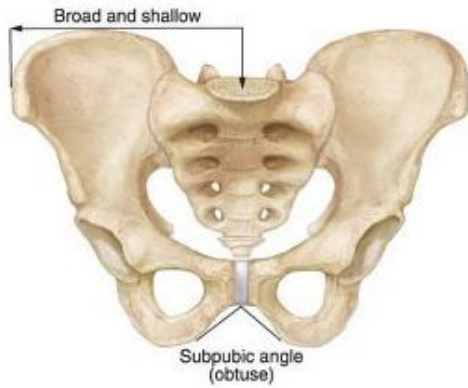
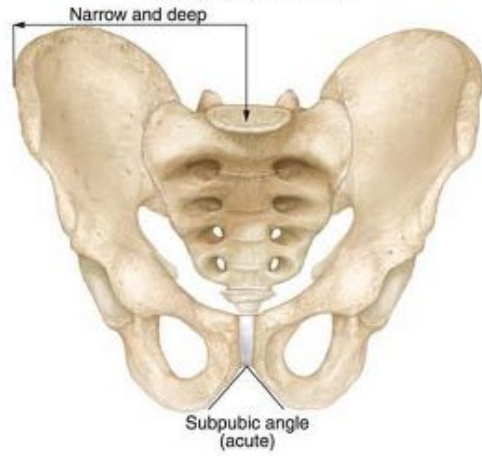


Plate 6.04 Articulated Pelvis, Male

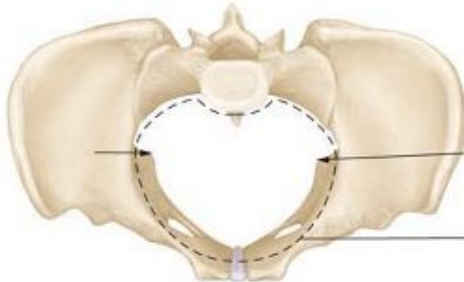A. Female, anterior view



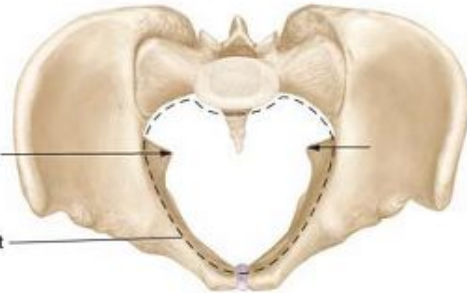
B. Male, anterior view



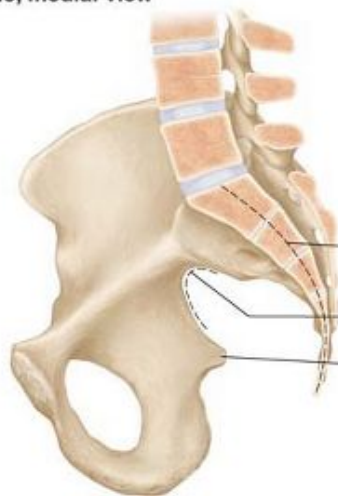C. Female, superior view



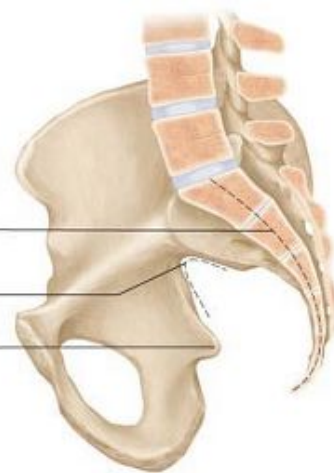D. Male, superior view



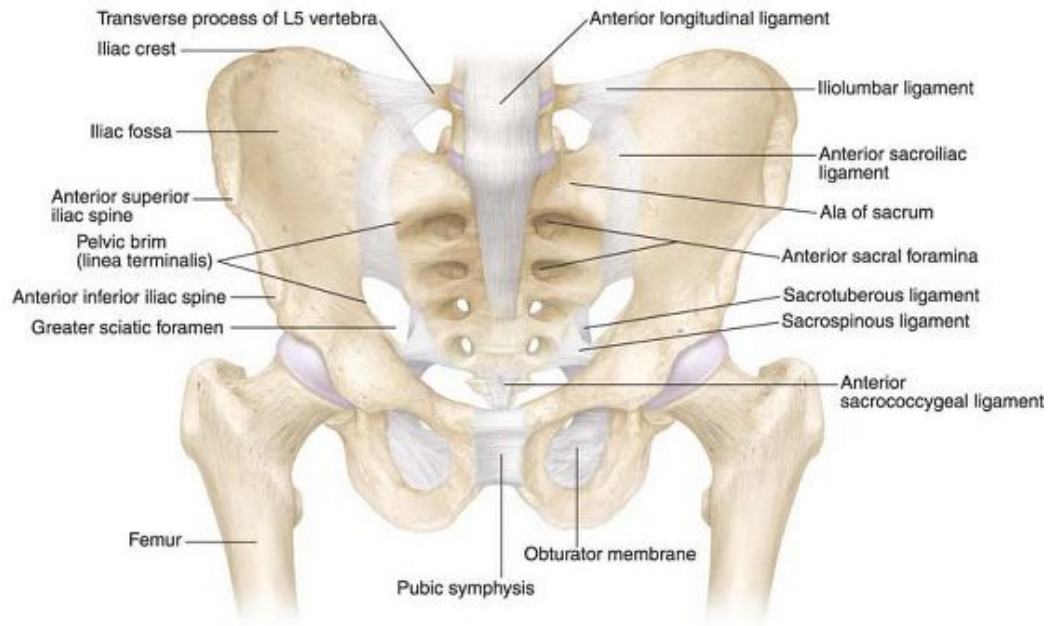
E. Female, medial view



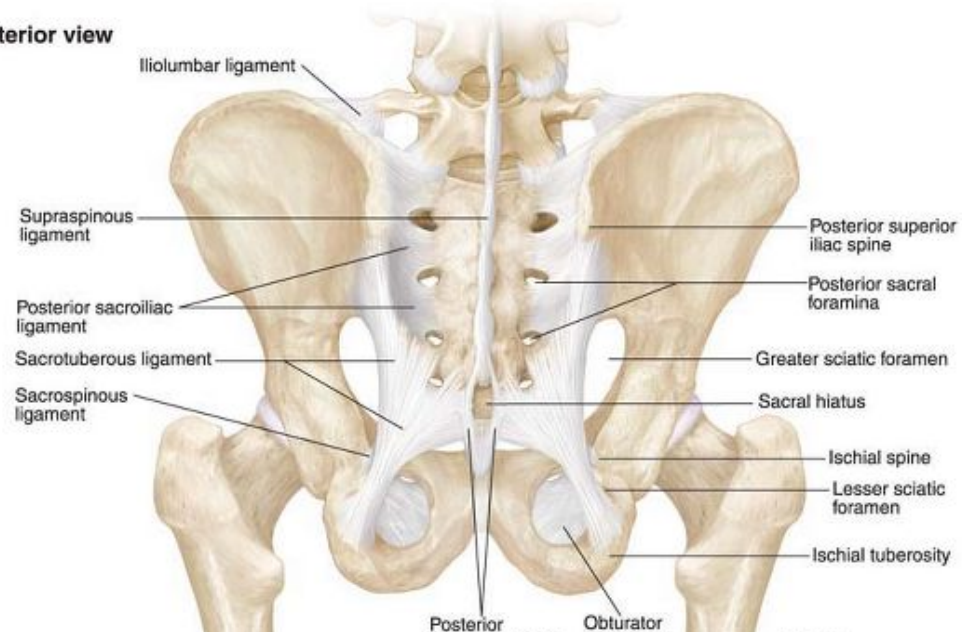
F. Male, medial view



A. Anterior view



B. Posterior view



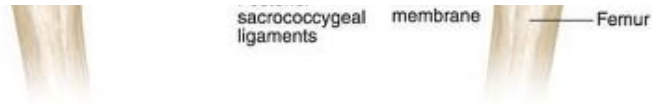
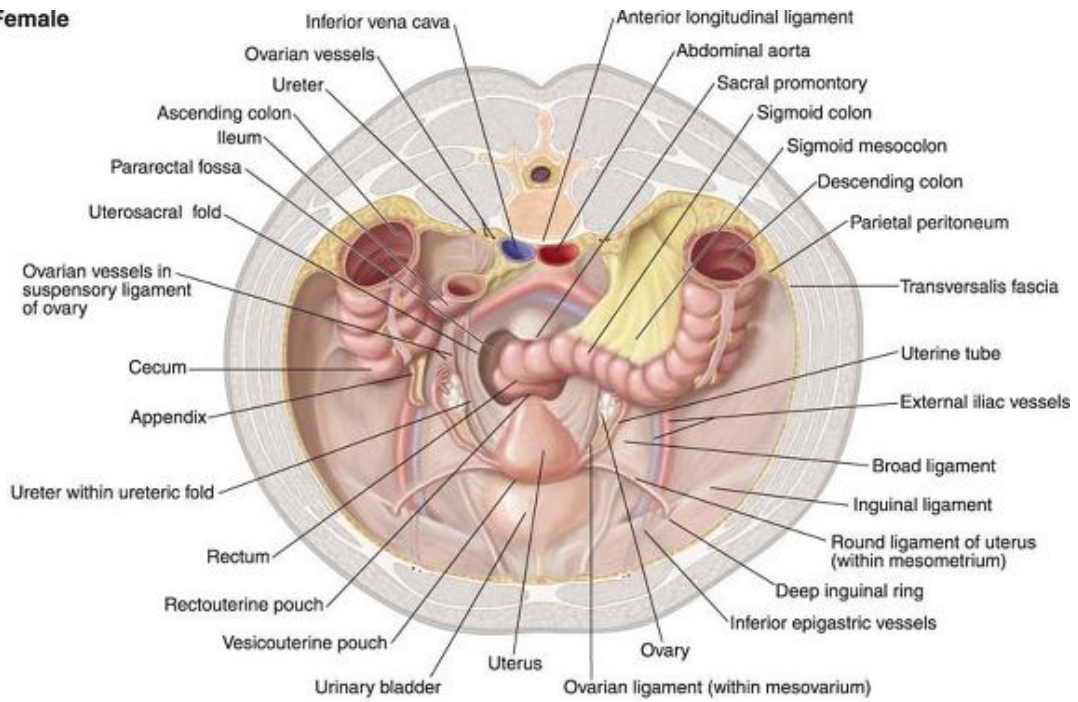
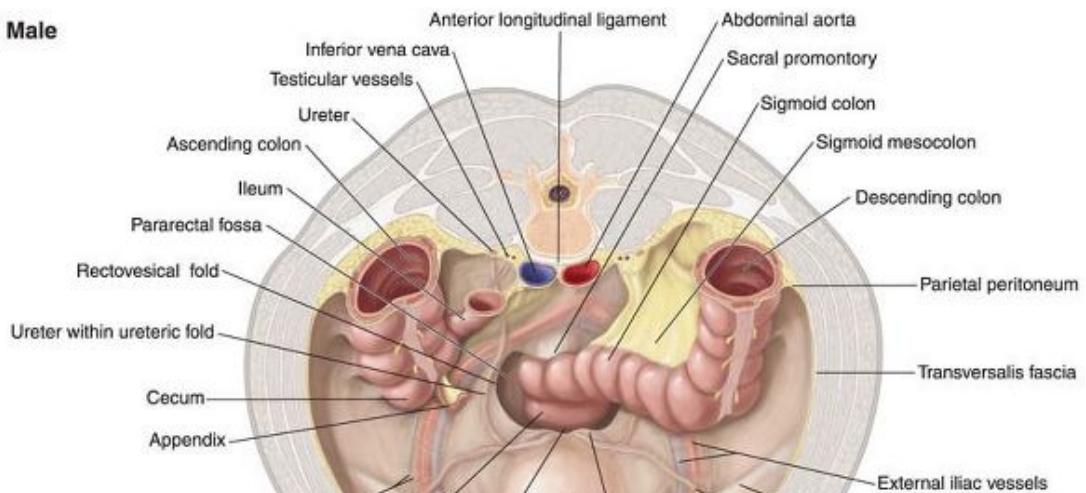


Plate 6-06 Ligaments of the Pelvis

A. Female



B. Male



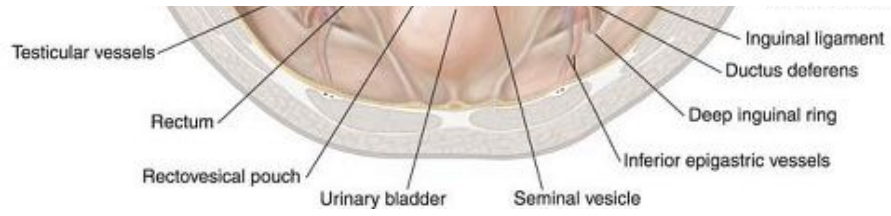
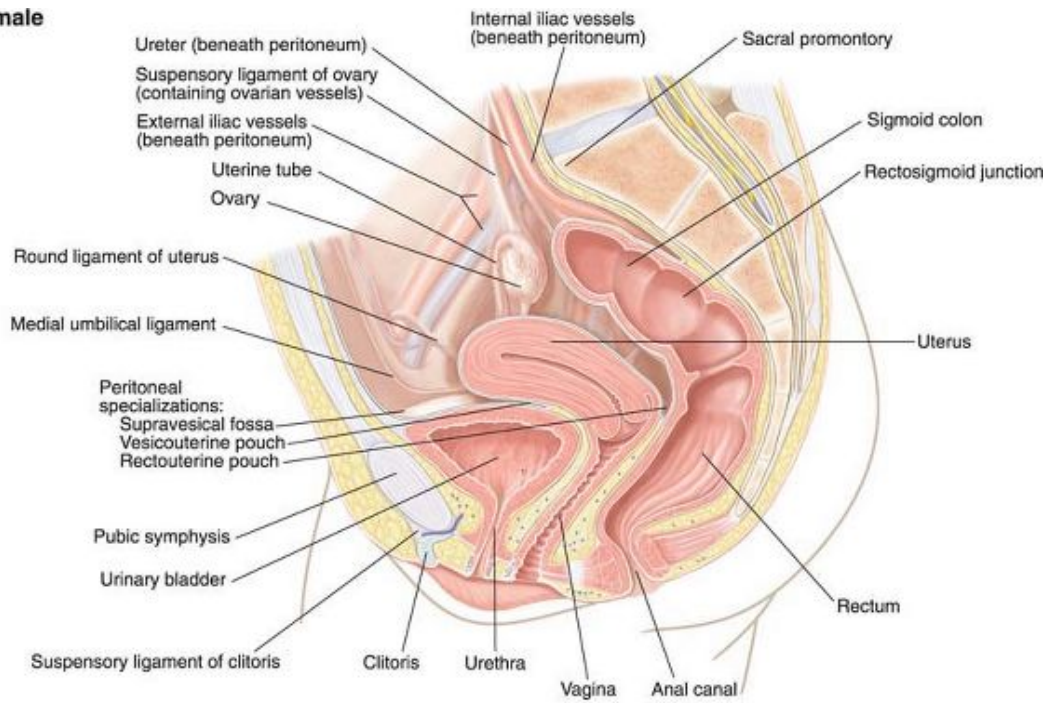
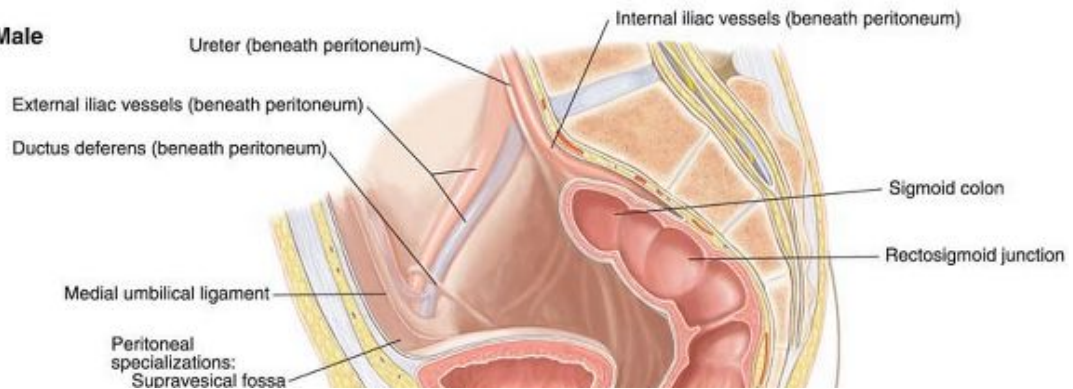


Plate 6-07 Pelvic Peritoneum, Superior View

A. Female



B. Male



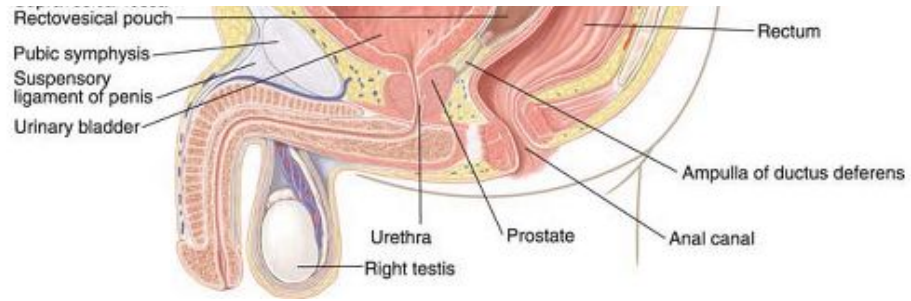
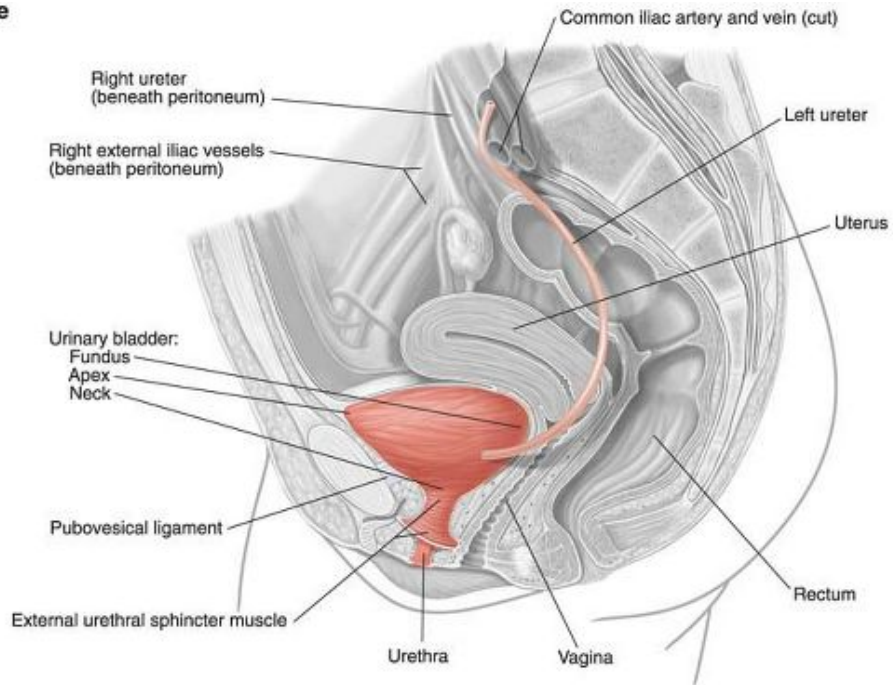
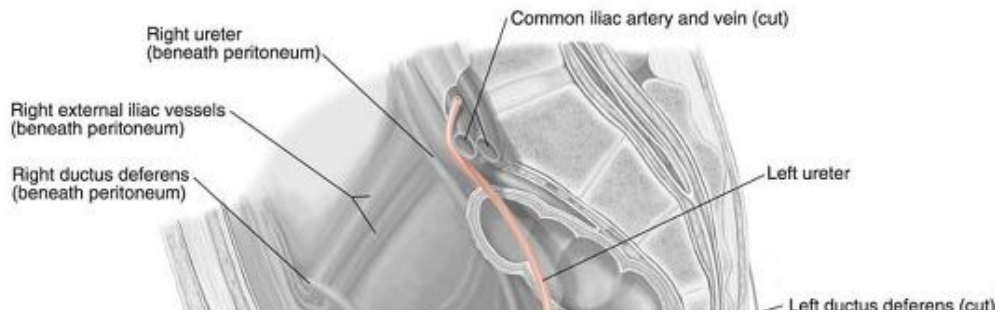


Plate 6-08 Pelvic Peritoneum, Sagittal View

A. Female



B. Male



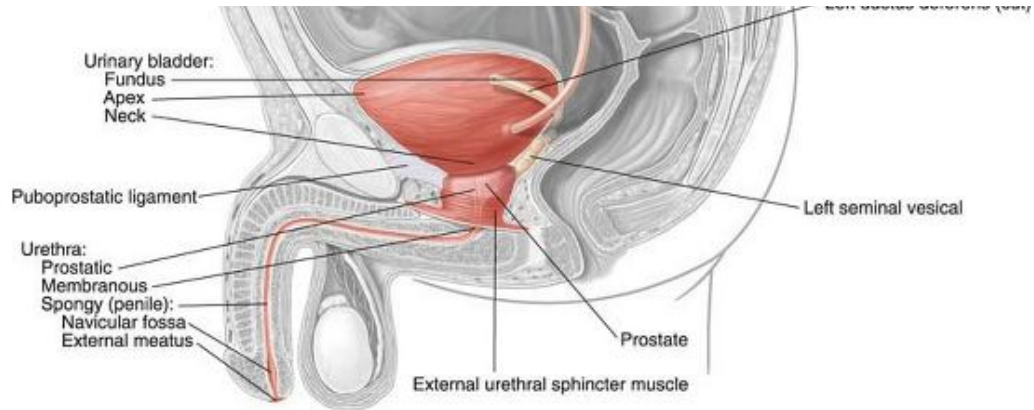
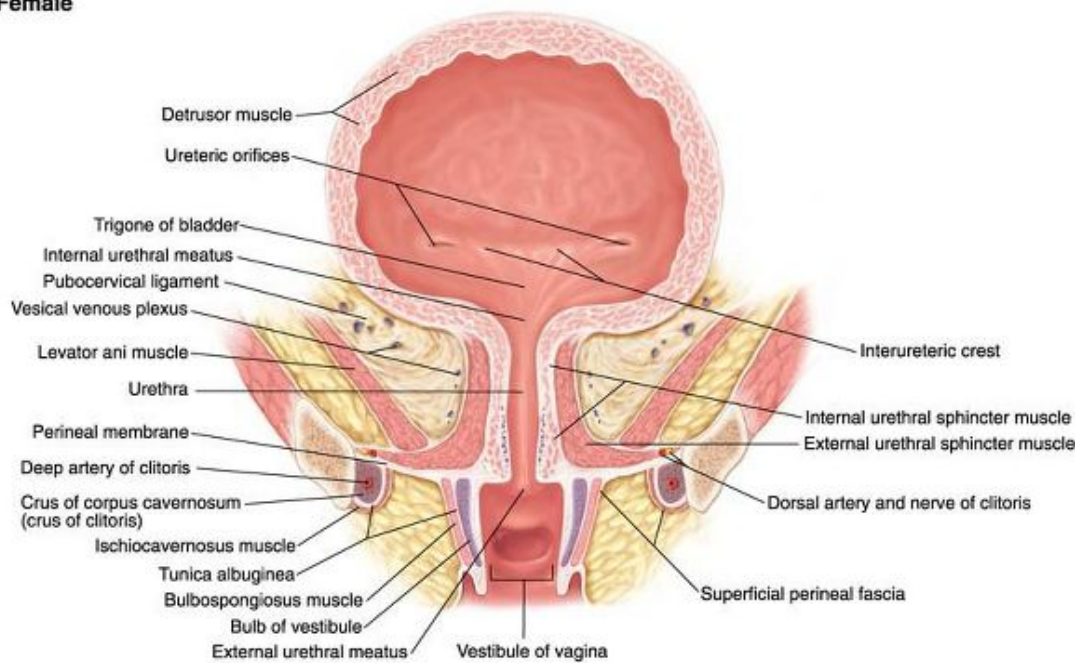


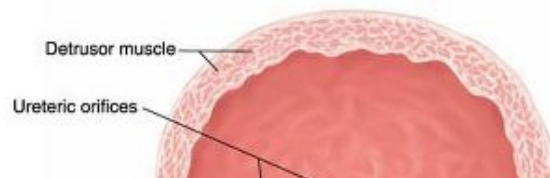Plate 6-09 Urinary Bladder, Lateral View

P.267

A. Female



B. Male



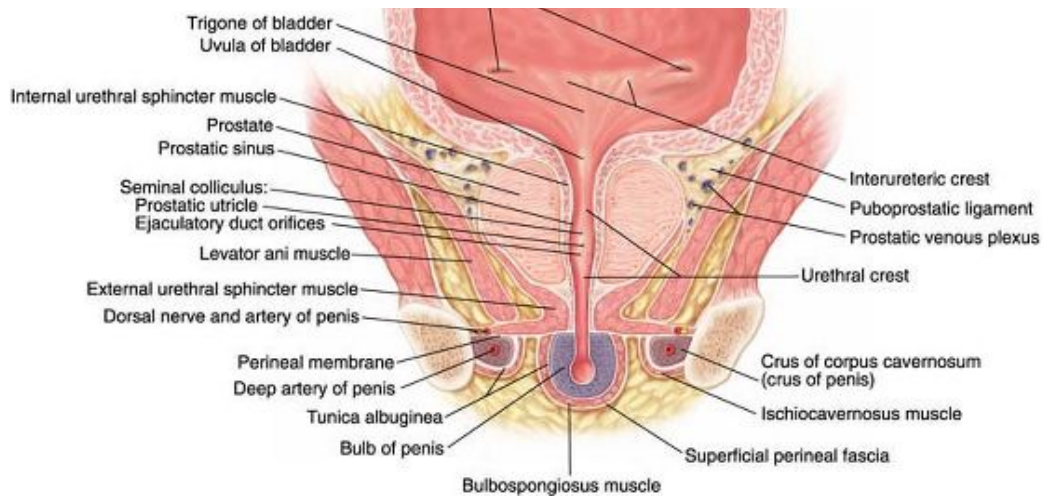
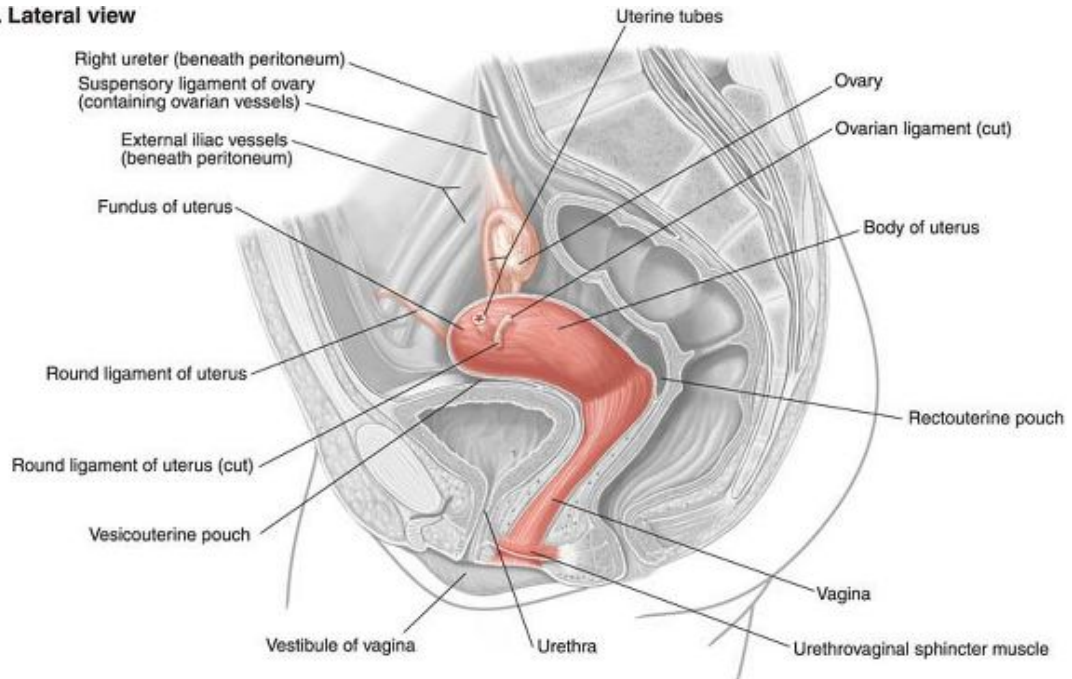



Plate 6-10 Urinary Bladder, Anterior View

A. Lateral view



B. Posterior view



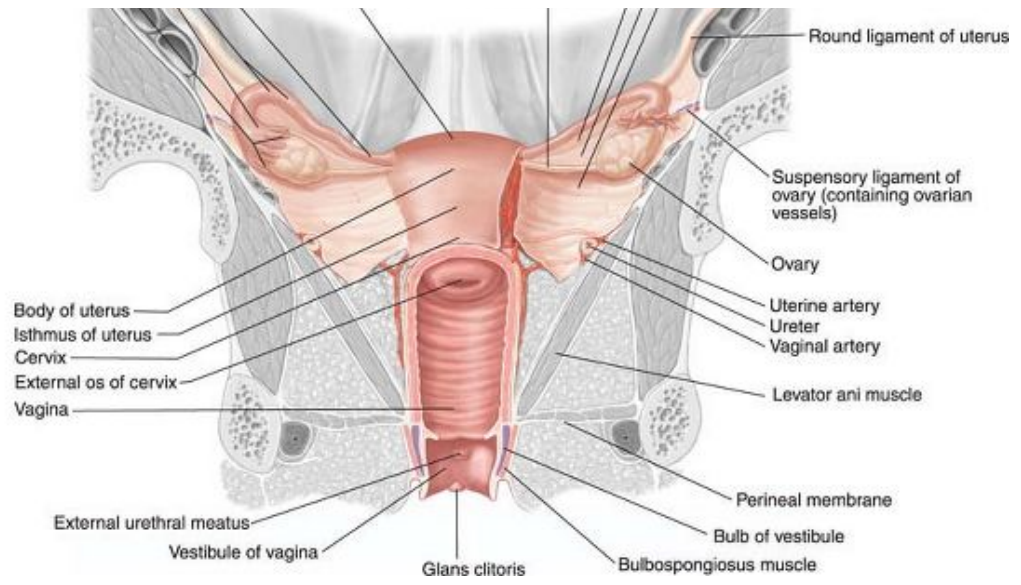
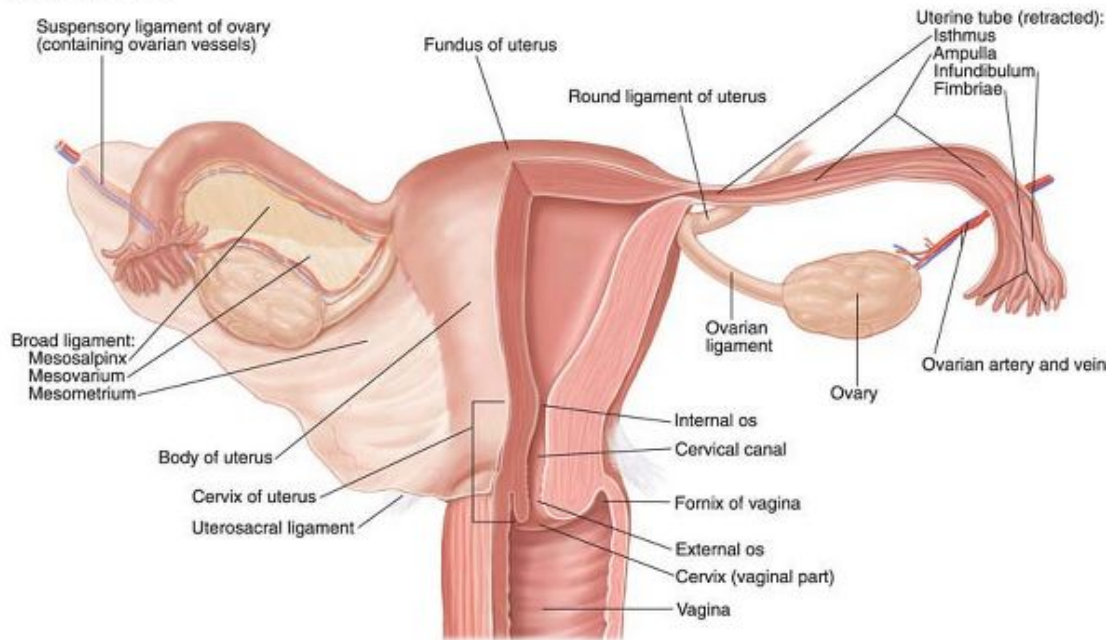


Plate 6-11 Uterus and Vagina I

A. Posterior view



B. Hysterosalpingogram

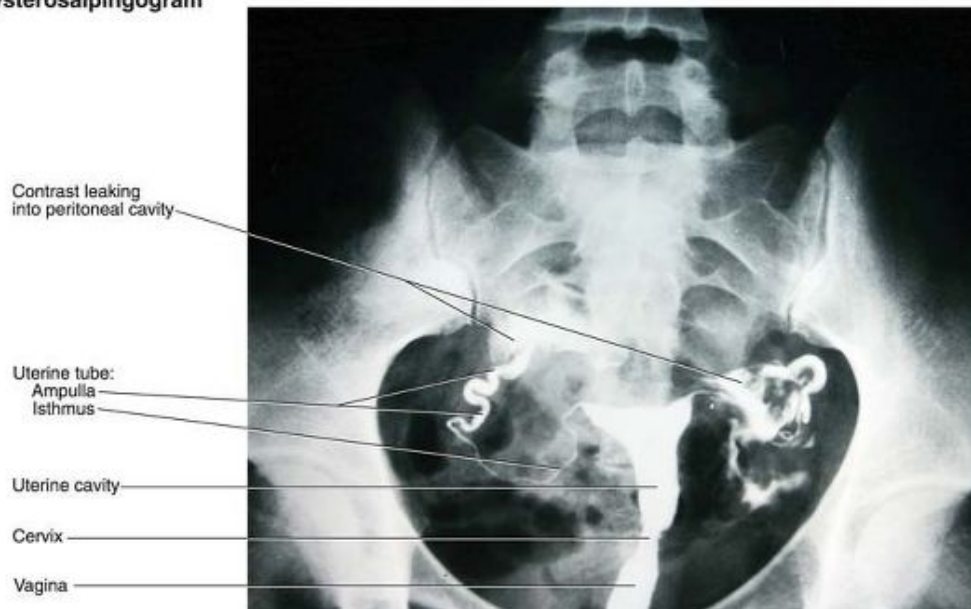
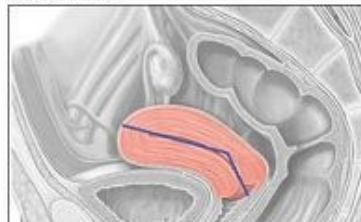

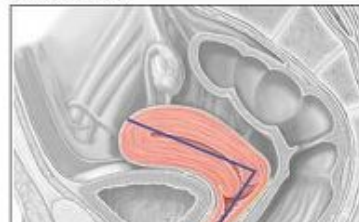Plate 6-12 Uterus and Vagina II

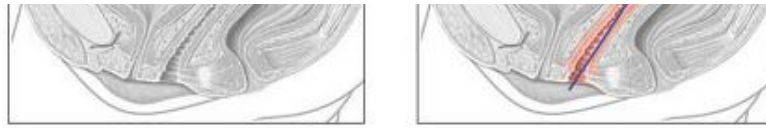A. Normal positions

Anteflexed

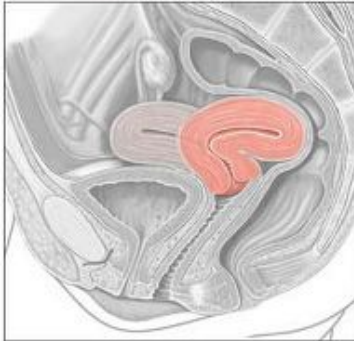


Anteverted

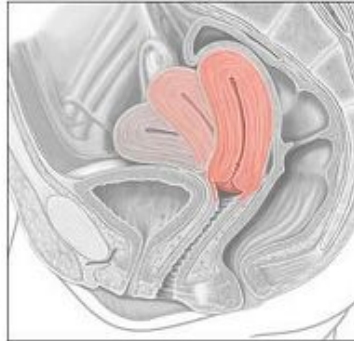




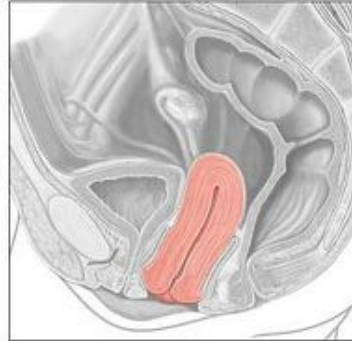
B. Retroflexed



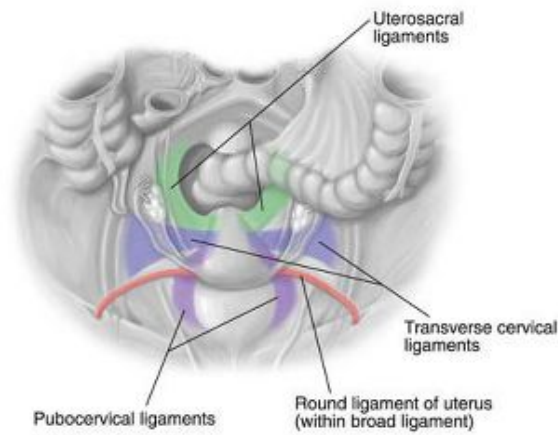
C. Retroverted



D. Prolapsed



E. Supporting structures of the uterus, superior view



F. Supporting structures of the uterus, lateral view

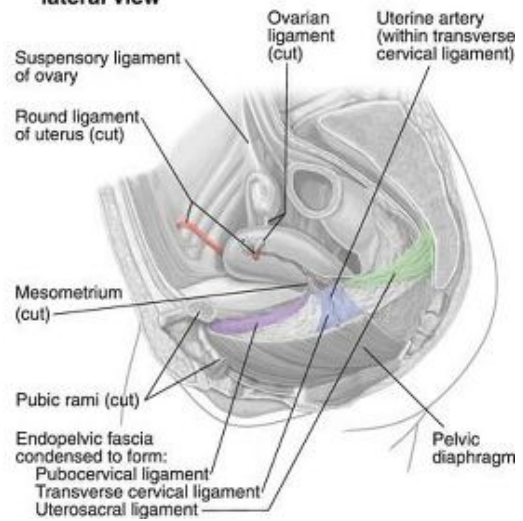
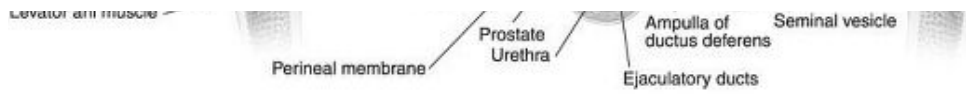


Plate 6-13 Positions and Supporting Structures of the Uterus



B. Vasogram

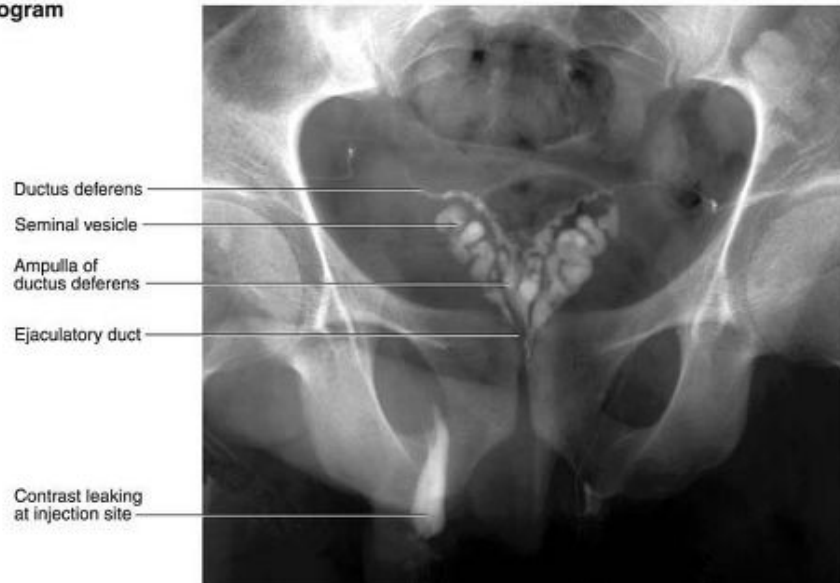
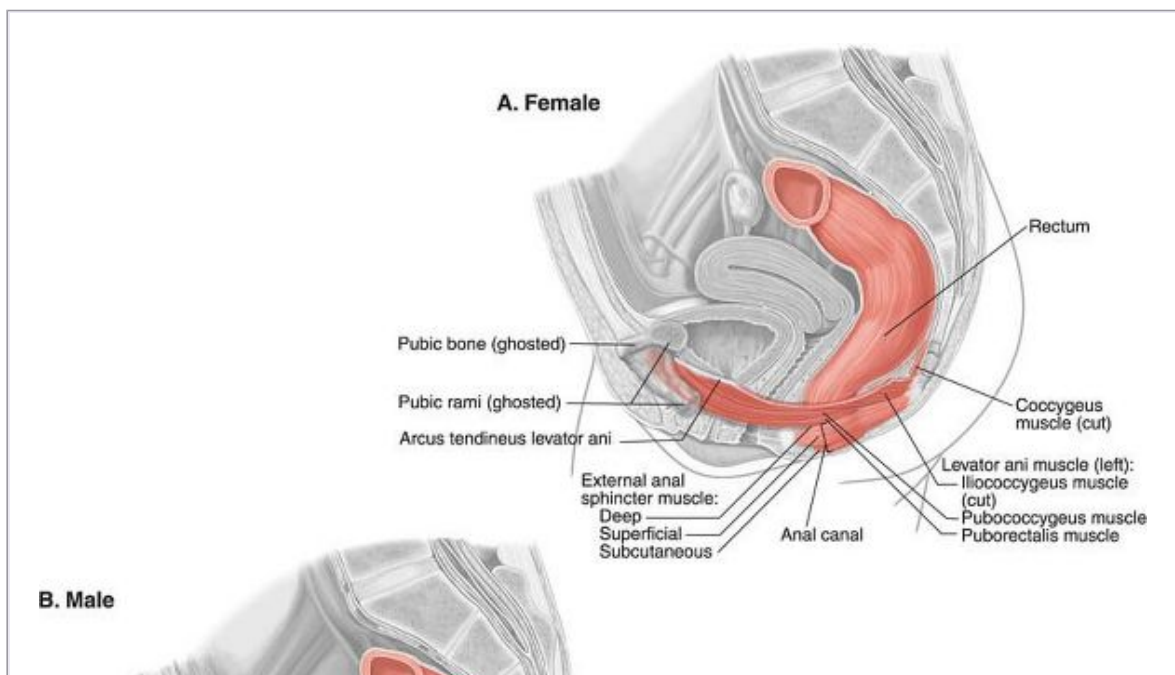


Plate 6-14 Male Internal Genitalia

P.272



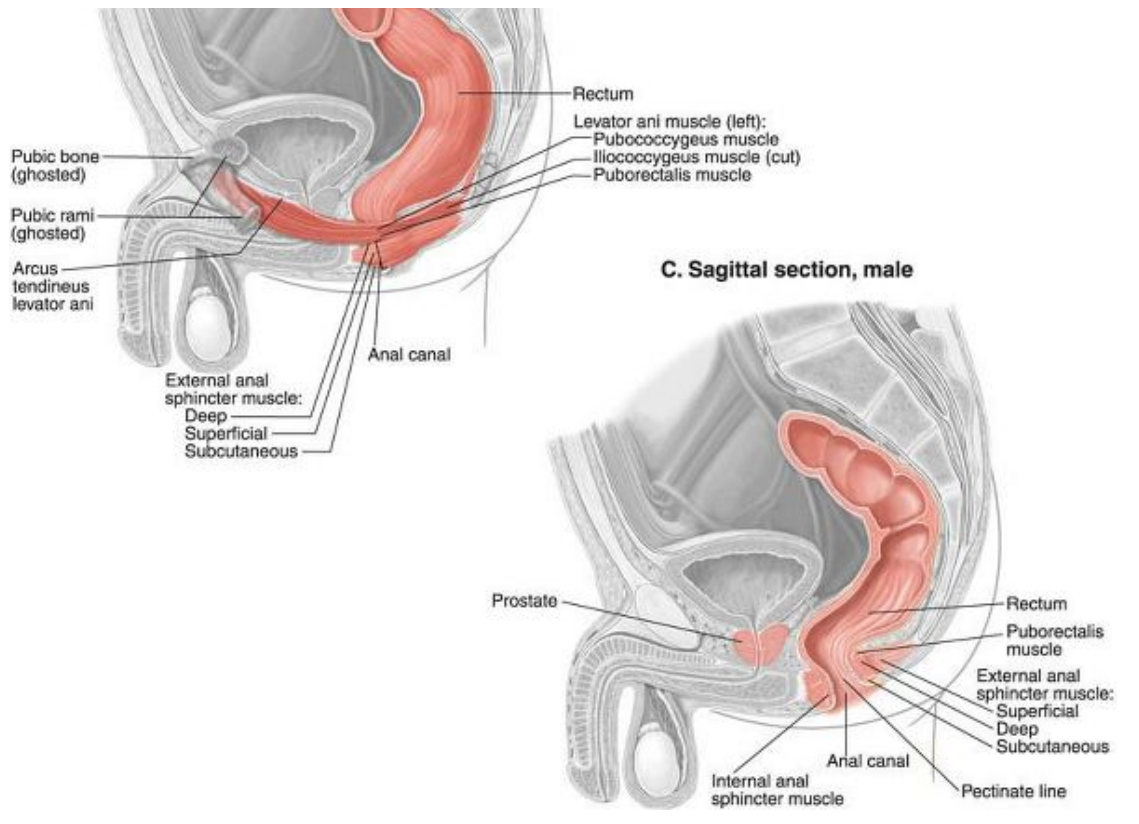


Plate 6-15 Rectum and Anal Canal, Relationships

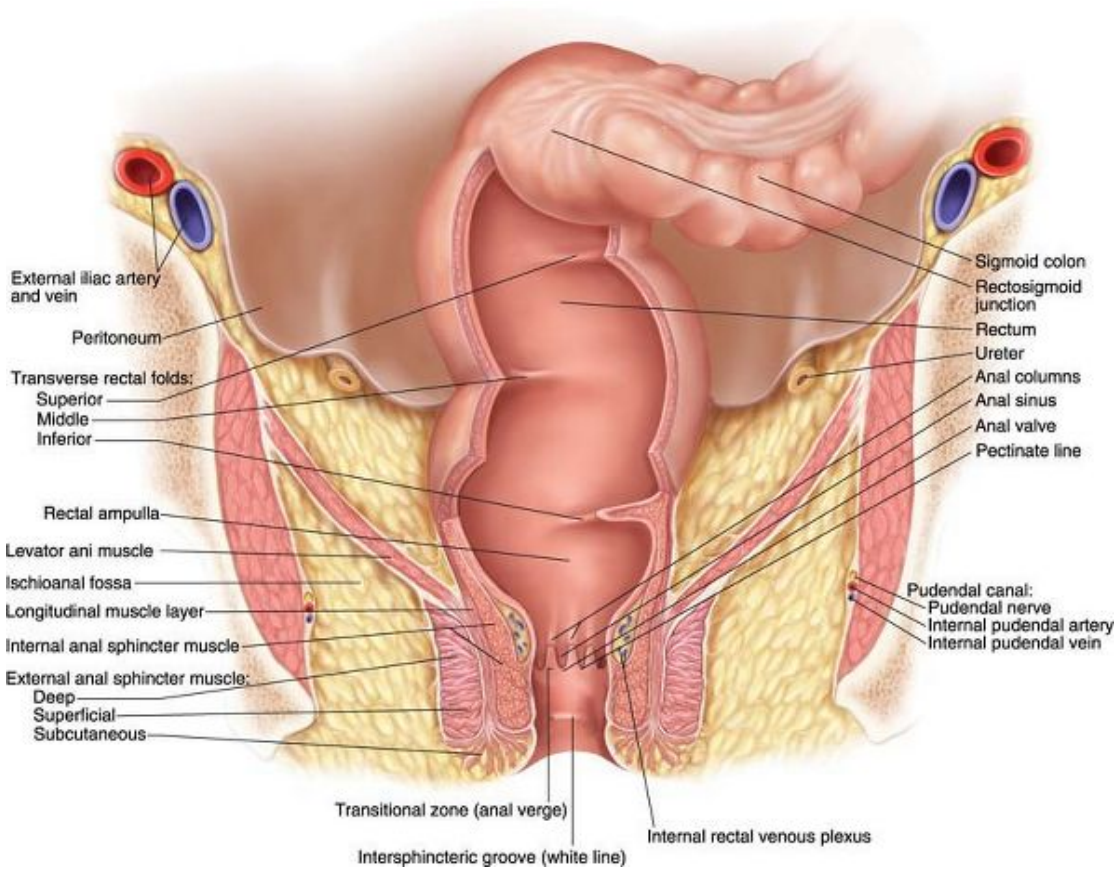
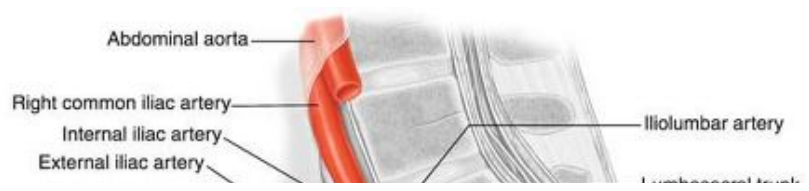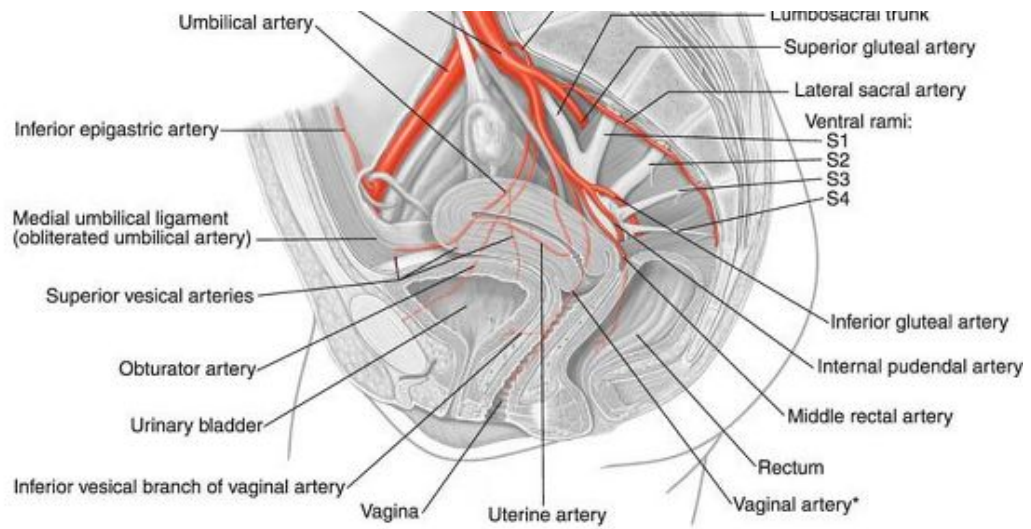


Plate 6-16 Rectum and Anal Canal, Internal Anterior View

A. Female





*Vaginal artery arises from uterine artery in 11% of cases

B. Male

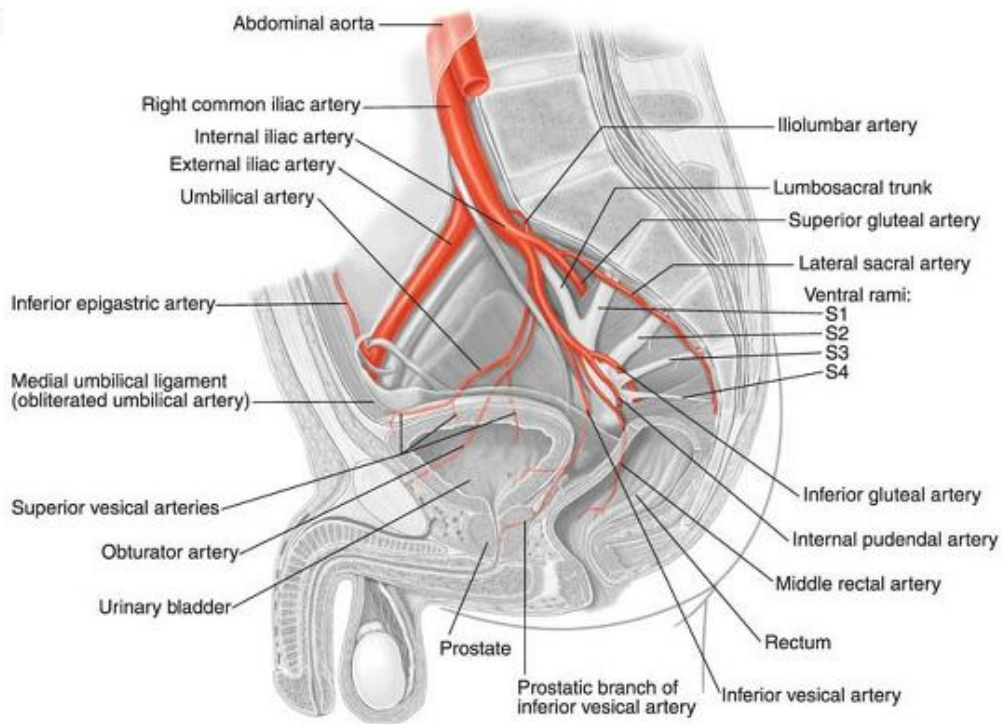
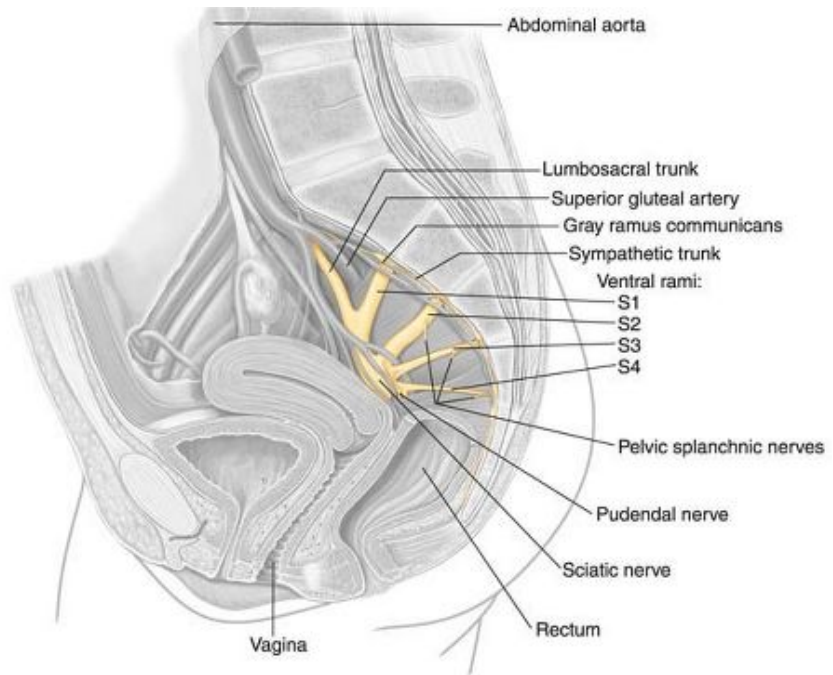


Plate 6-17 Blood Supply of the Pelvis

A. Medial view



Note:
Sacral plexus nerve branches
are the same in the male

B. Anterior view

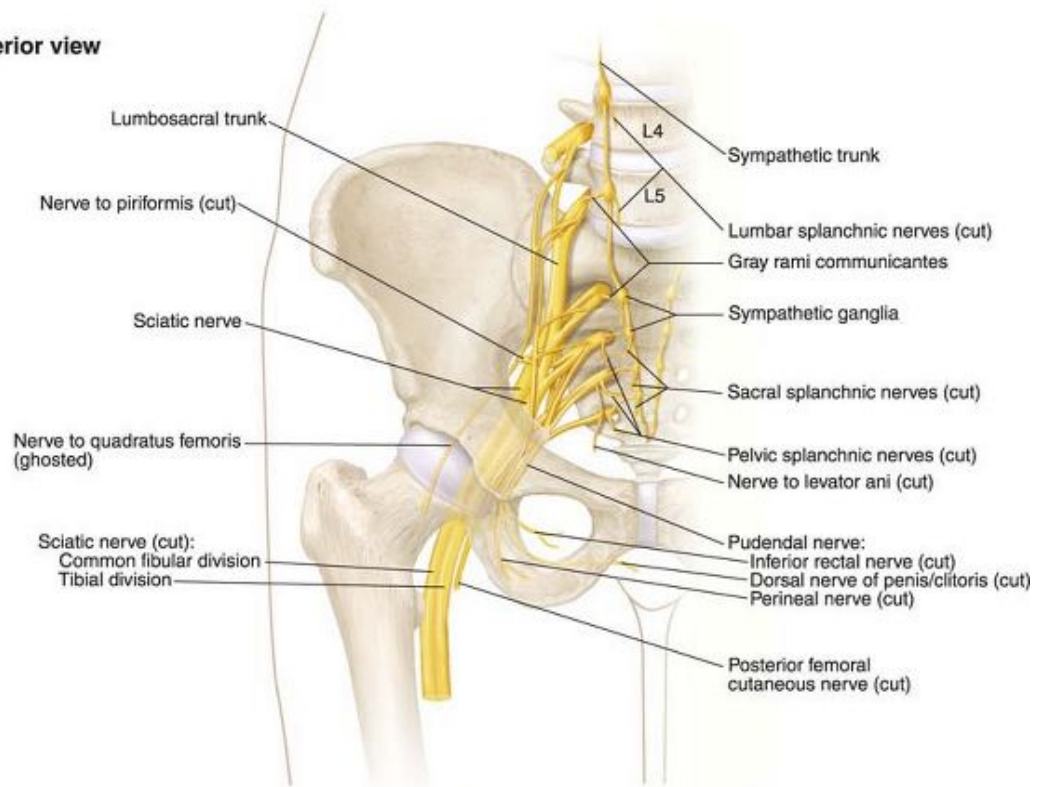
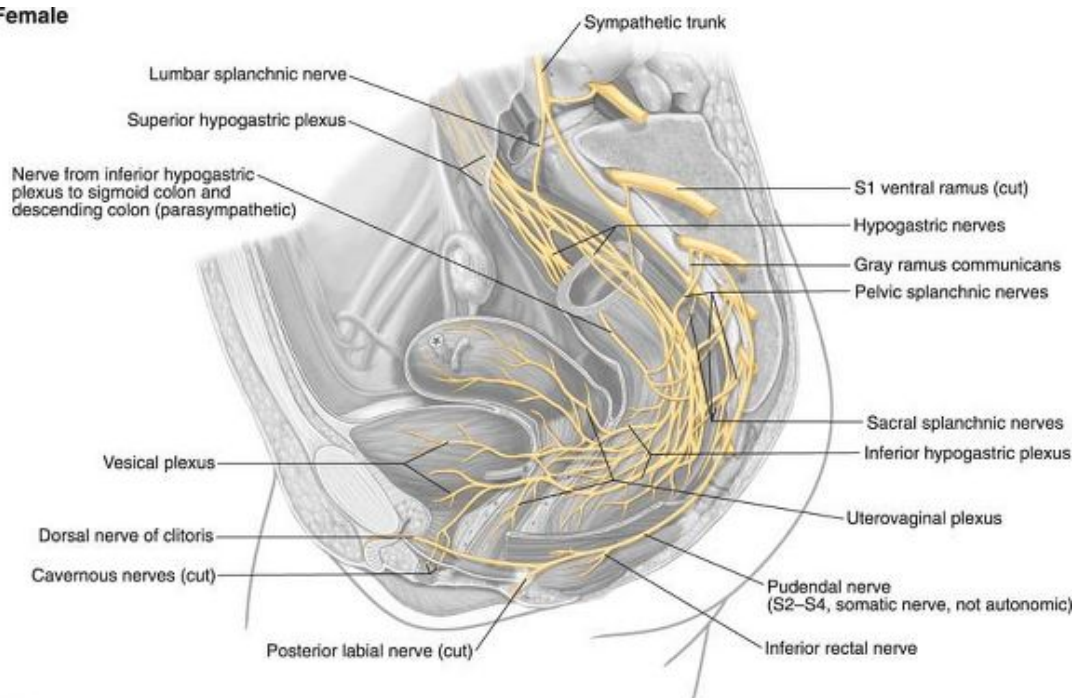
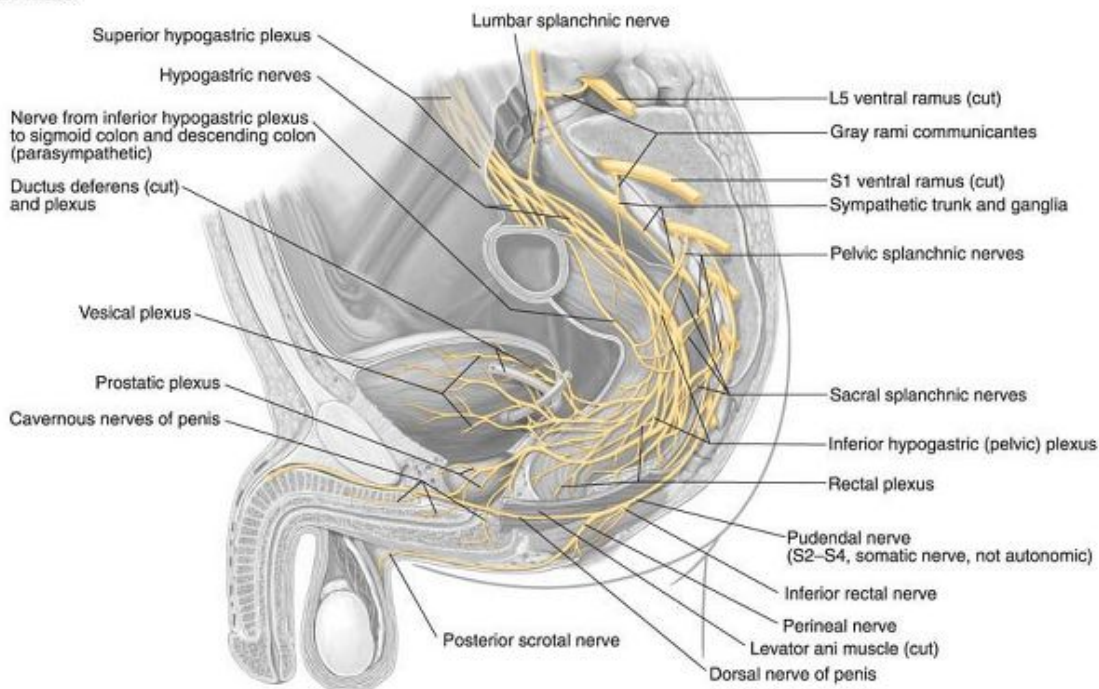


Plate 6-18 Sacral Plexus

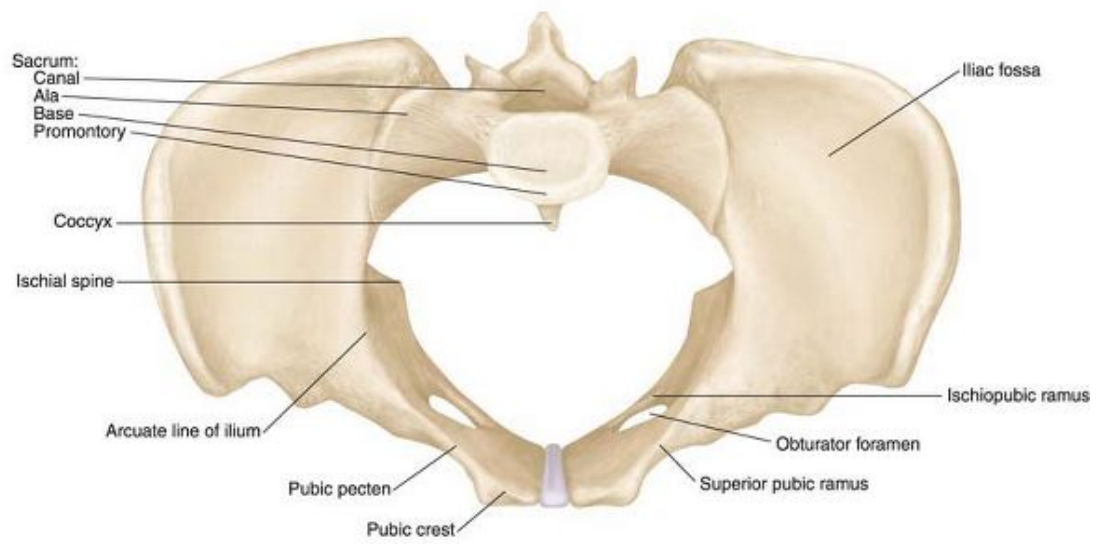
A. Female



B. Male



A. Female



B. Male

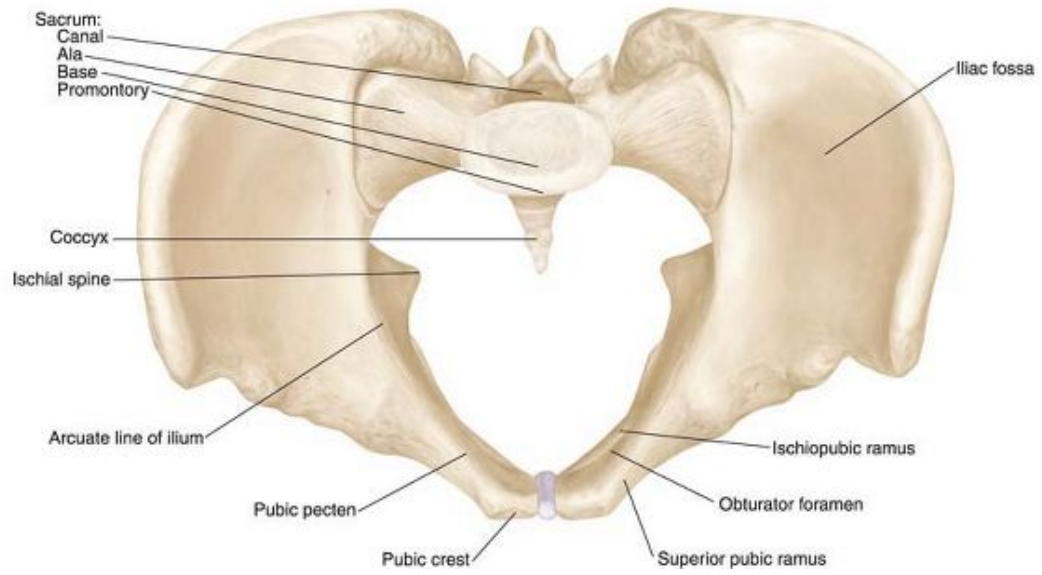
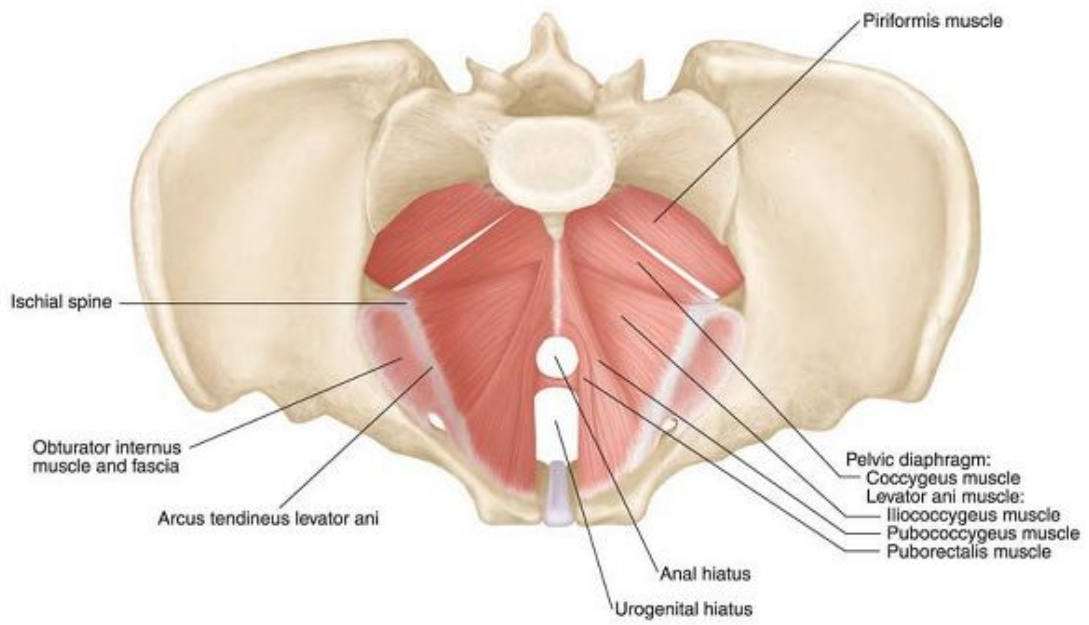
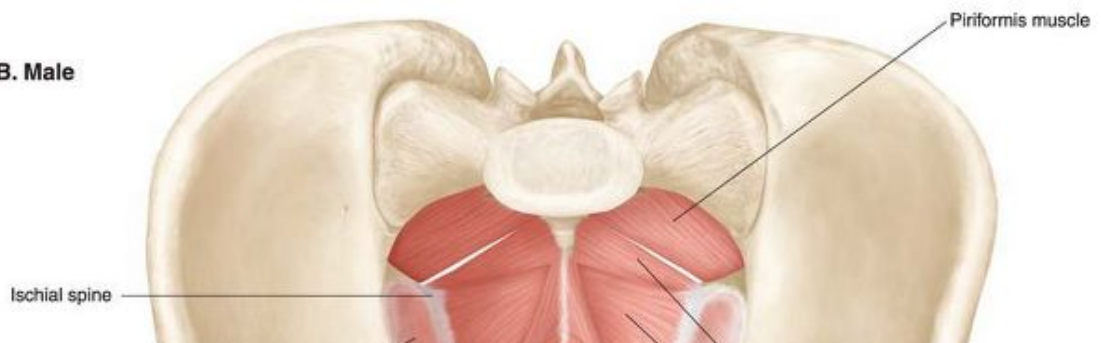

Plate 6-20 Pelvis, Superior View

A. Female



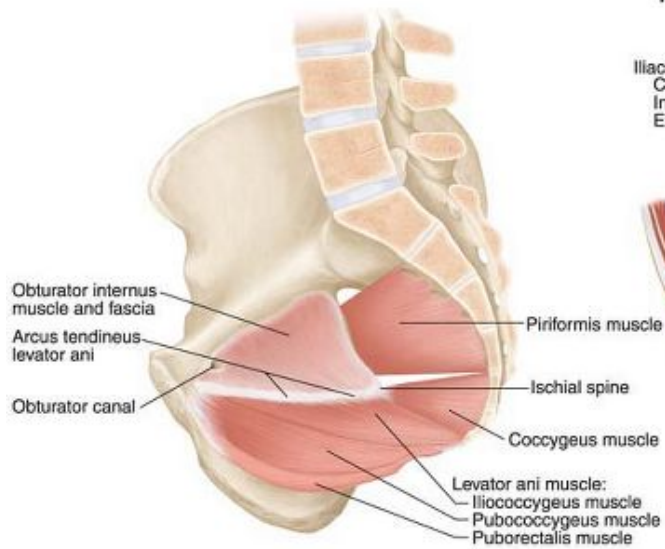
B. Male



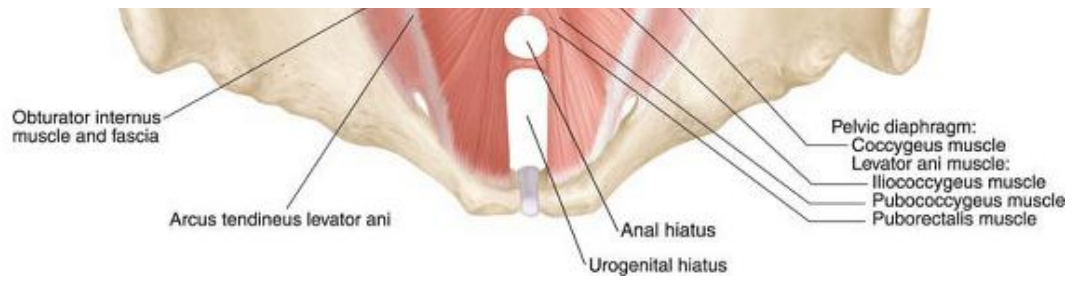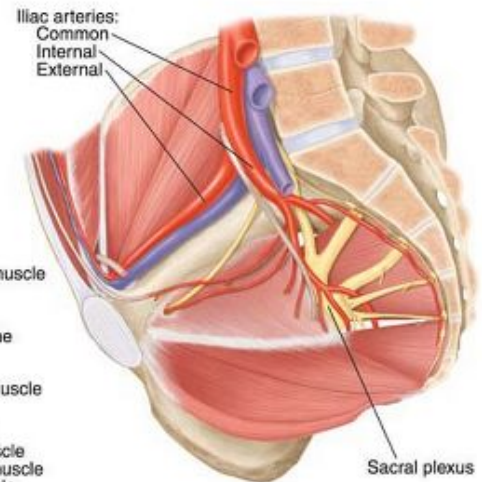


Plate 6-21 Pelvic Diaphragm, Superior View

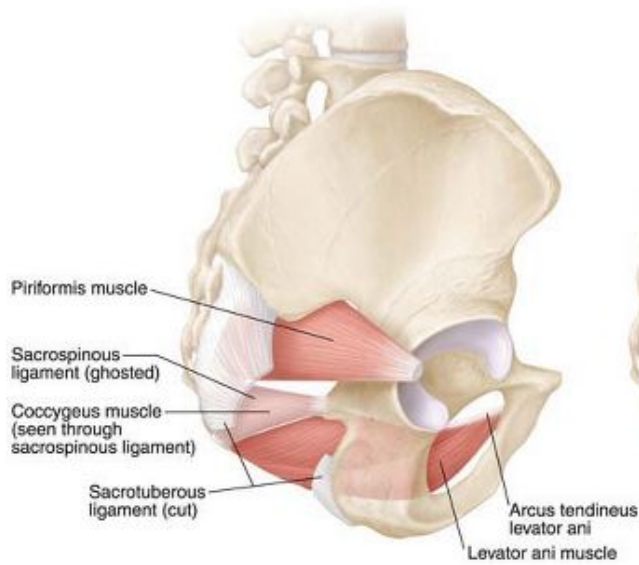
A. Medial view



B. Relationships to nerves and vessels, medial view



C. Lateral view



D. Relationships to nerves and vessels, lateral view

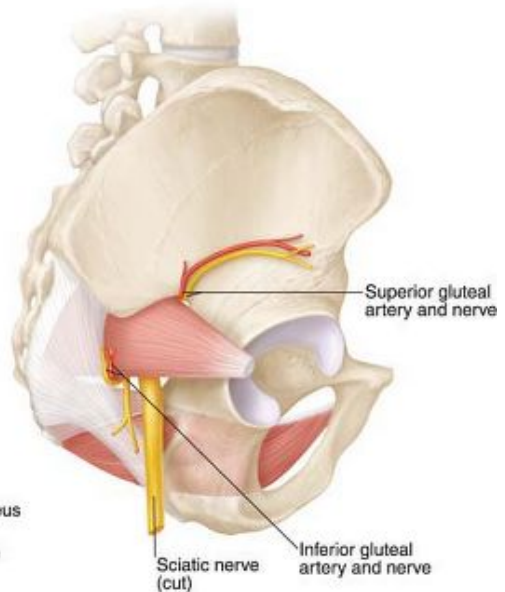
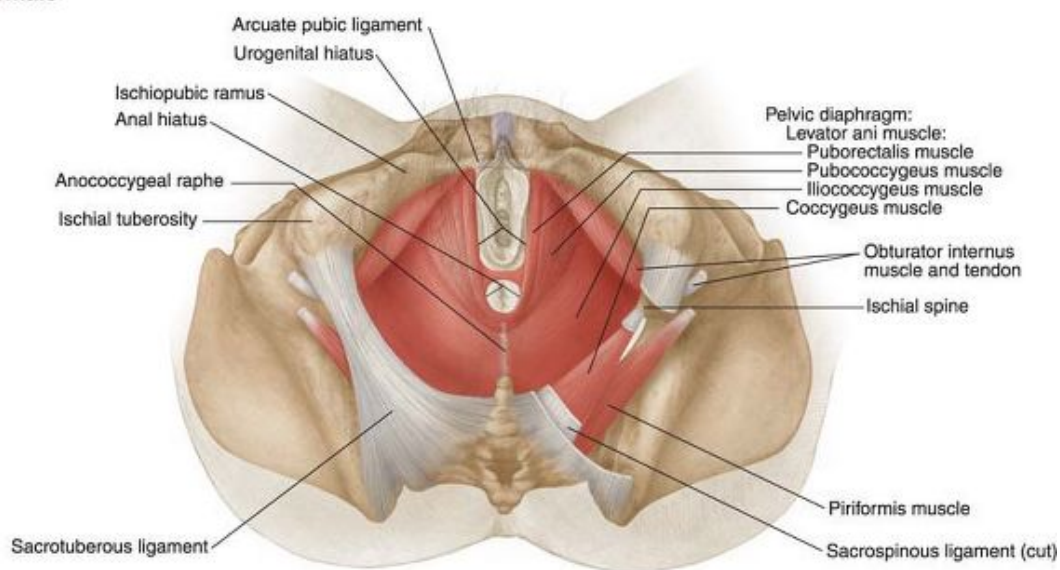


Plate 6-22 Muscles of the Pelvis

A. Female



B. Male

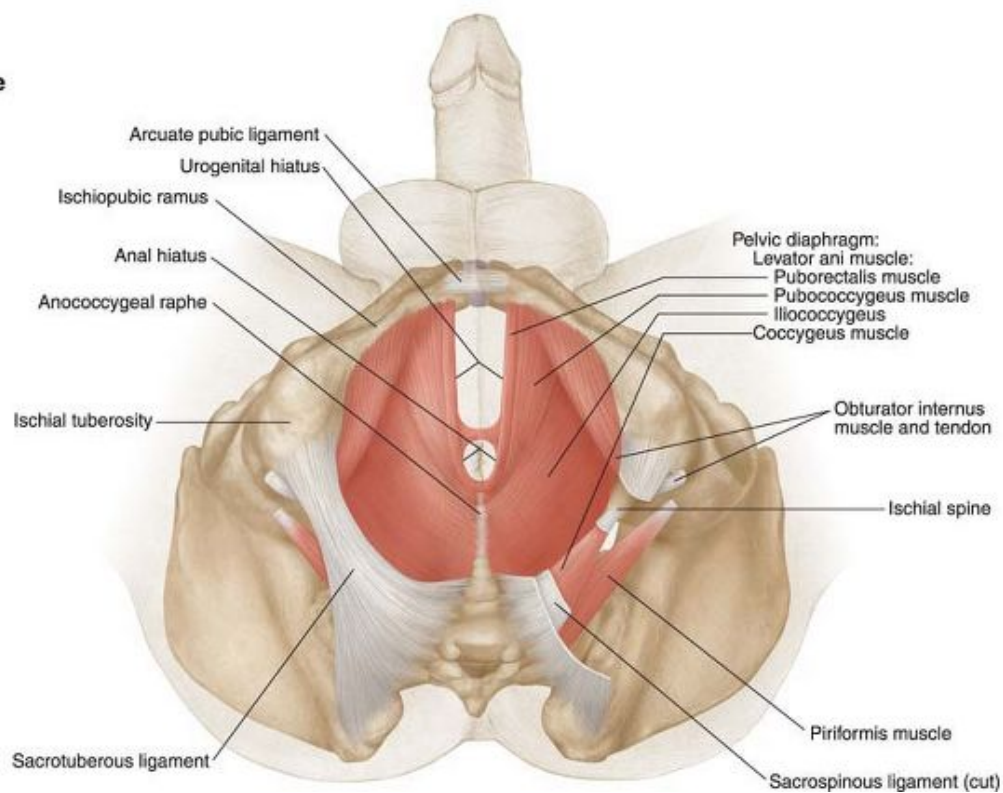


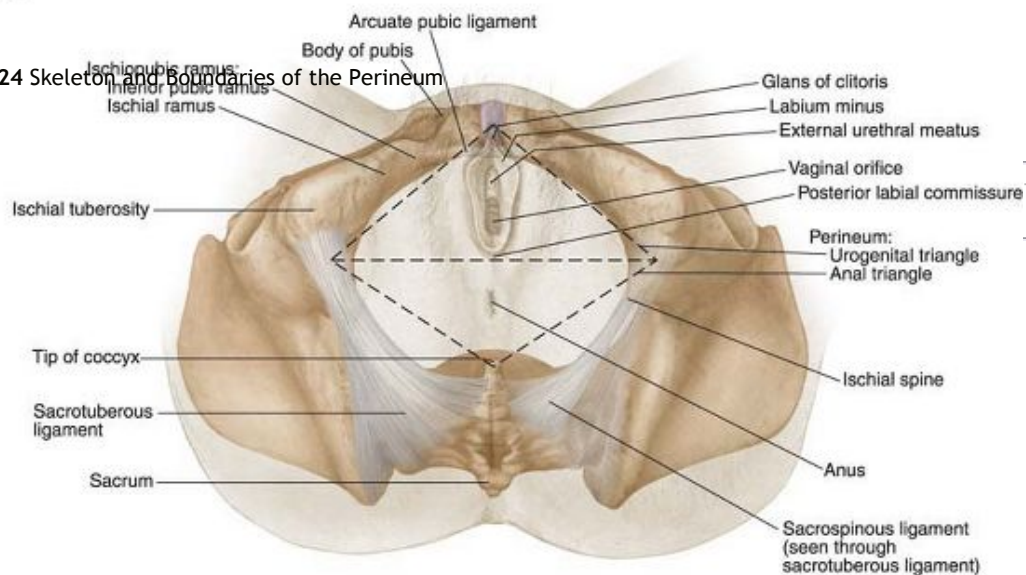
Plate 6-23 Pelvic Diaphragm, Inferior View

P.281

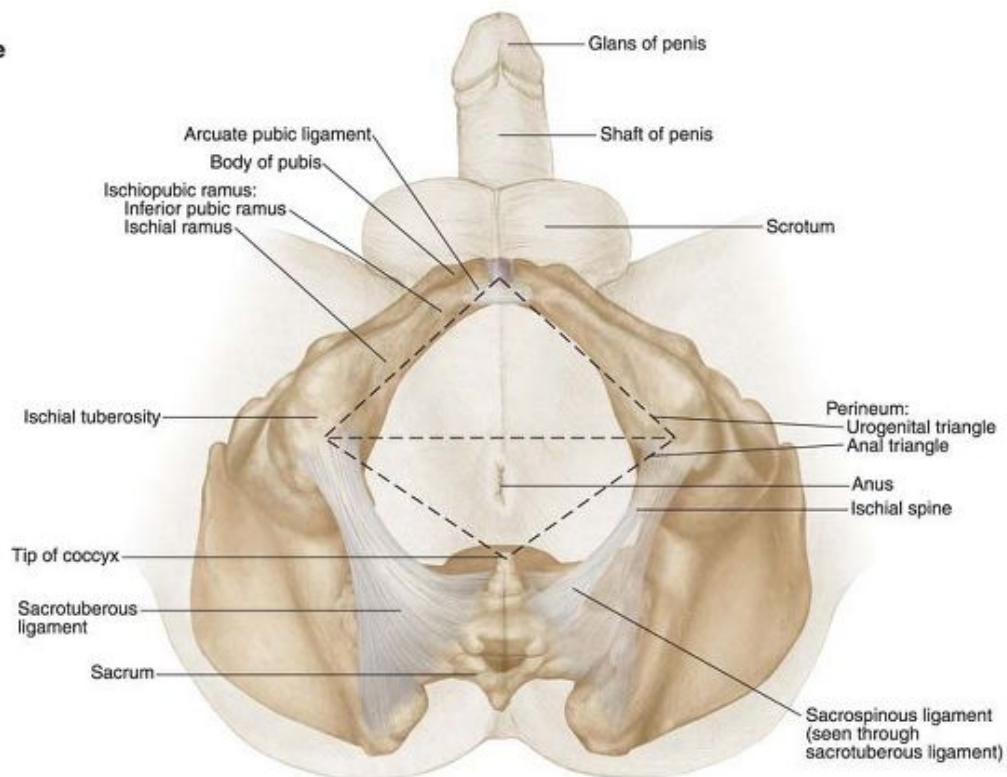


A. Female

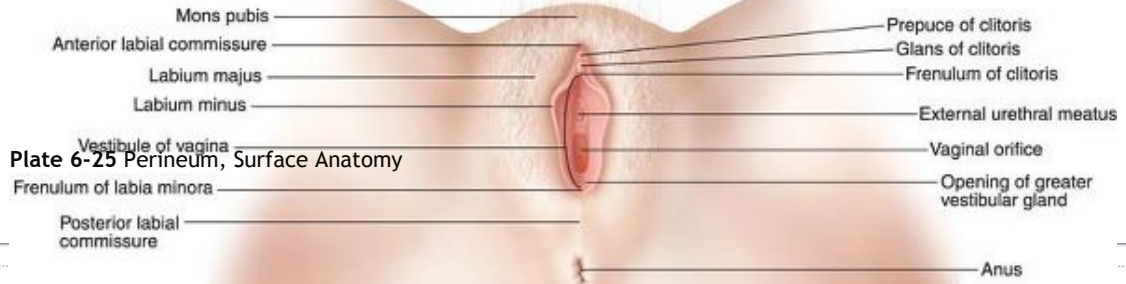Plate 6-24 Skeleton and Boundaries of the Perineum



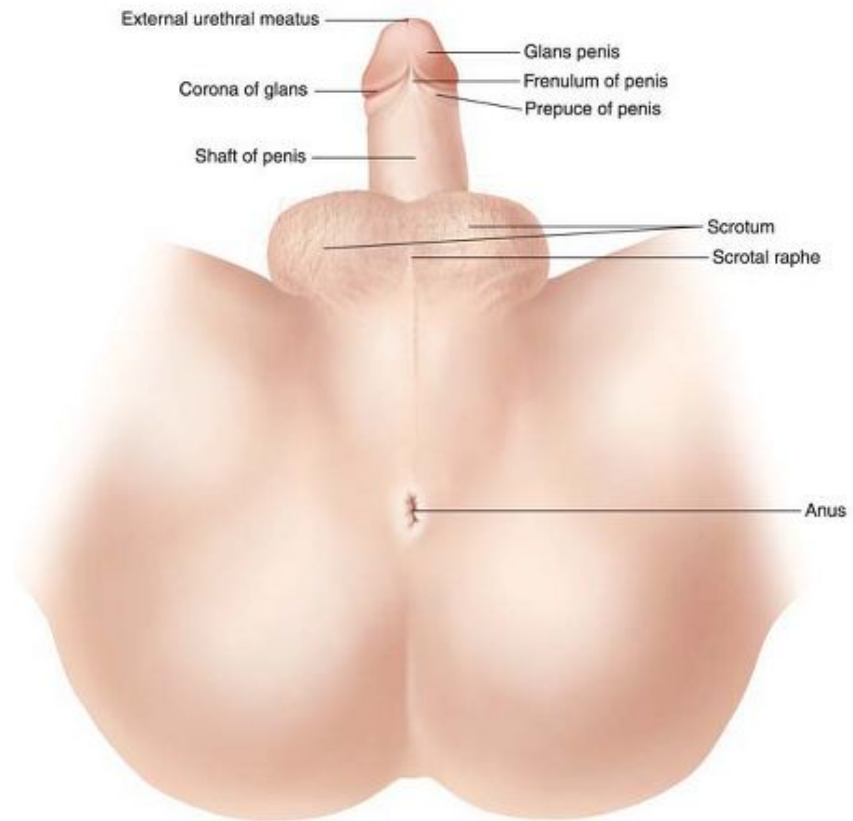
B. Male



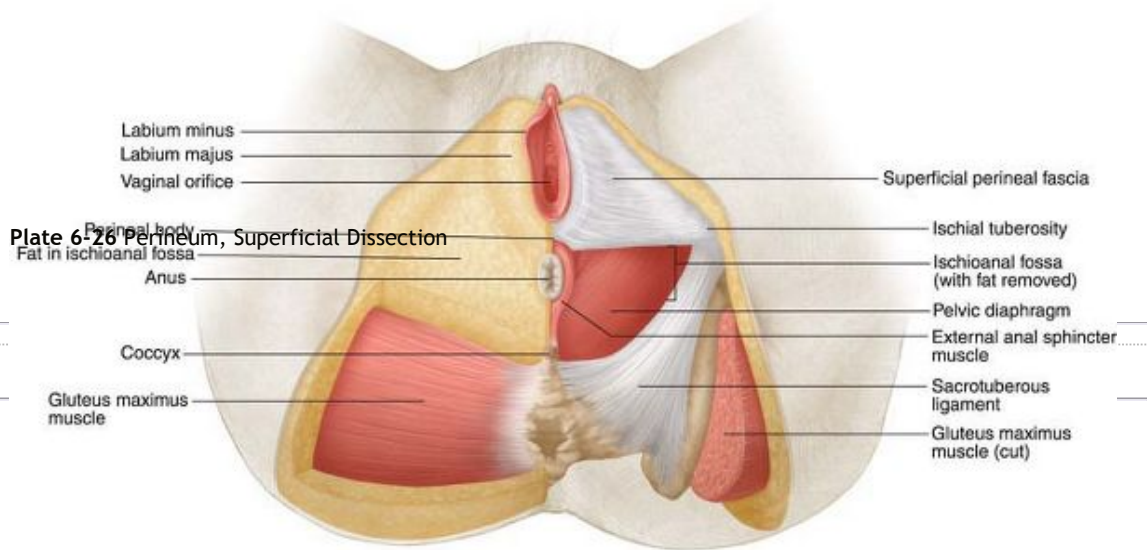
A. Female



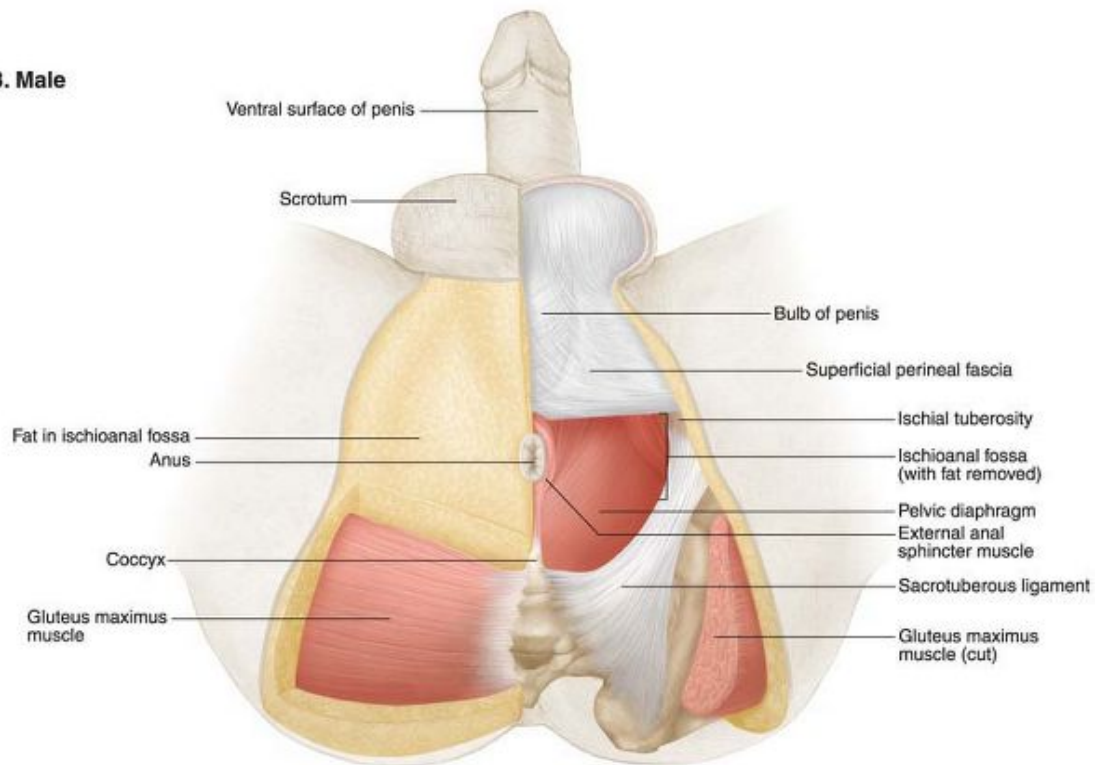
B. Male



A. Female



B. Male



A. Female

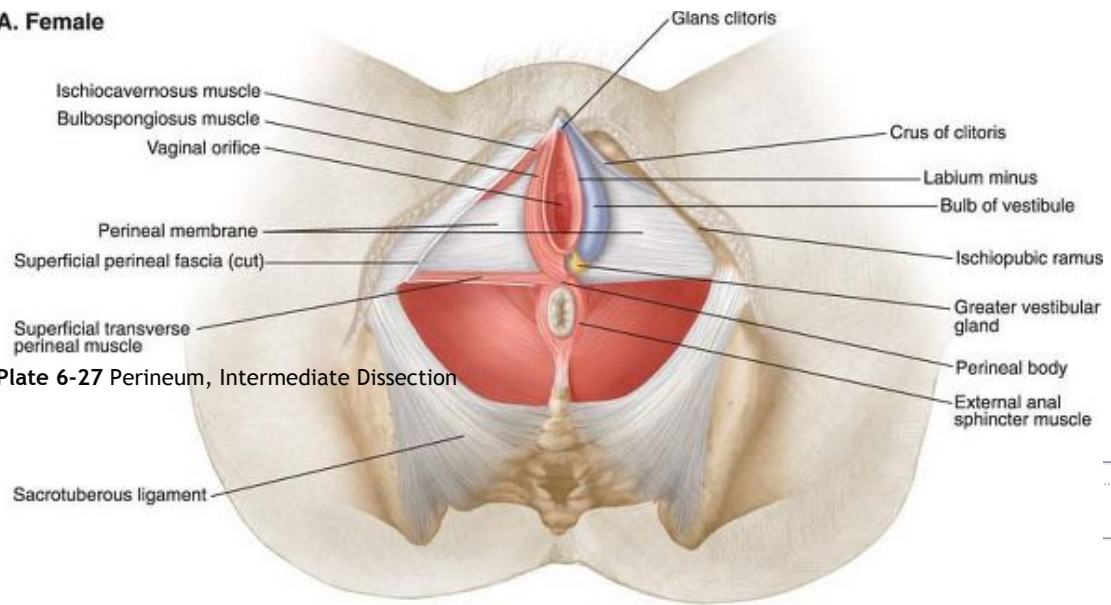
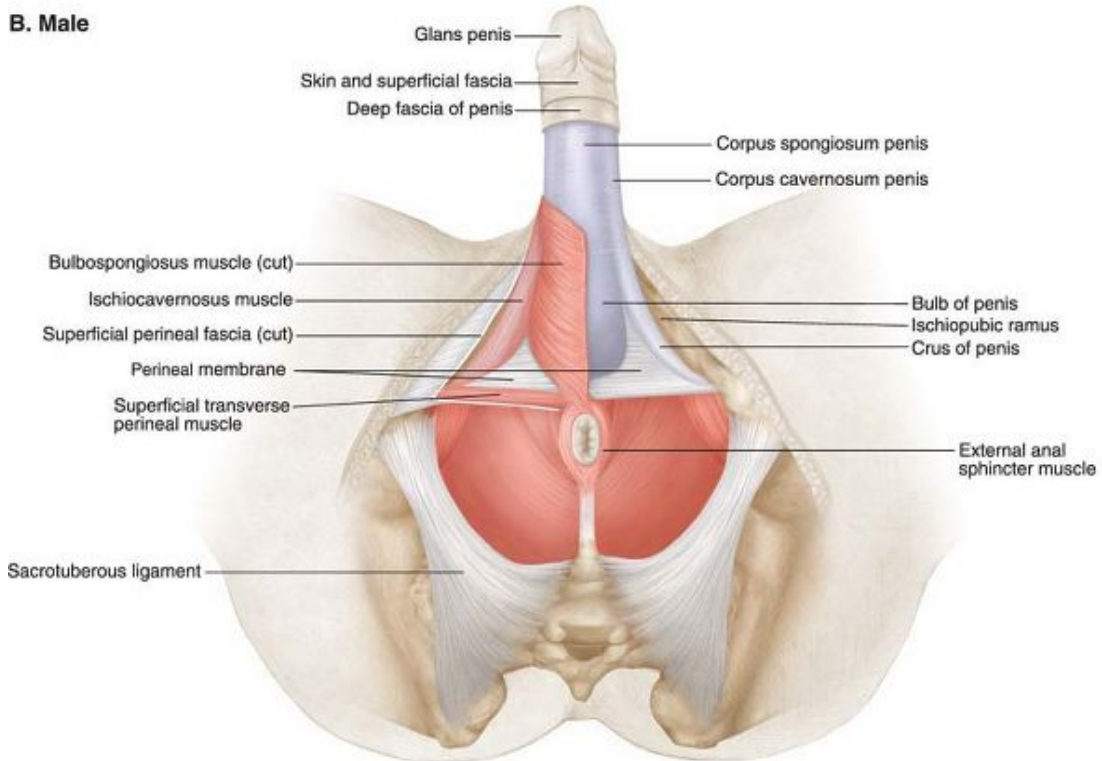
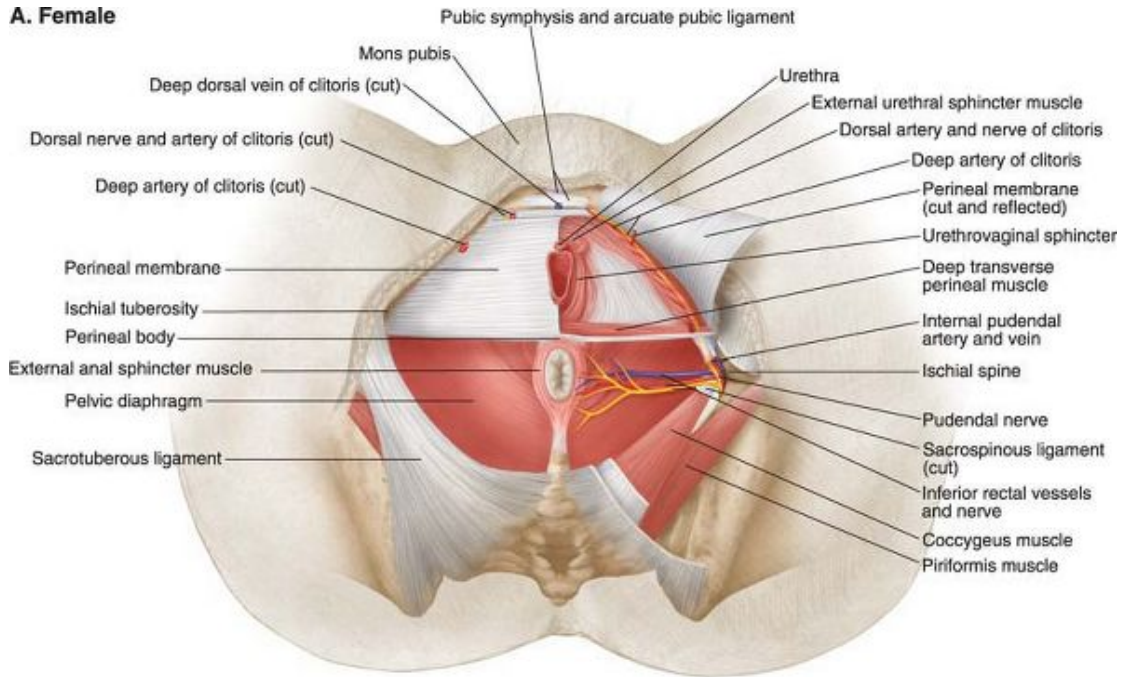


Plate 6-27 Perineum, Intermediate Dissection

B. Male



A. Female



B. Male

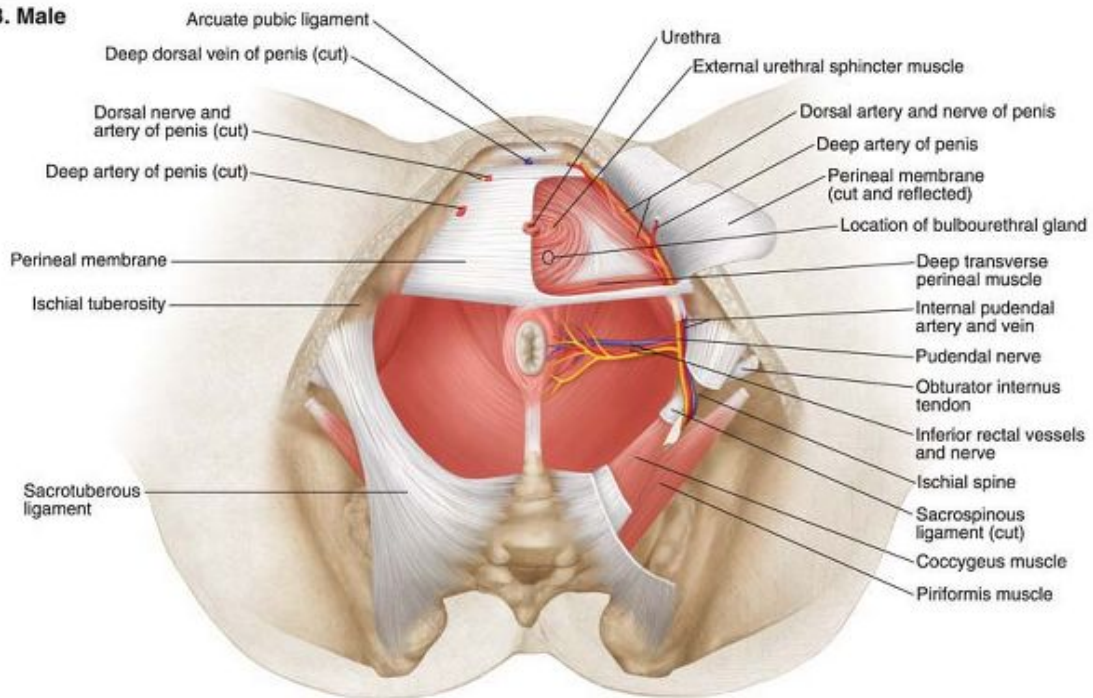
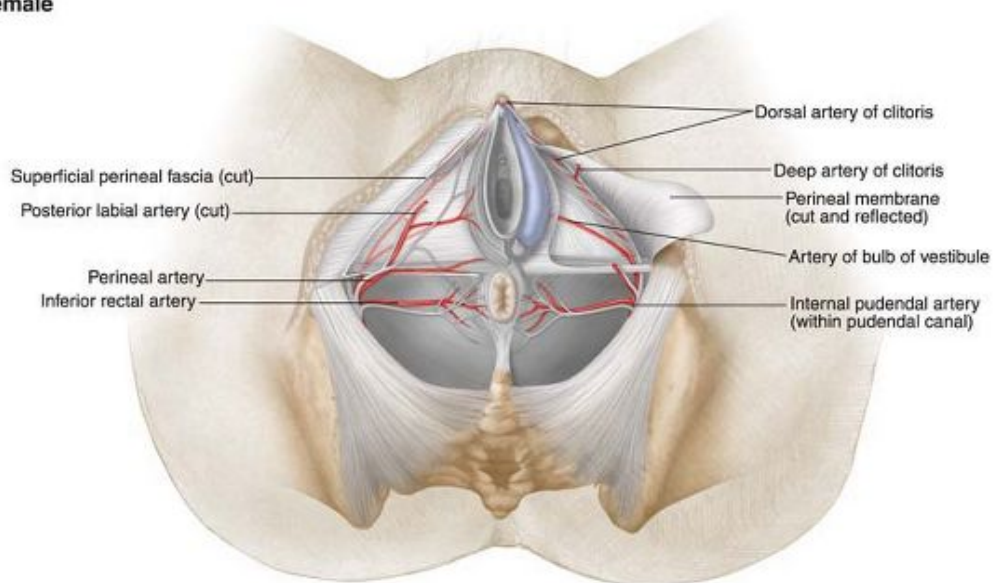


Plate 6-28 Perineum, Deep Dissection

A. Female



B. Male

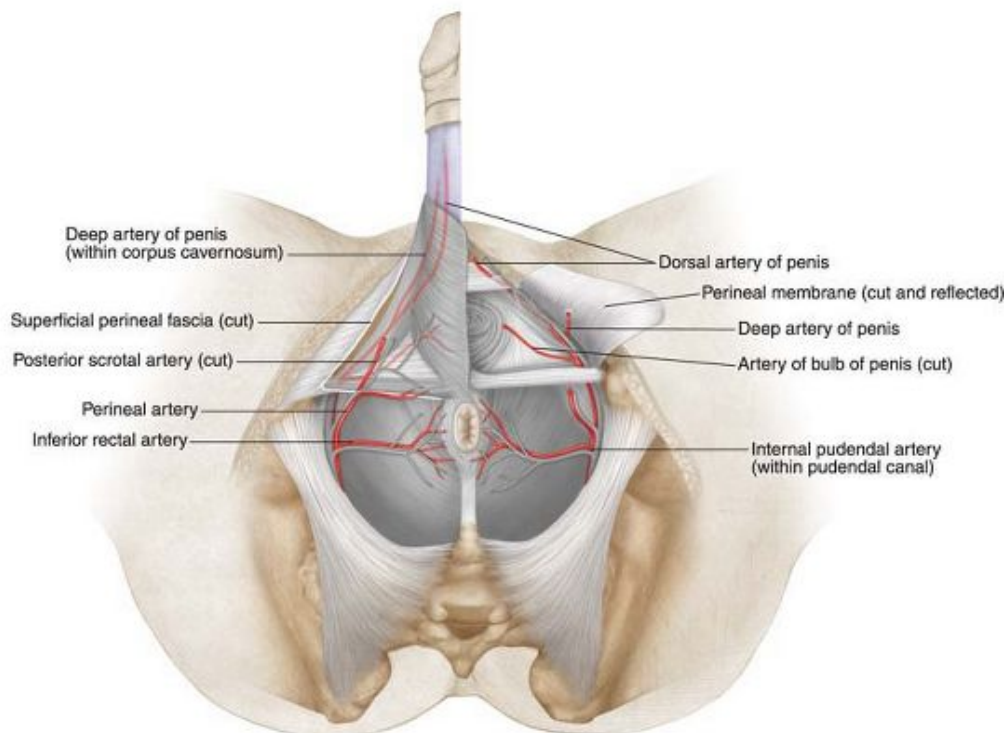
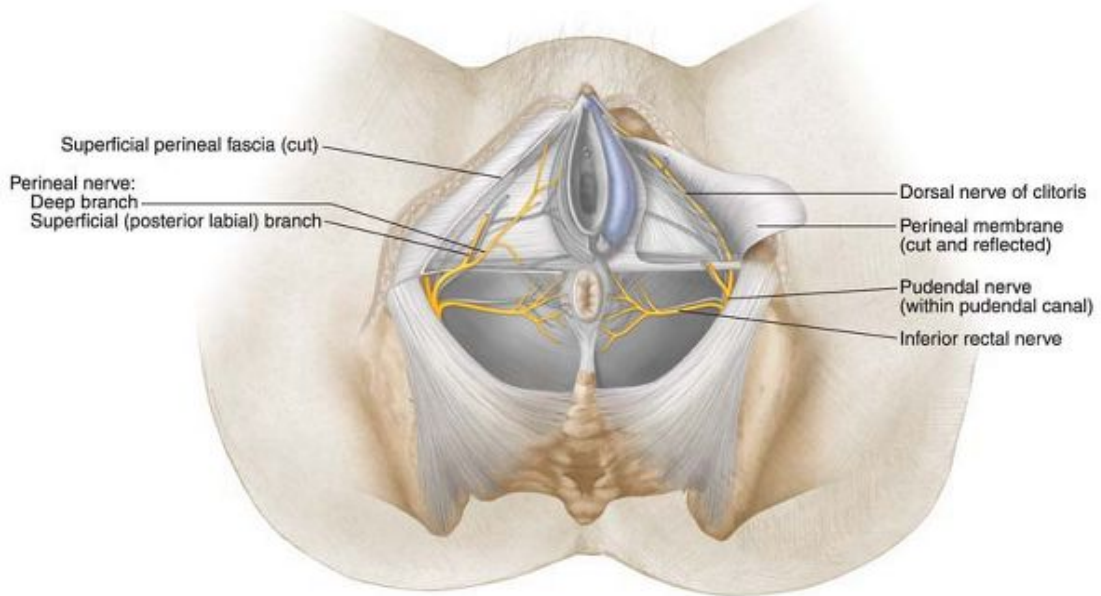


Plate 6-29 Arteries of the Perineum

A. Female



B. Male

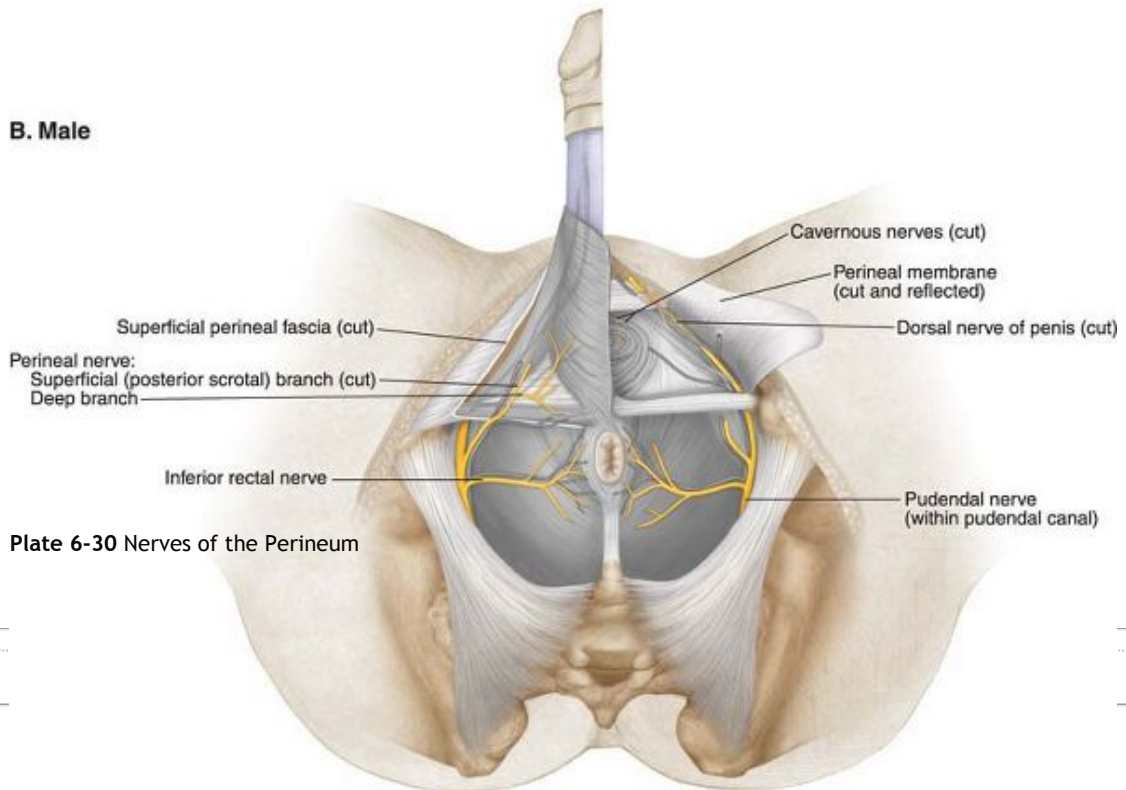
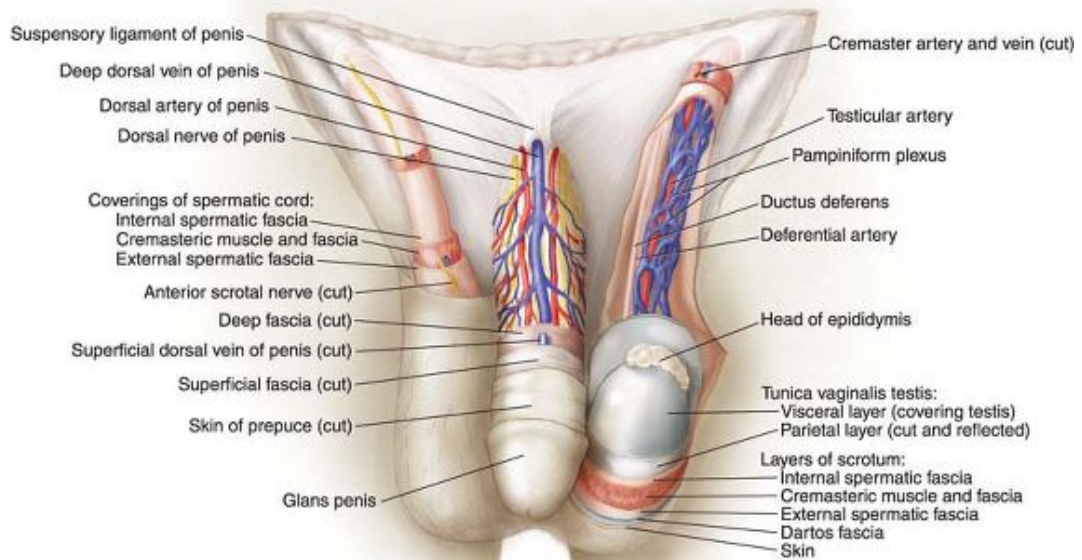


Plate 6-30 Nerves of the Perineum

A. Anterior view



B. Lateral view

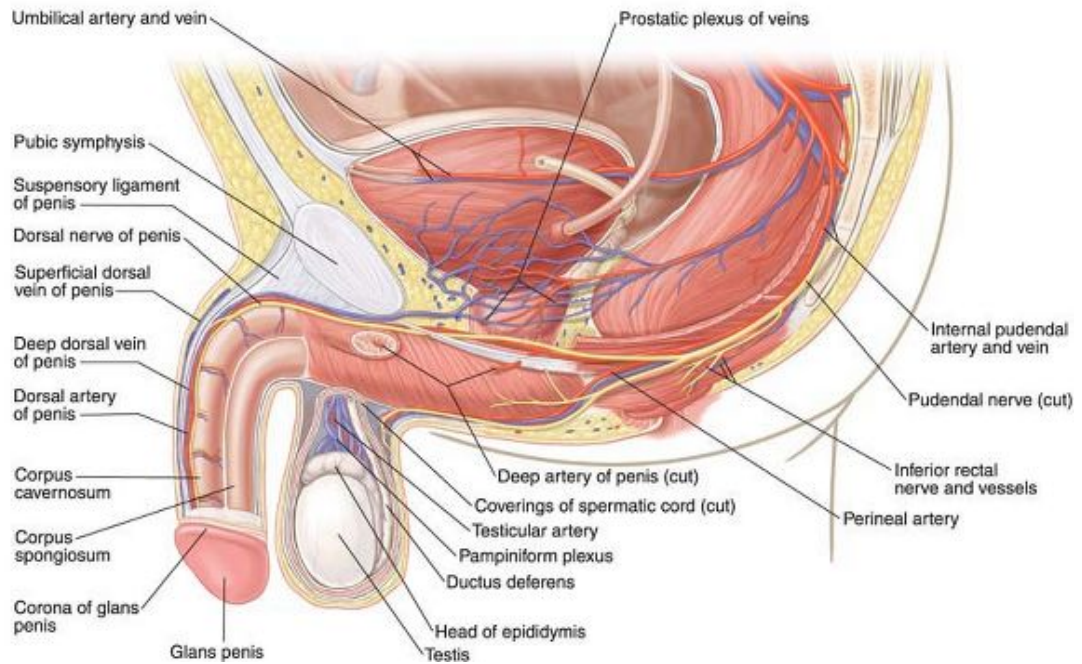
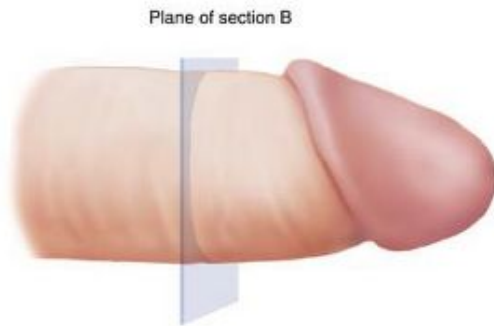


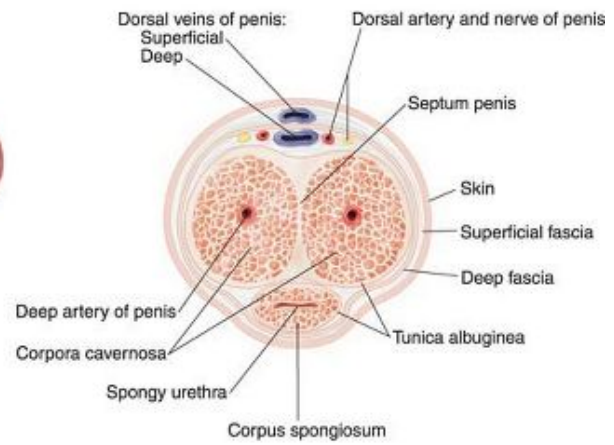
Plate 6-31 Penis and Testes

P.289

A. Orientation



B. Section through penis



C. Section through testis

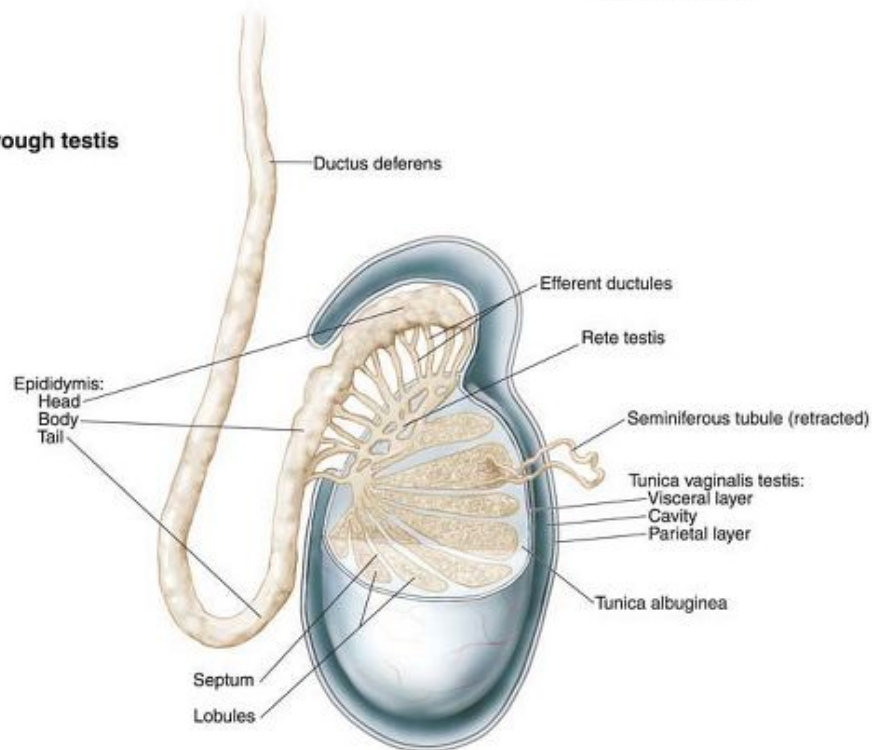


Plate 6-32 Sectional View of Penis and Testis

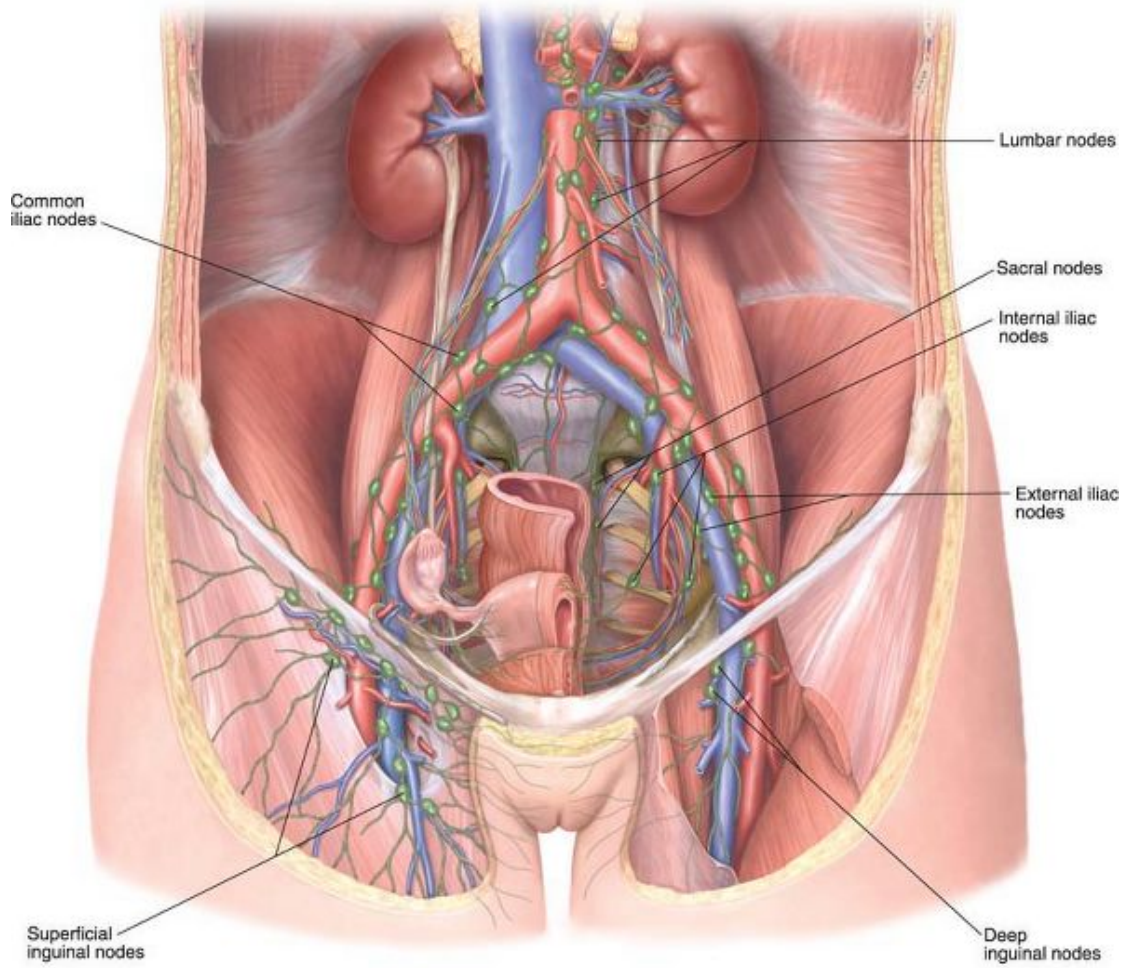


Plate 6-33 Lymphatics of the Pelvis and Perineum, Female

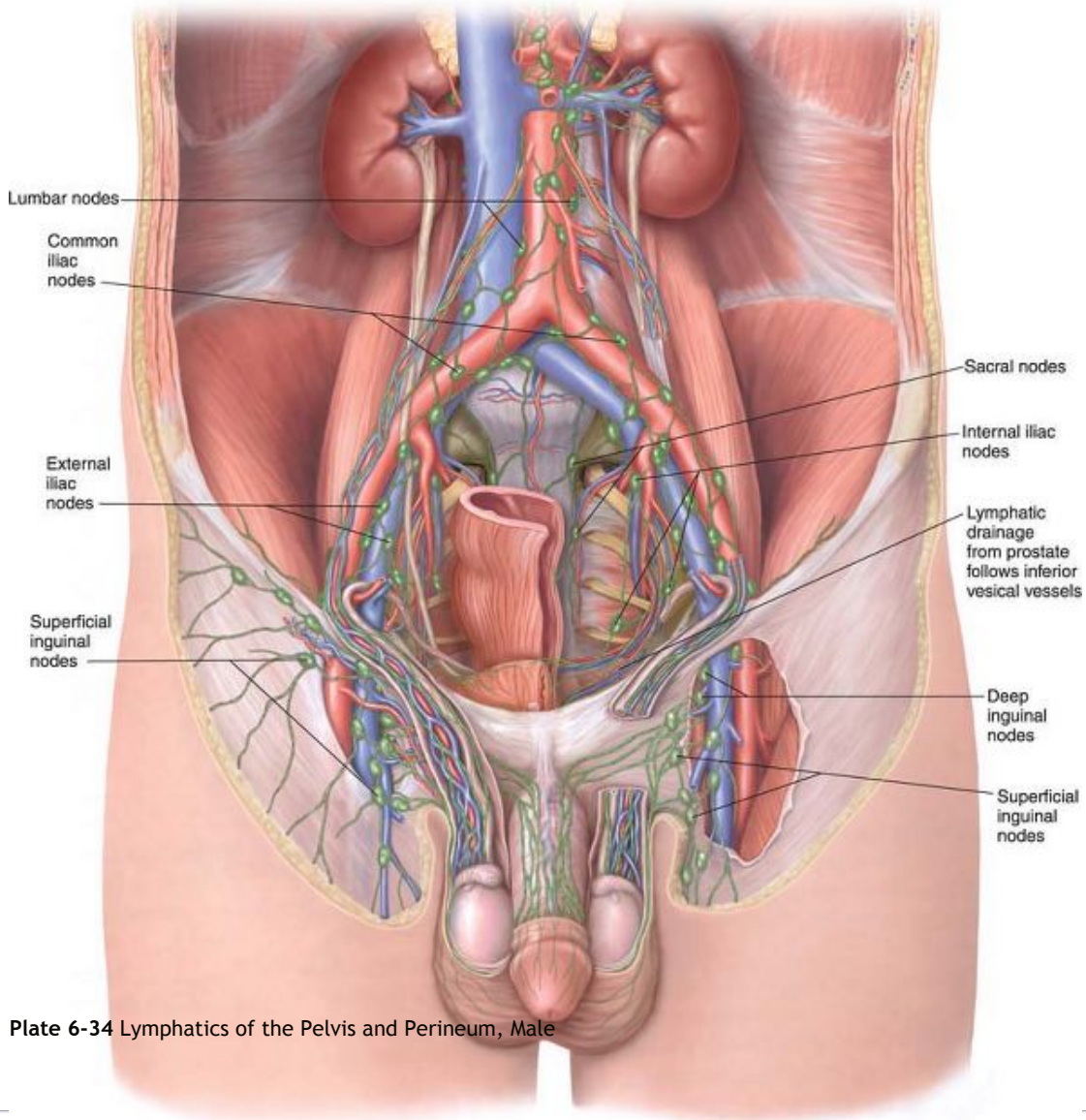
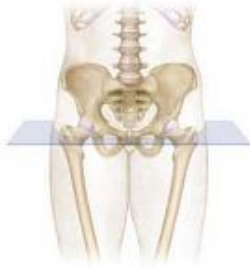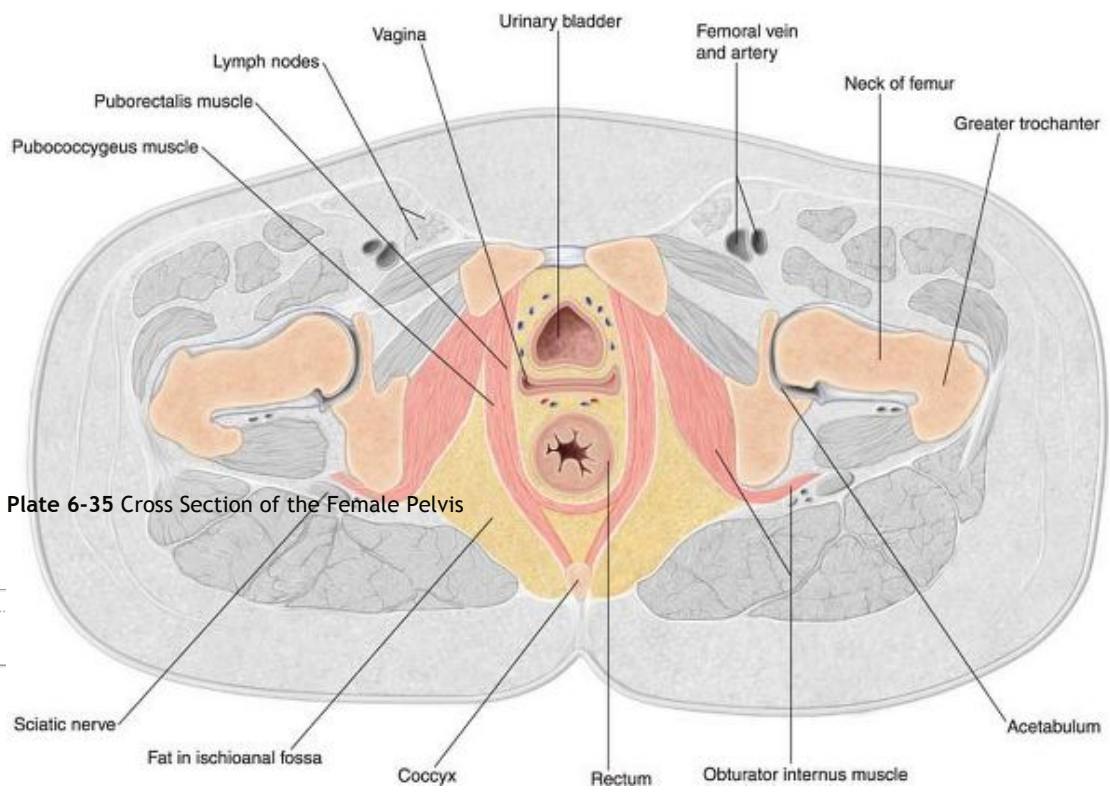


Plate 6-34 Lymphatics of the Pelvis and Perineum, Male

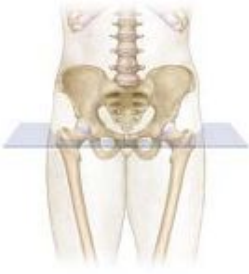A. Orientation



B. Cross section



A. Orientation



B. Cross section

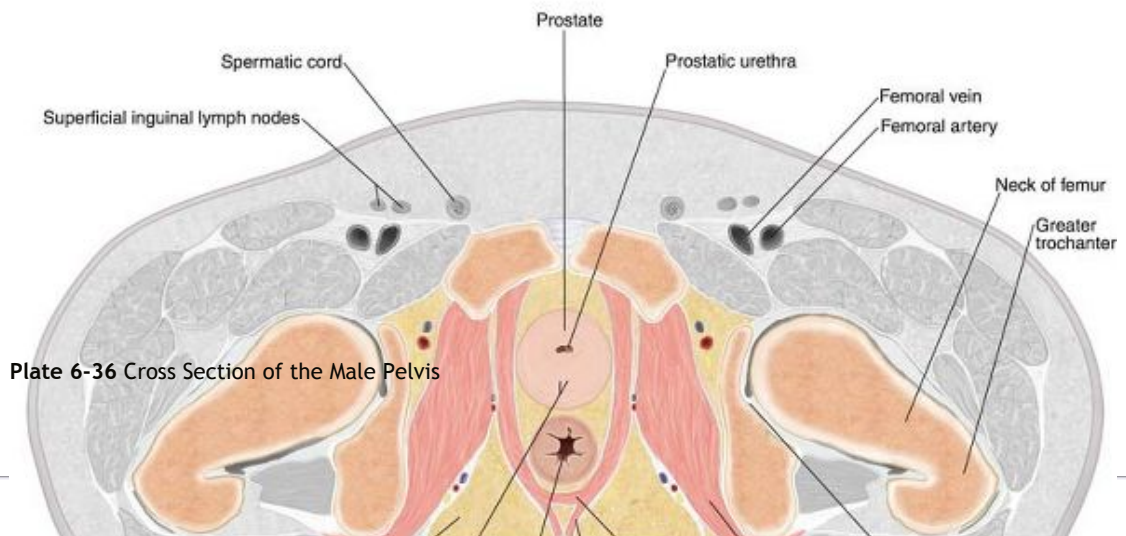


Plate 6-36 Cross Section of the Male Pelvis

Authors: Tank, Patrick W.; Gest, Thomas R.

Title: *Lippincott Williams & Wilkins Atlas of Anatomy, 1st Edition*

Copyright ©2009 Lippincott Williams & Wilkins

> Table of Contents > Chapter 7 - The Head and Neck

Chapter 7

The Head and Neck

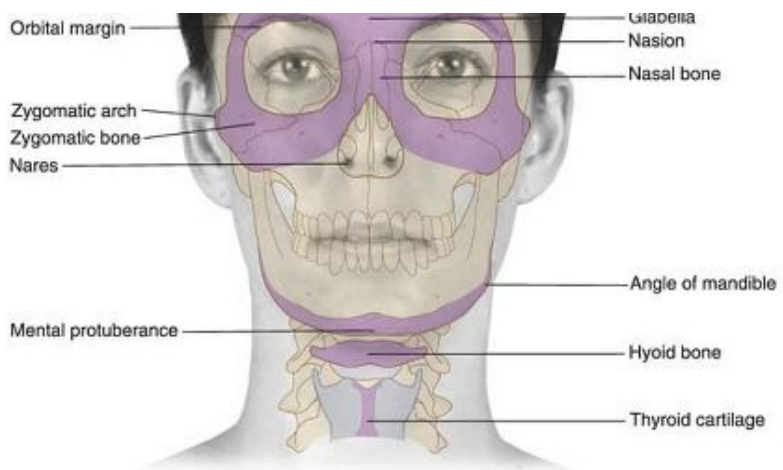
P.295

P.296

A. Anatomical position



Palpable bony structures



B. Head extended

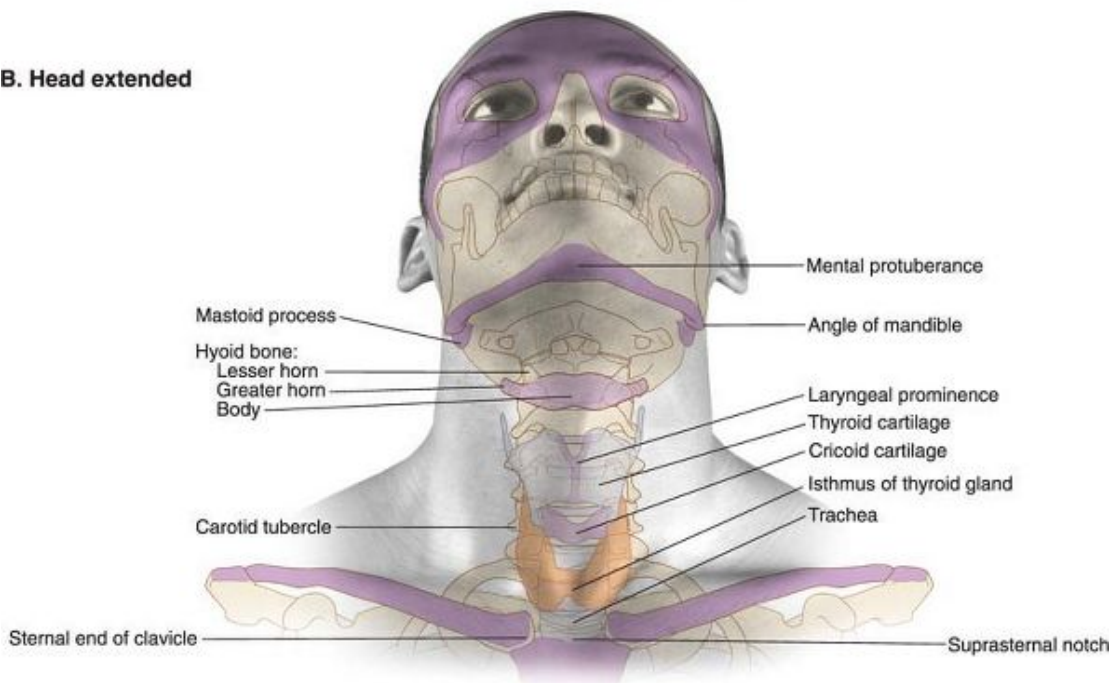
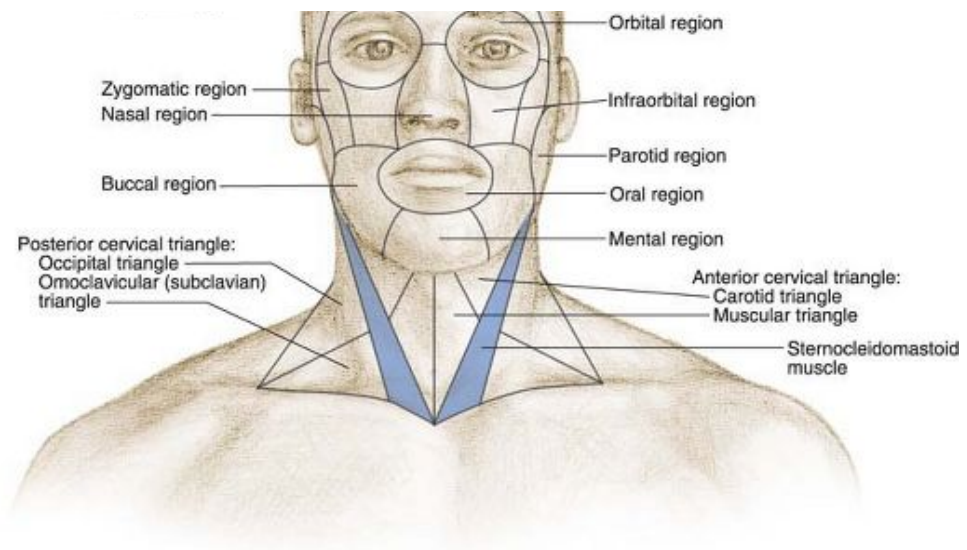


Plate 7-01 Palpable Features and Landmarks of the Head and Neck, Anterior View

A. Anterior view





B. Lateral view

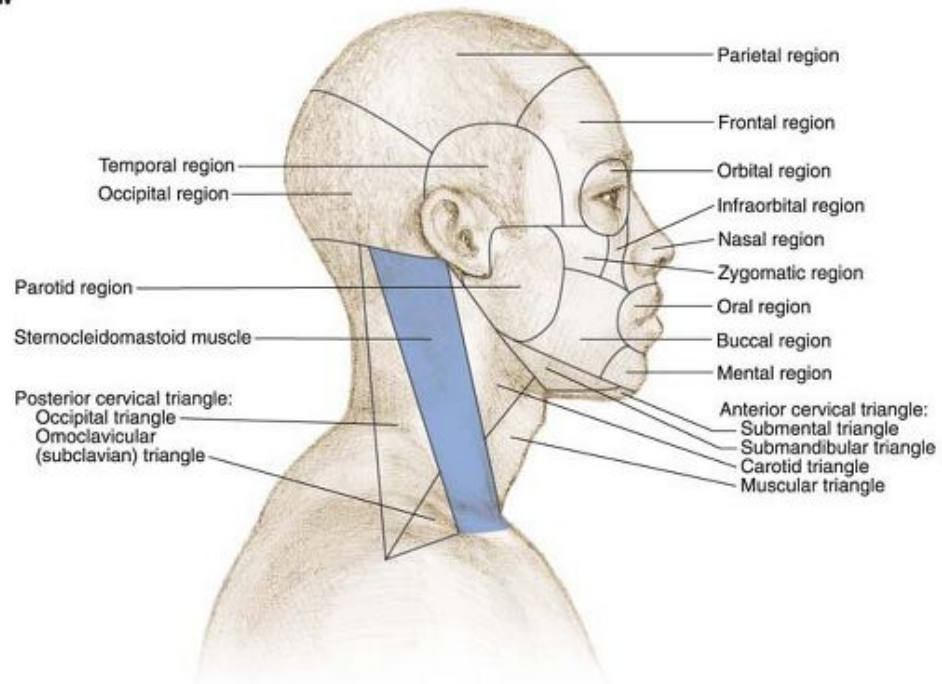


Plate 7-02 Regions of the Head and Triangles of the Neck

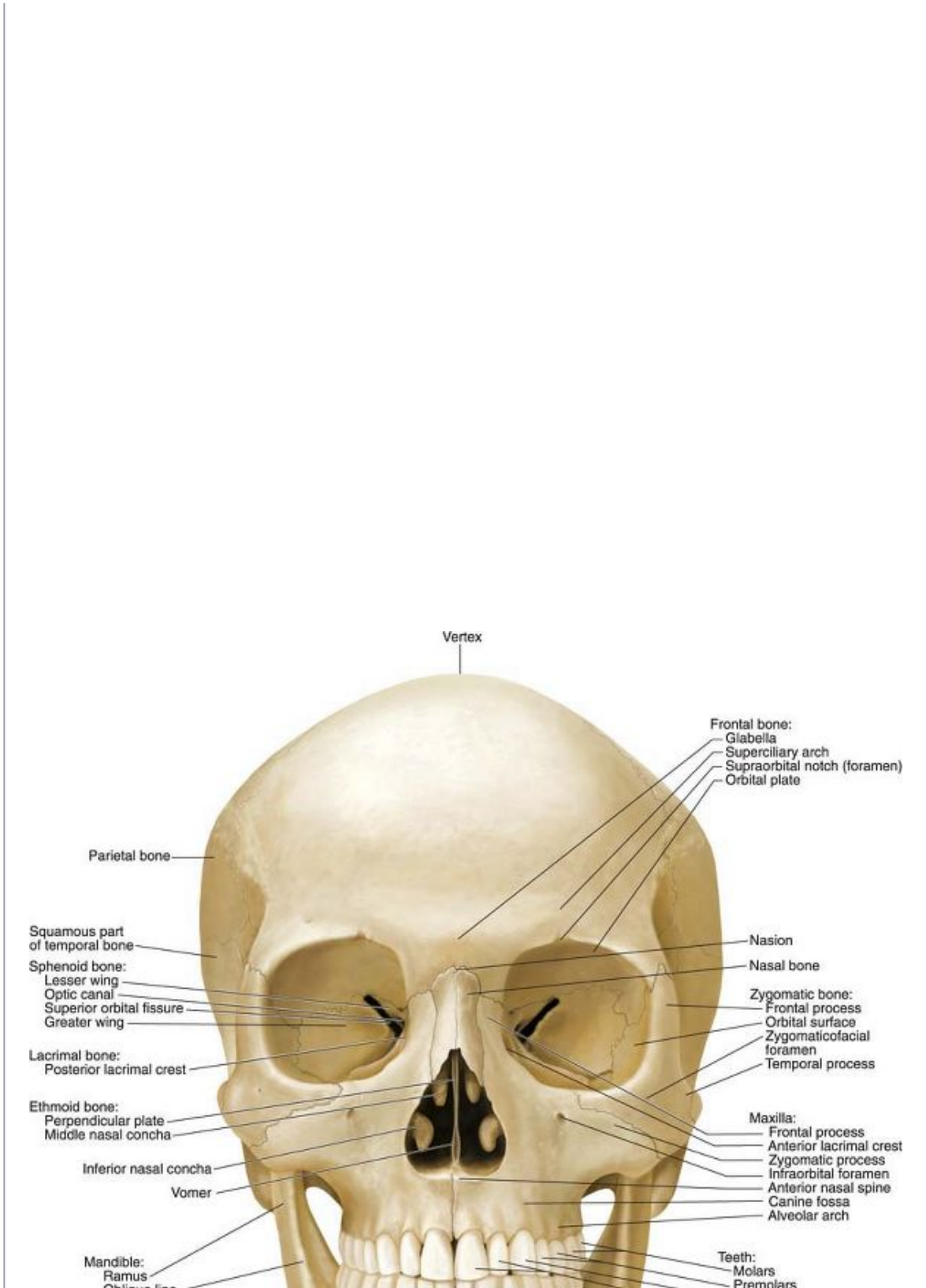
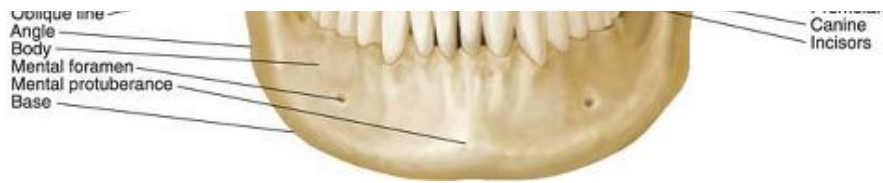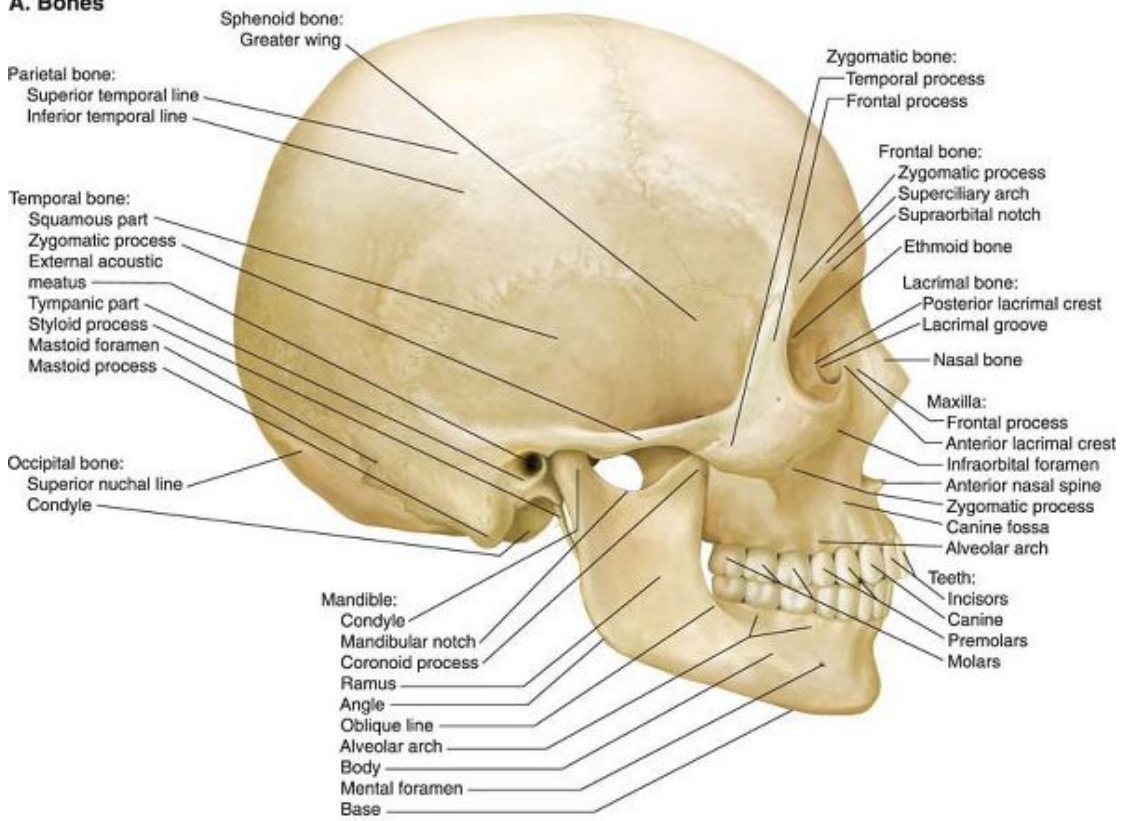


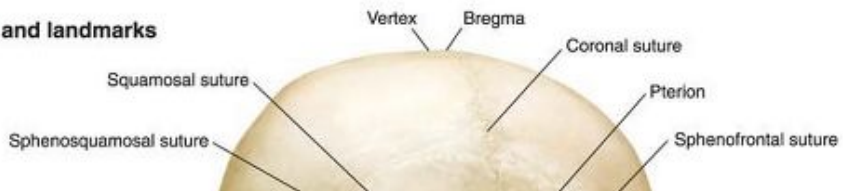

Plate 7-03 Skull, Anterior View

A. Bones



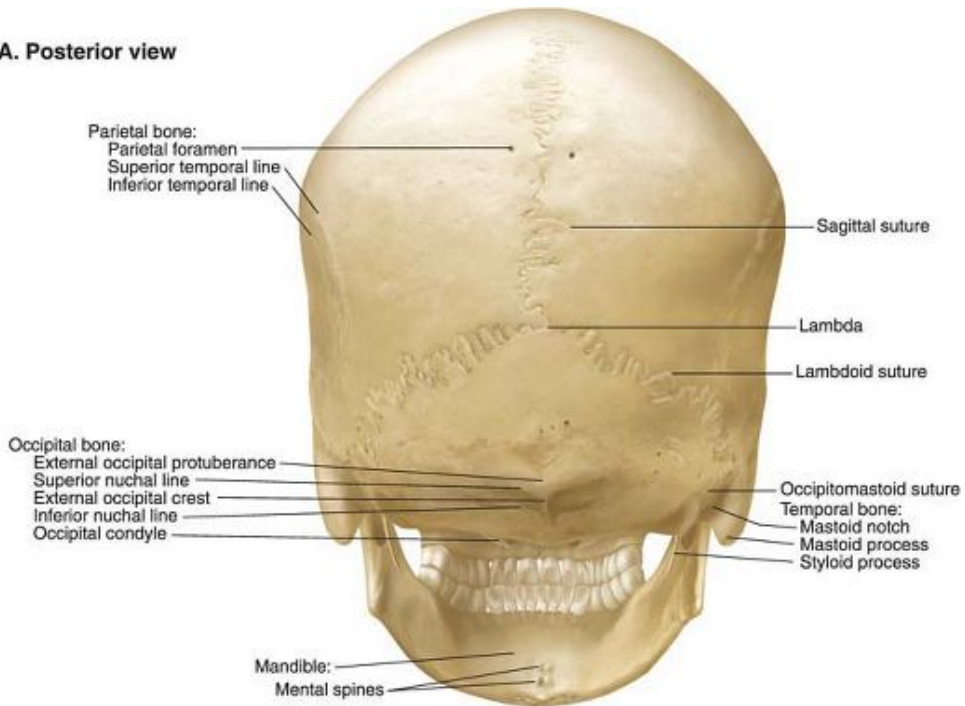
B. Sutures and landmarks



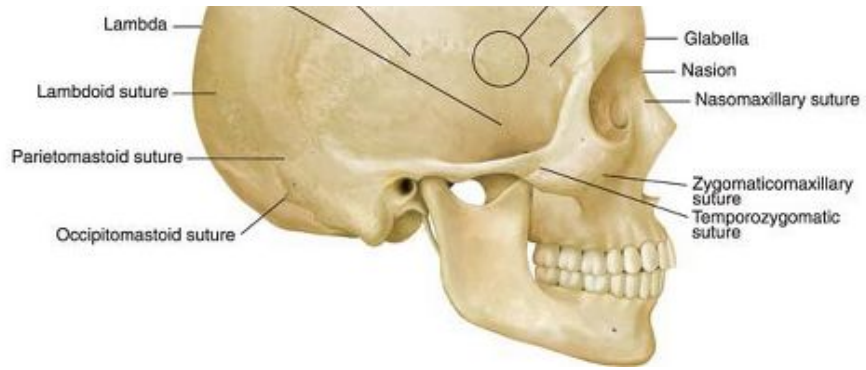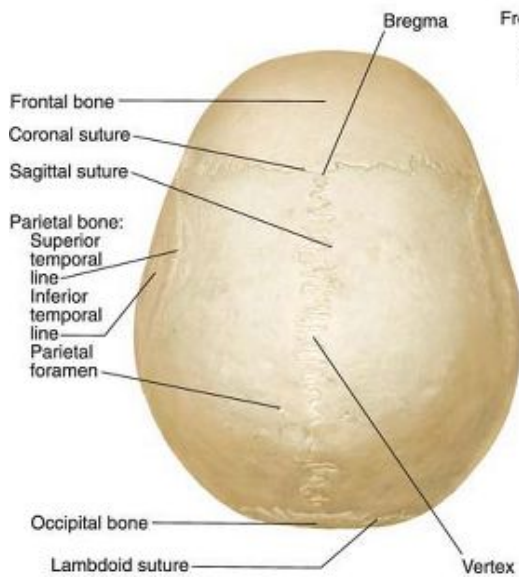


Plate 7-04 Skull, Lateral View

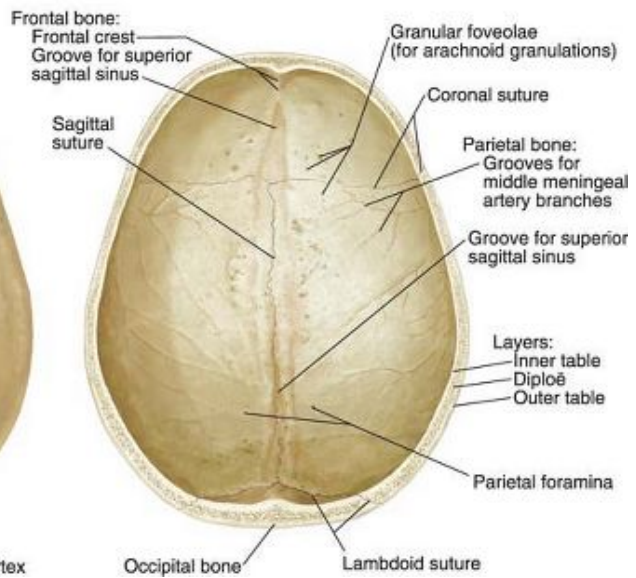
A. Posterior view

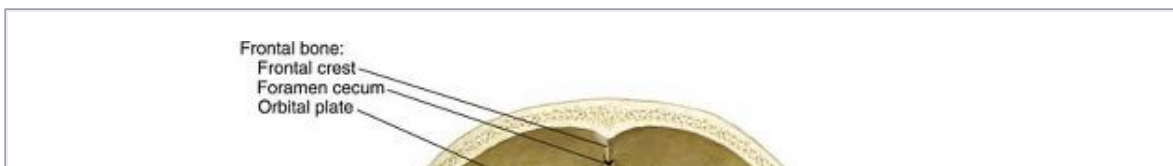
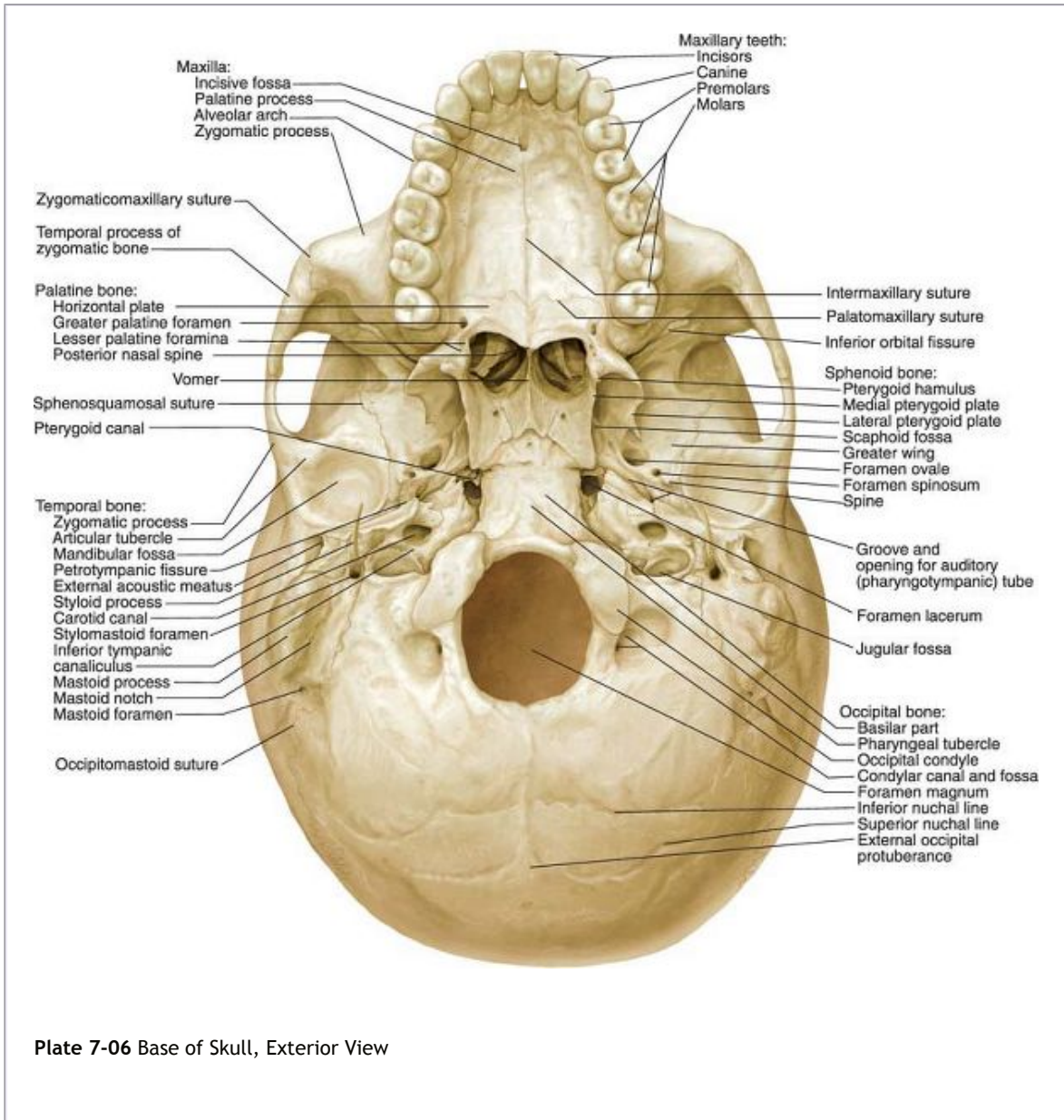


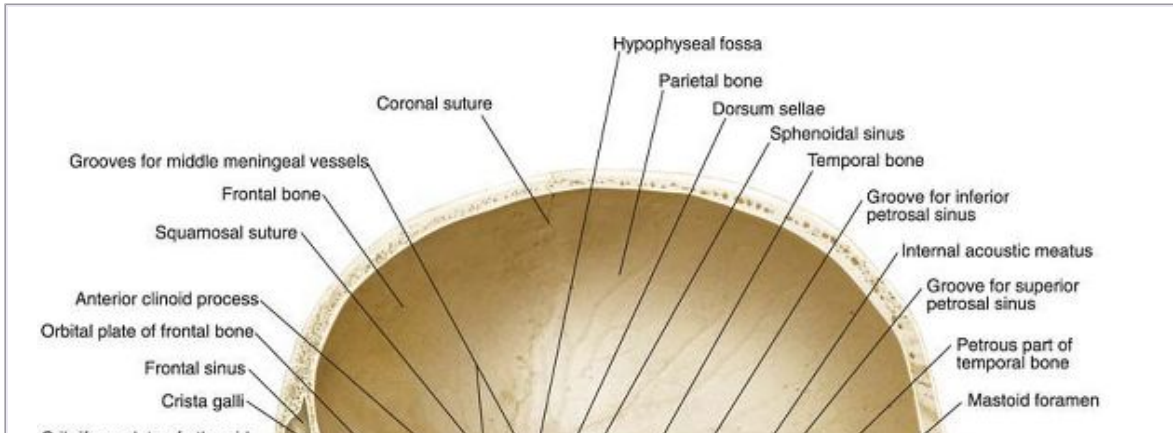
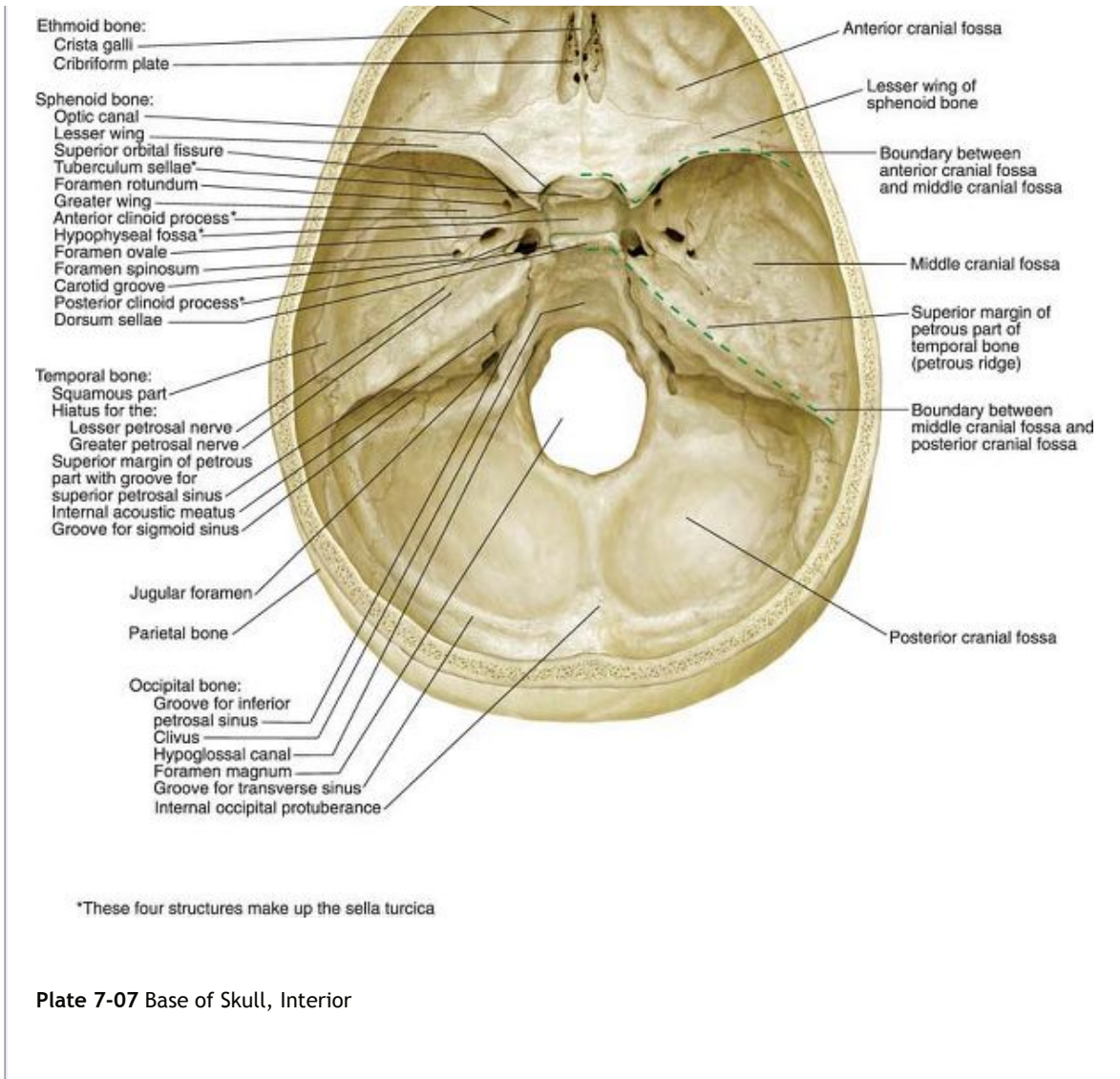
B. Calvaria, superior view

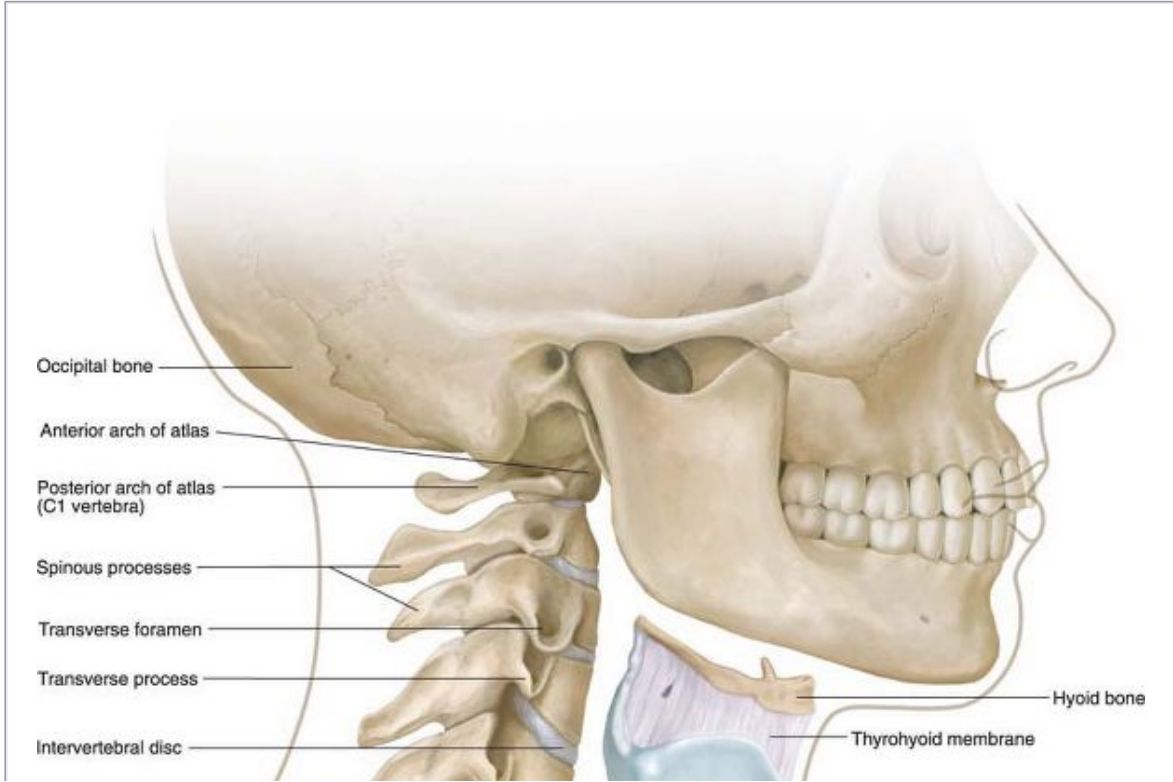
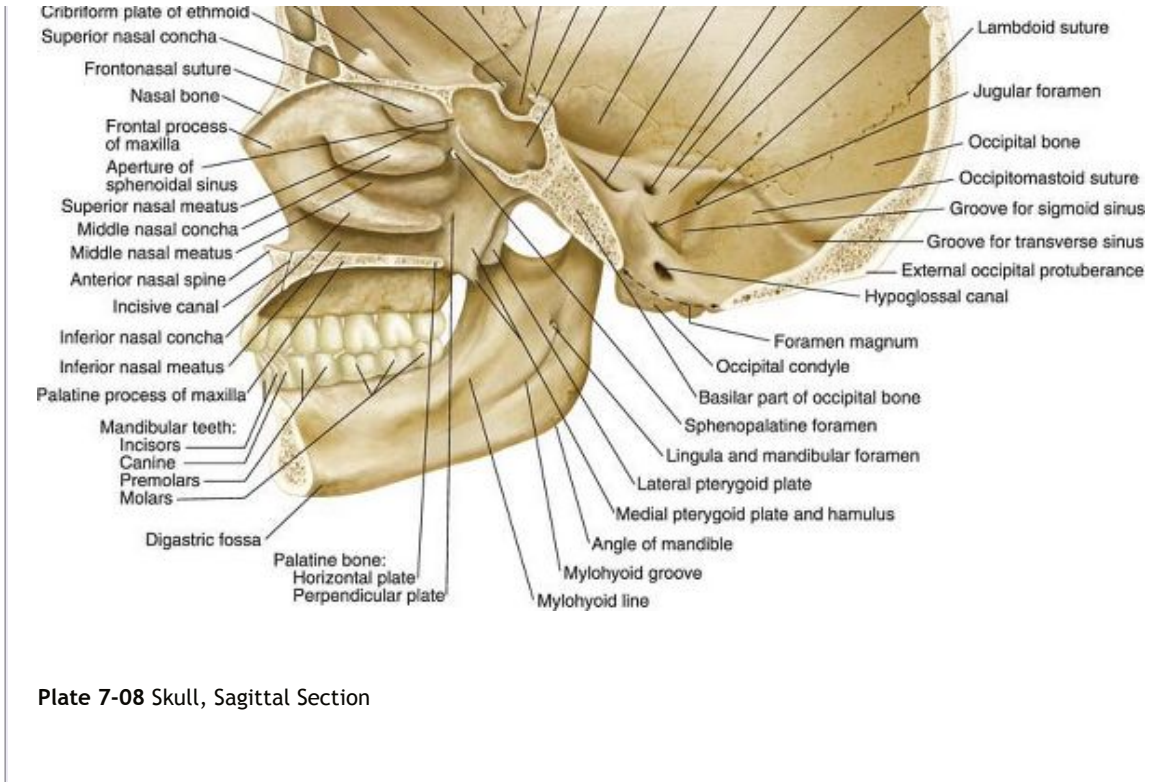


C. Calvaria, internal surface









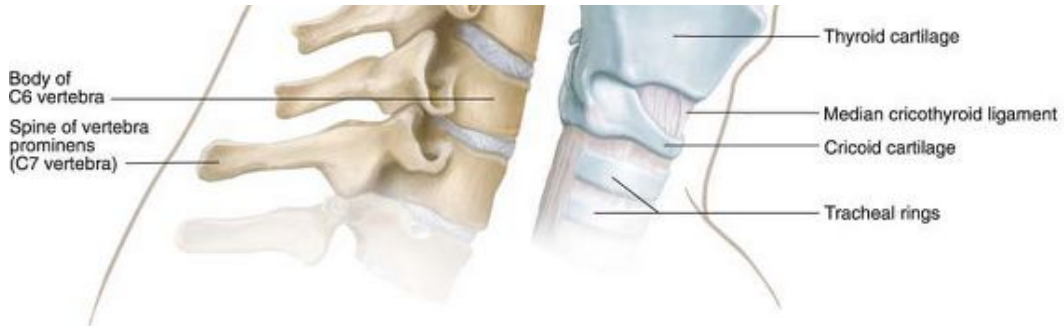
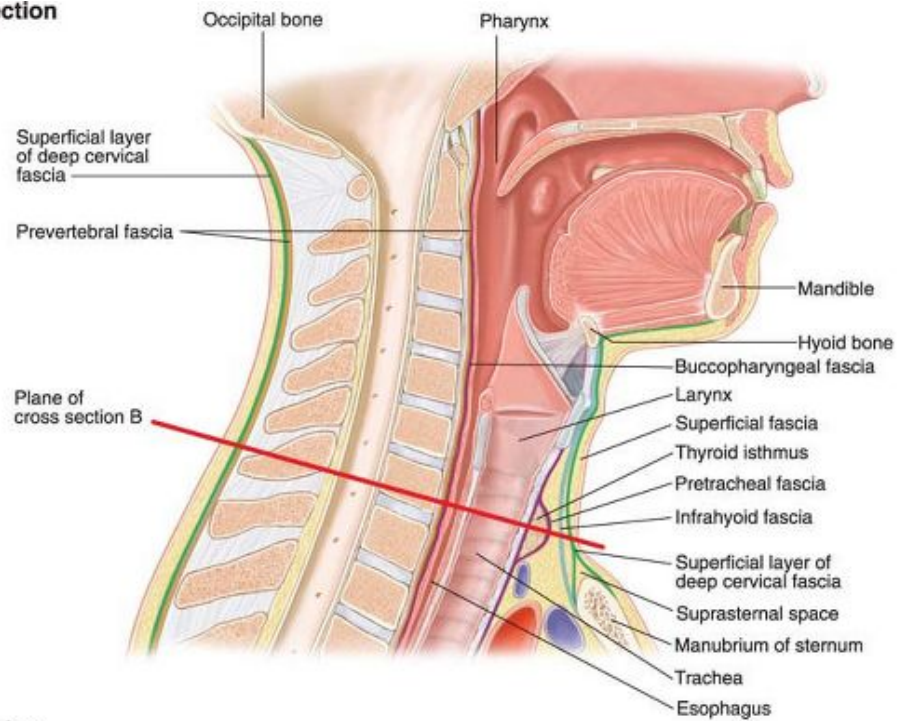
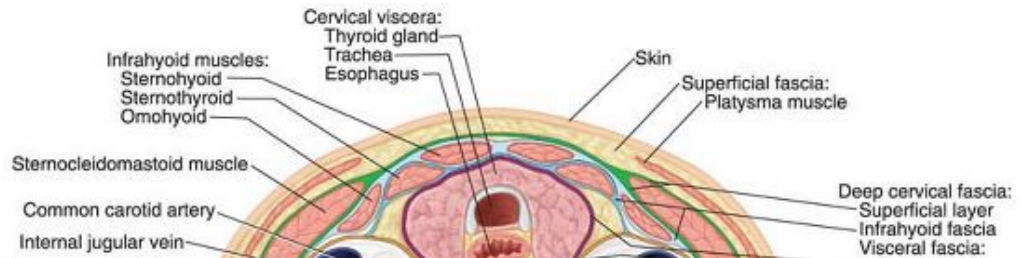


Plate 7-09 Skeleton of the Neck, Lateral View

A. Sagittal section



B. Cross section



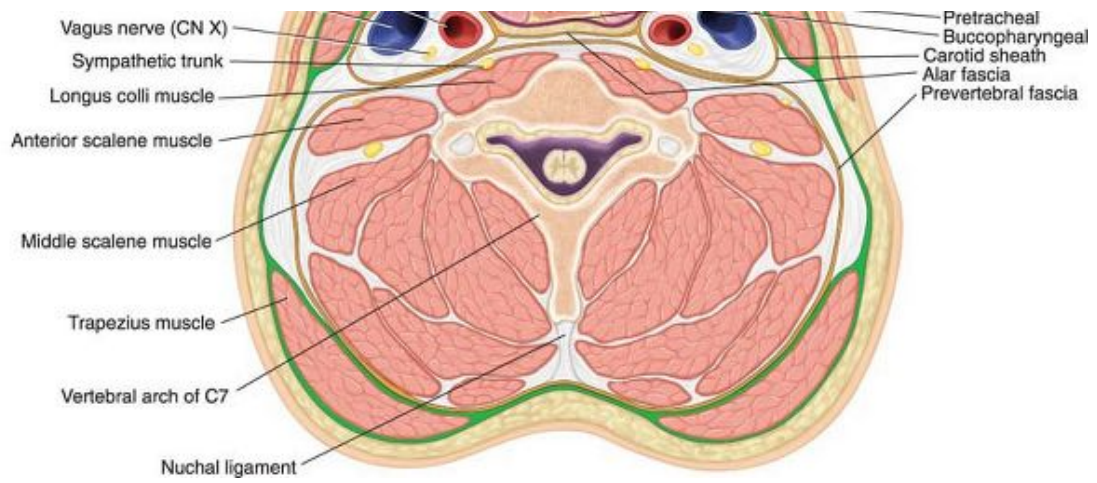
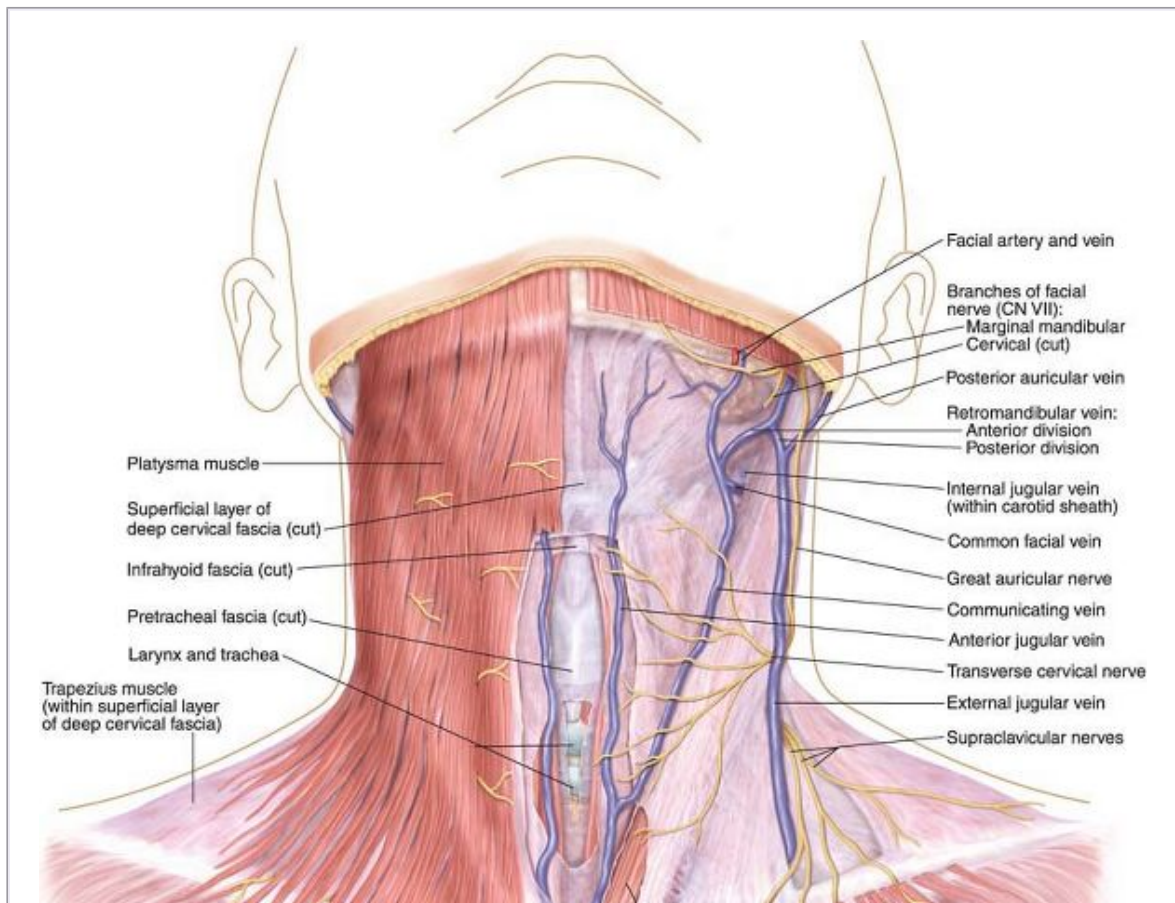
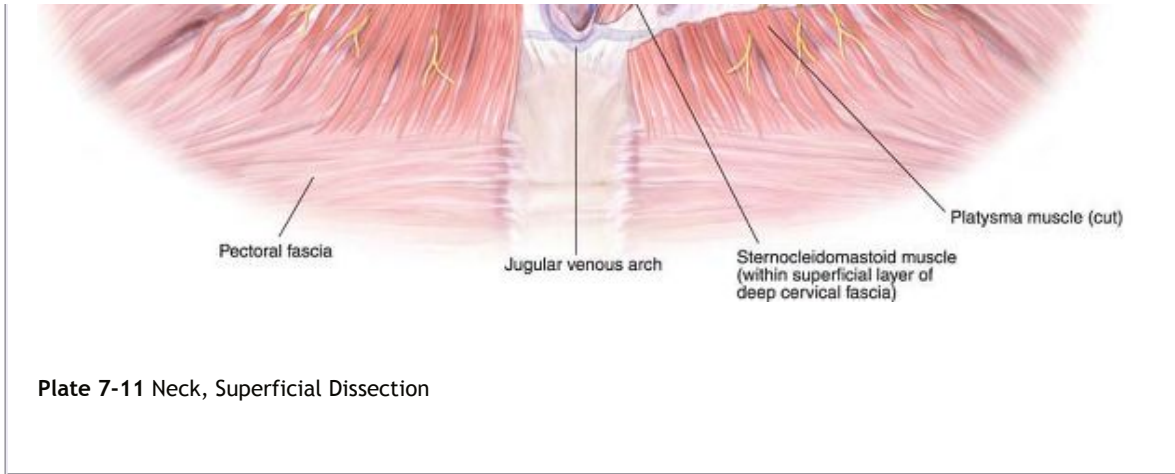


Plate 7-10 Cervical Fascia





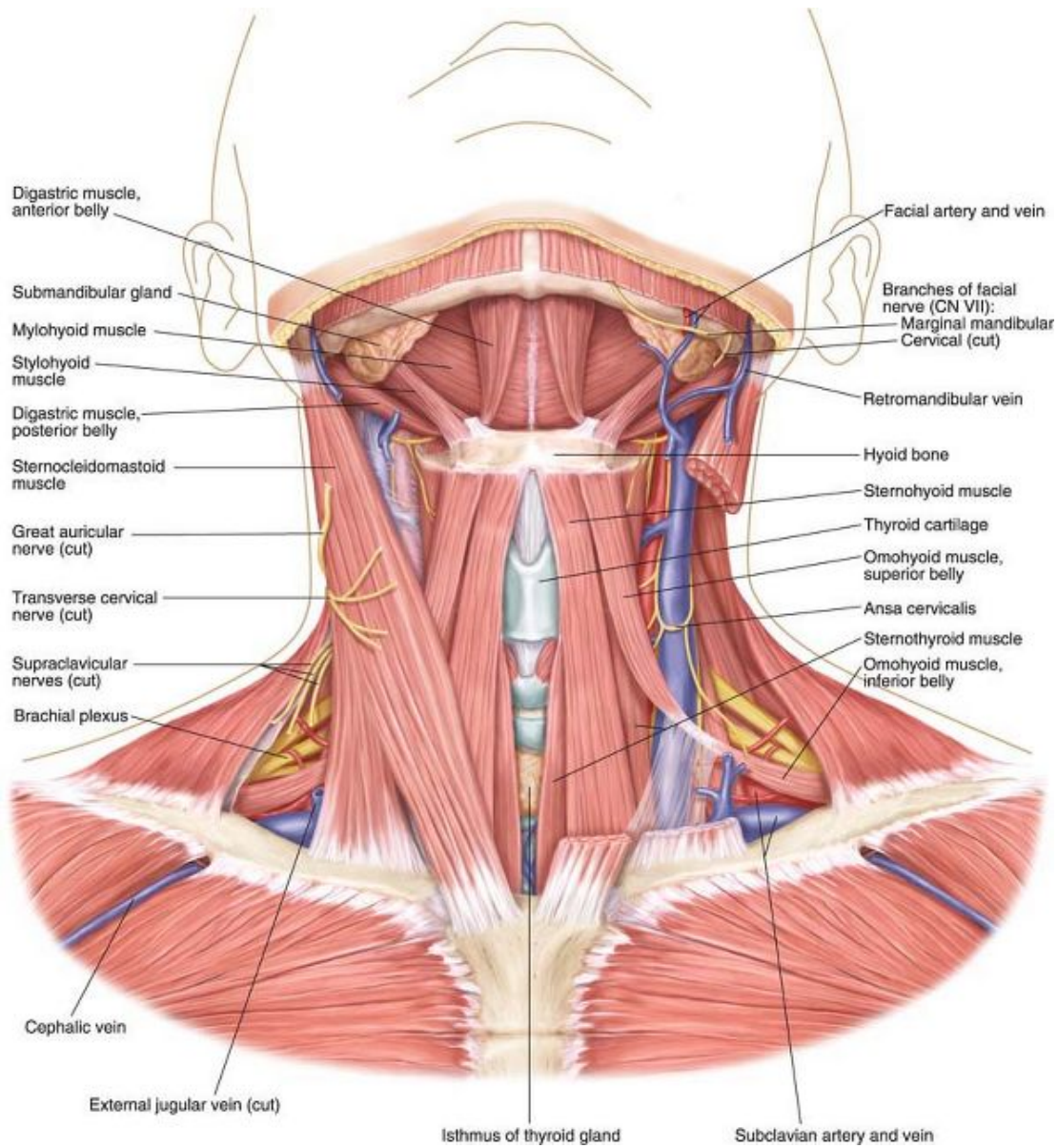


Plate 7-12 Neck, Intermediate Dissection

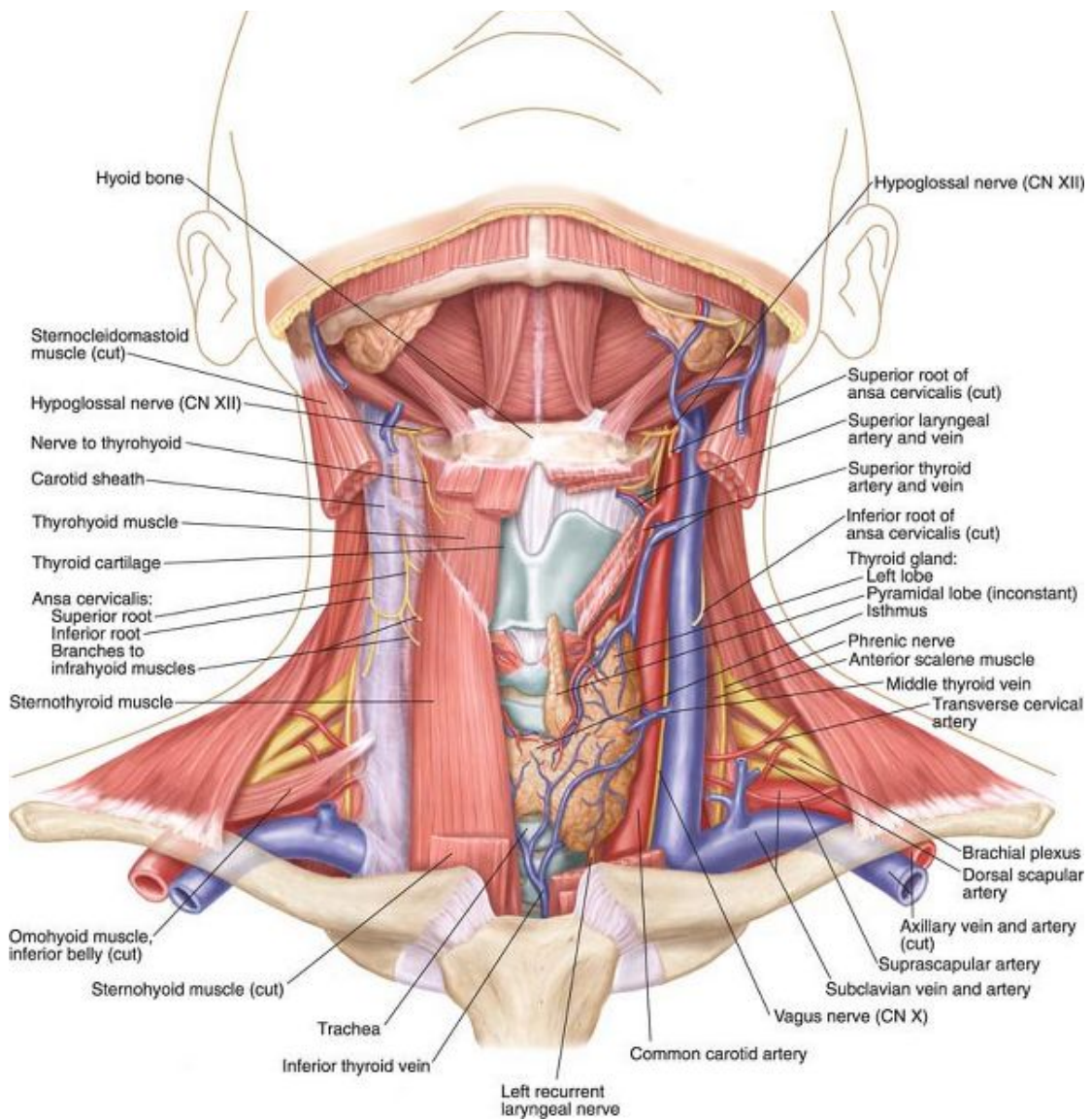
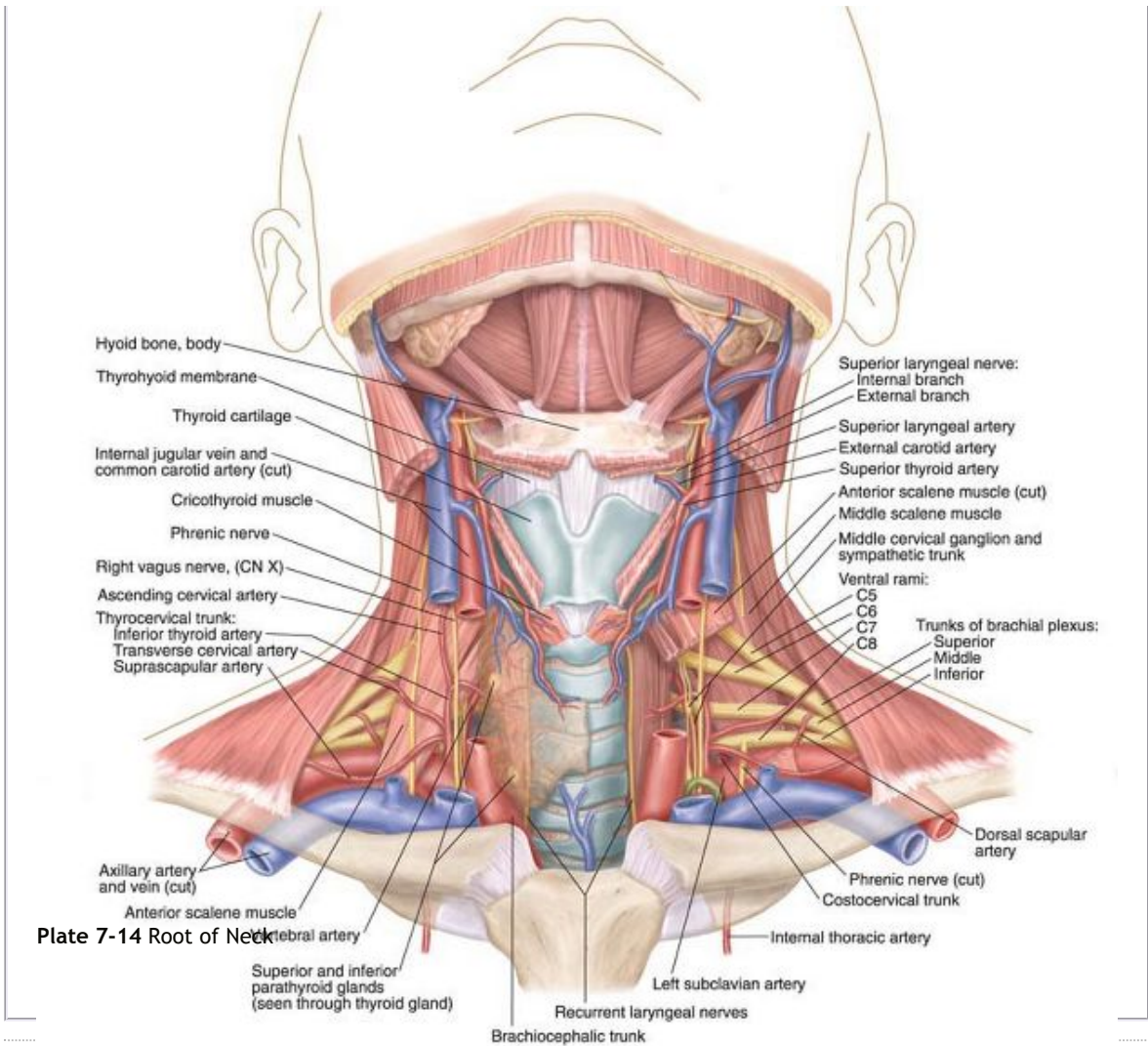
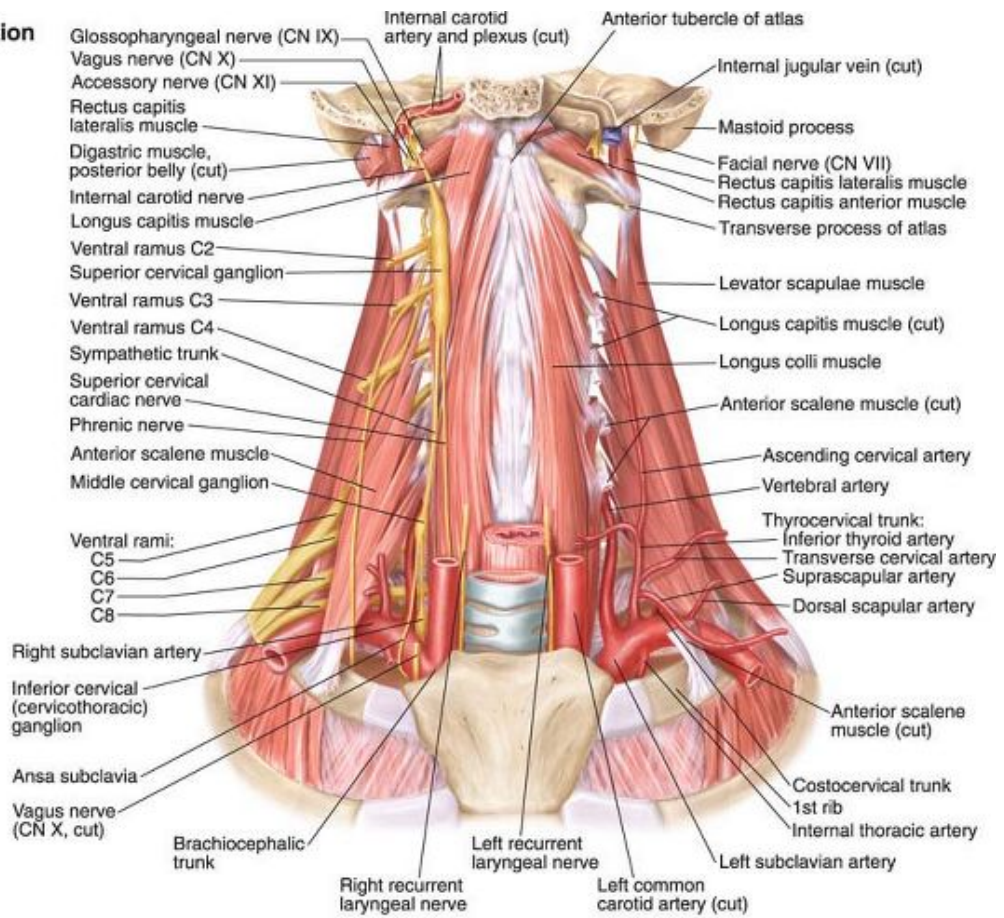


Plate 7-13 Neck, Deep Dissection

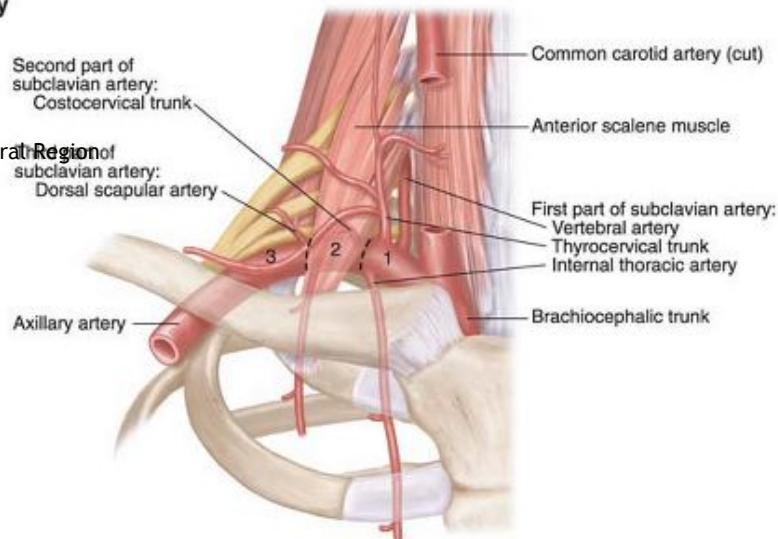


A. Dissection

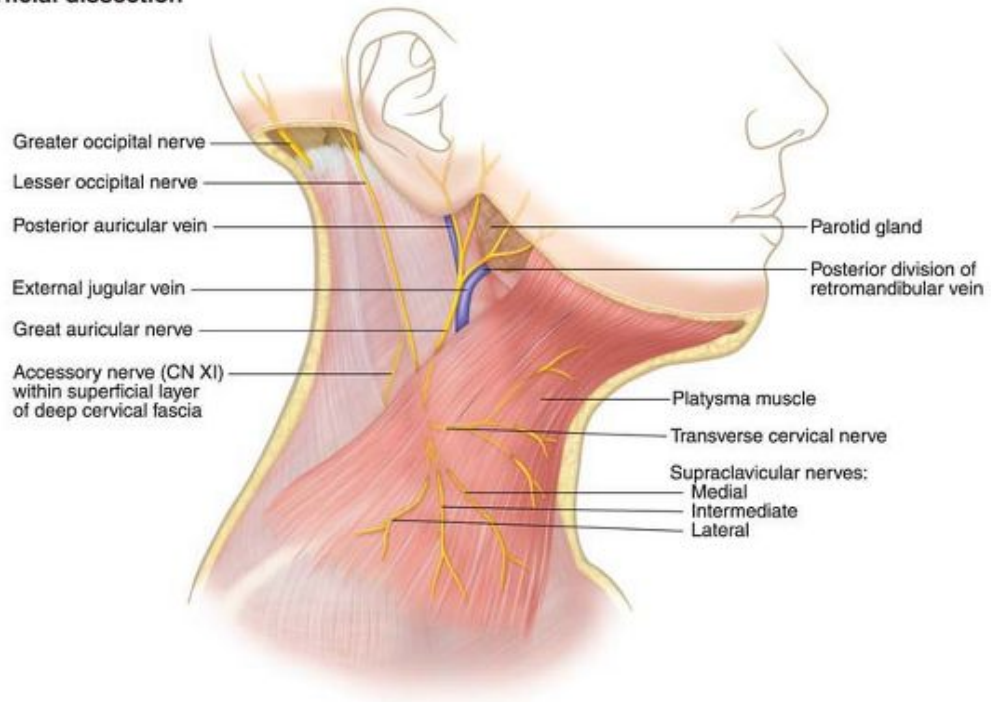


B. Subclavian artery

Plate 7-15 Prevertebral Region



A. Superficial dissection



B. Intermediate dissection

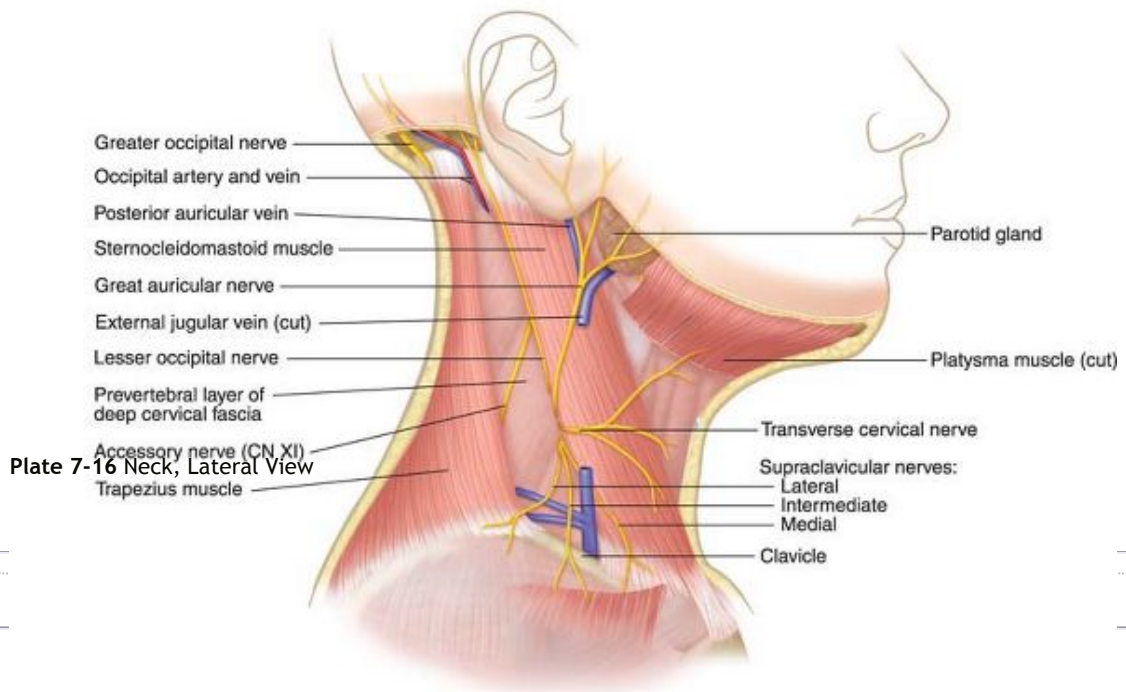


Plate 7-16 Neck, Lateral View

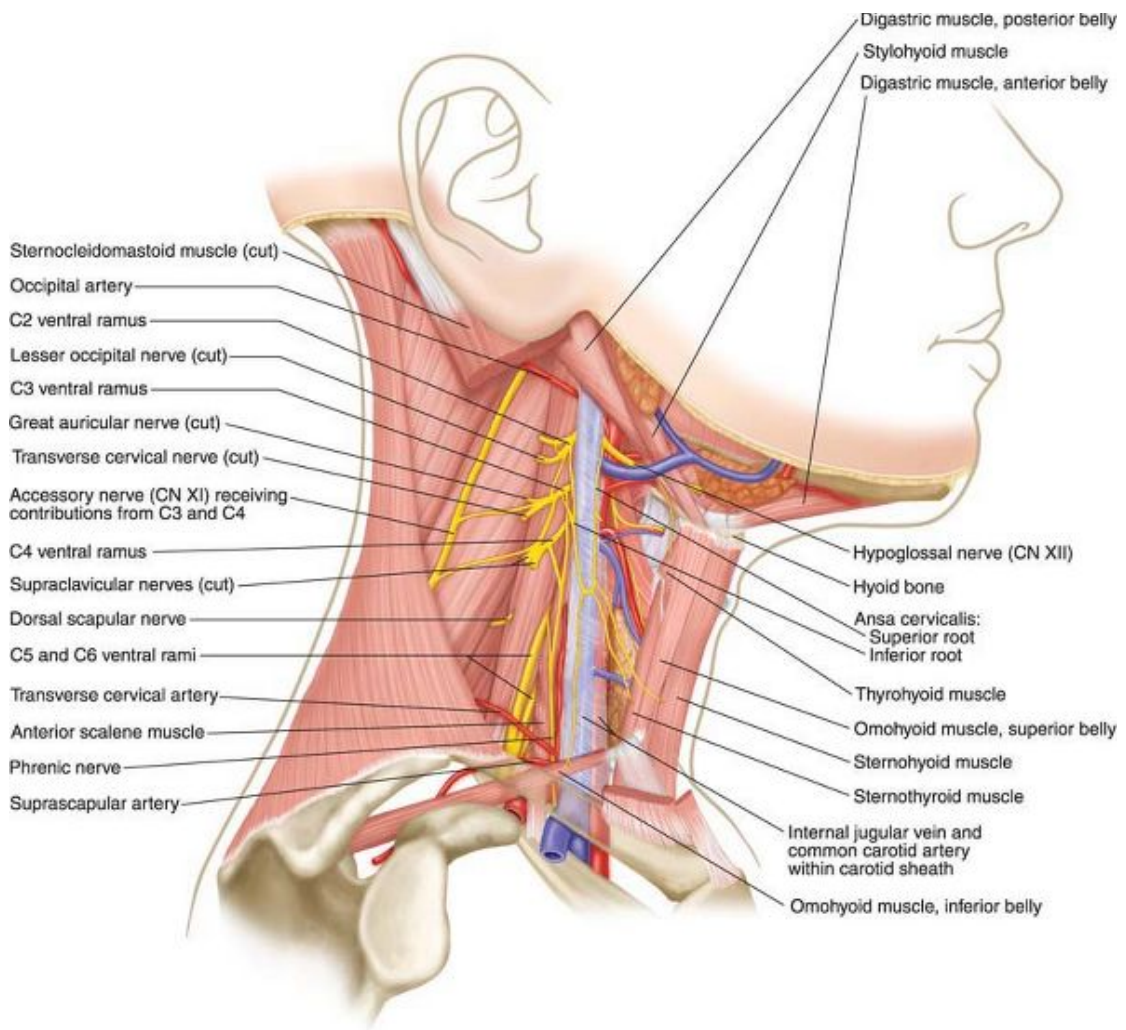


Plate 7-17 Neck, Lateral View, Deeper Dissection

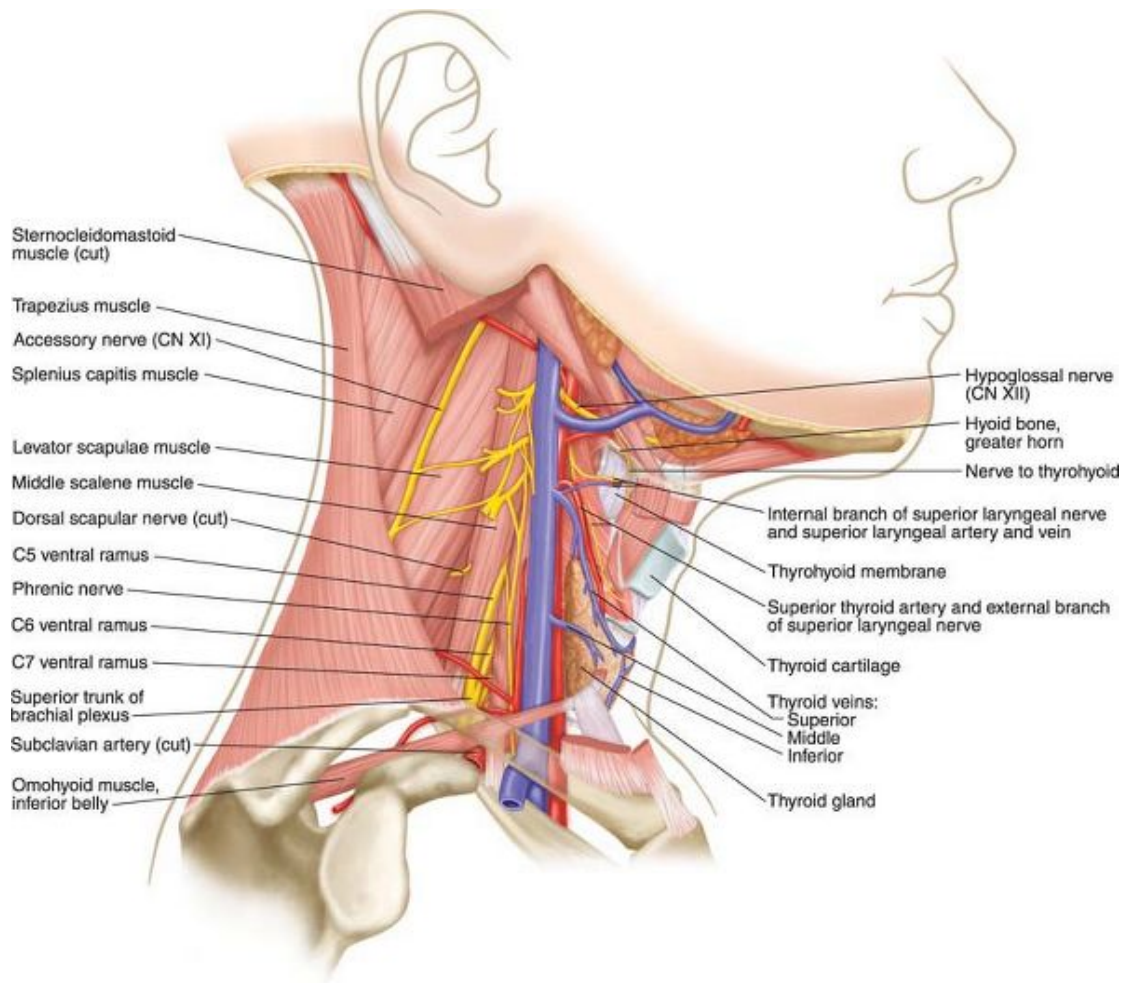


Plate 7-18 Neck, Lateral View, Deepest Dissection

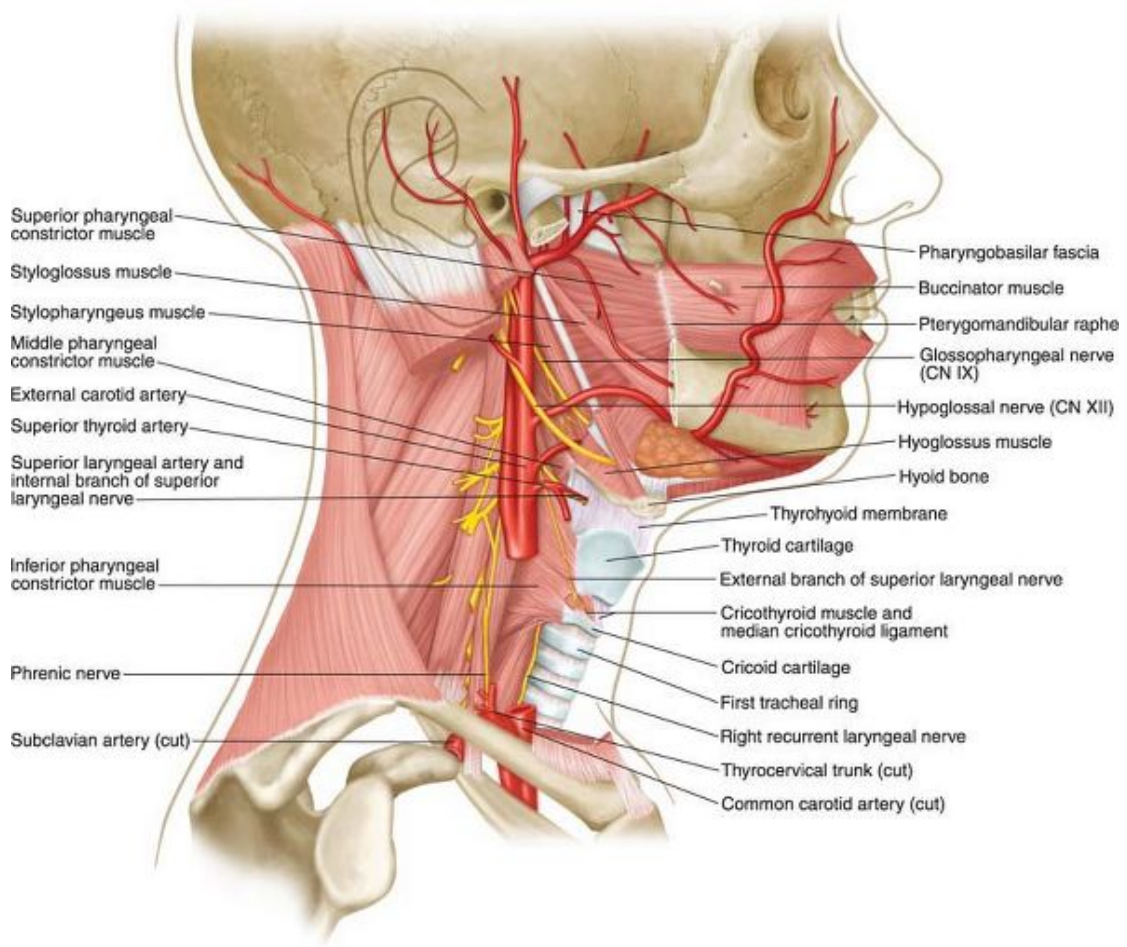


Plate 7-19 Neck, Lateral View, Larynx and Pharynx

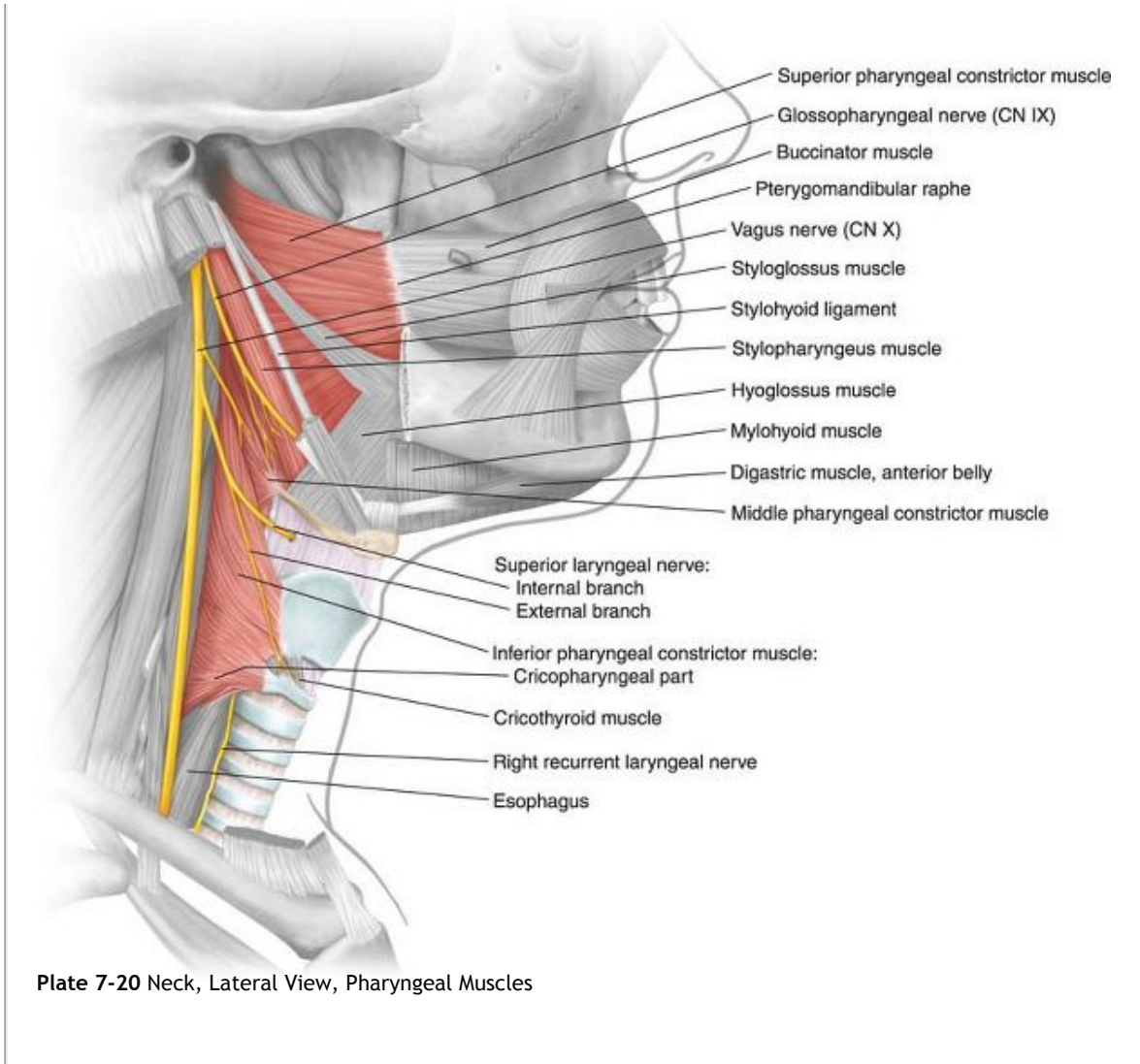


Plate 7-20 Neck, Lateral View, Pharyngeal Muscles

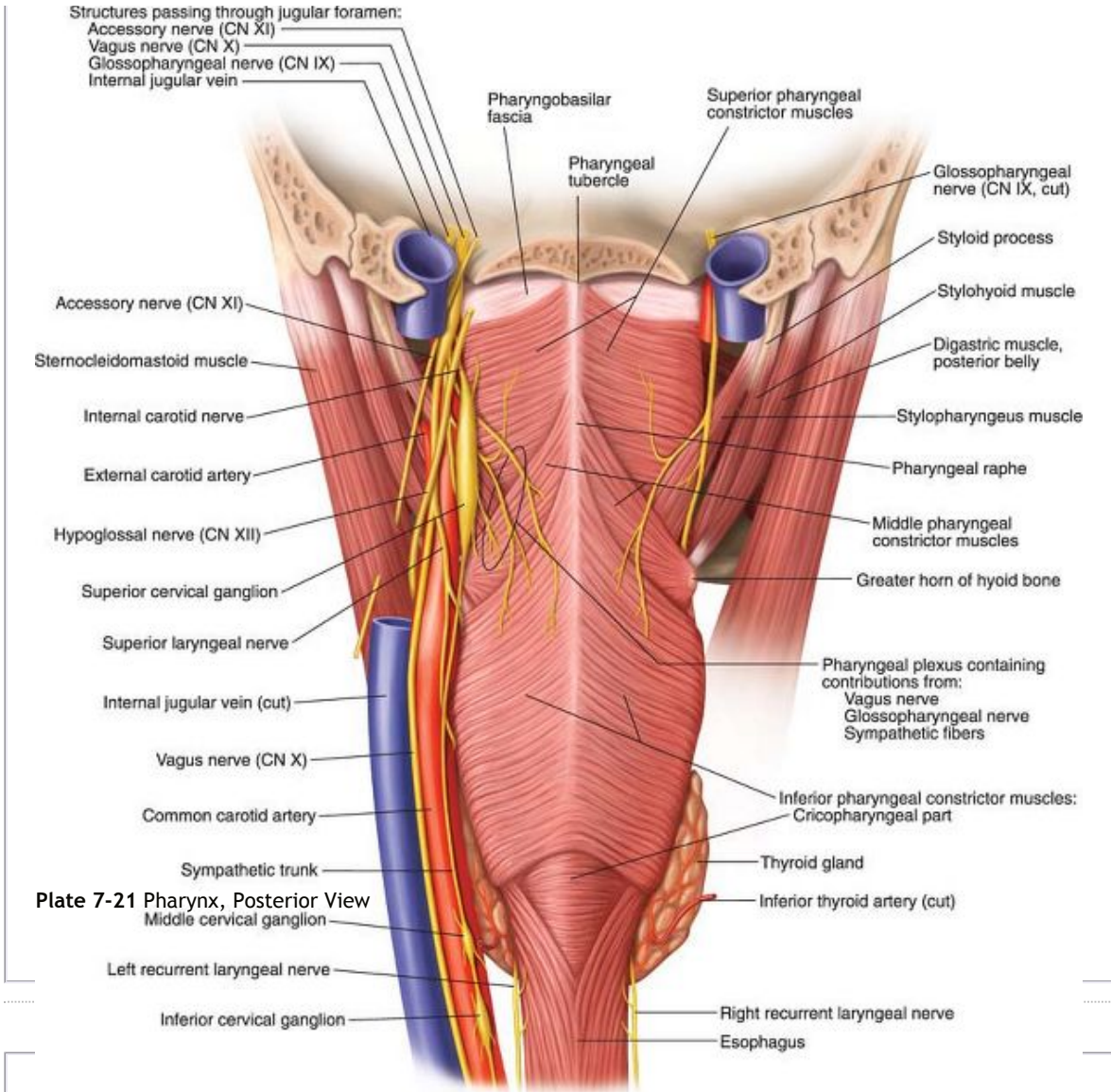
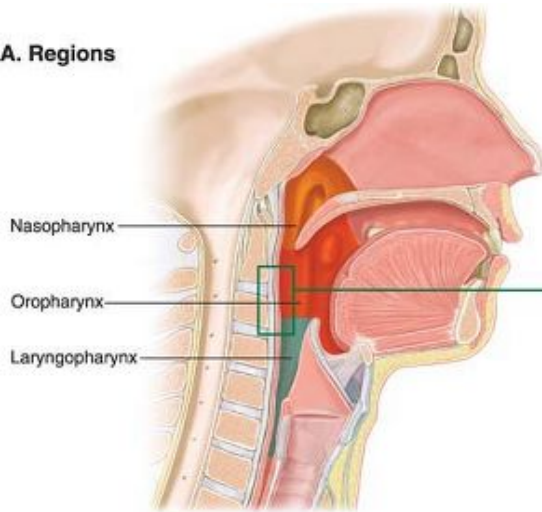
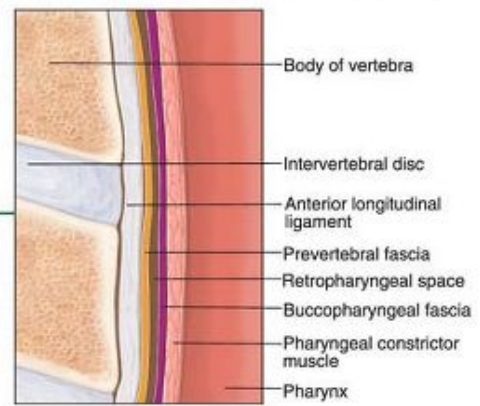


Plate 7-21 Pharynx, Posterior View

A. Regions



B. Enlargement of the retropharyngeal space



C. Mucosal features

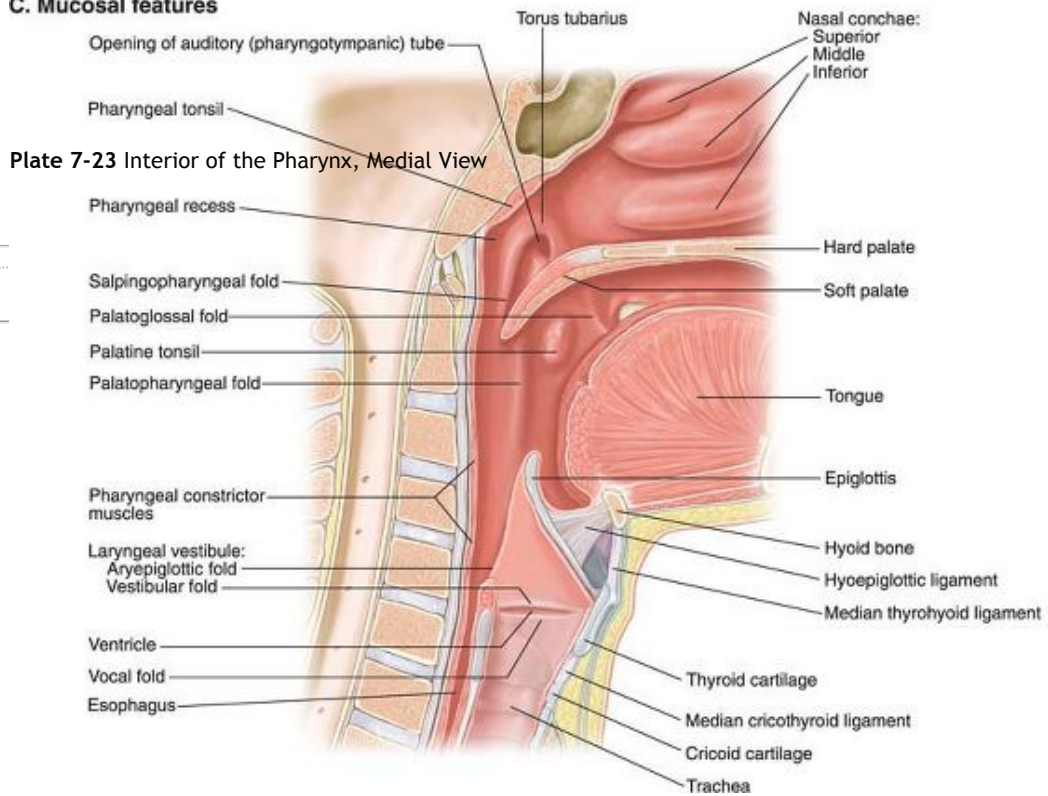


Plate 7-23 Interior of the Pharynx, Medial View

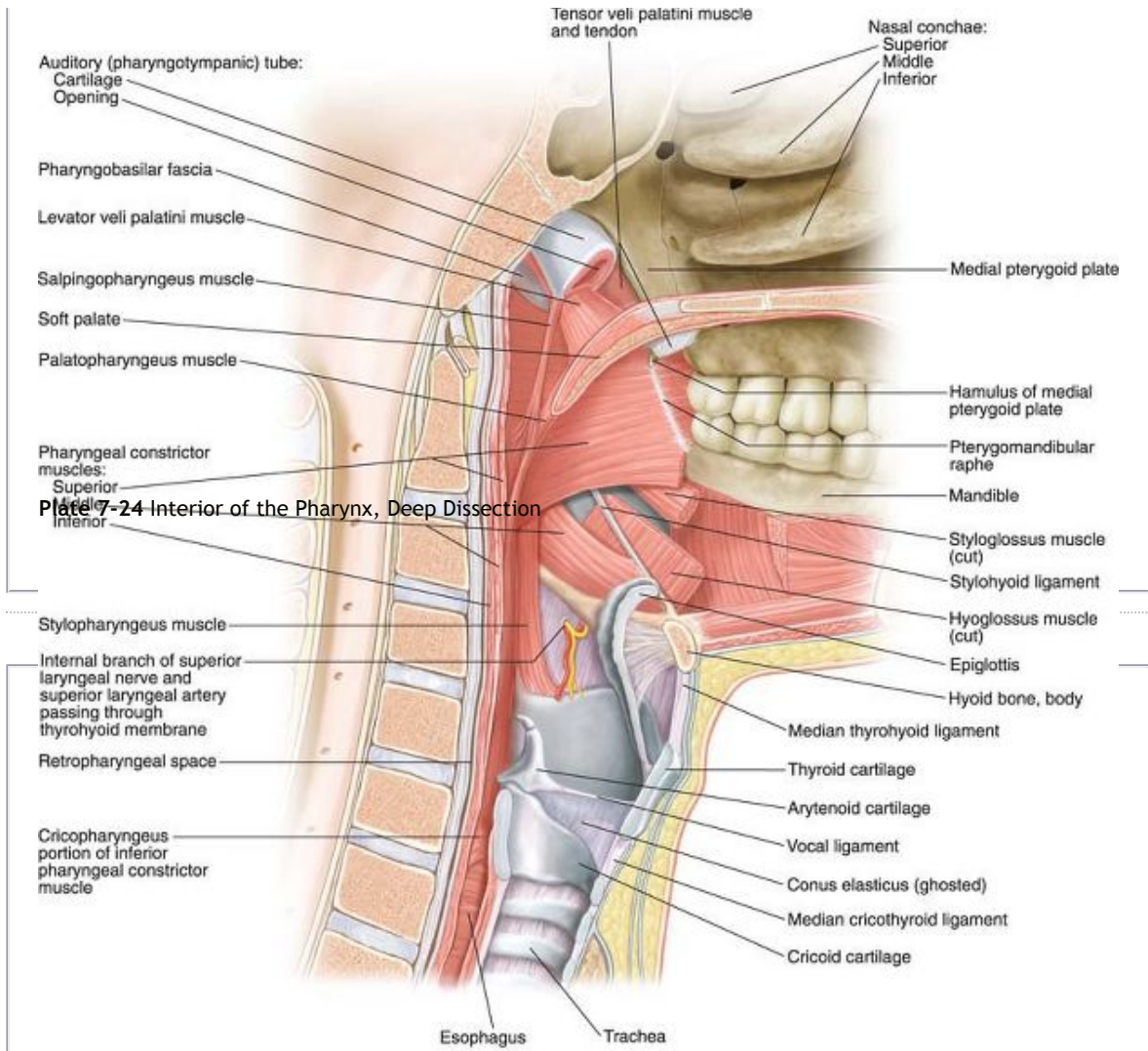
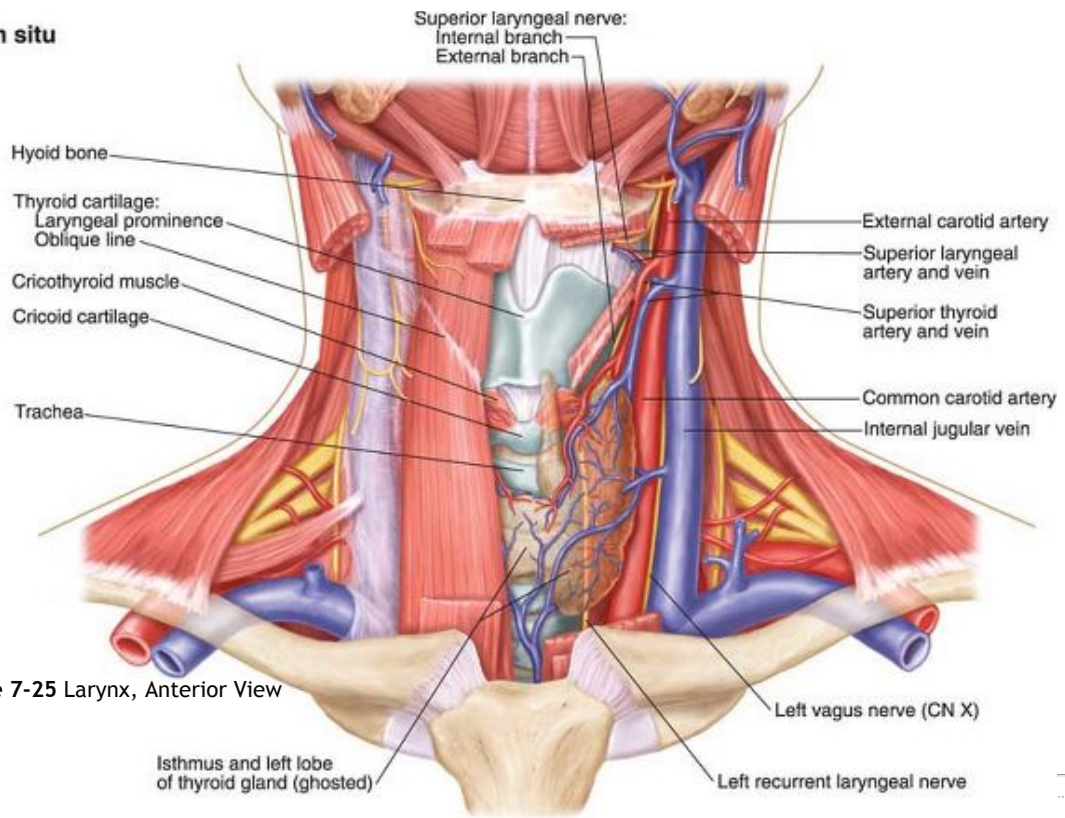
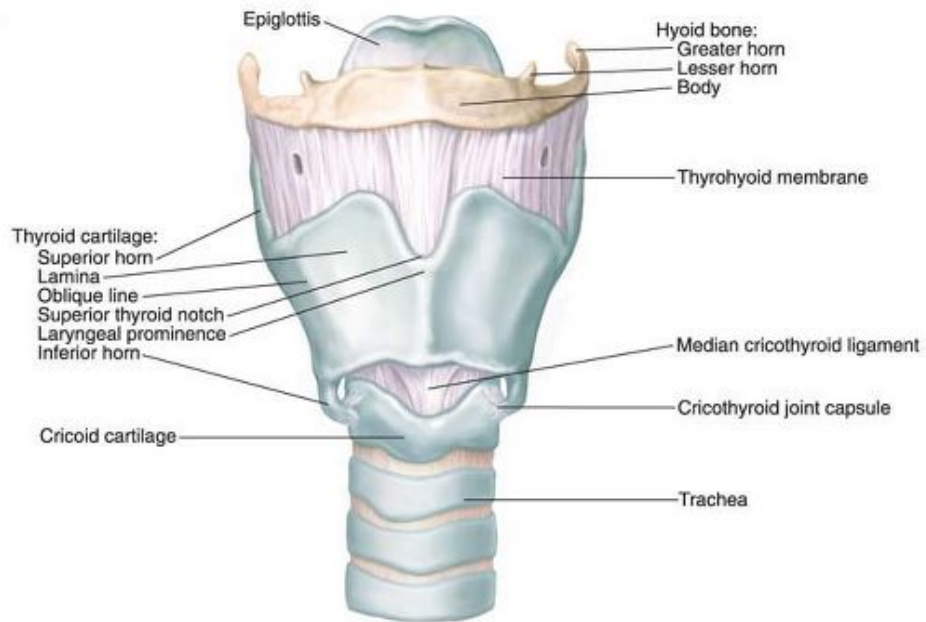


Plate 7-24 Interior of the Pharynx, Deep Dissection

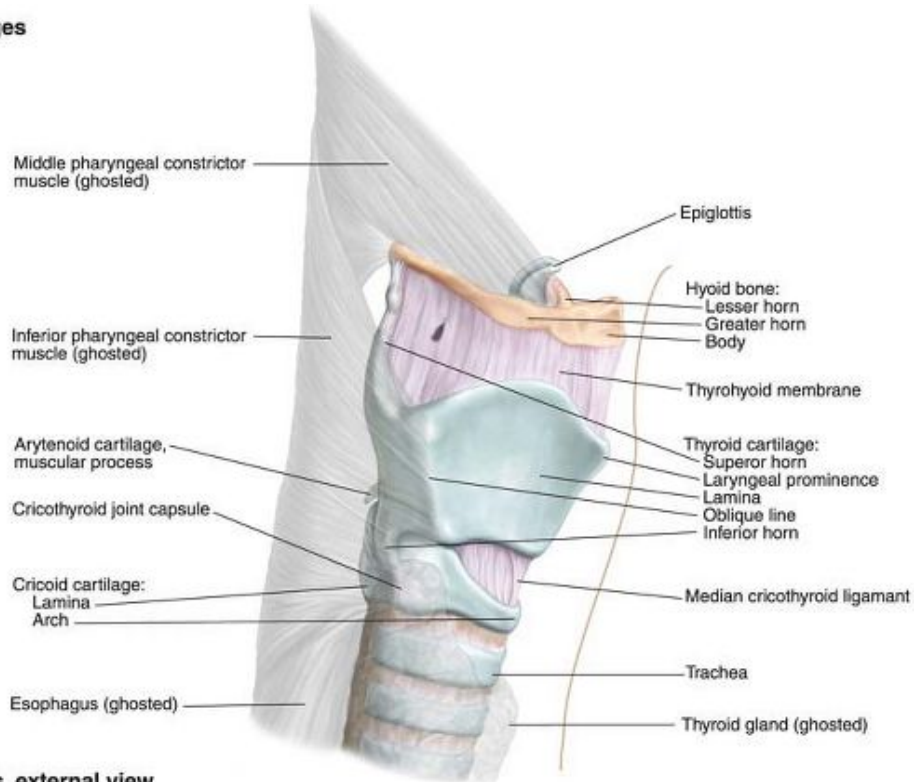
A. In situ



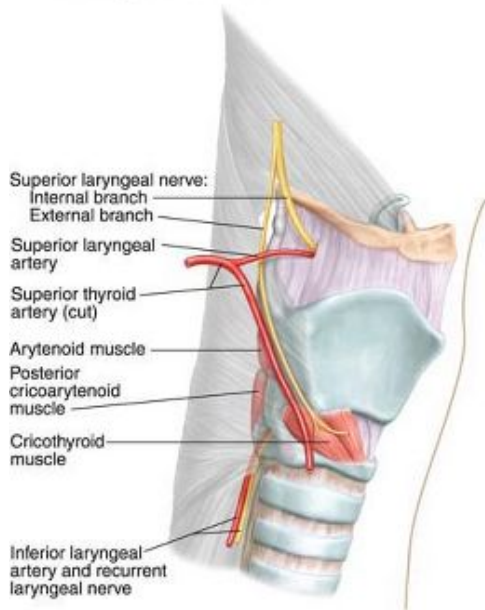
B. Cartilages



A. Cartilages



B. Muscles, external view



C. Muscles, thyroid lamina removed

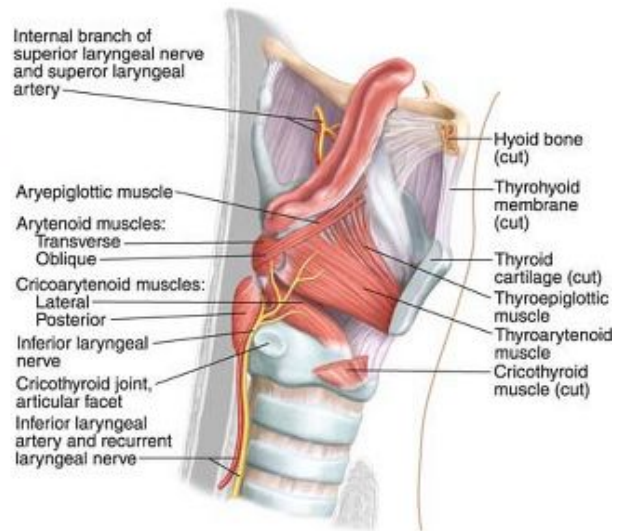
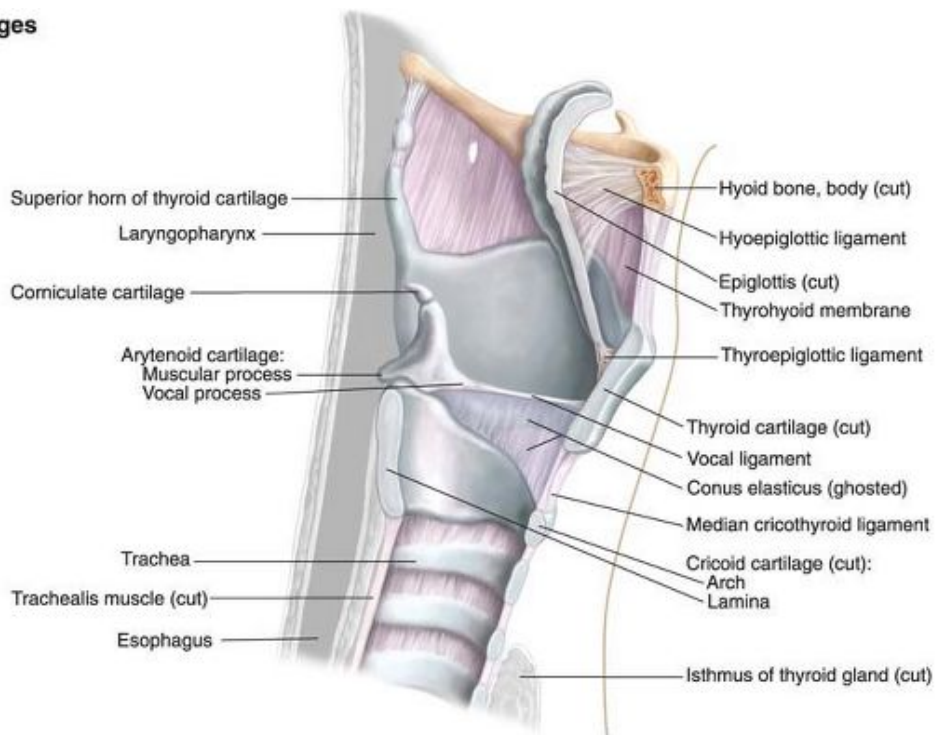


Plate 7-26 Larynx, Lateral View

A. Cartilages



B. Muscles, left side of larynx

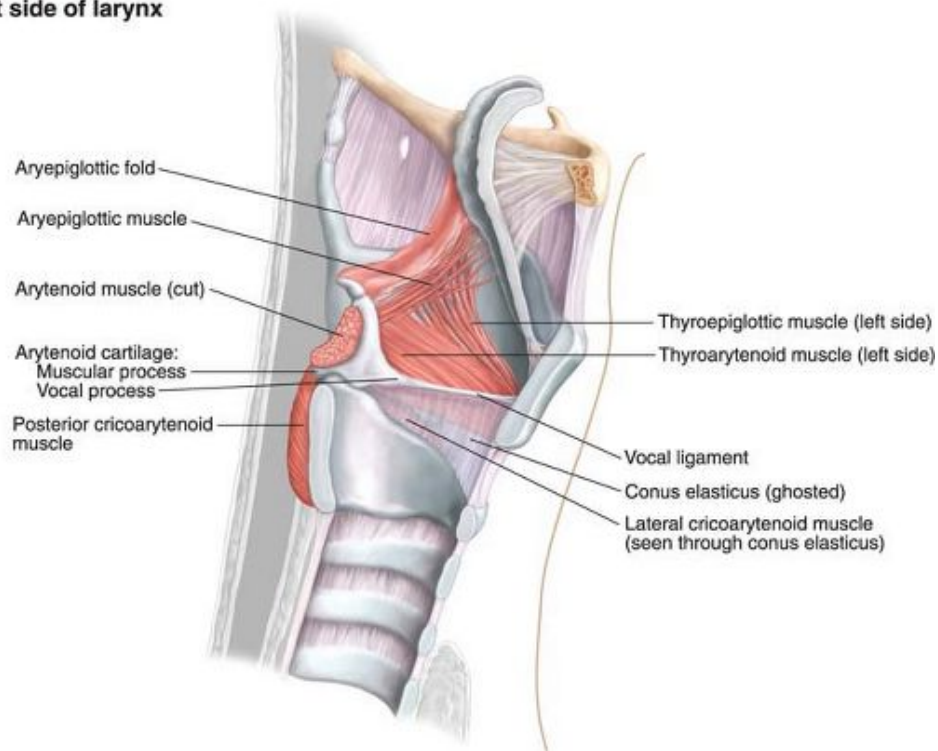


Plate 7-27 Larynx, Sagittal Section

P.323



A. Cartilages

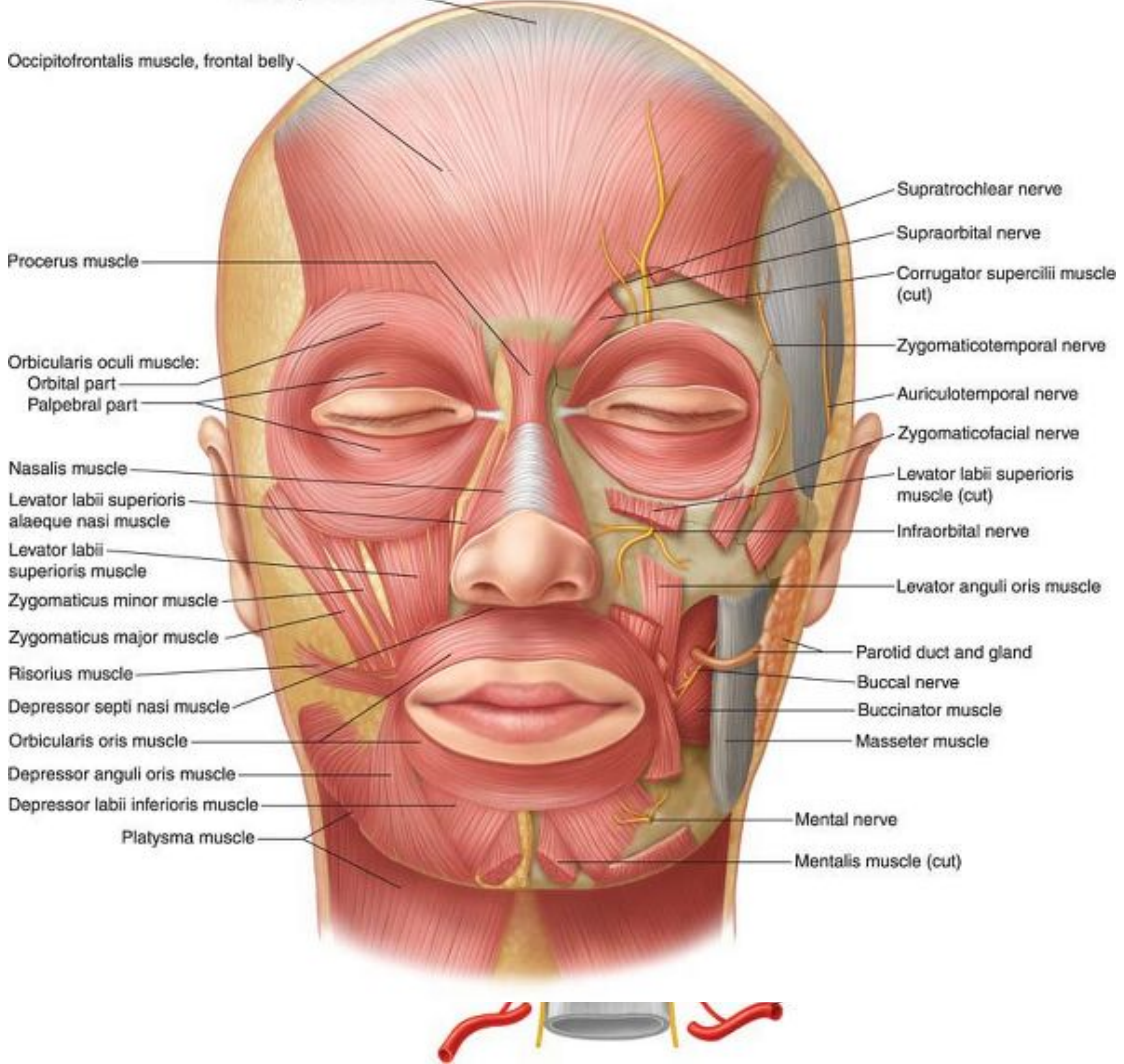
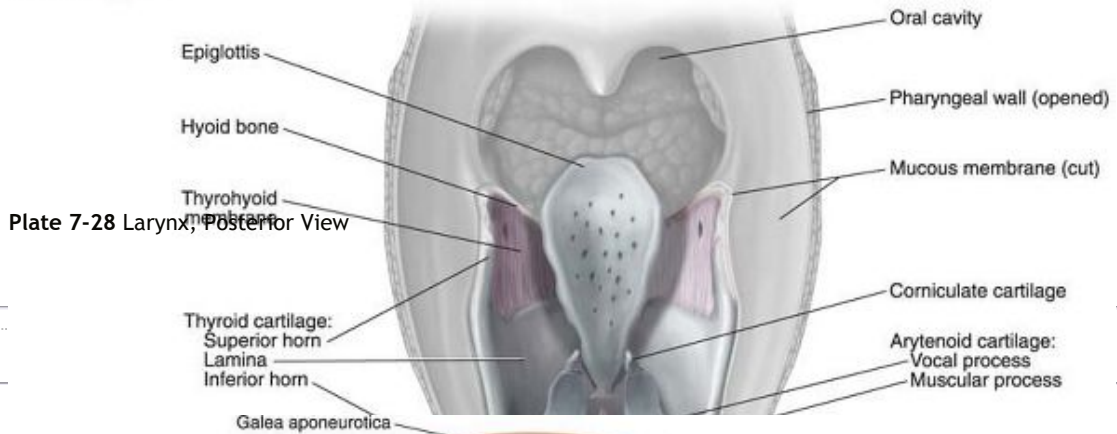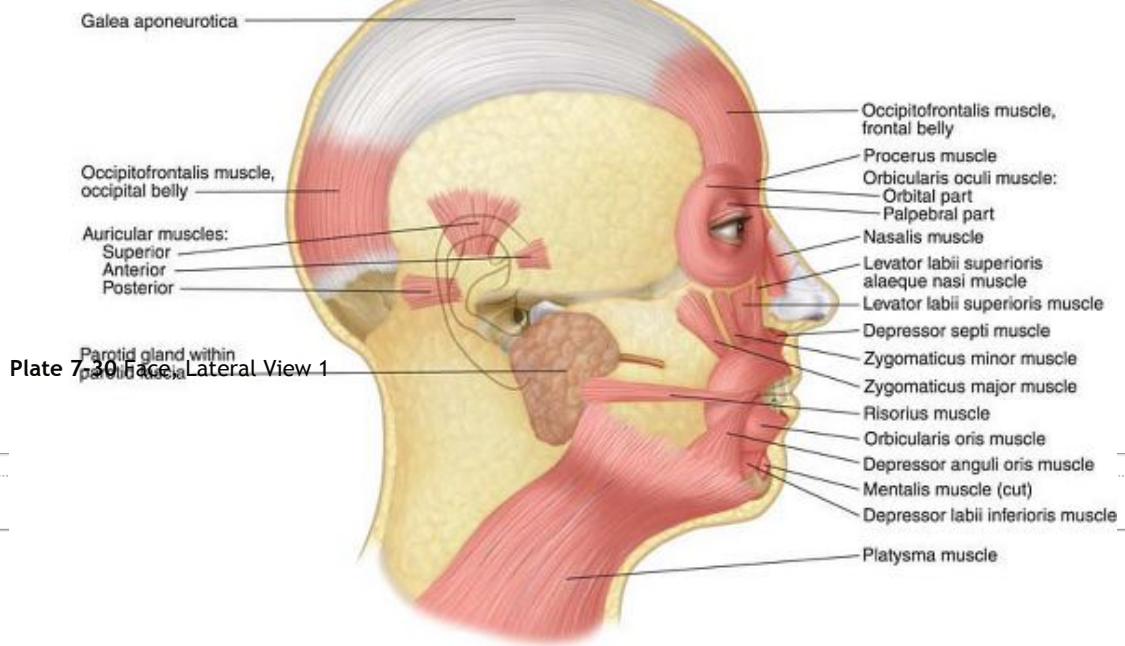


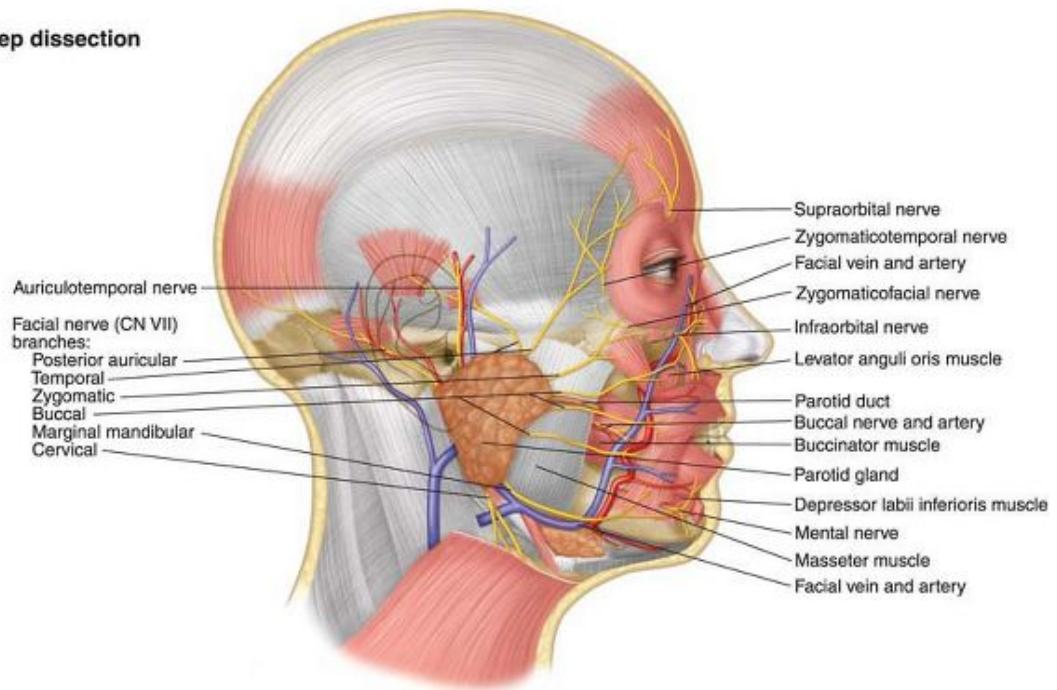
Plate 7-29 Face, Anterior View

P.325

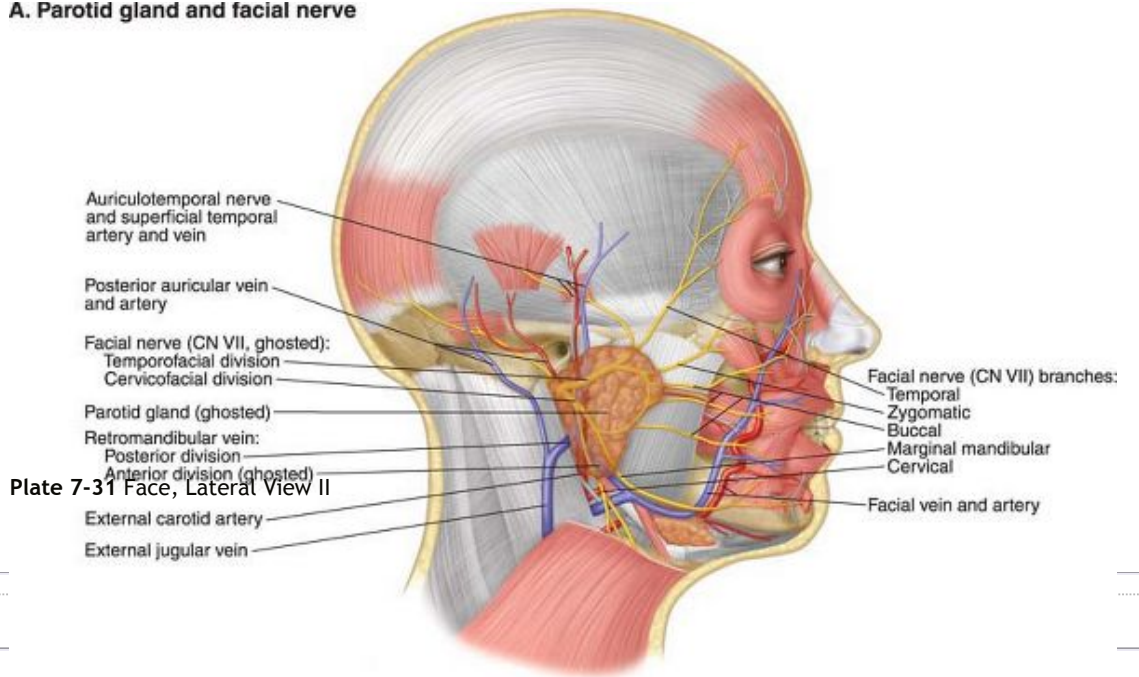
A. Superficial dissection



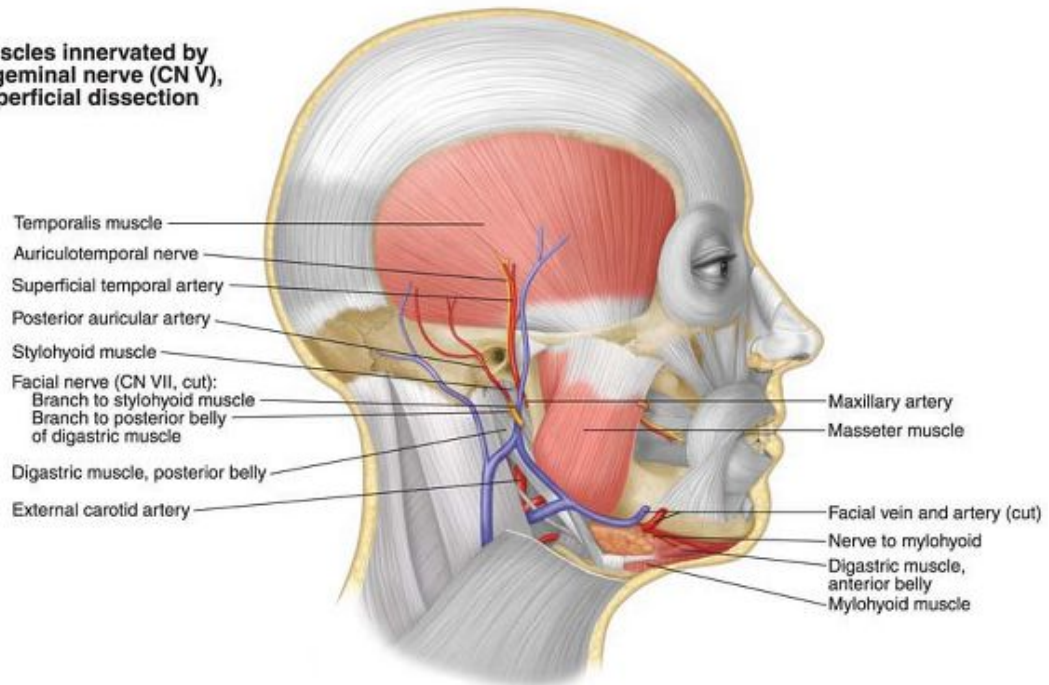
B. Deep dissection



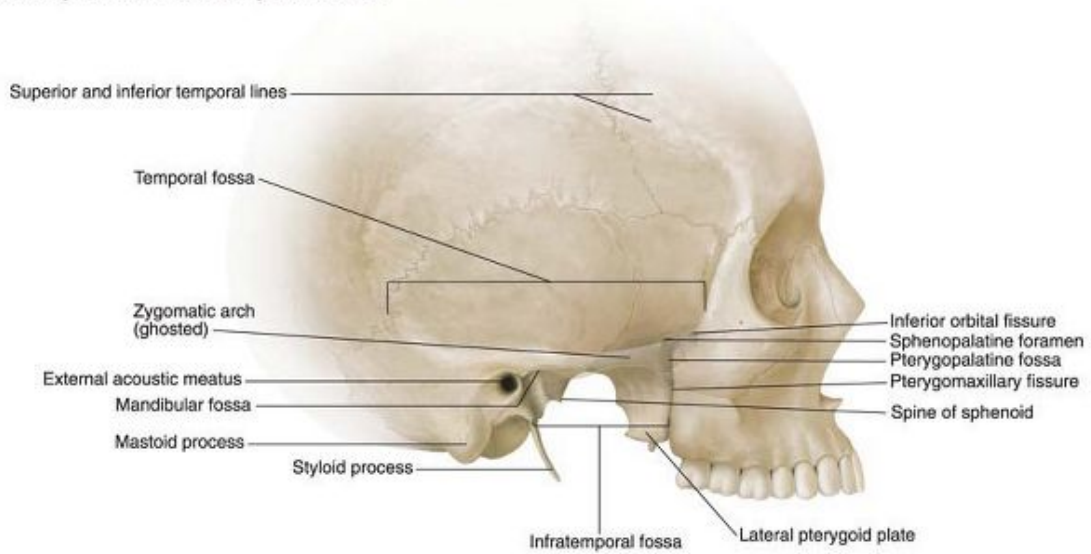
A. Parotid gland and facial nerve



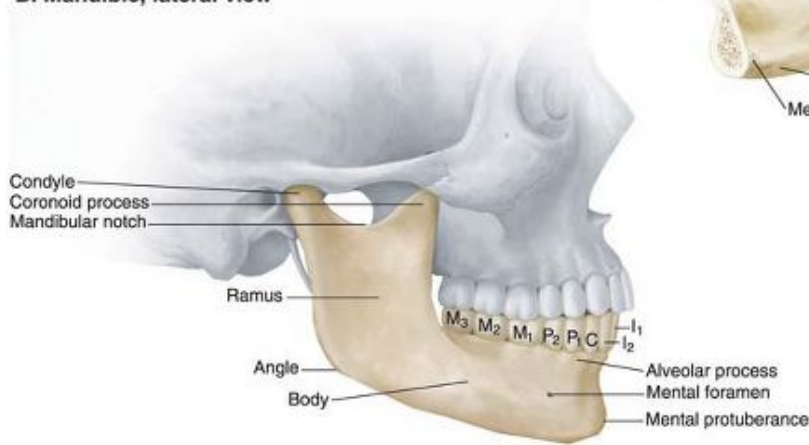
B. Muscles innervated by trigeminal nerve (CN V), superficial dissection



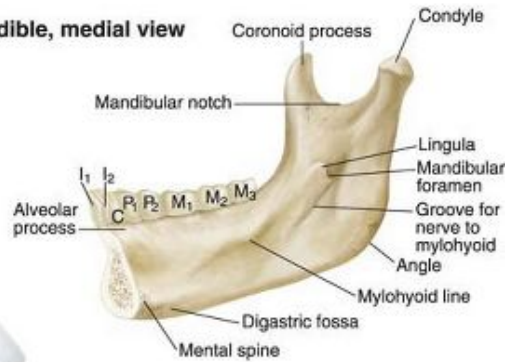
A. Temporal and infratemporal fossae



B. Mandible, lateral view

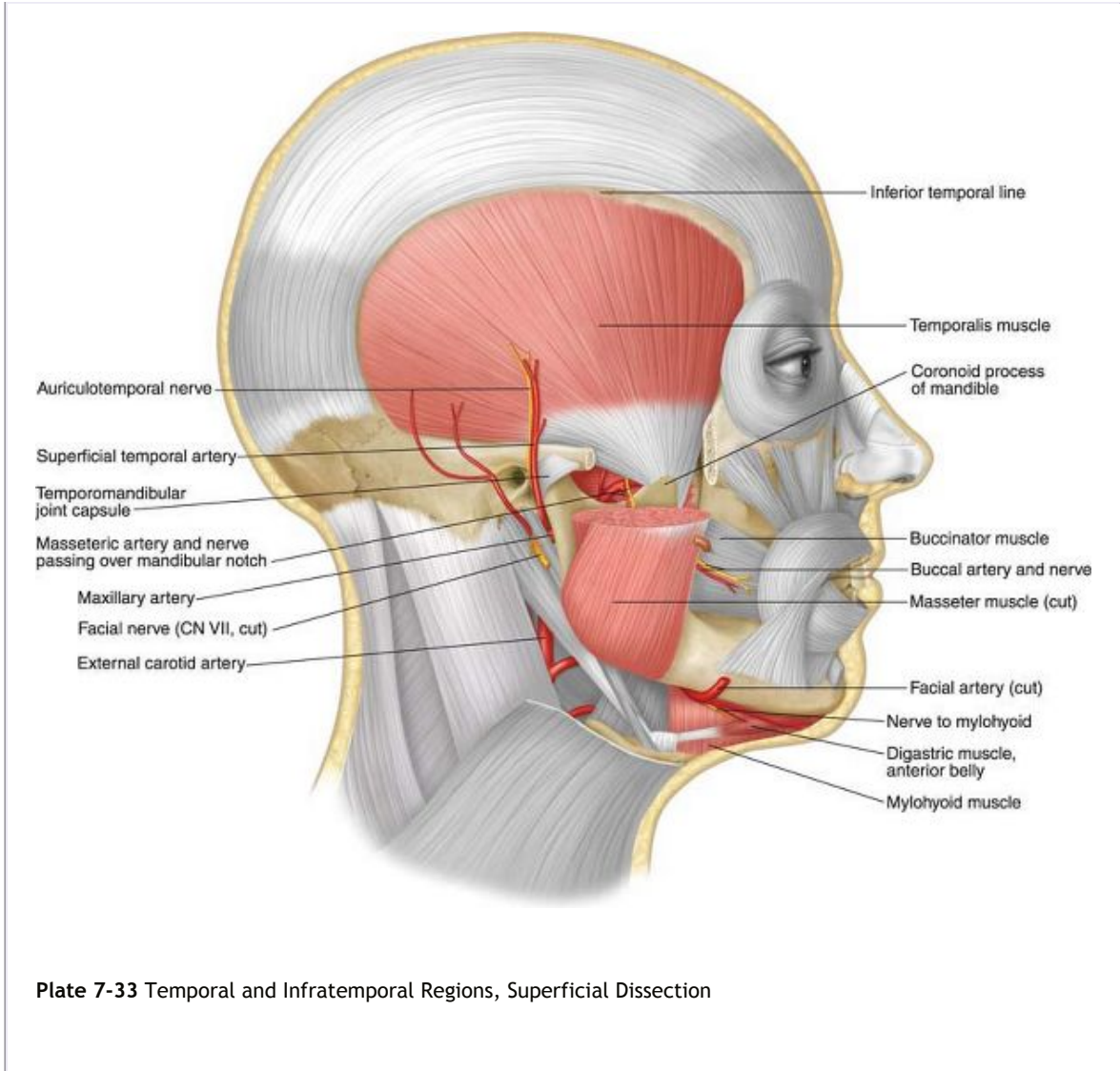


C. Mandible, medial view



Key to teeth:
 I = incisor
 C = canine
 P = premolar
 M = molar

Plate 7-32 Bones of the Temporal and Infratemporal Regions



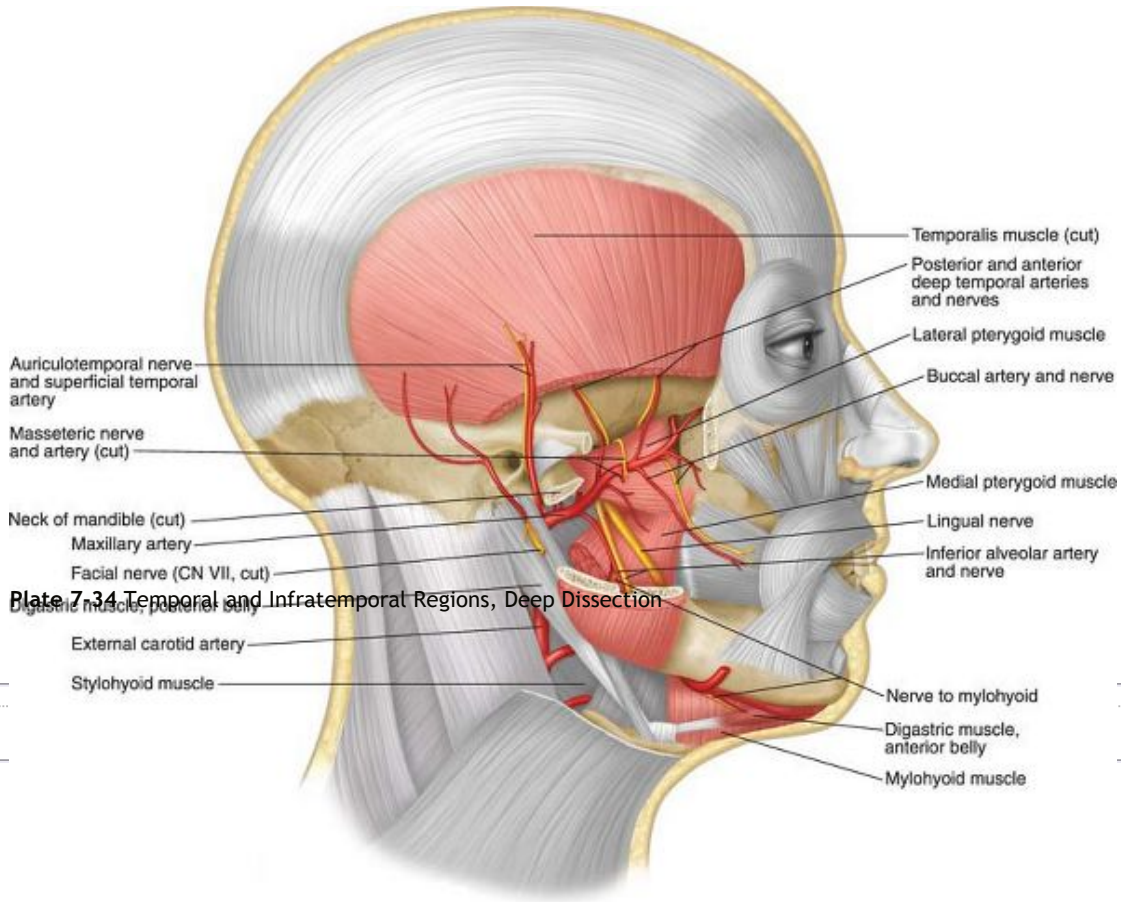
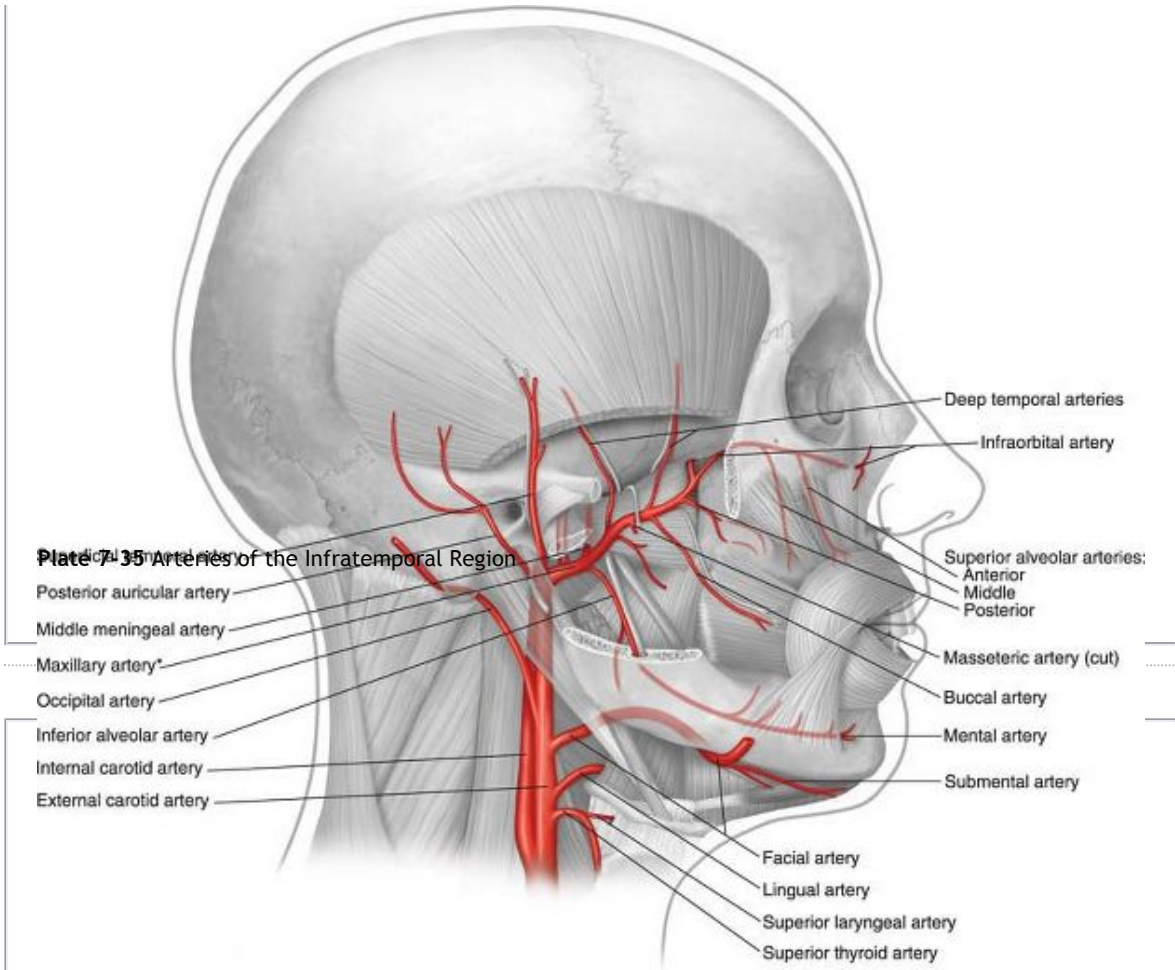
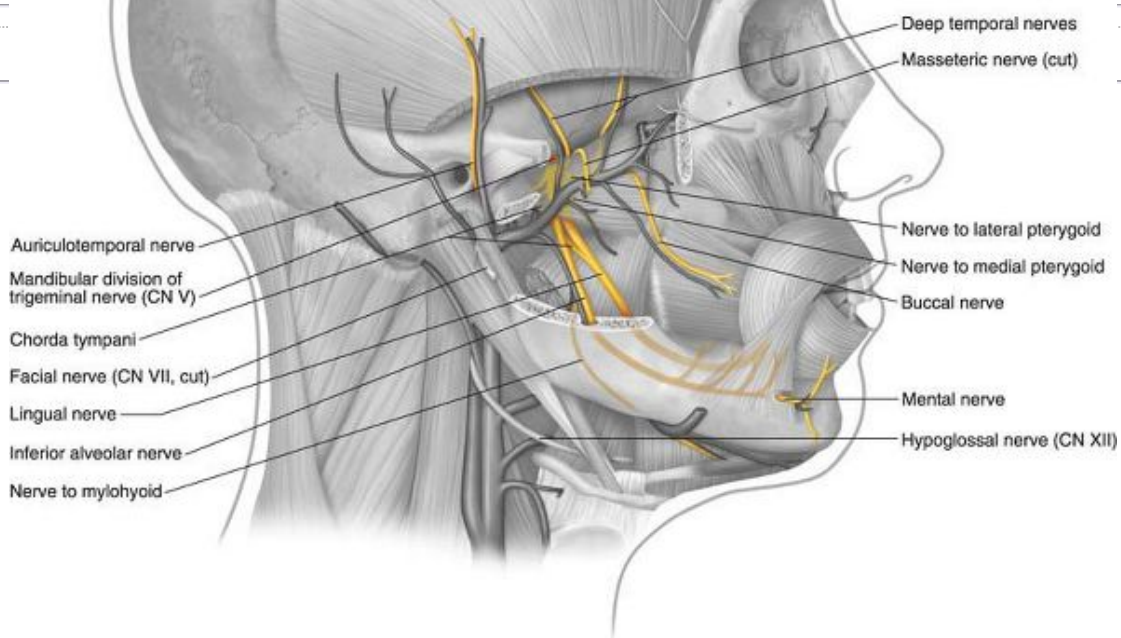


Plate 7.34 Temporal and Infratemporal Regions, Deep Dissection



* The maxillary artery may pass medial (42%) or lateral to lateral pterygoid muscle

Plate 7-36 Nerves of the Infratemporal Region



A. Lateral view

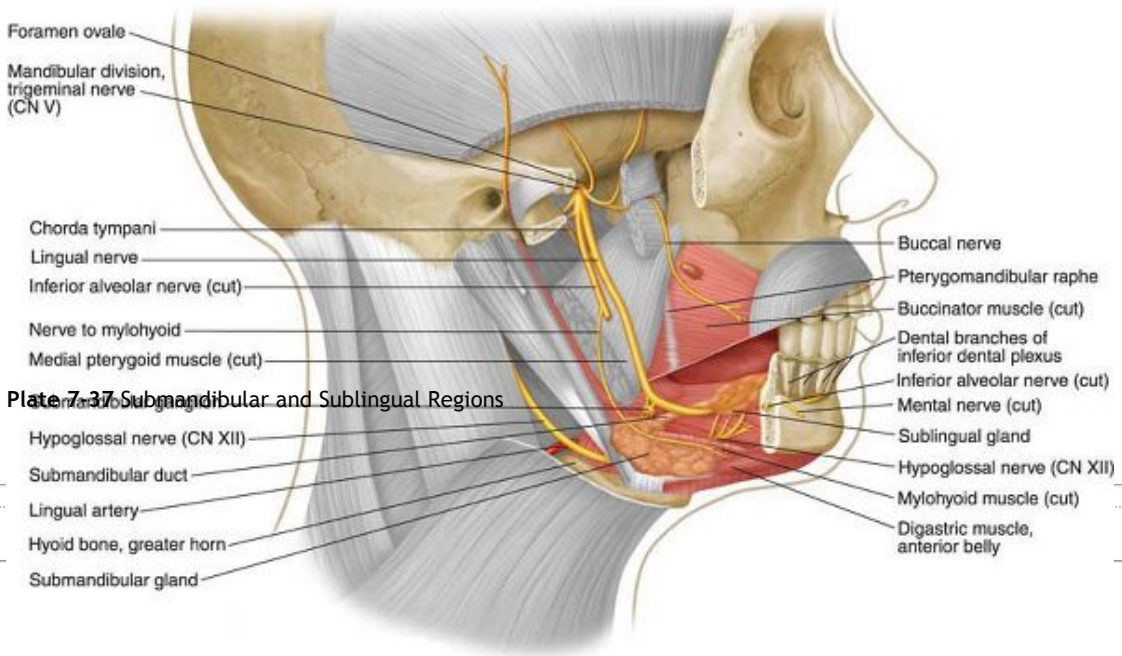
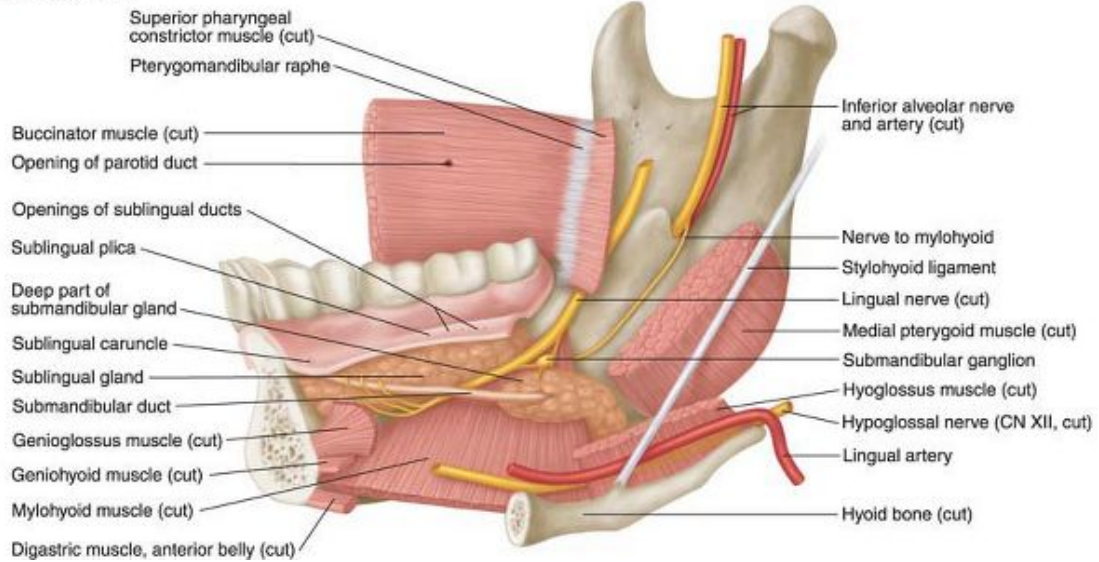
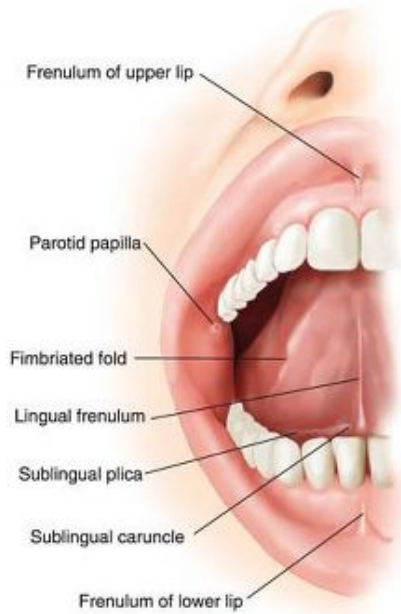

Plate 7.37 Submandibular and Sublingual Regions

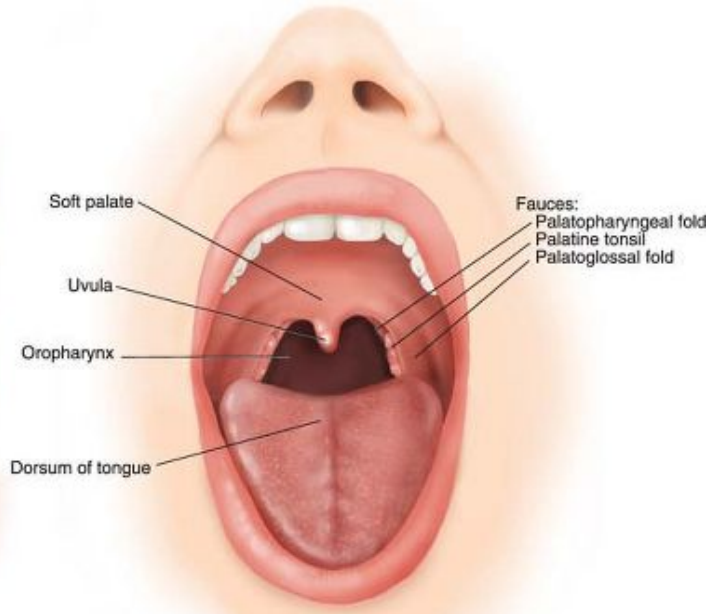
B. Medial view



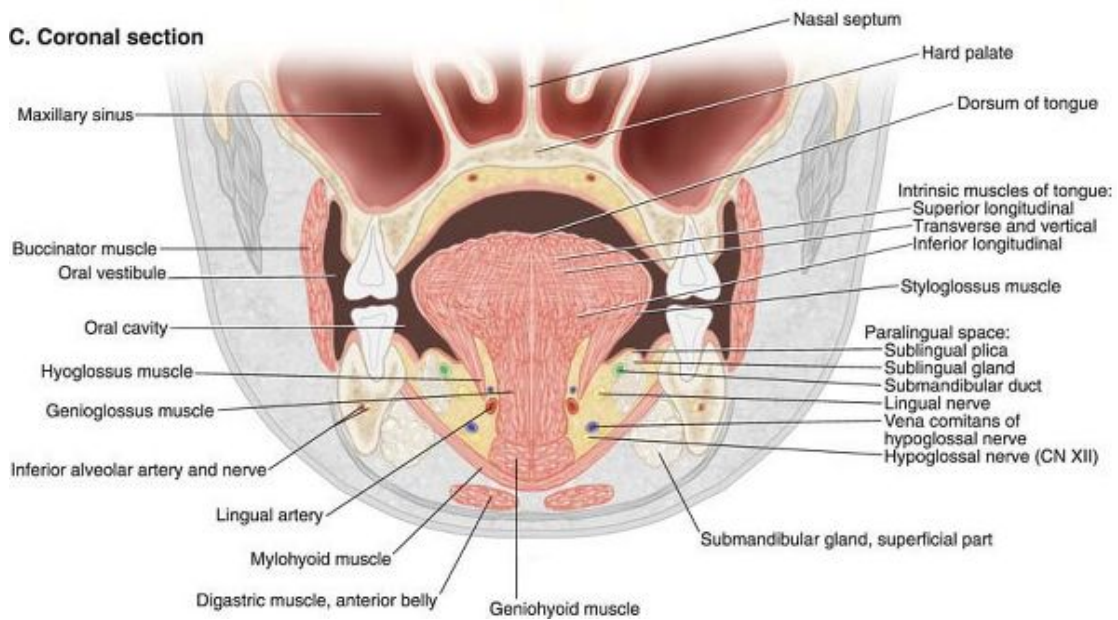
A. Mucosal features



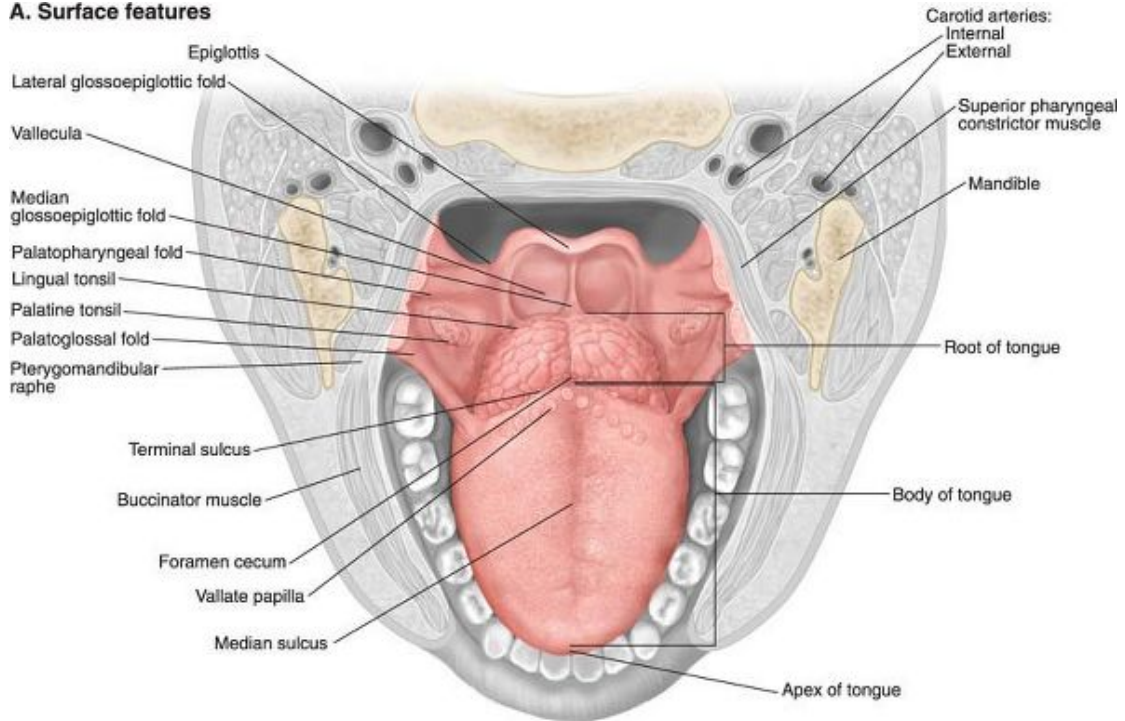
B. Palate and fauces



C. Coronal section



A. Surface features



B. Innervation

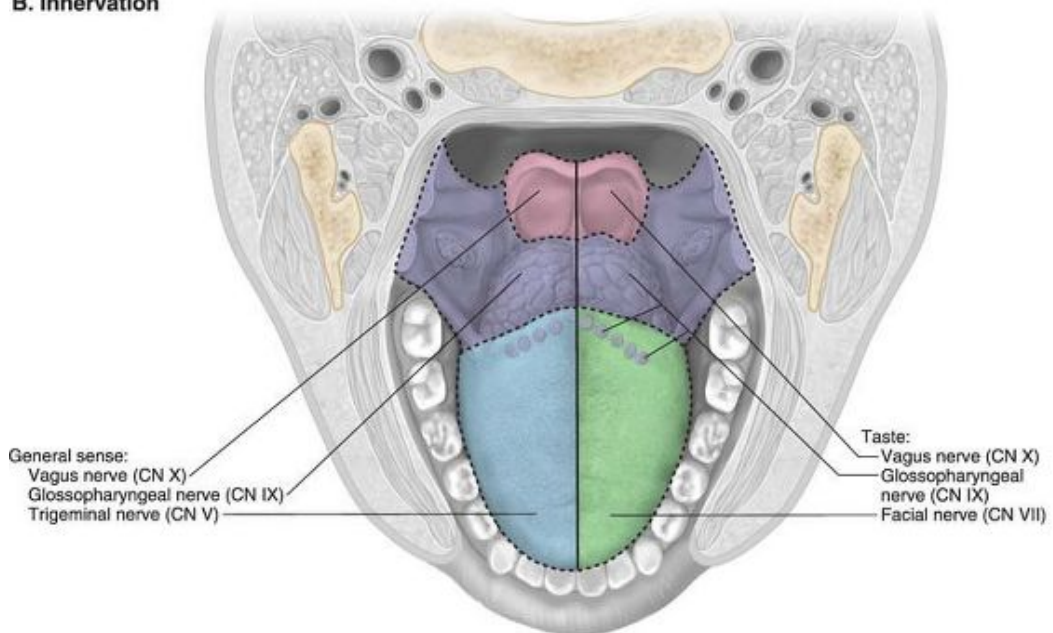
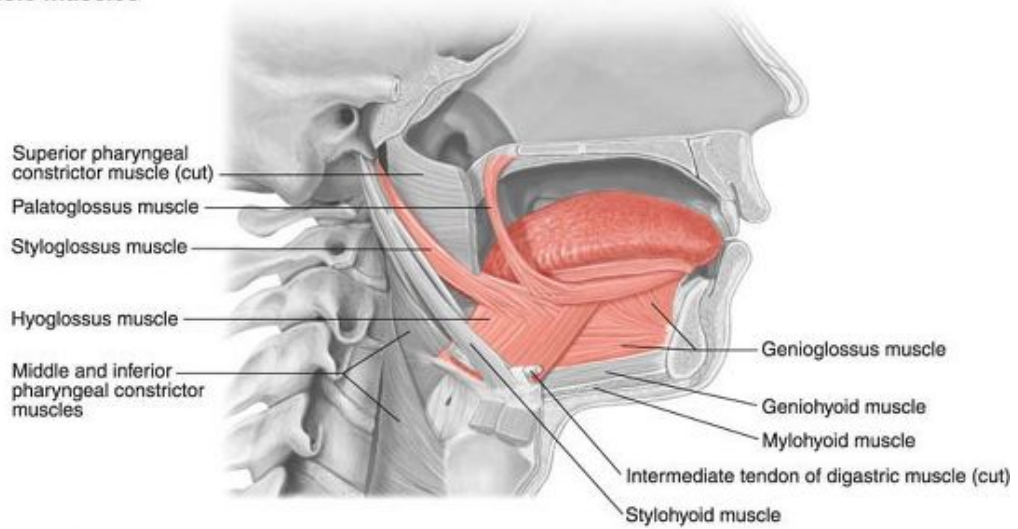
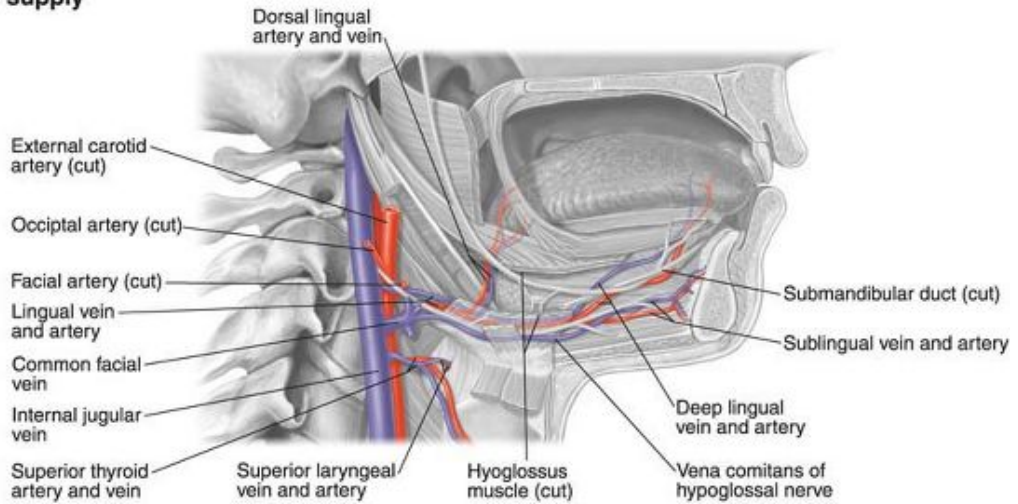


Plate 7-39 Dorsum of Tongue

A. Extrinsic muscles



B. Blood supply



C. Nerve supply

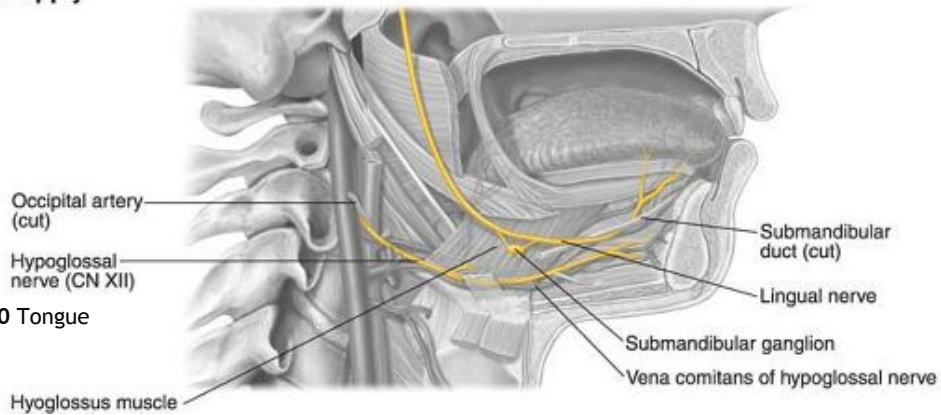
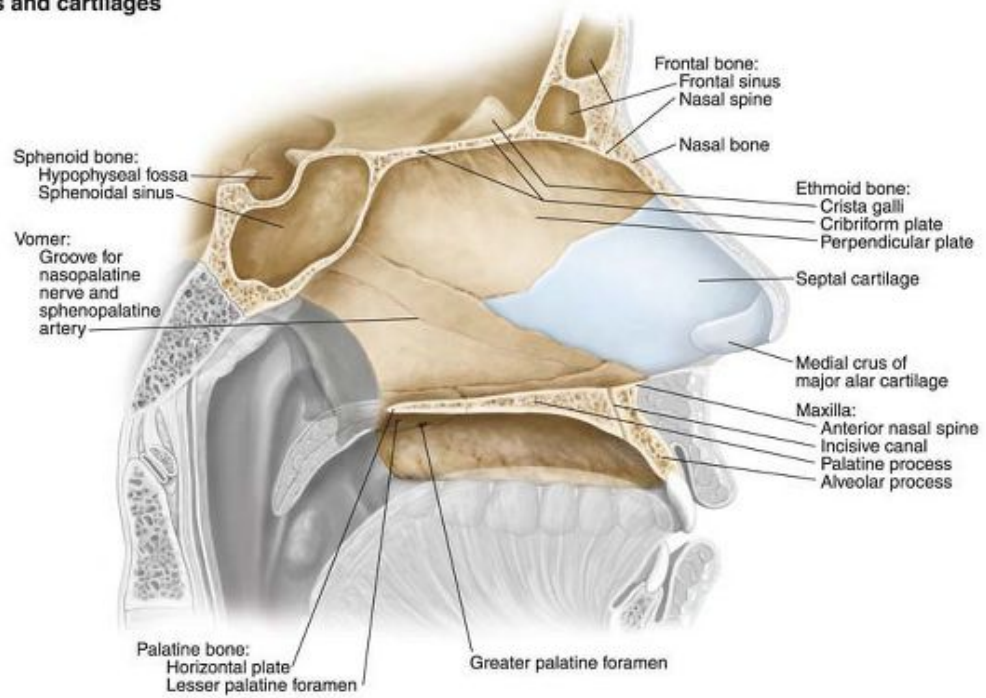


Plate 7-40 Tongue

A. Bones and cartilages



B. Mucosal features

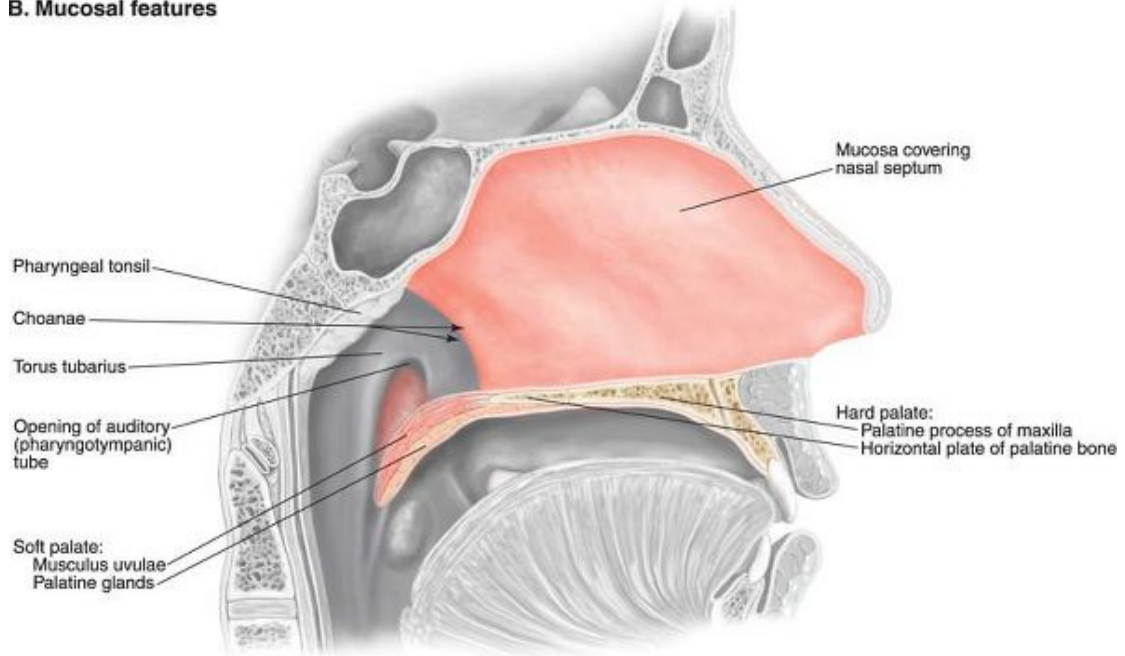


Plate 7-41 Nasal Septum and Palate

A. Bones

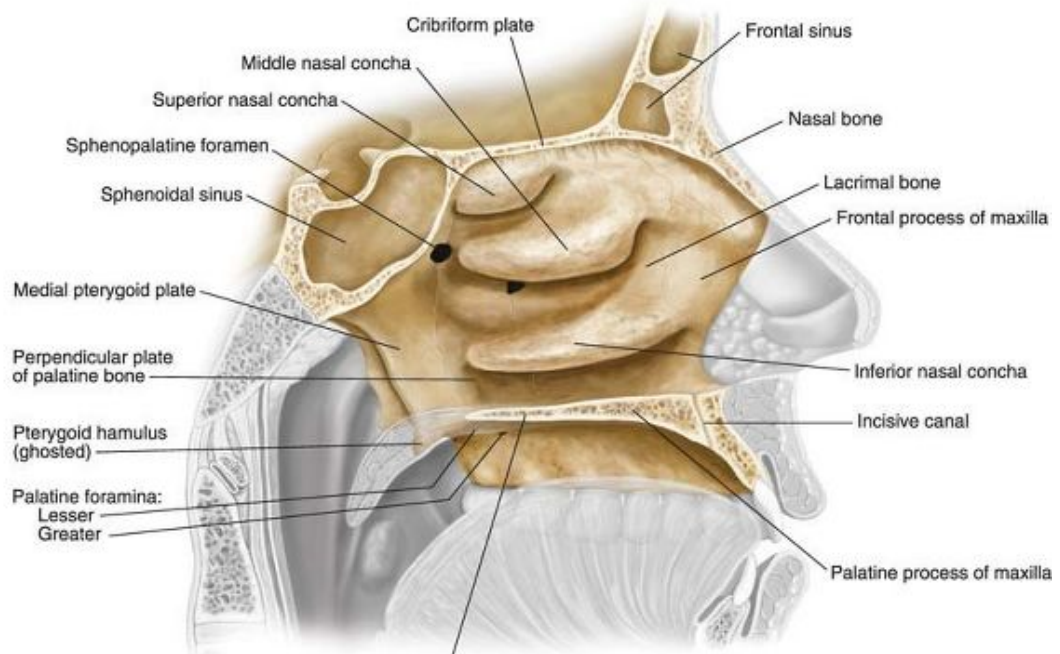
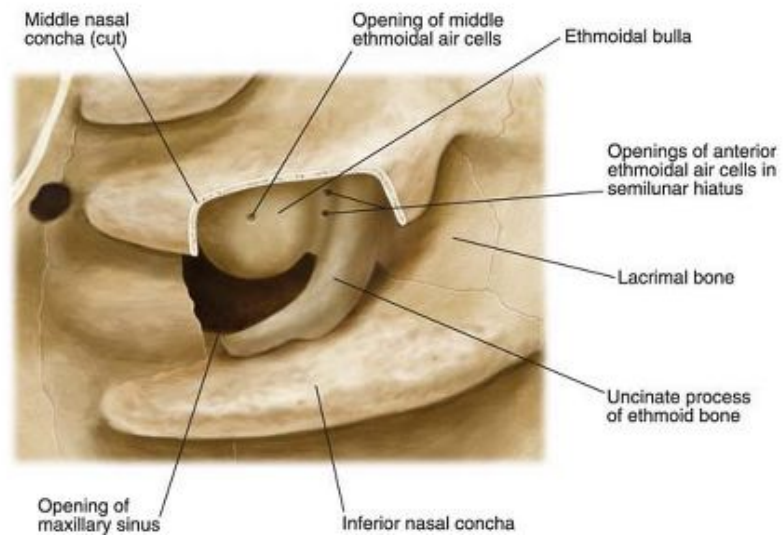
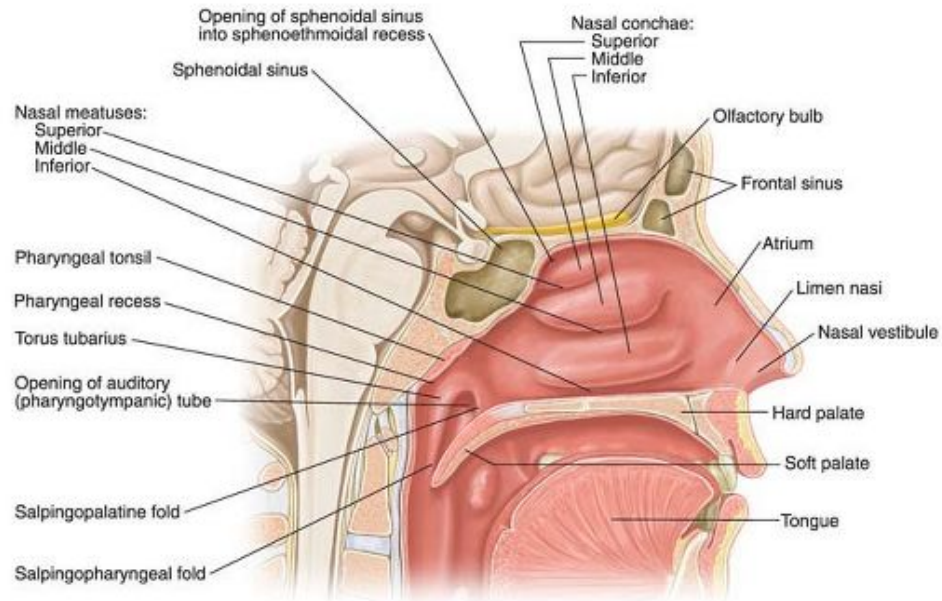


Plate 7-42 Lateral Wall of Nasal Cavity

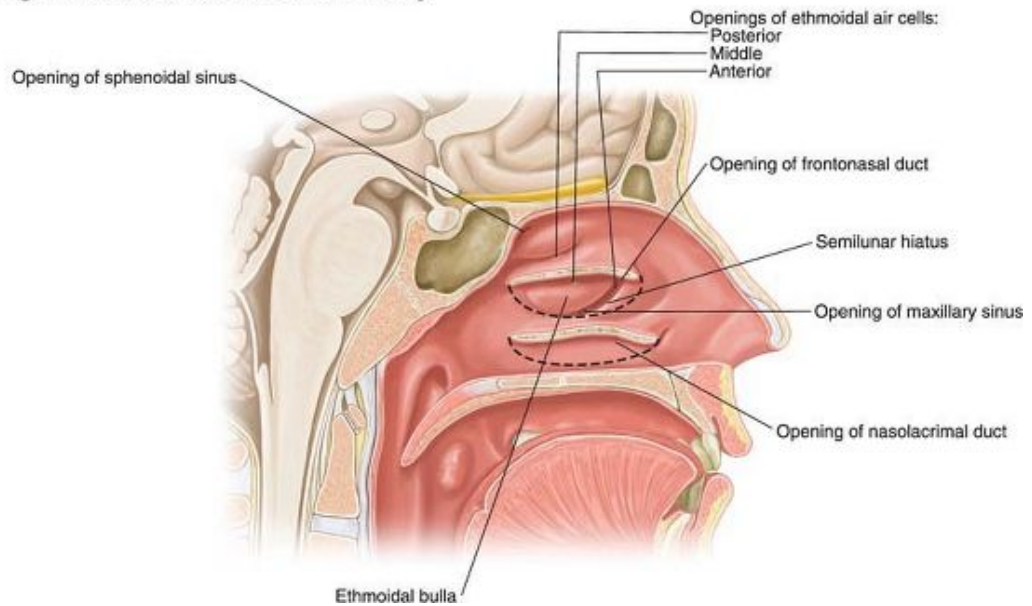
B. Bones of the middle meatus



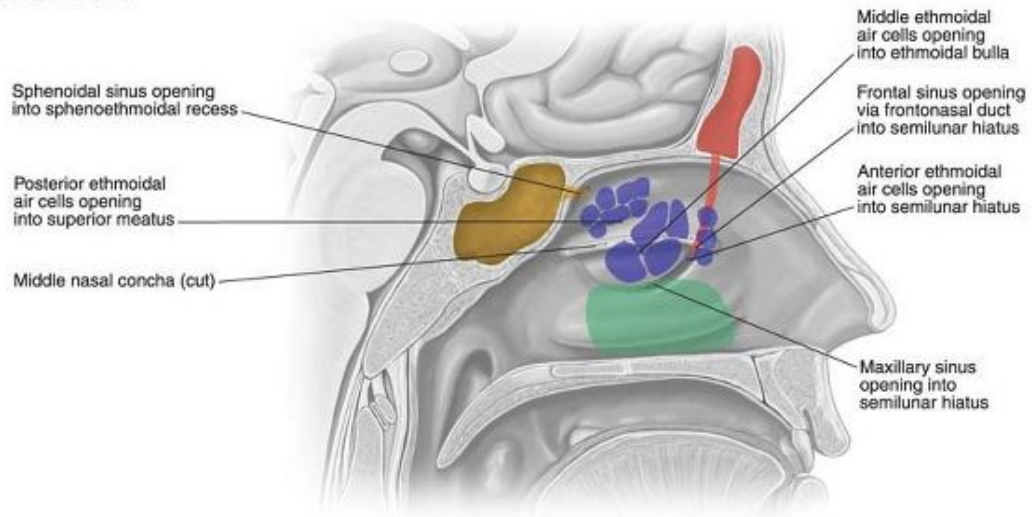
A. Nasal conchae and meatuses



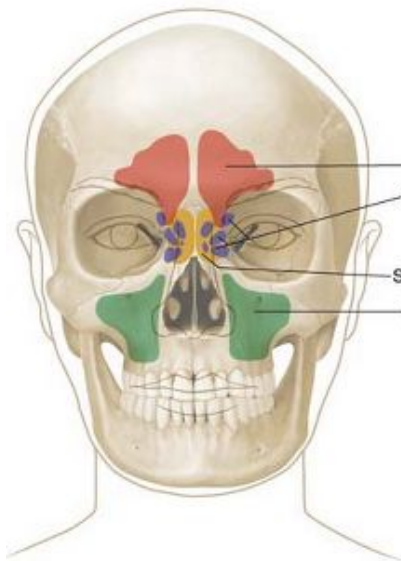
B. Openings in the lateral wall of the nasal cavity



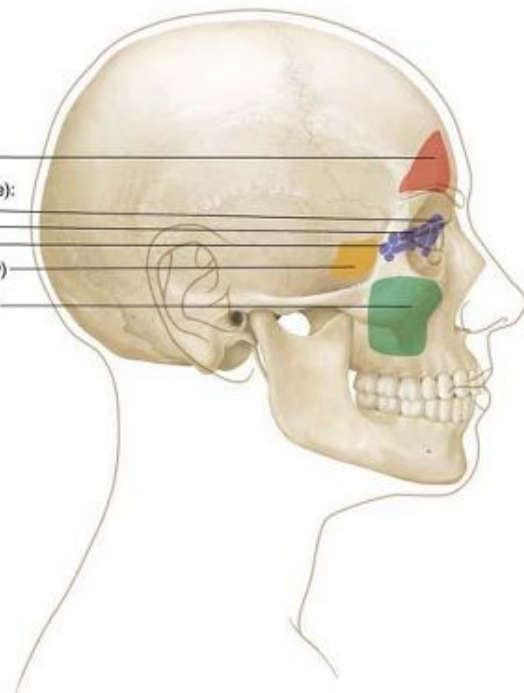
A. Medial view



B. Anterior view



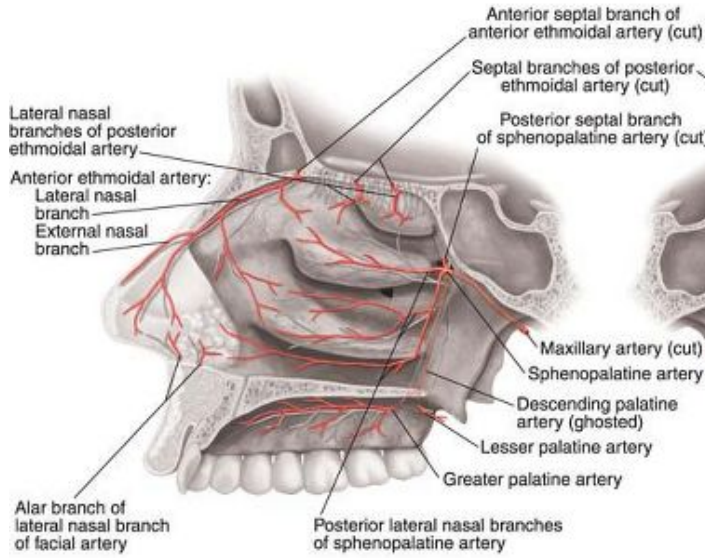
C. Lateral view



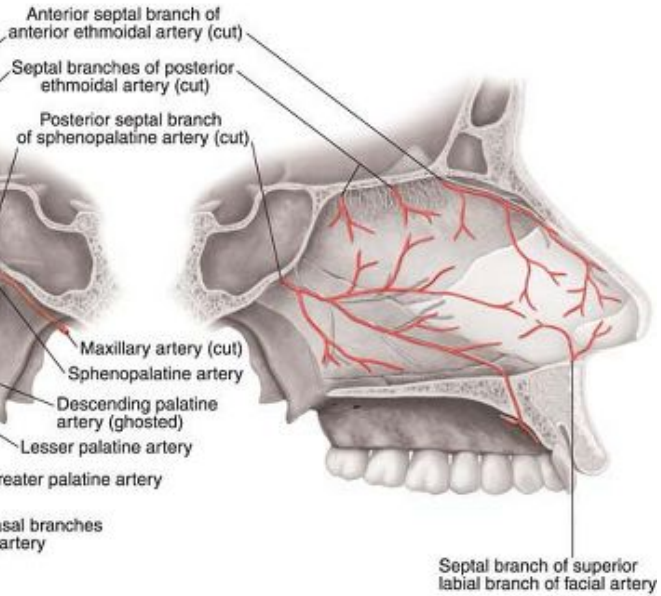
- Frontal sinus (red)
- Ethmoidal air cells (blue):
 - Anterior
 - Middle
 - Posterior
- Sphenoidal sinus (yellow)
- Maxillary sinus (green)

Plate 7-44 Paranasal Sinuses

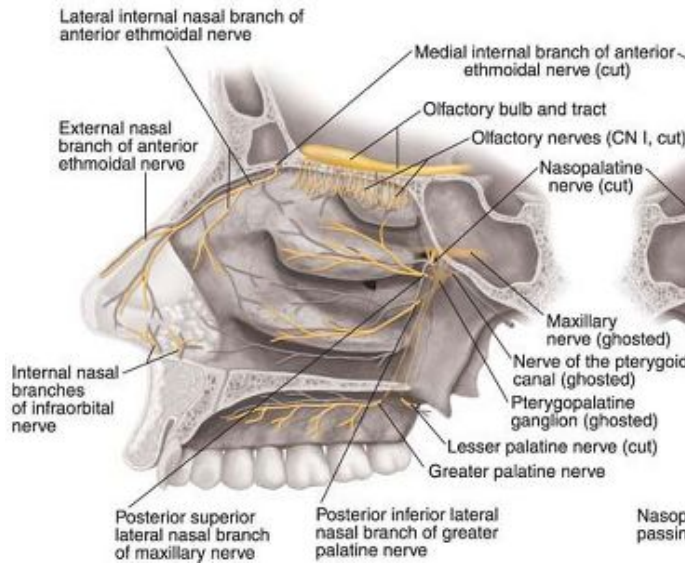
A. Blood supply of lateral wall



B. Blood supply of nasal septum



C. Nerves of lateral wall



D. Nerves of nasal septum

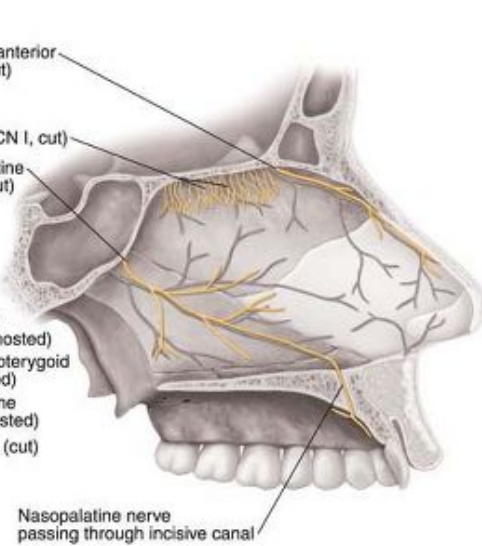


Plate 7-45 Blood Supply and Innervation of the Nasal Cavity

P.341

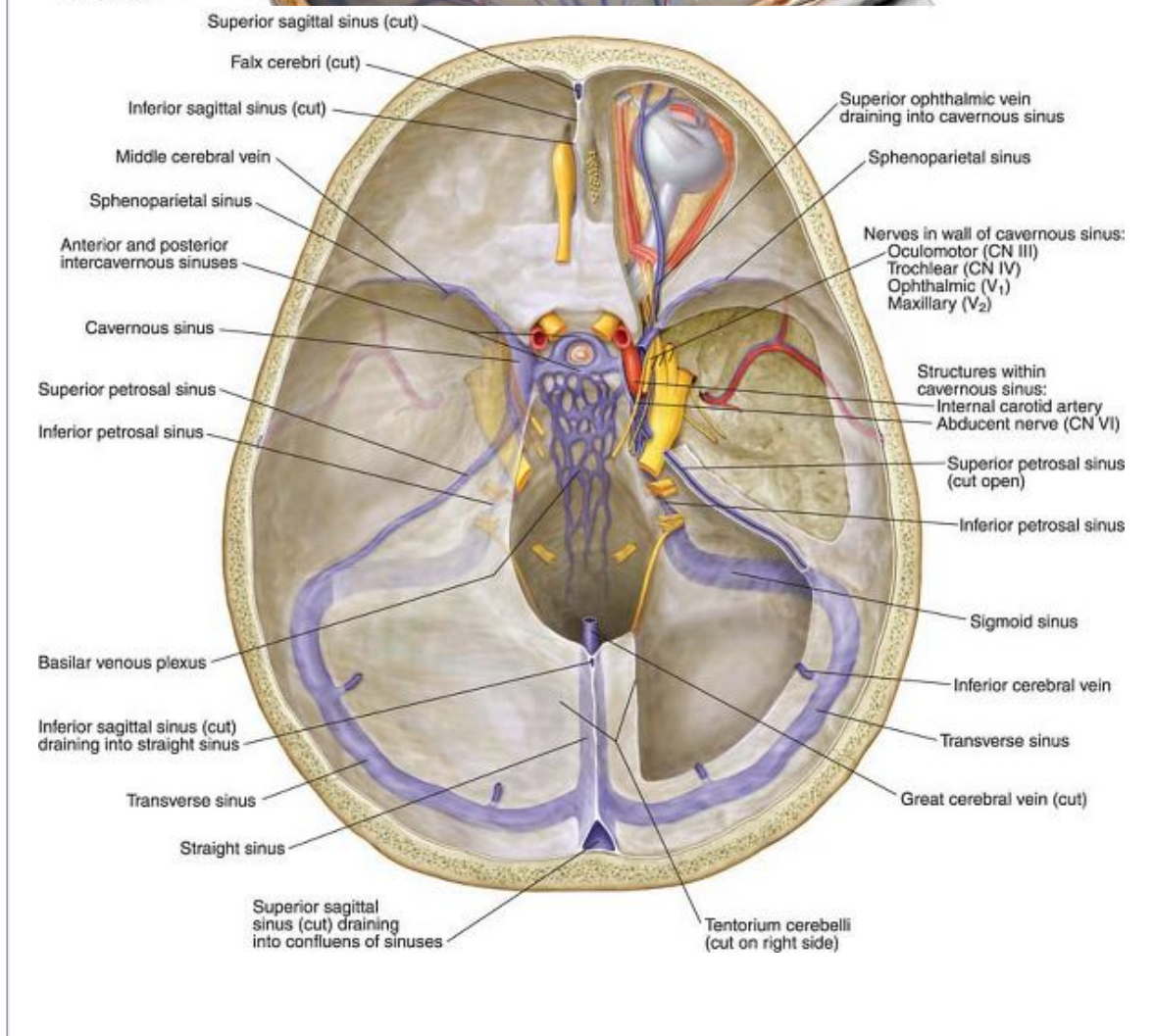
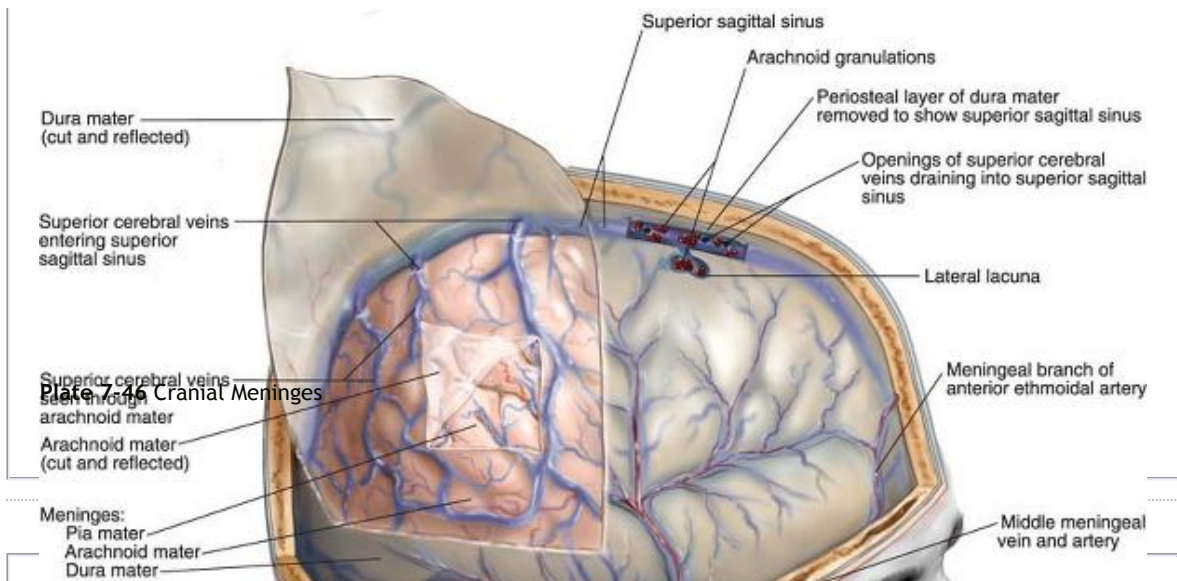


Plate 7-47 Dural Venous Sinuses, Superior View

P.343

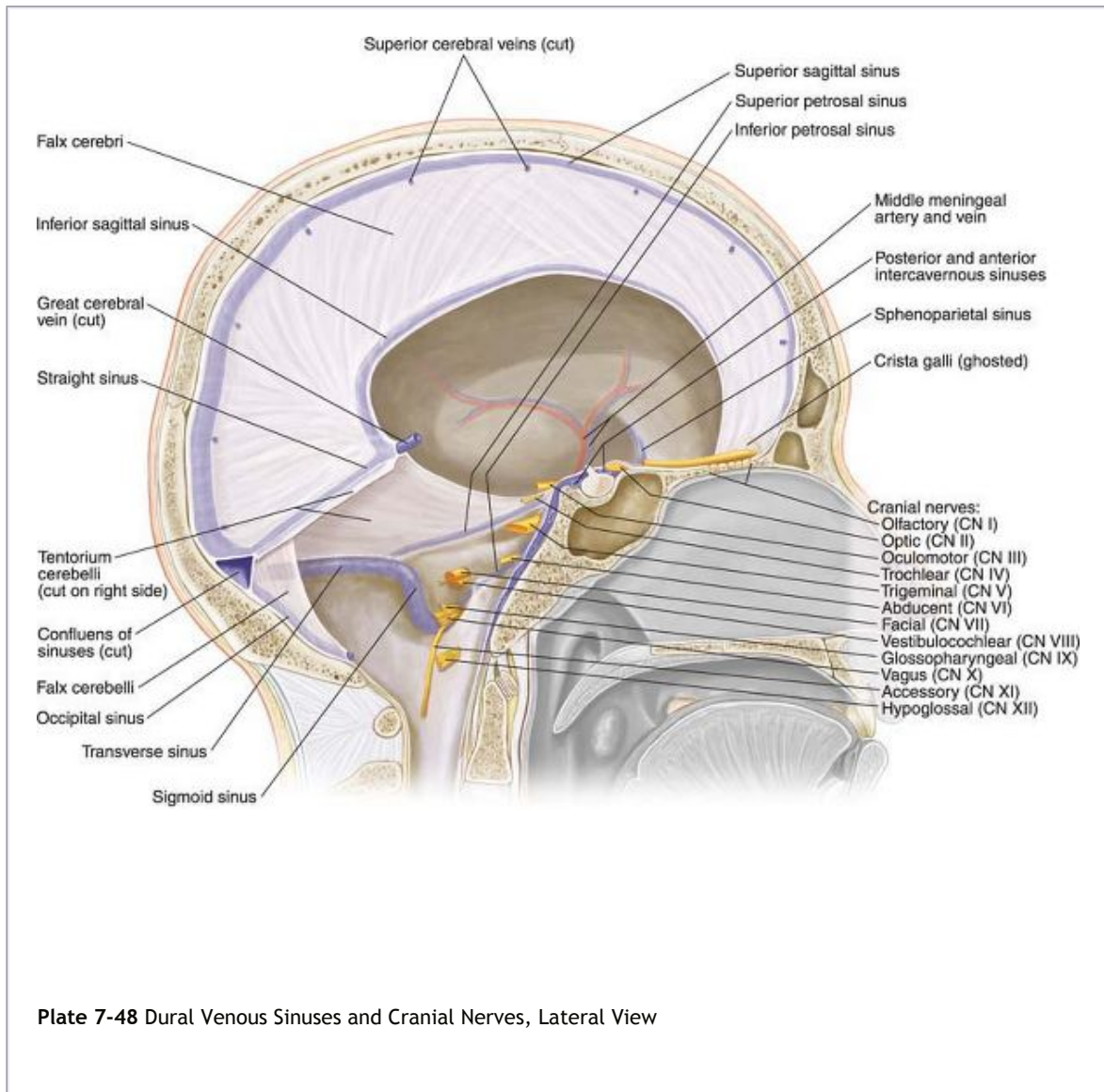
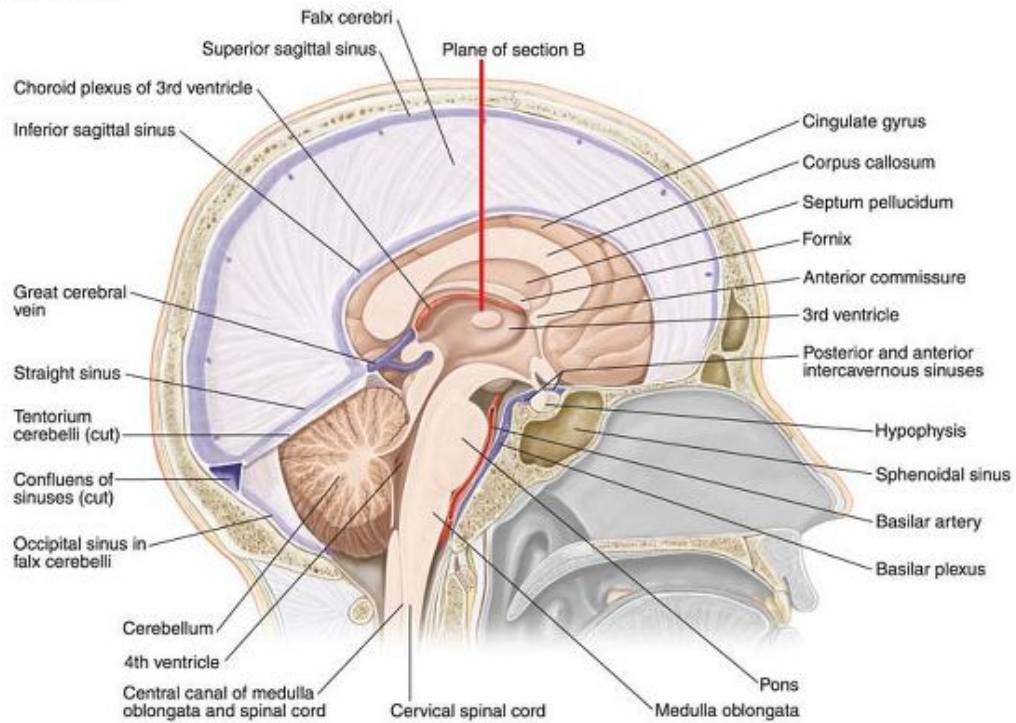


Plate 7-48 Dural Venous Sinuses and Cranial Nerves, Lateral View

P.344

A. Sagittal section



B. Coronal section

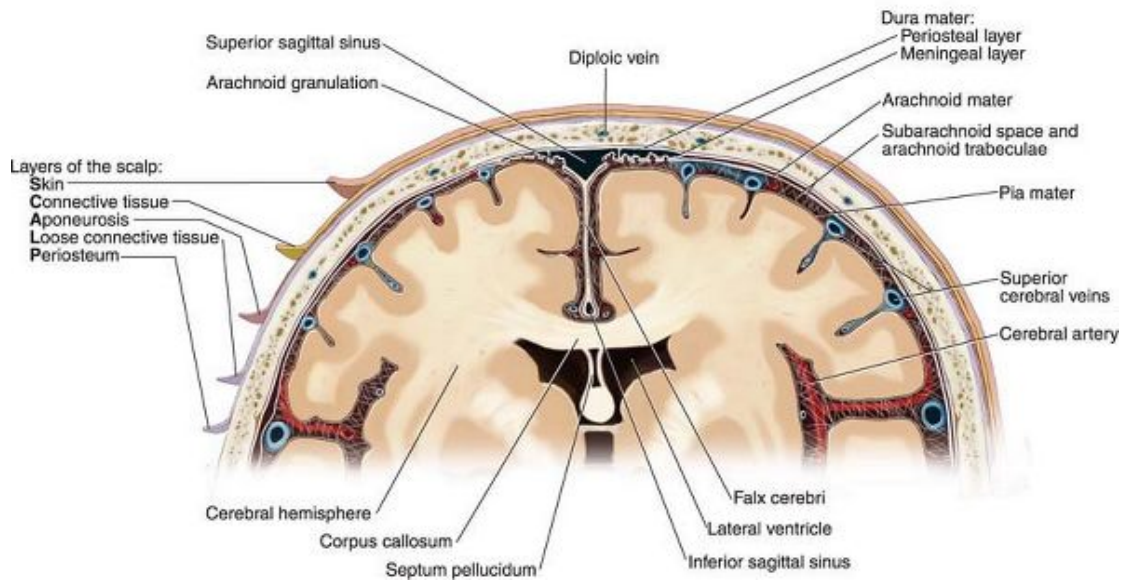
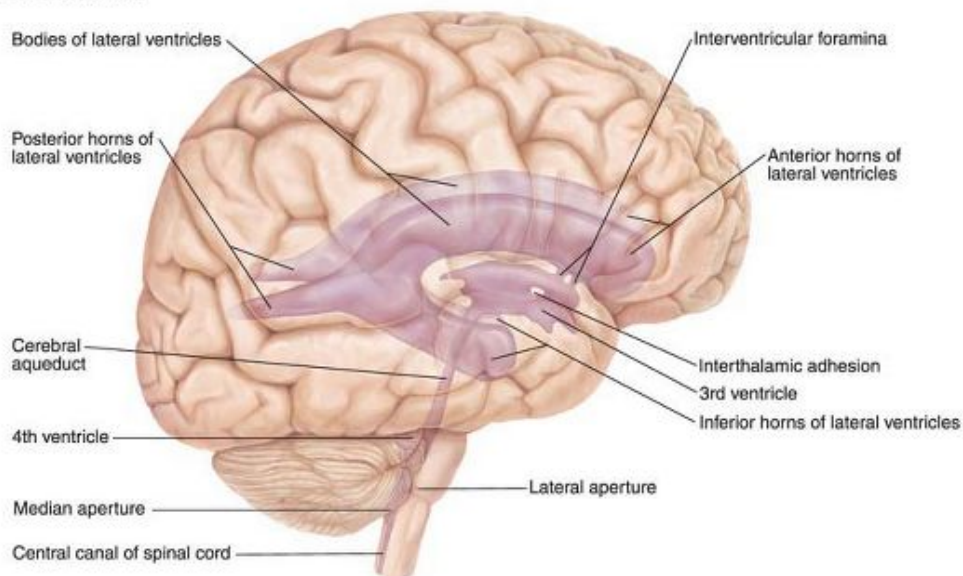


Plate 7-49 Dural Venous Sinuses, Sectioned

A. Location of ventricles



B. Circulation of cerebrospinal fluid

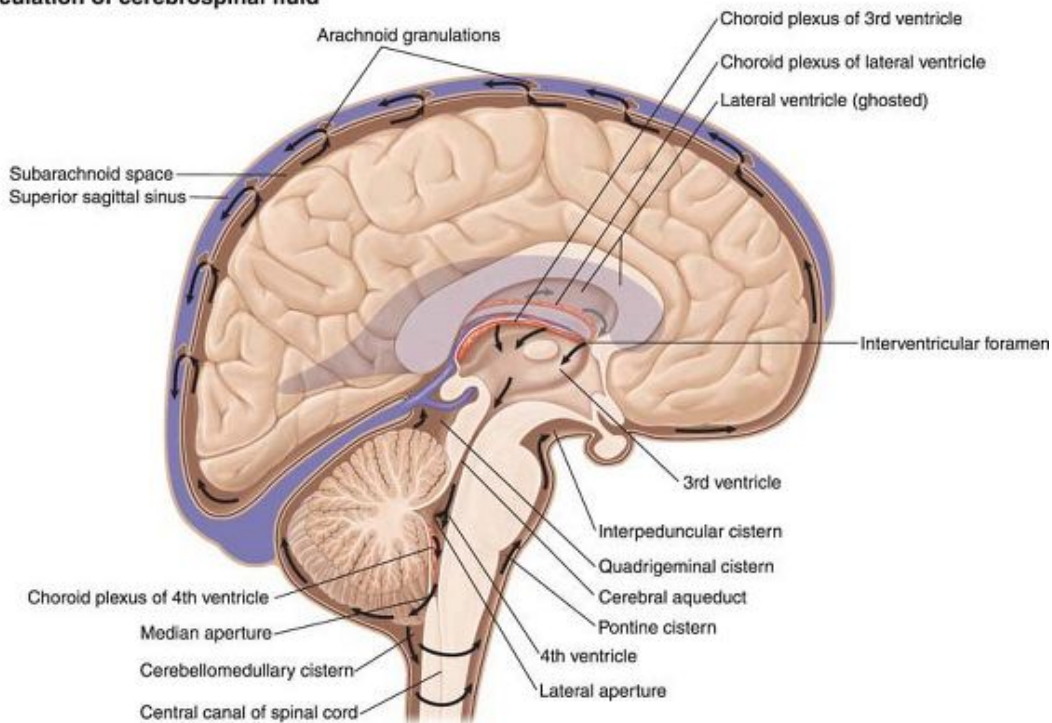


Plate 7-50 Ventricles of the Brain

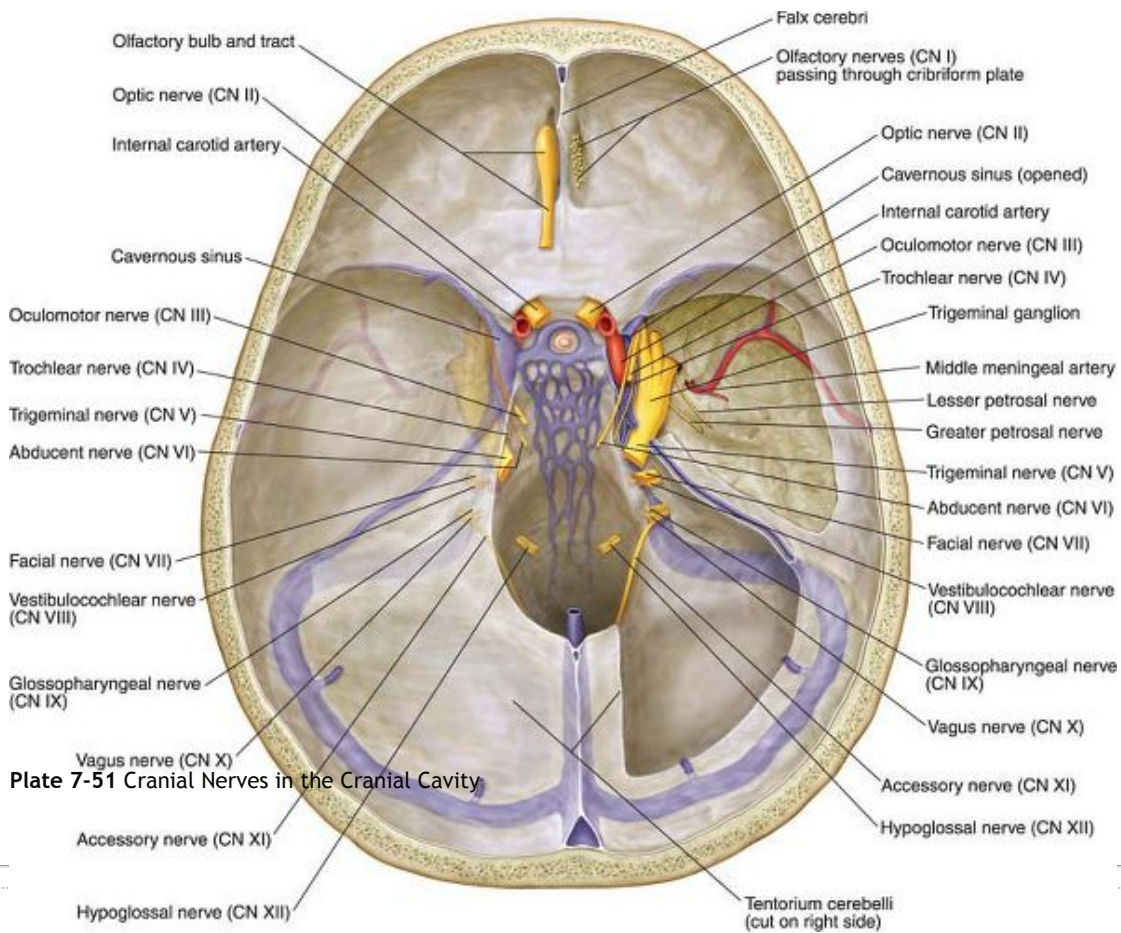


Plate 7-51 Cranial Nerves in the Cranial Cavity

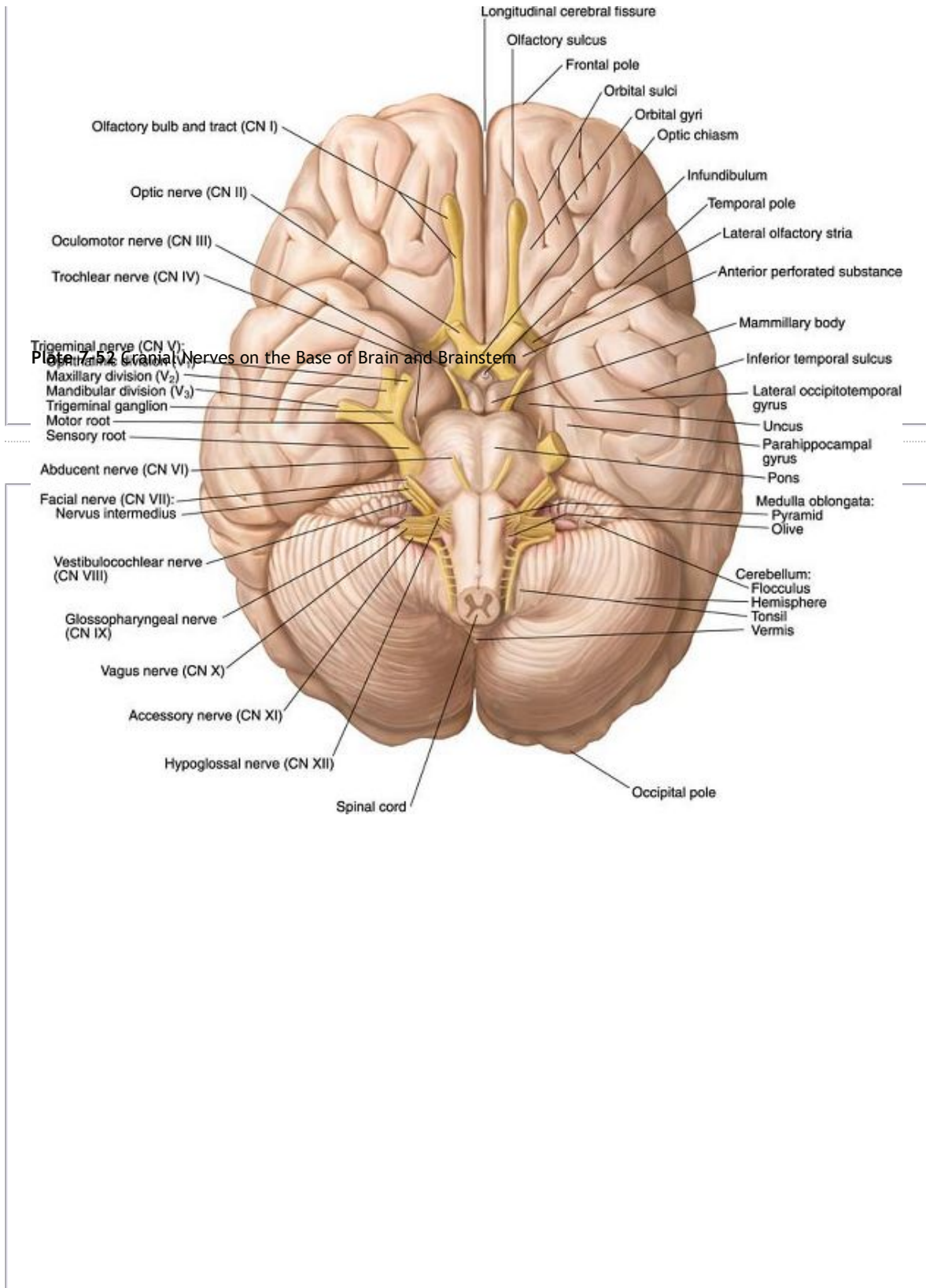


Plate 52 Cranial Nerves on the Base of Brain and Brainstem

A. Lateral view

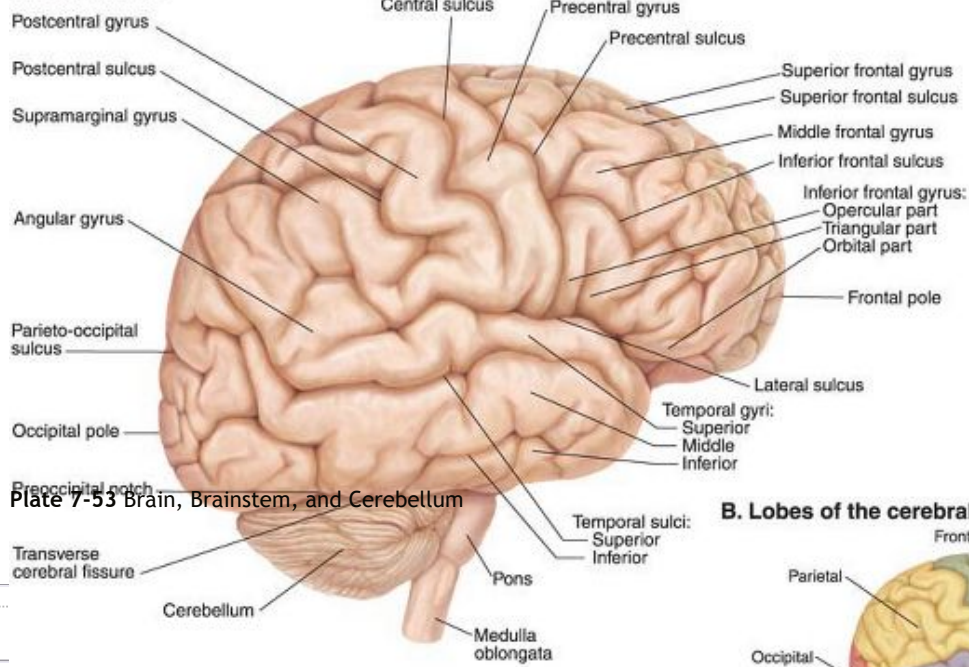
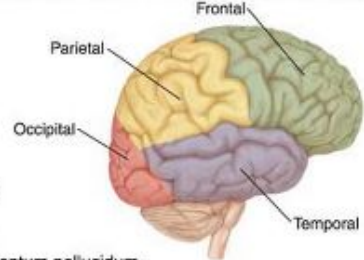
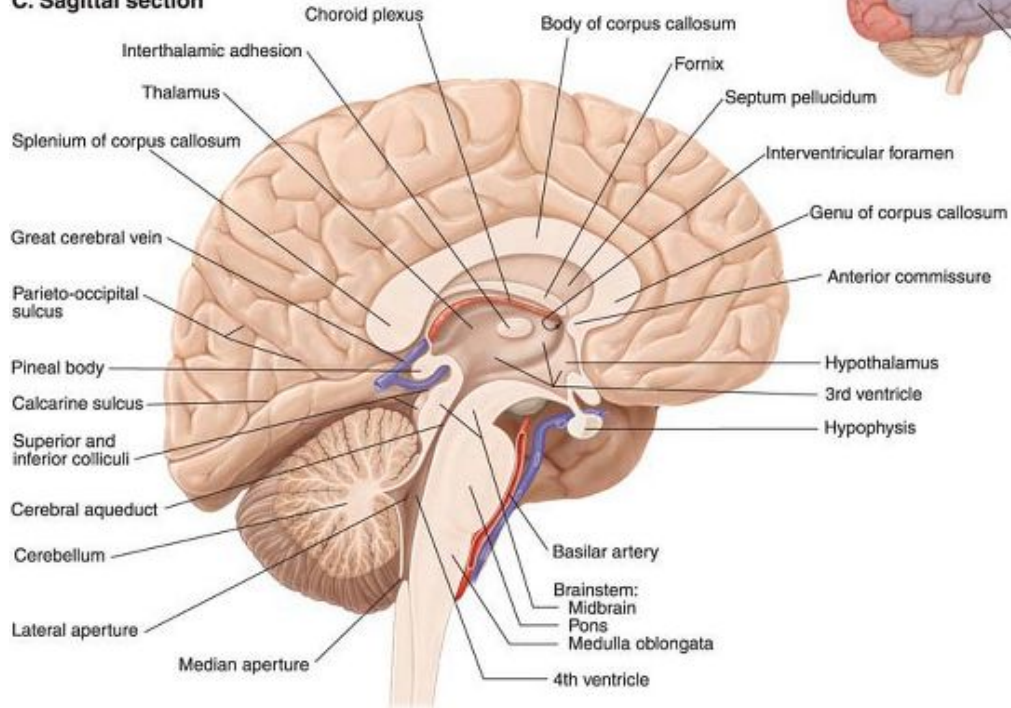


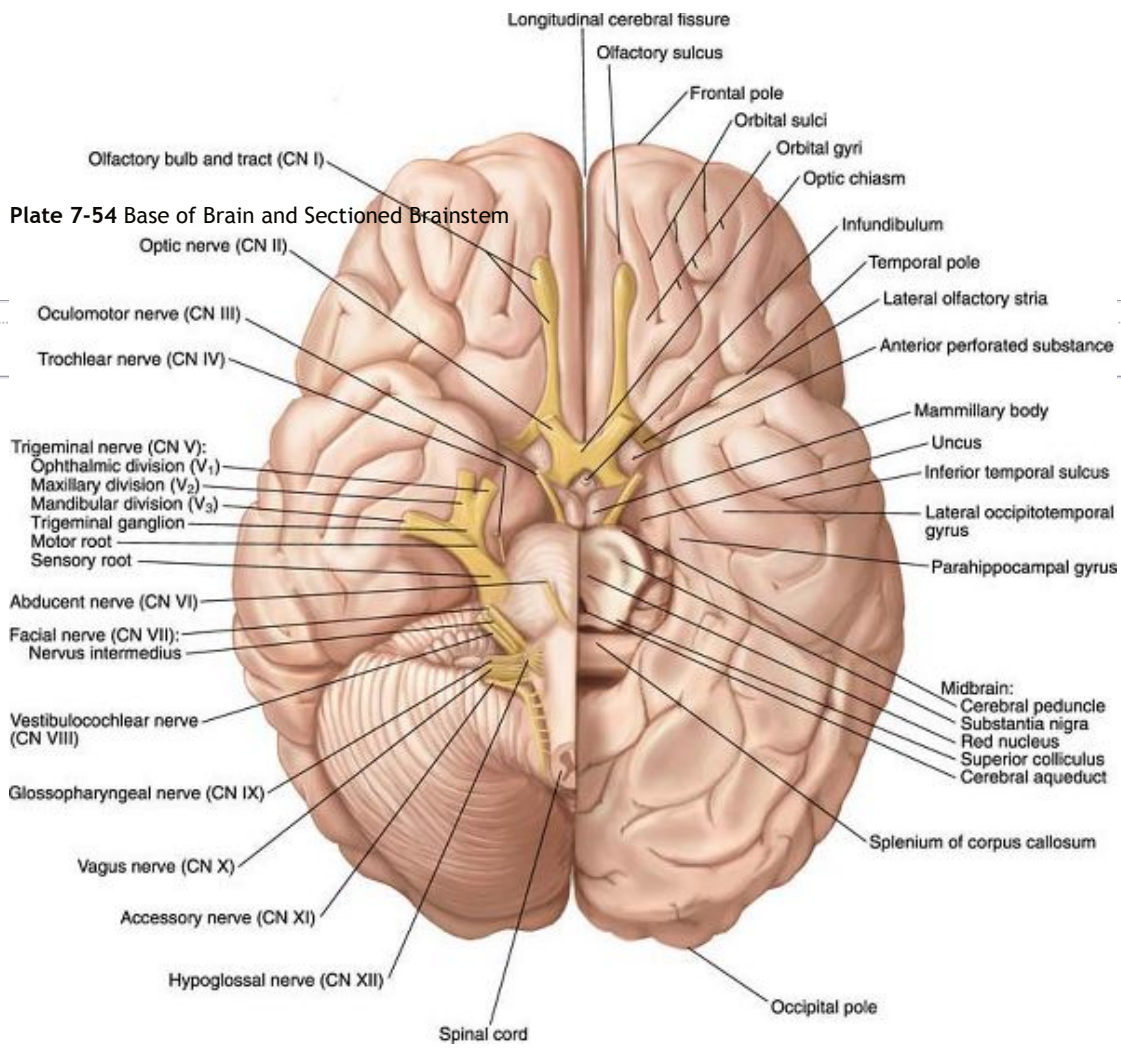
Plate 7-53 Brain, Brainstem, and Cerebellum

B. Lobes of the cerebral hemispheres

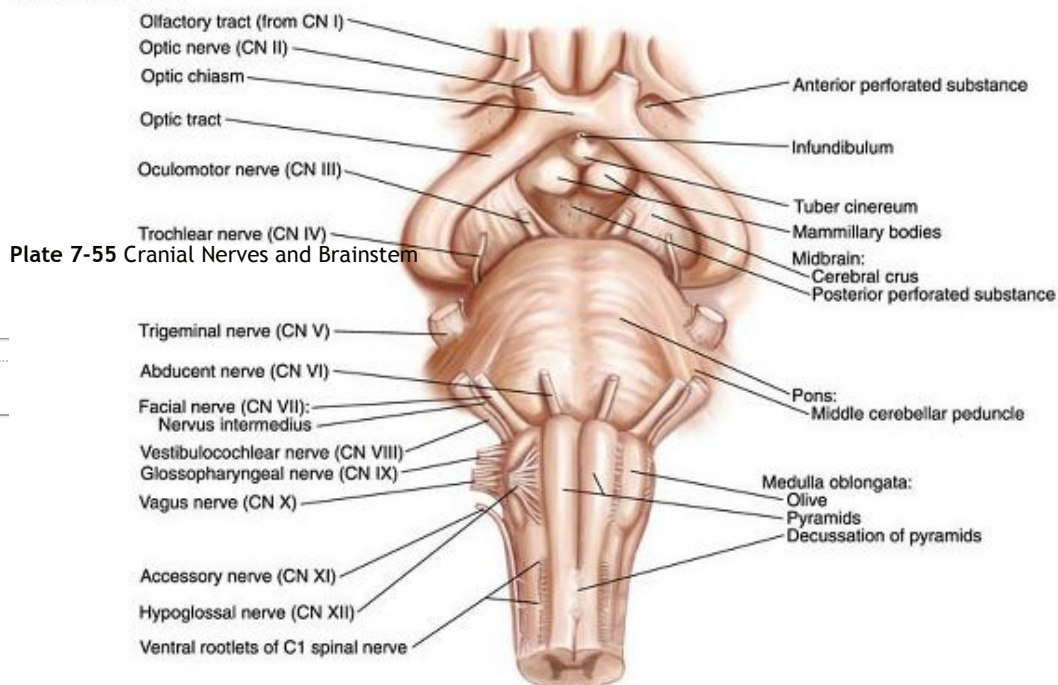


C. Sagittal section

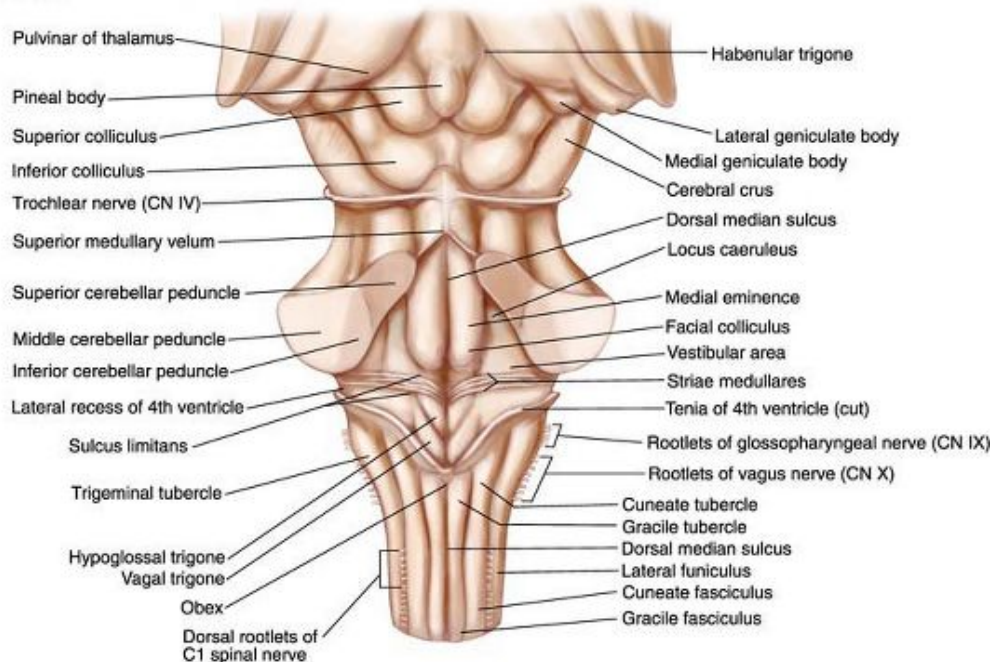




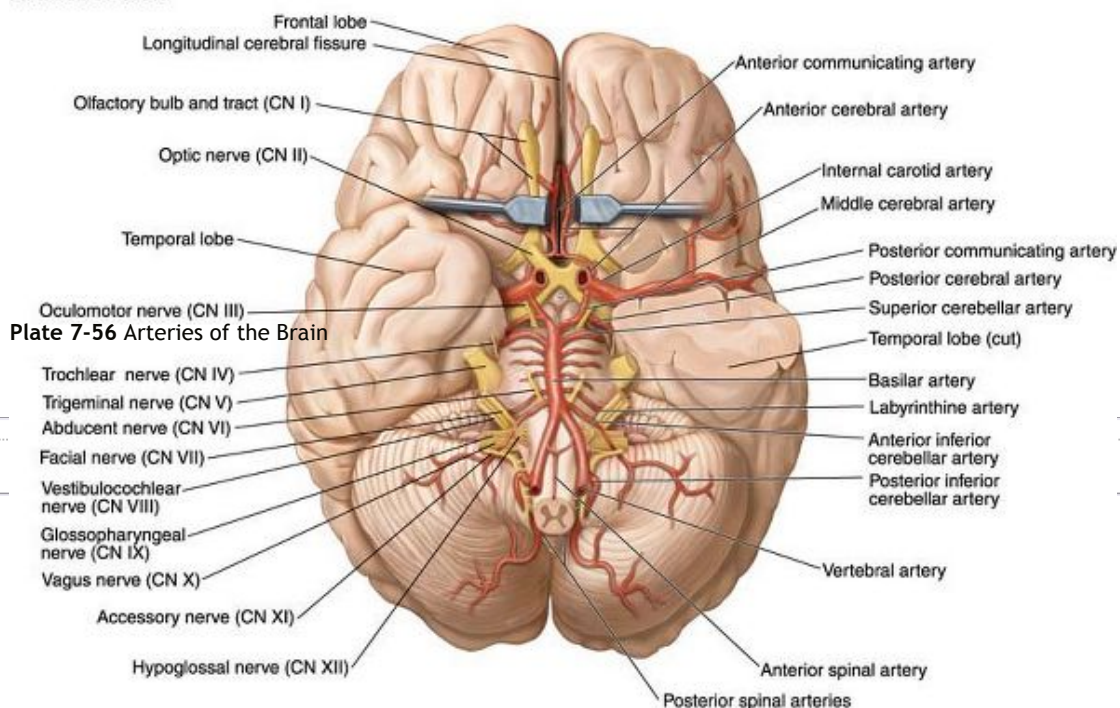
A. Anterior view



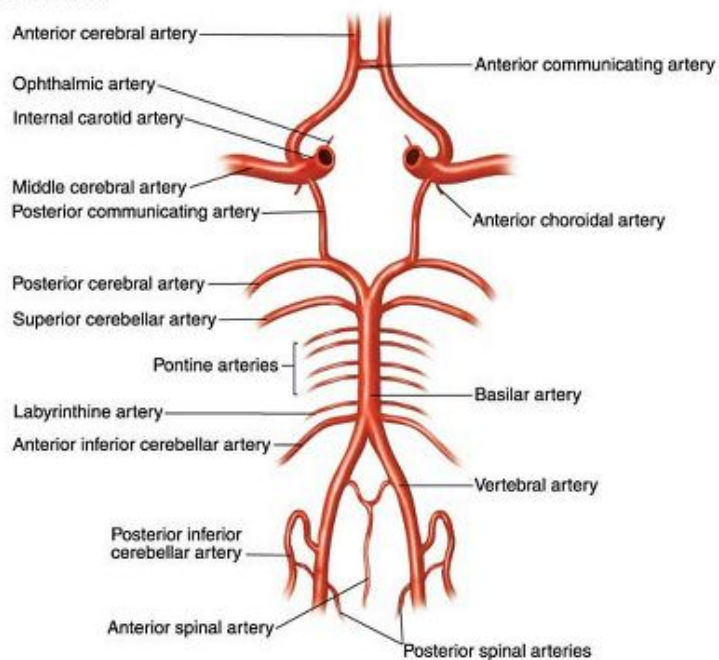
B. Posterior view



A. Inferior view



B. Schematic, inferior view



A. Surface projection

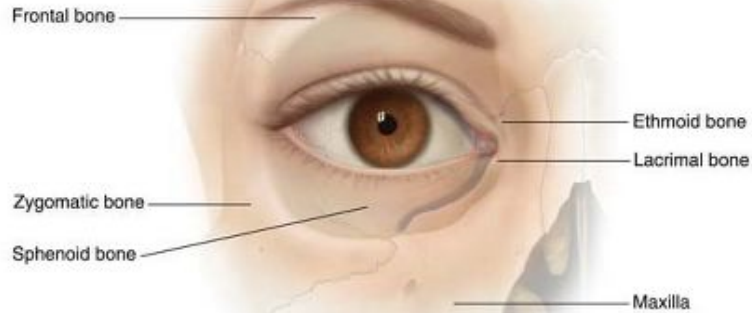
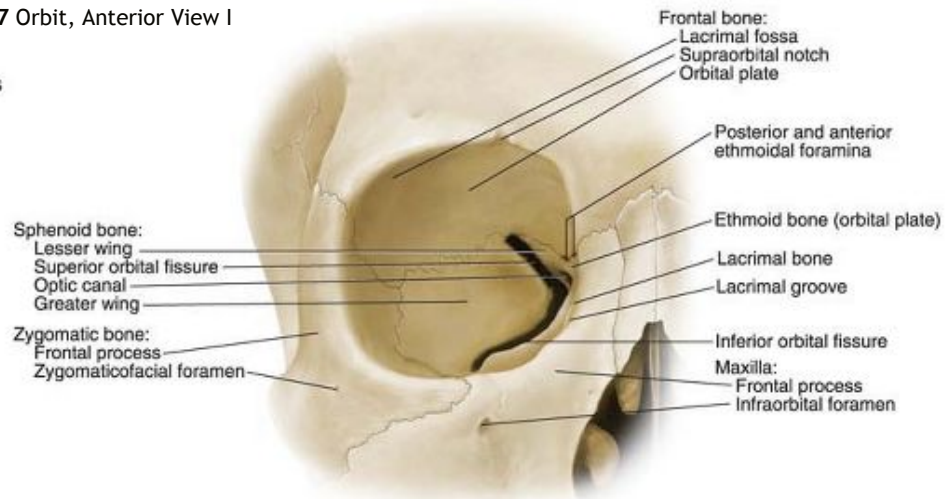
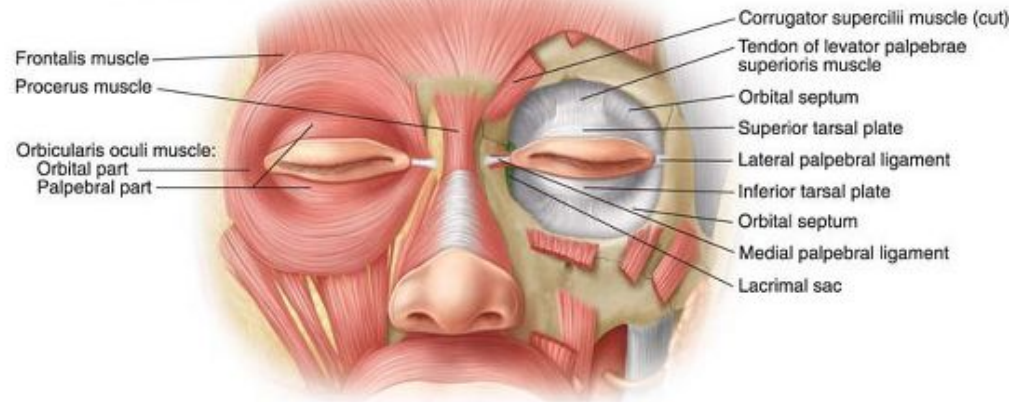


Plate 7-57 Orbit, Anterior View I

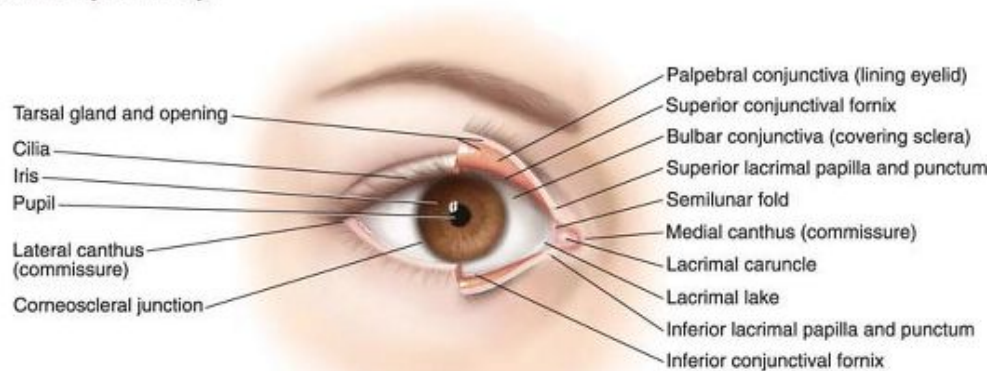
B. Bones



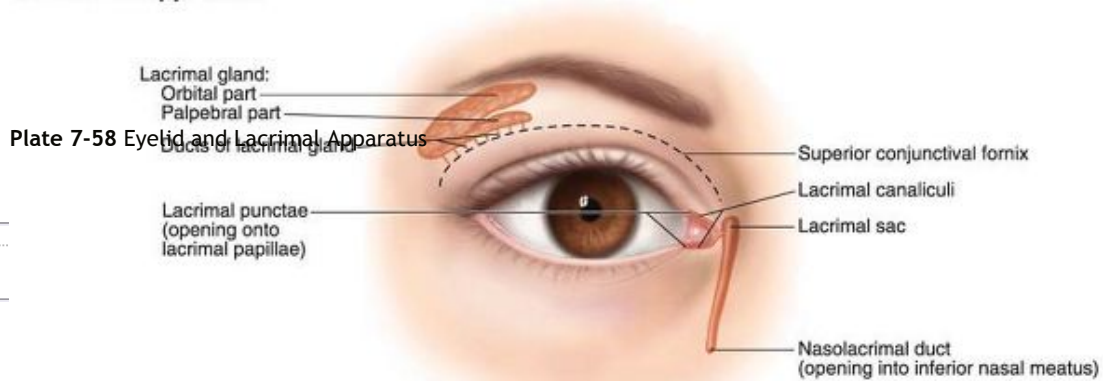
C. Muscles and orbital septum



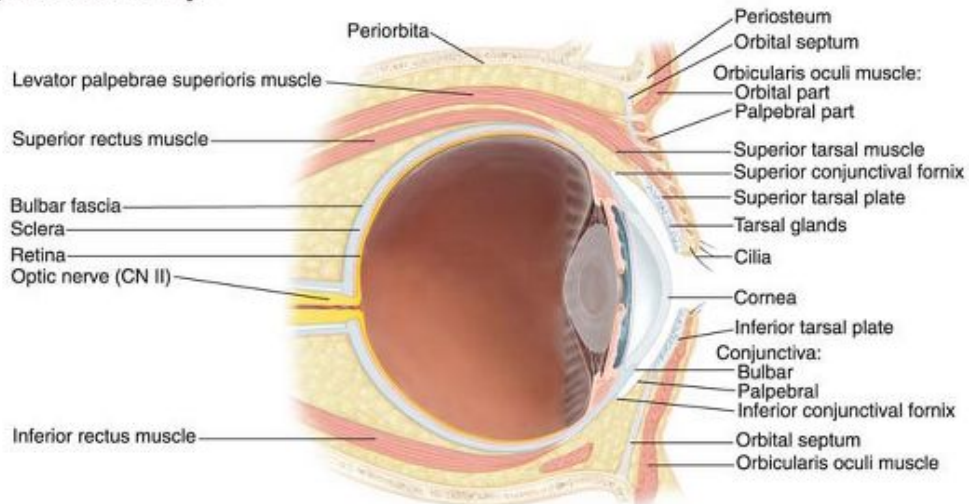
A. Surface anatomy of the eye



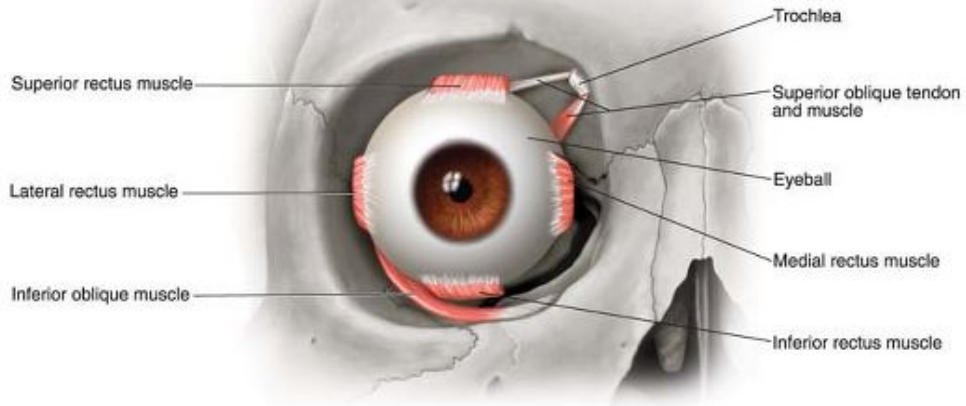
B. Lacrimal apparatus



C. Sagittal section of eye



A. Extraocular muscles



B. Coronal section

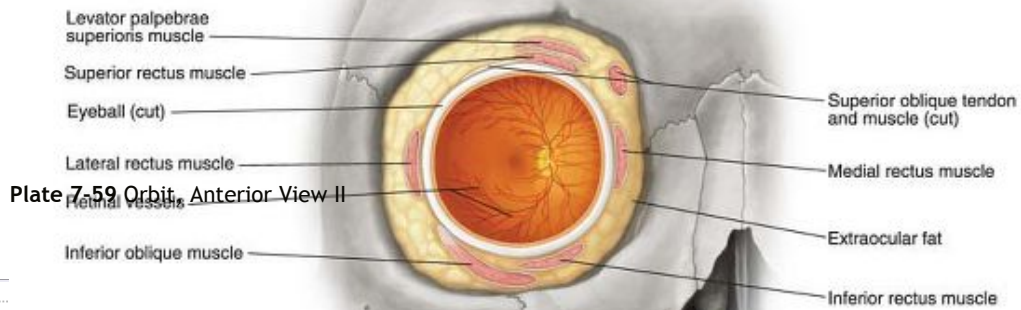
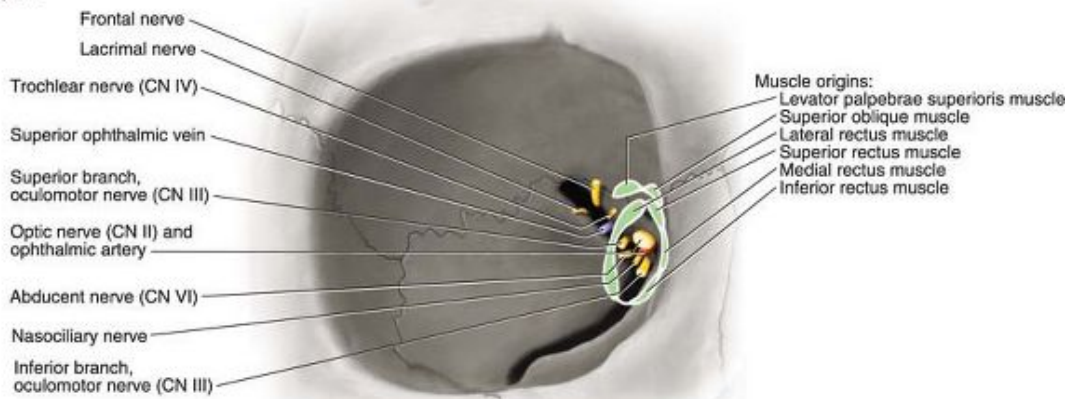
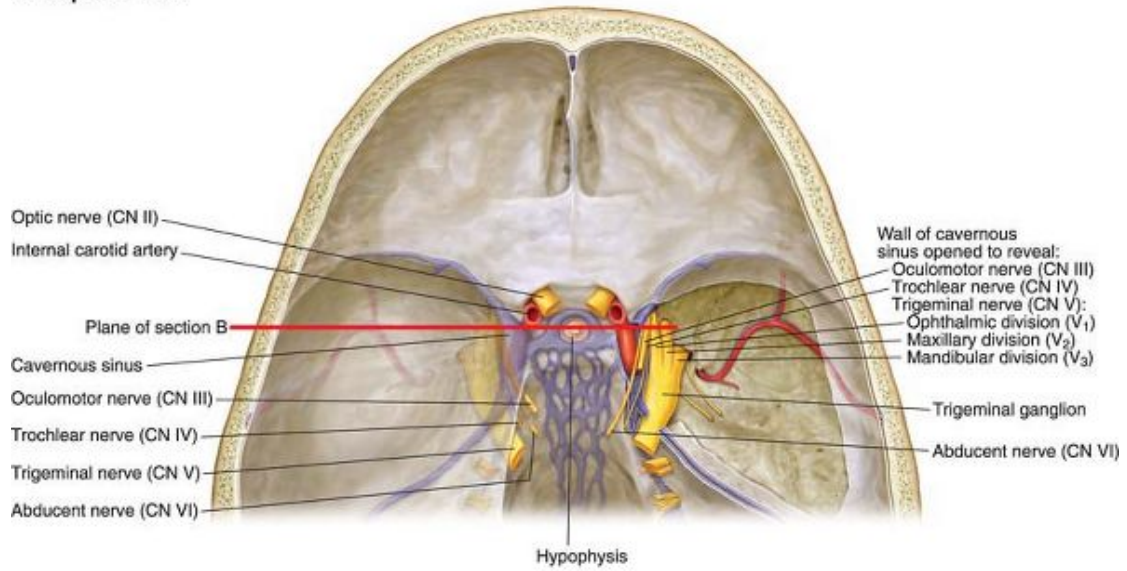


Plate 7-59 Orbit, Anterior View II

C. Apex



A. Superior view



B. Coronal section

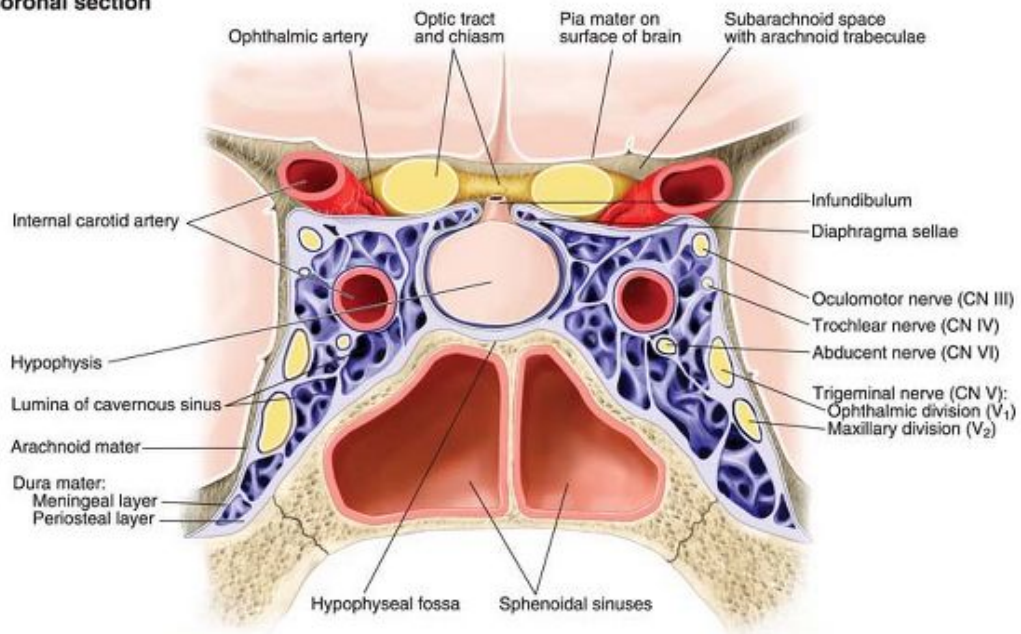


Plate 7-60 Cavernous Sinus

A. Layer I

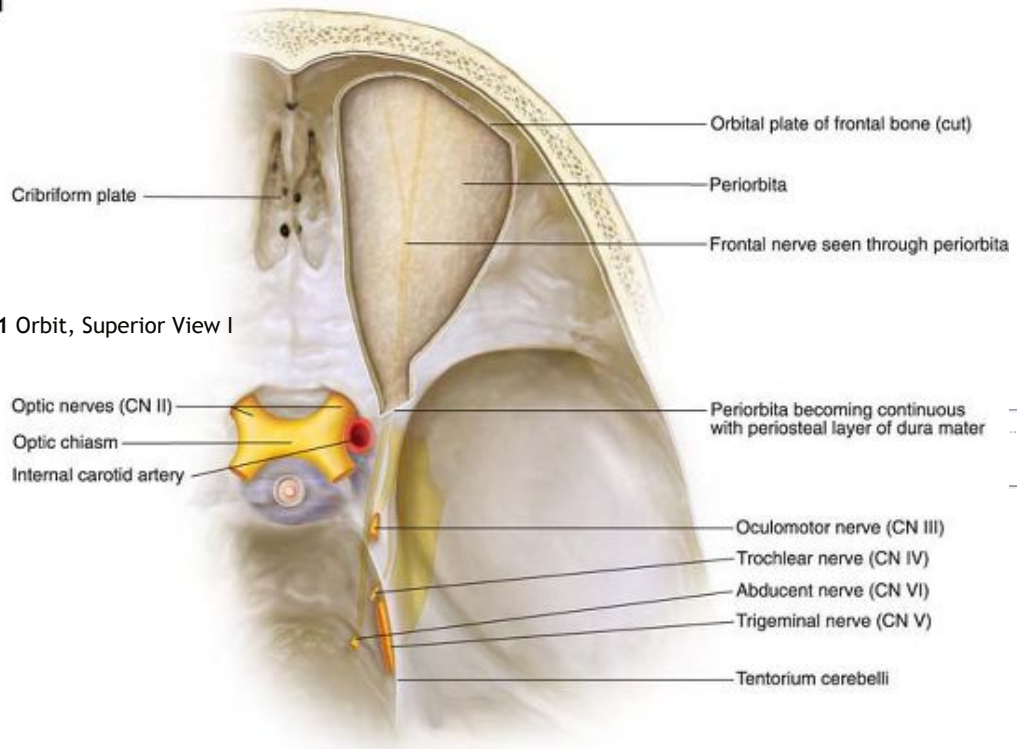
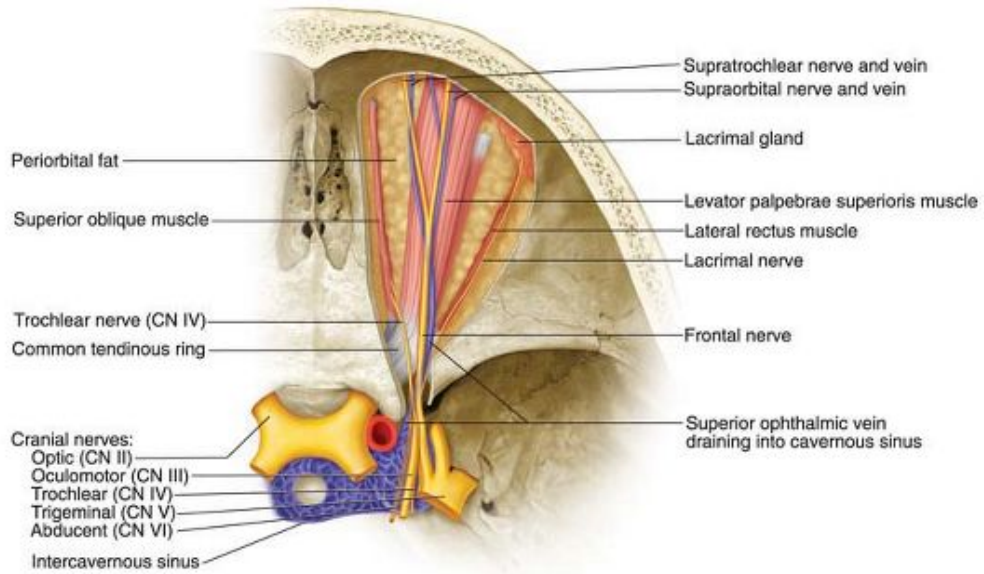
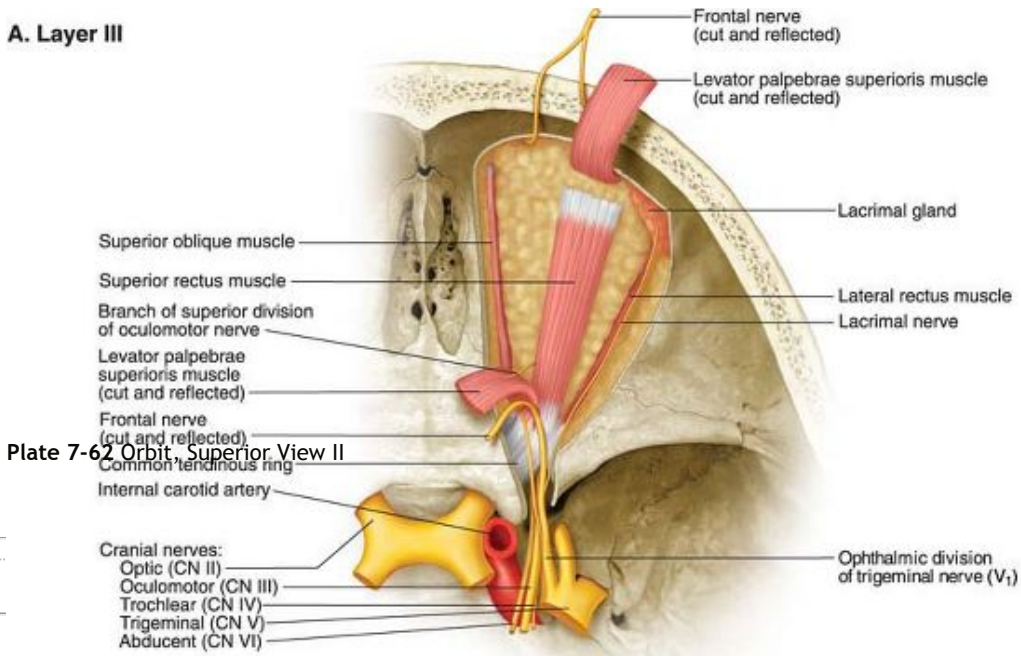


Plate 7-61 Orbit, Superior View I

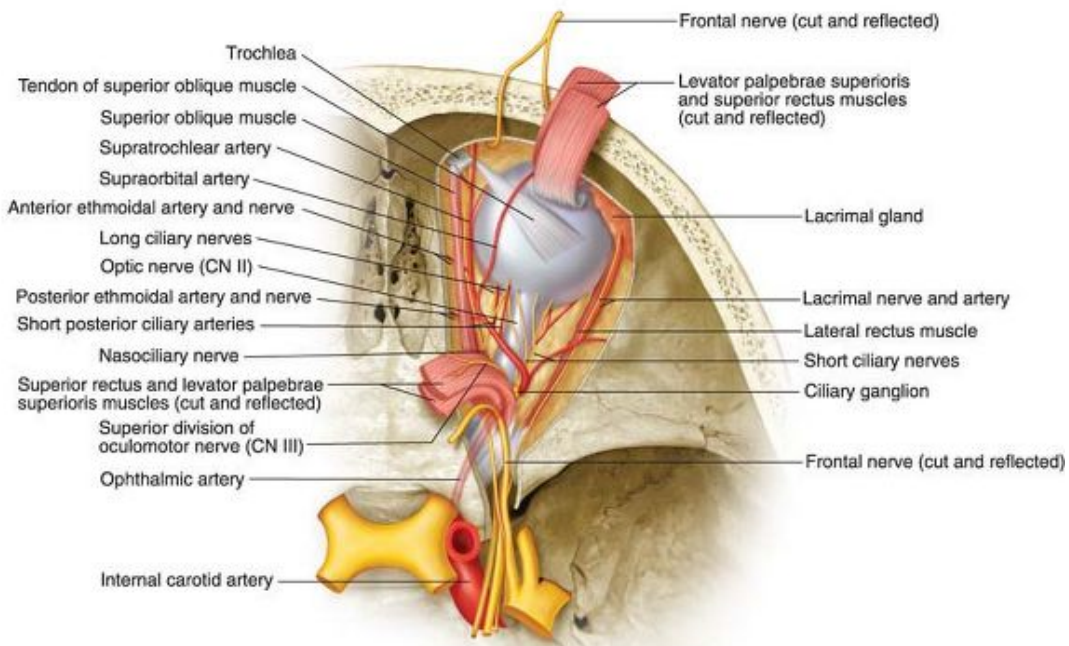
B. Layer II



A. Layer III



B. Layer IV



A. Layer V

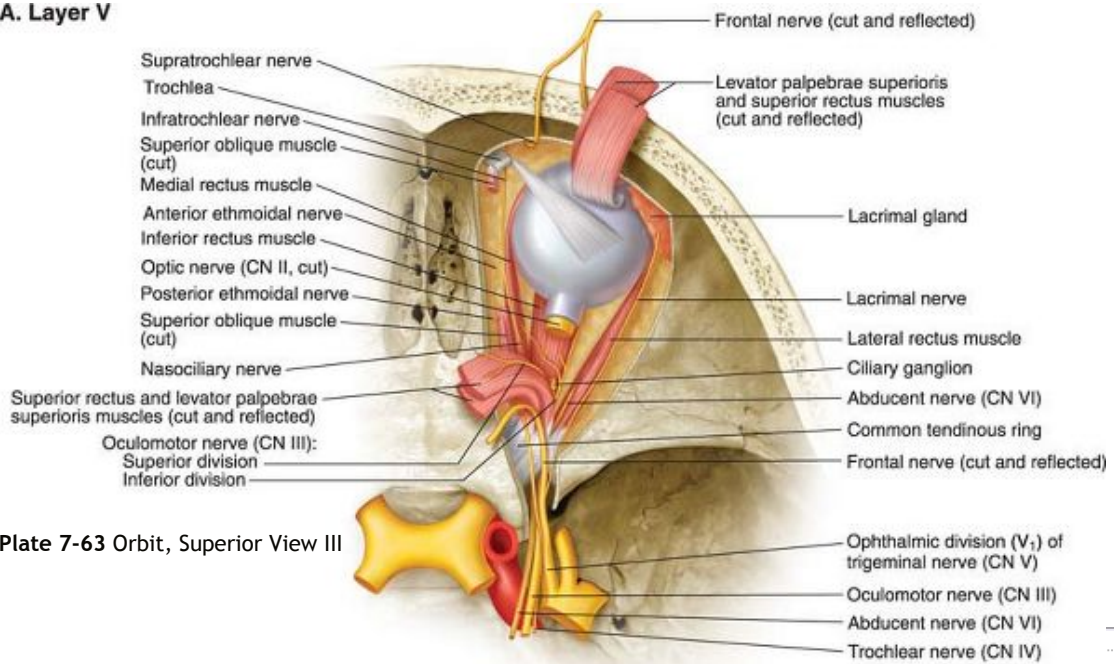
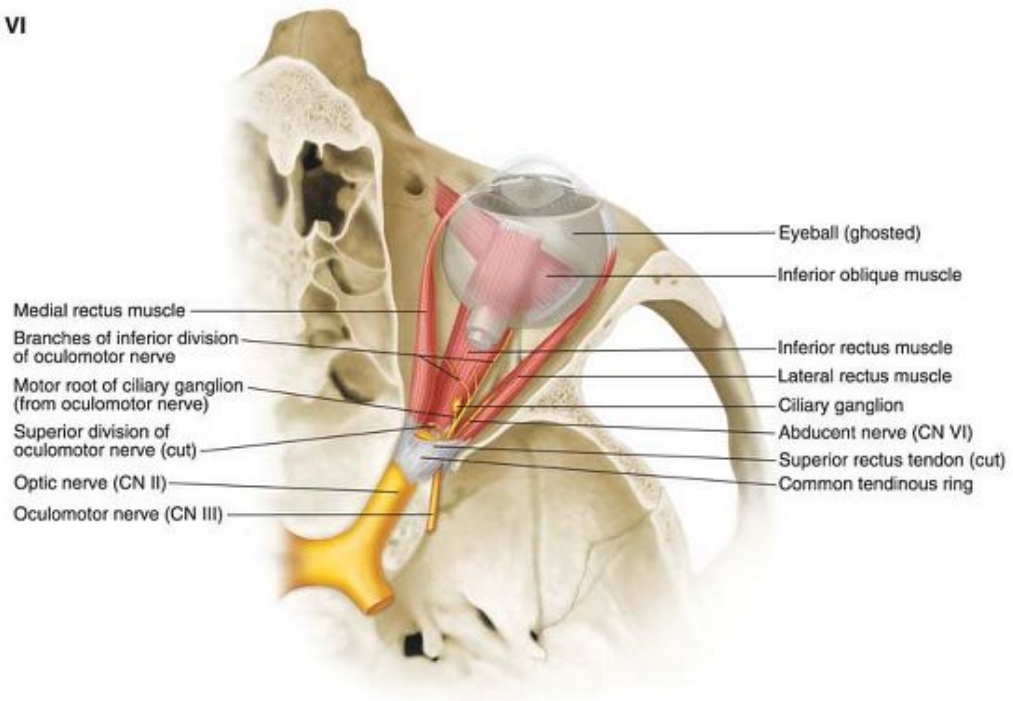
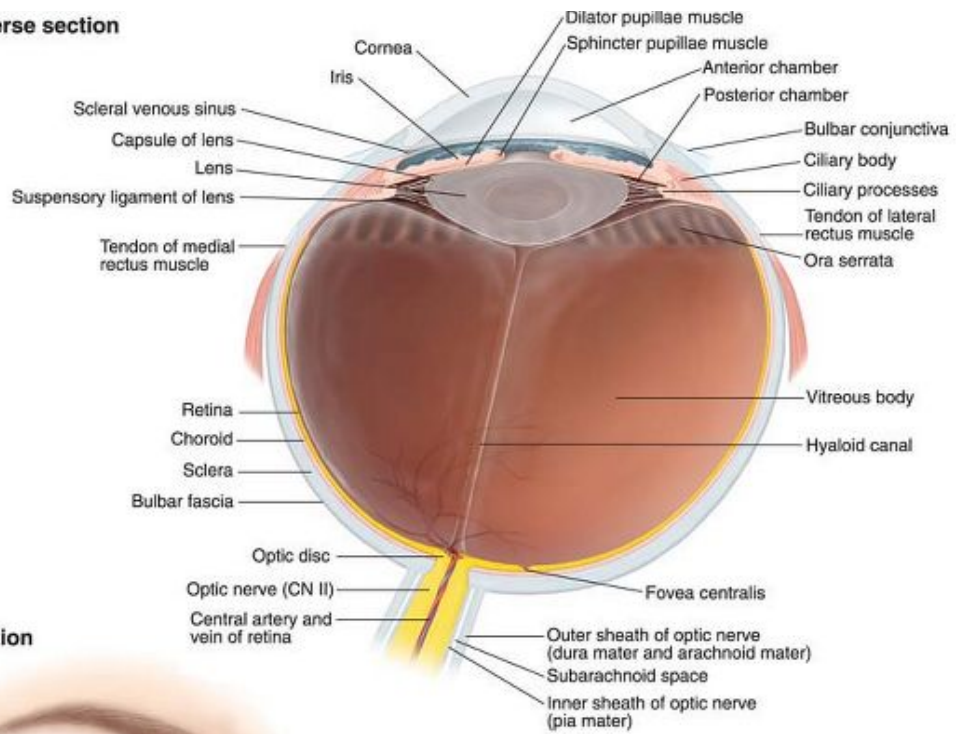


Plate 7-63 Orbit, Superior View III

B. Layer VI



A. Transverse section

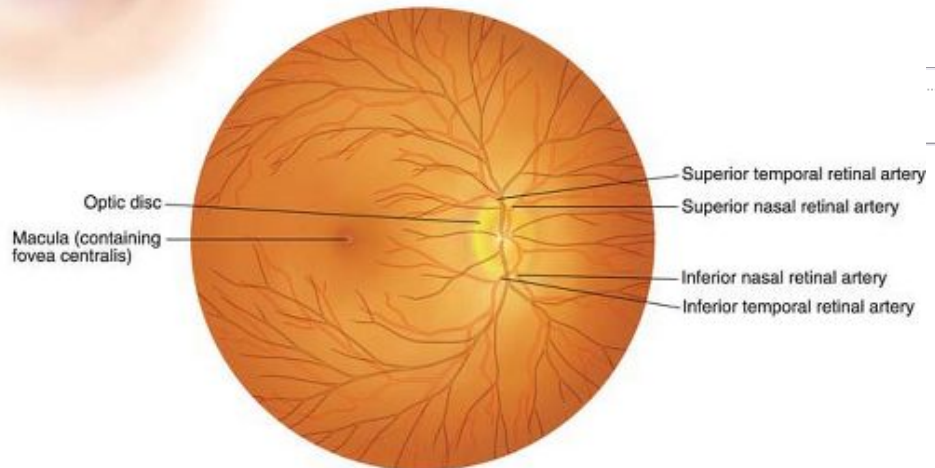


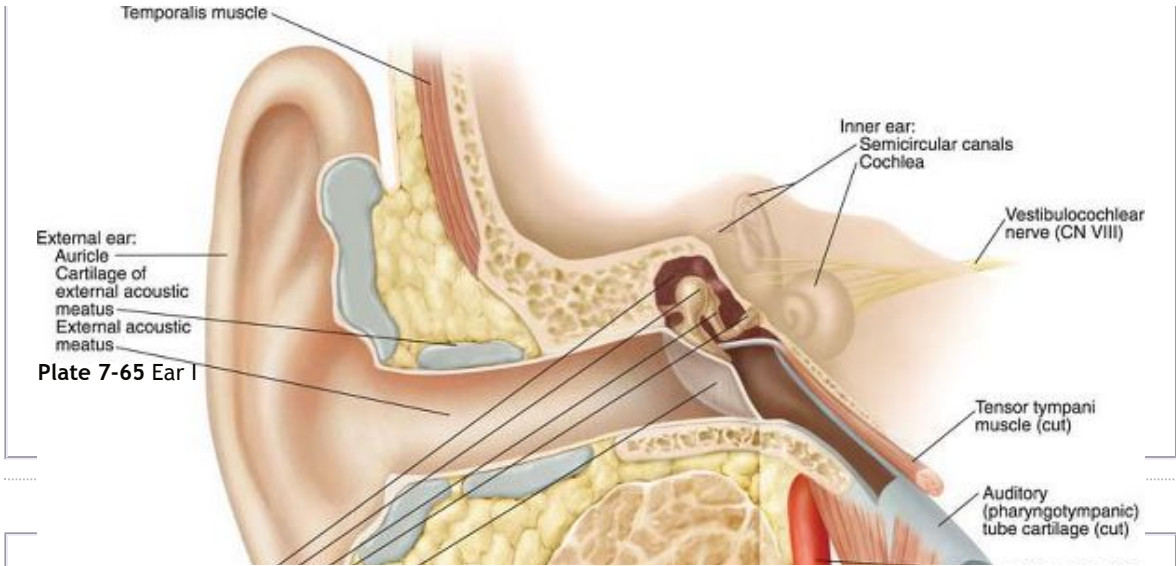
B. Orientation

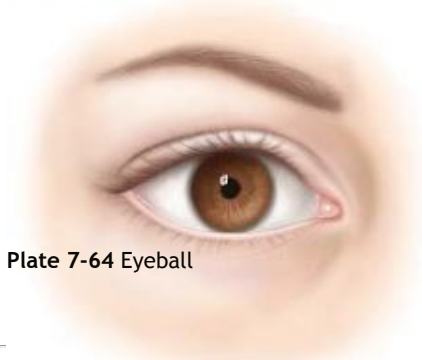

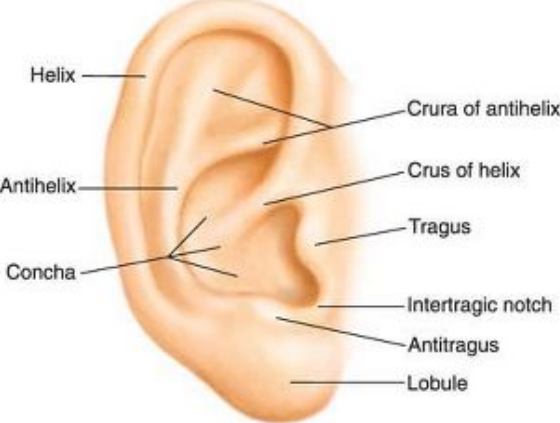
Plate 7-64 Eyeball

C. Vessels of the retina

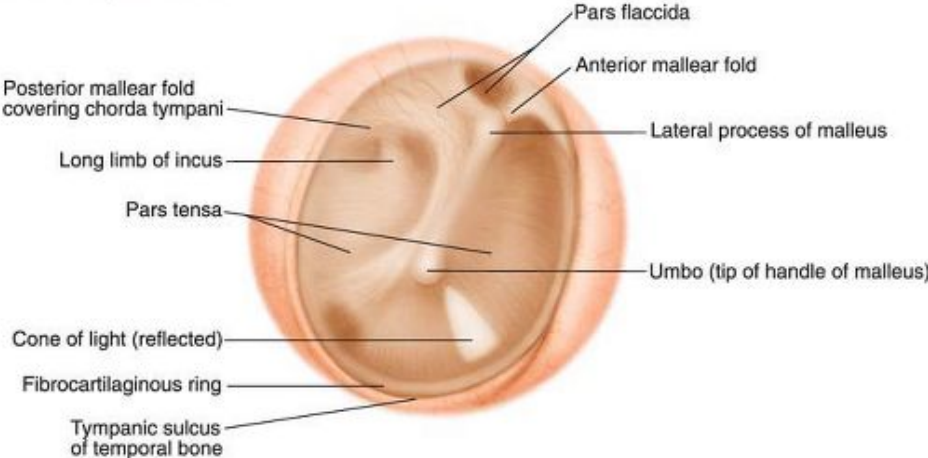




A. Auricle



B. Tympanic membrane, lateral view



C. Ossicles of ear seen through tympanic membrane



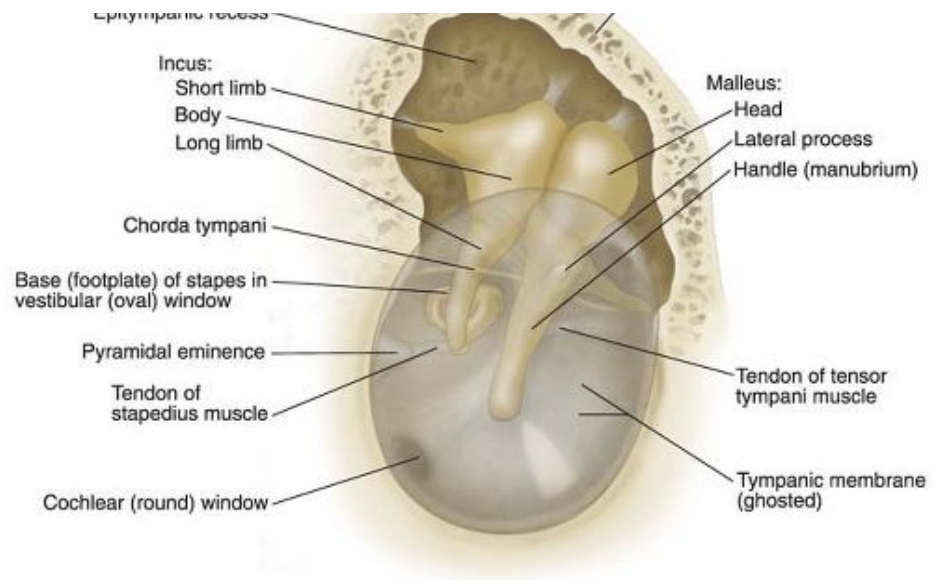
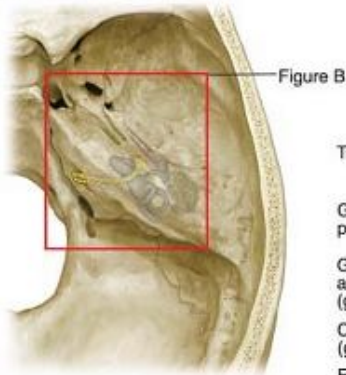
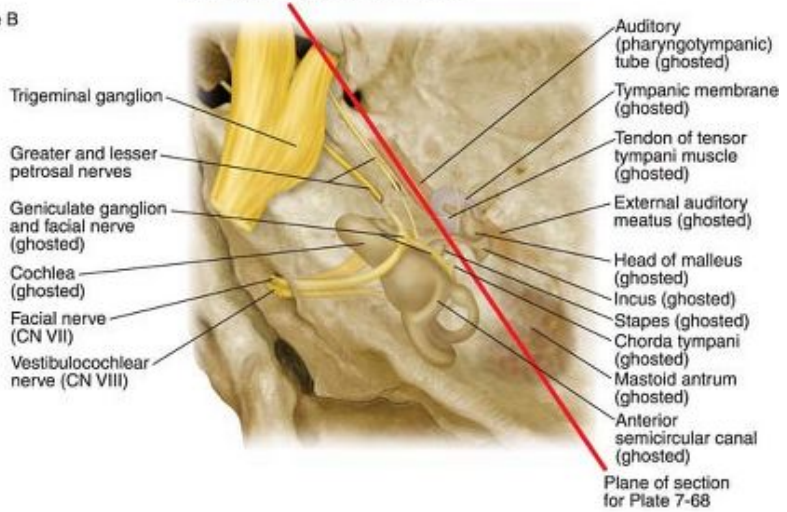


Plate 7-66 Ear II

A. Orientation



B. Right ear, superior view



C. Right ear, inferior view

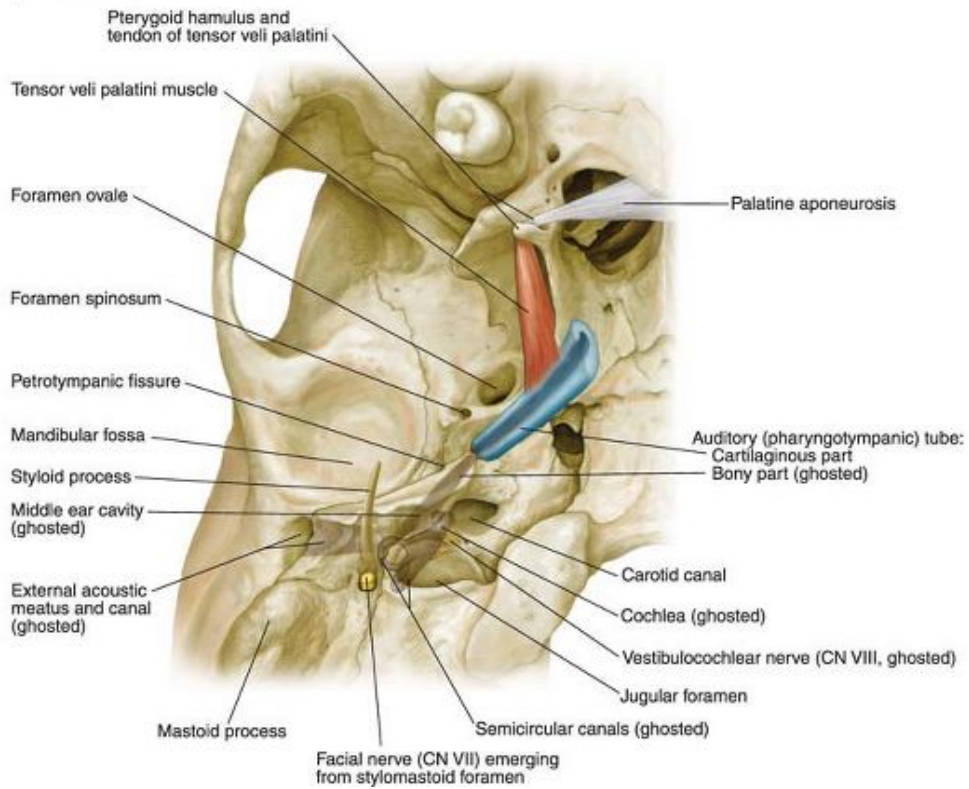


Plate 7-67 Ear III

P.363

A. Lateral wall of middle ear, right

Plate 7-68 Ear IV

Semicanal for tensor tympani muscle

Auditory (pharyngotympanic) tube, bony part

Handle (manubrium) of malleus

Internal carotid artery (cut)

B. Medial wall of middle ear, right

Prominence of lateral semicircular canal

Base (footplate) of stapes within vestibular (oval) window

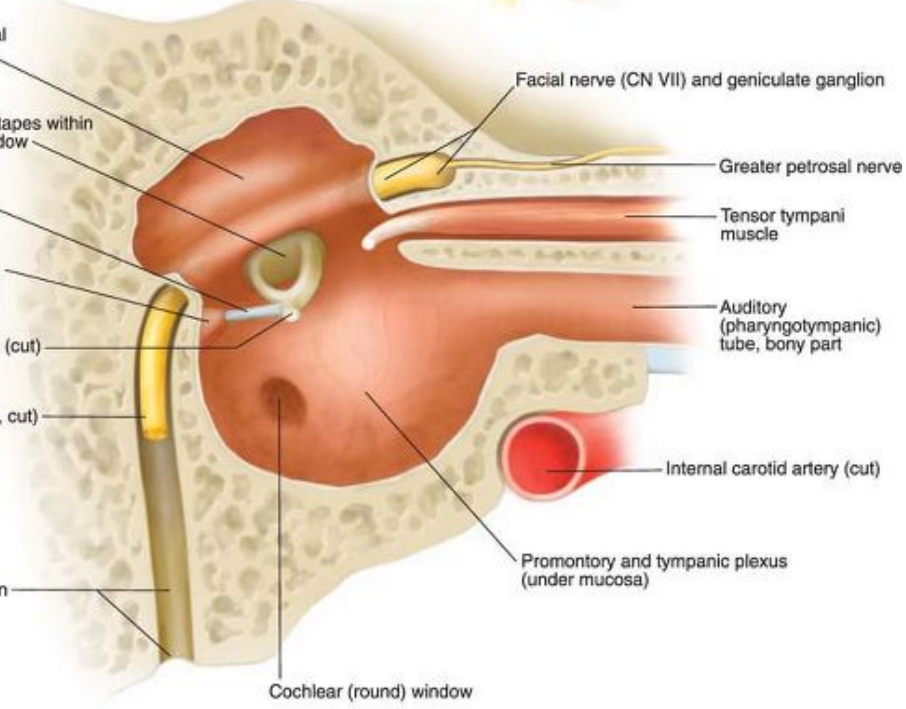
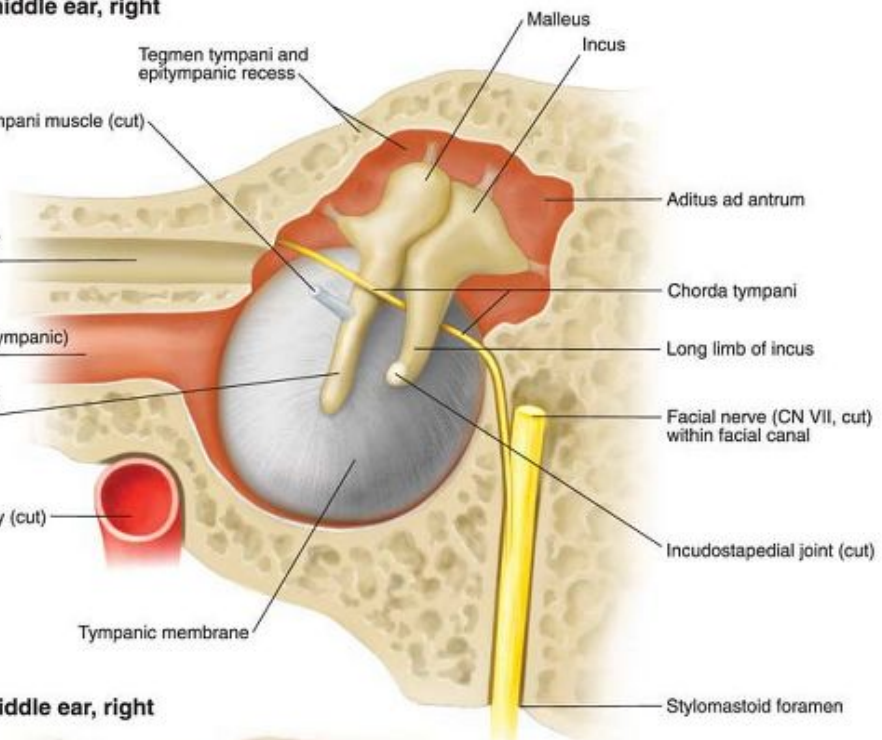
Tendon of stapedius muscle

Pyramidal eminence

Incudostapedial joint (cut)

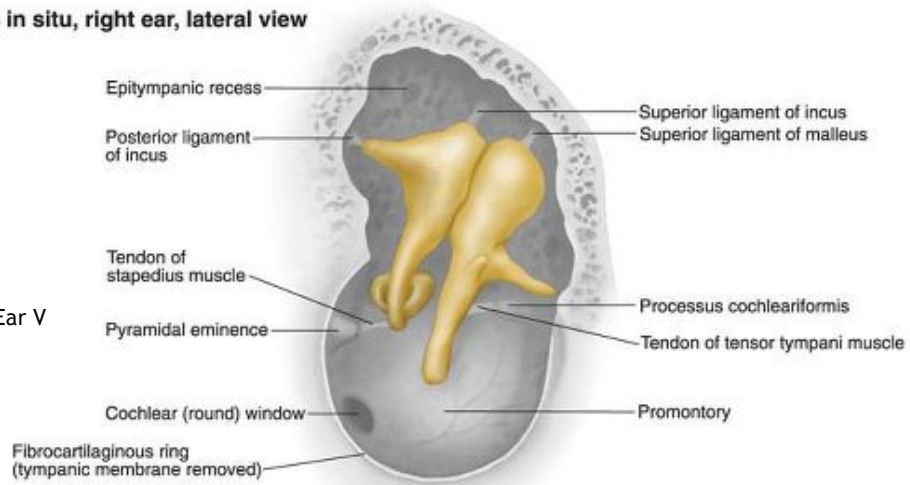
Facial nerve (CN VII, cut)

Facial canal and stylomastoid foramen

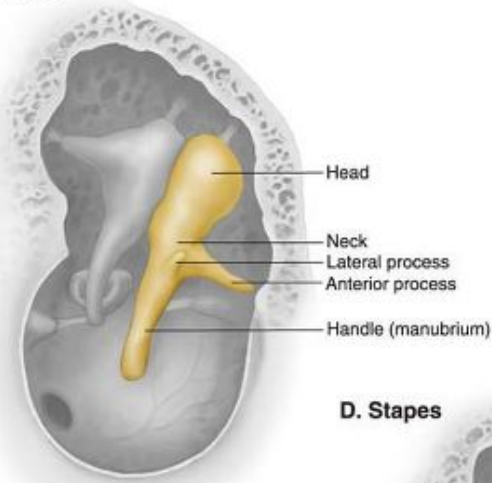


A. Ossicles in situ, right ear, lateral view

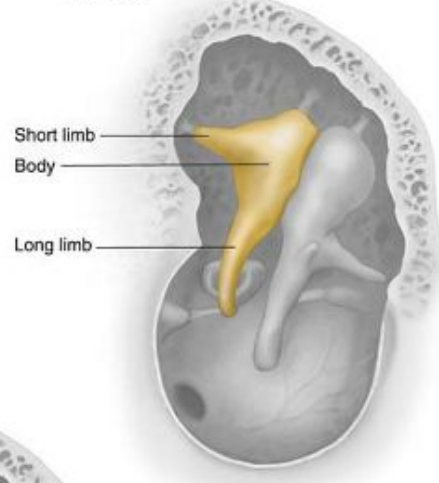
Plate 7-69 Ear V



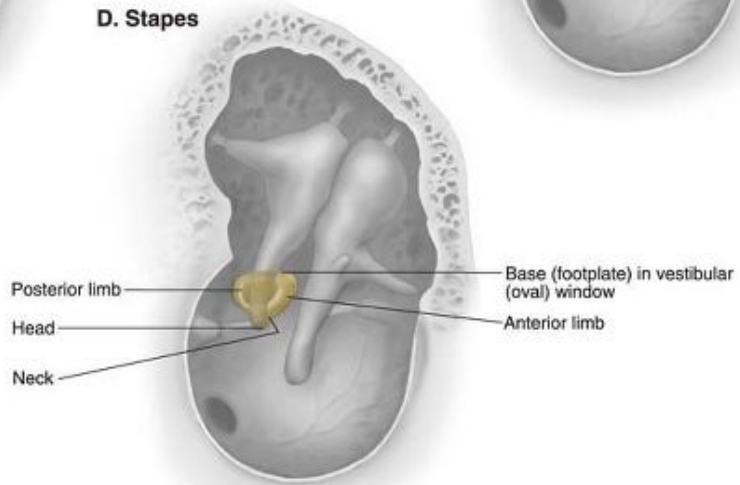
B. Malleus



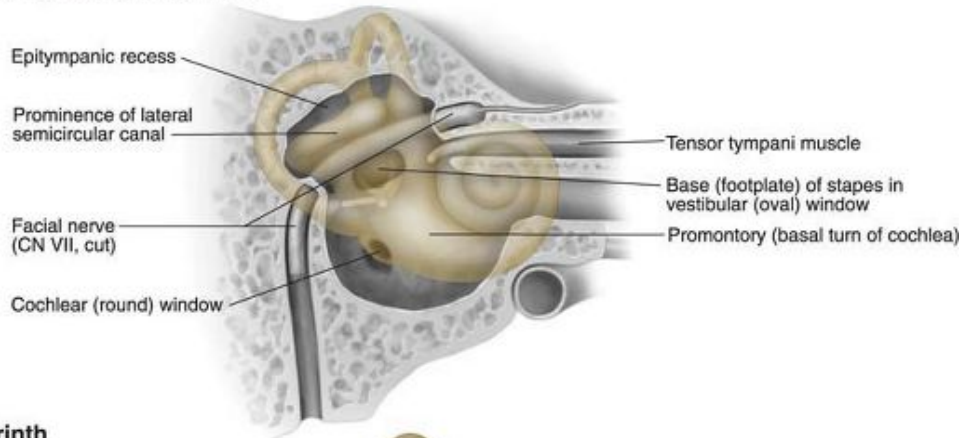
C. Incus



D. Stapes

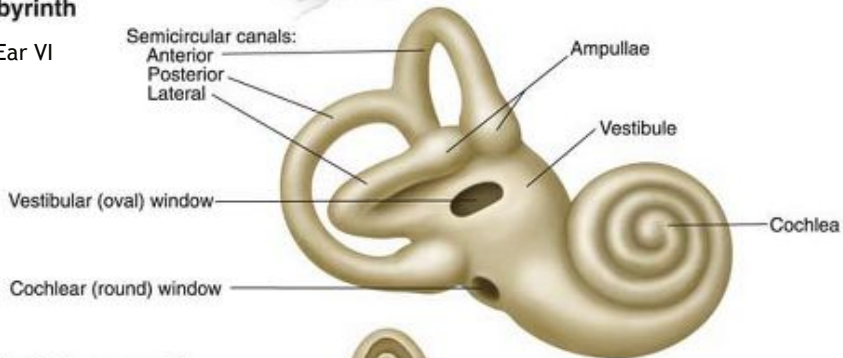


A. Orientation, right ear, lateral view



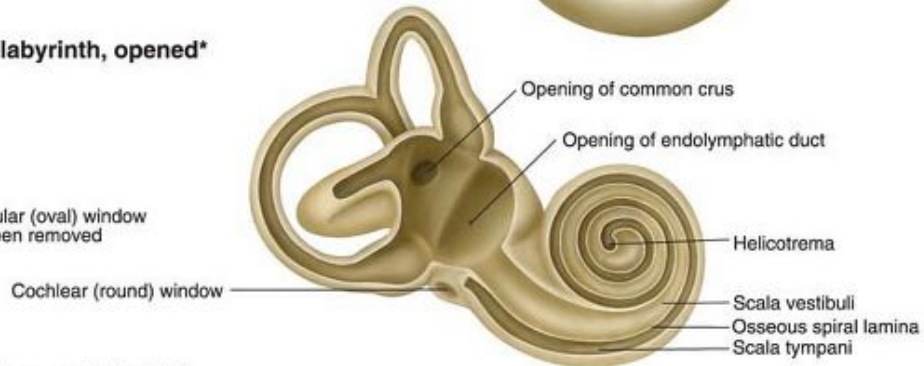
B. Bony labyrinth

Plate 7-70 Ear VI

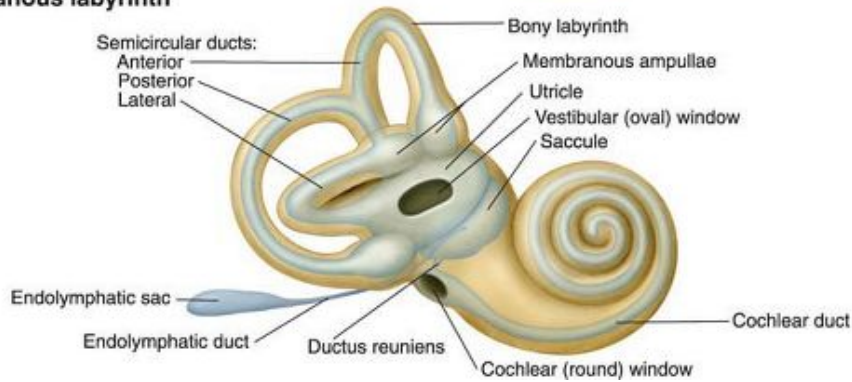


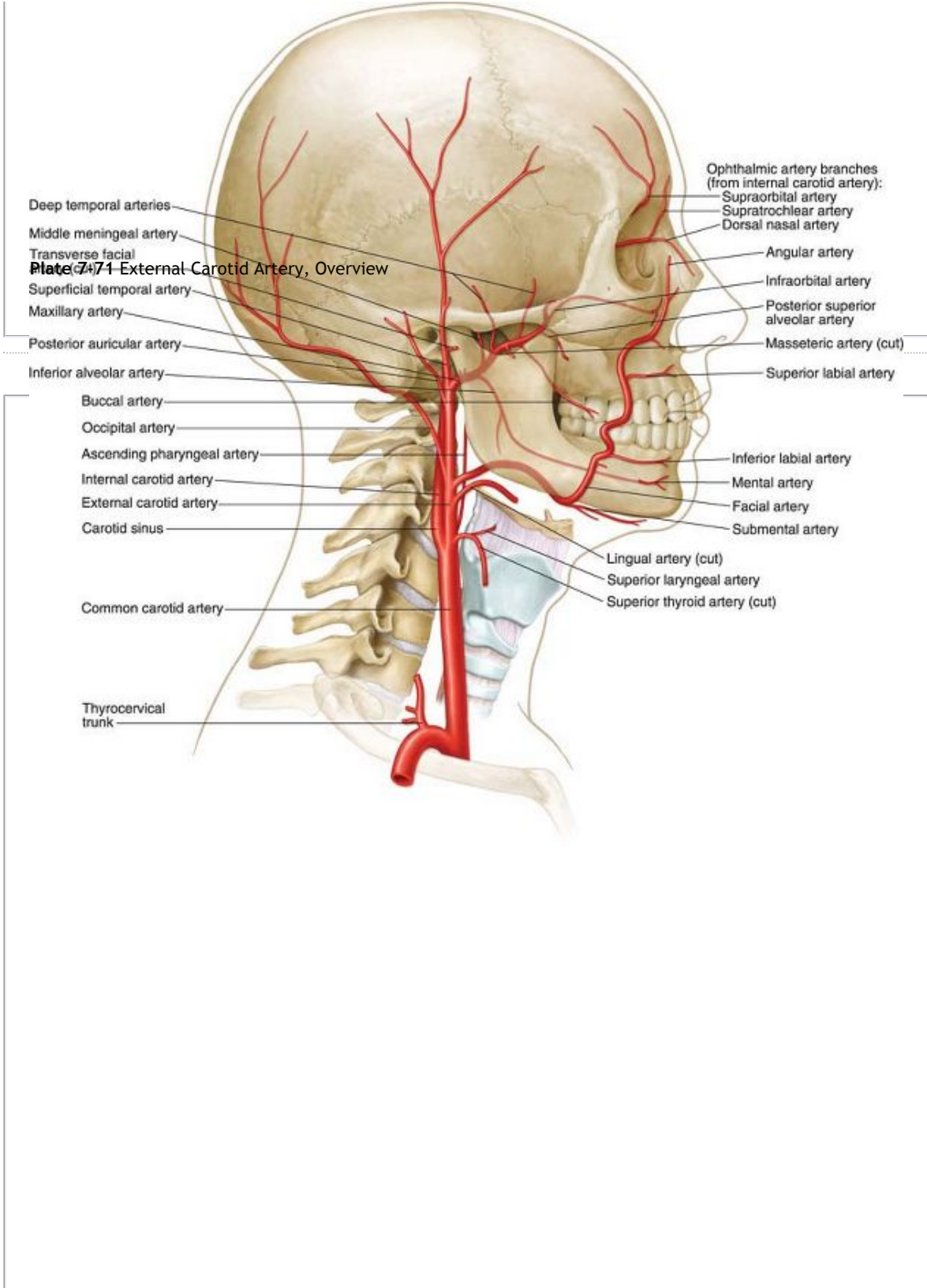
C. Bony labyrinth, opened*

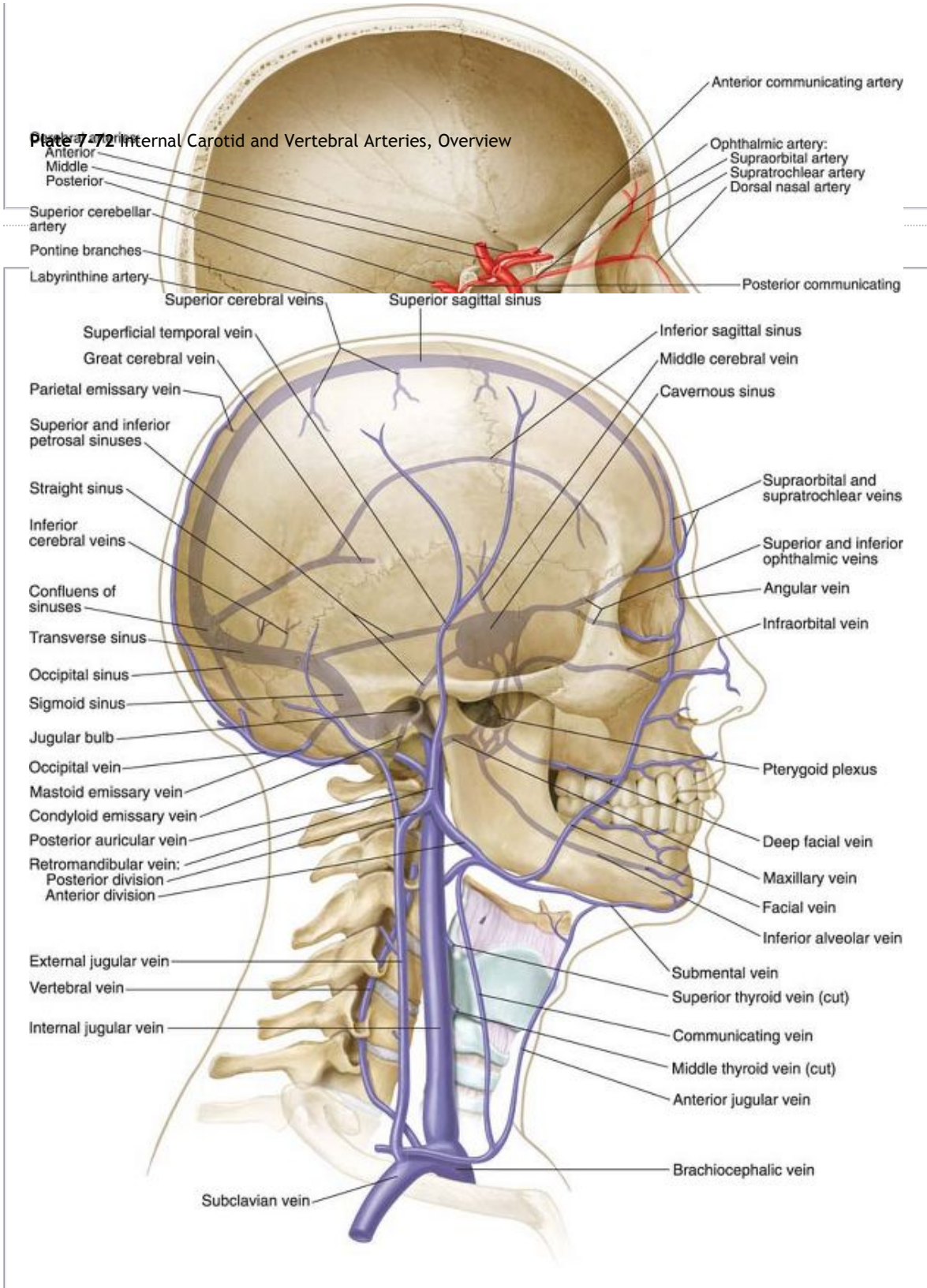
*Vestibular (oval) window has been removed



D. Membranous labyrinth







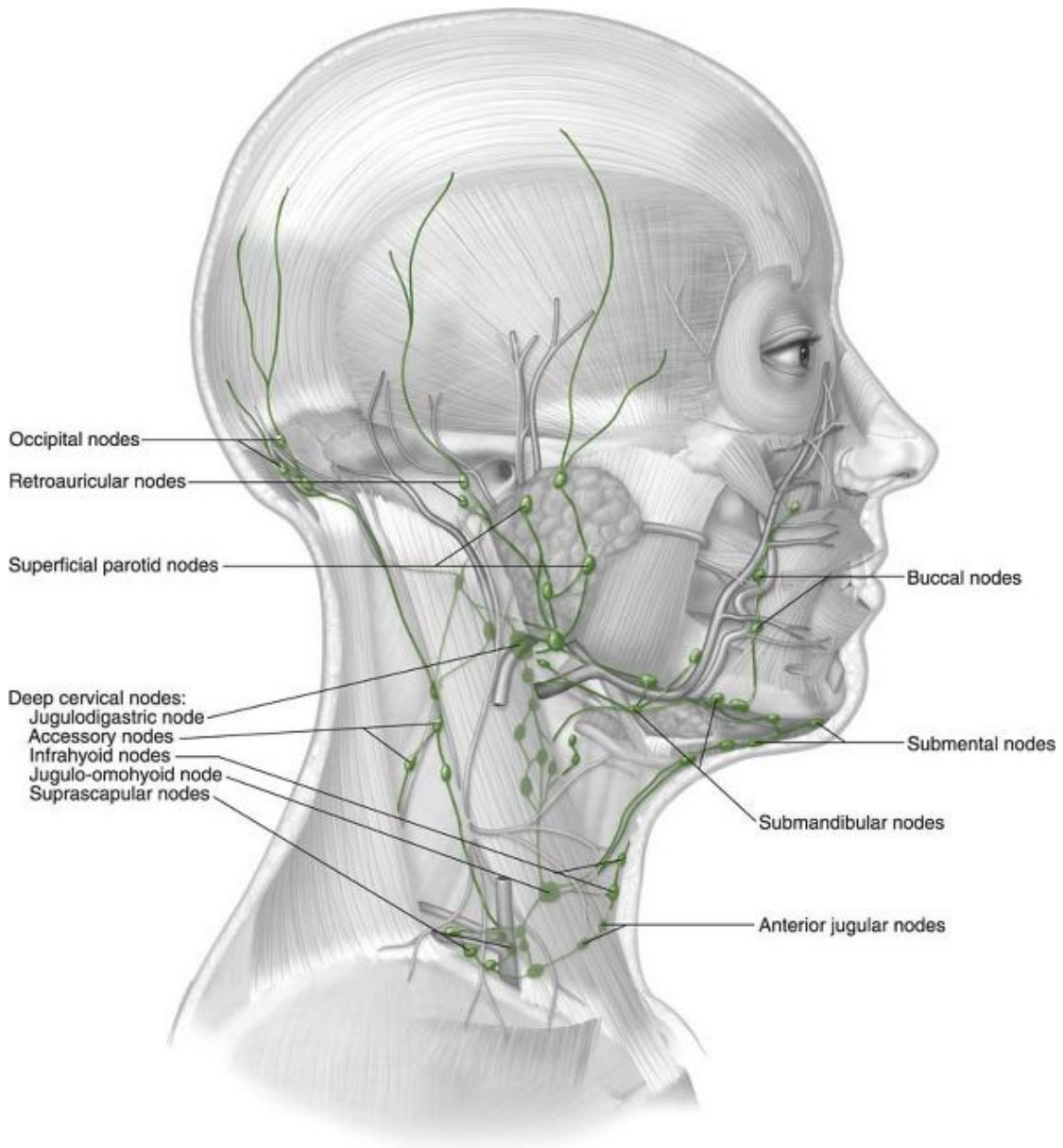


Plate 7-74 Lymphatics of the Head and Neck

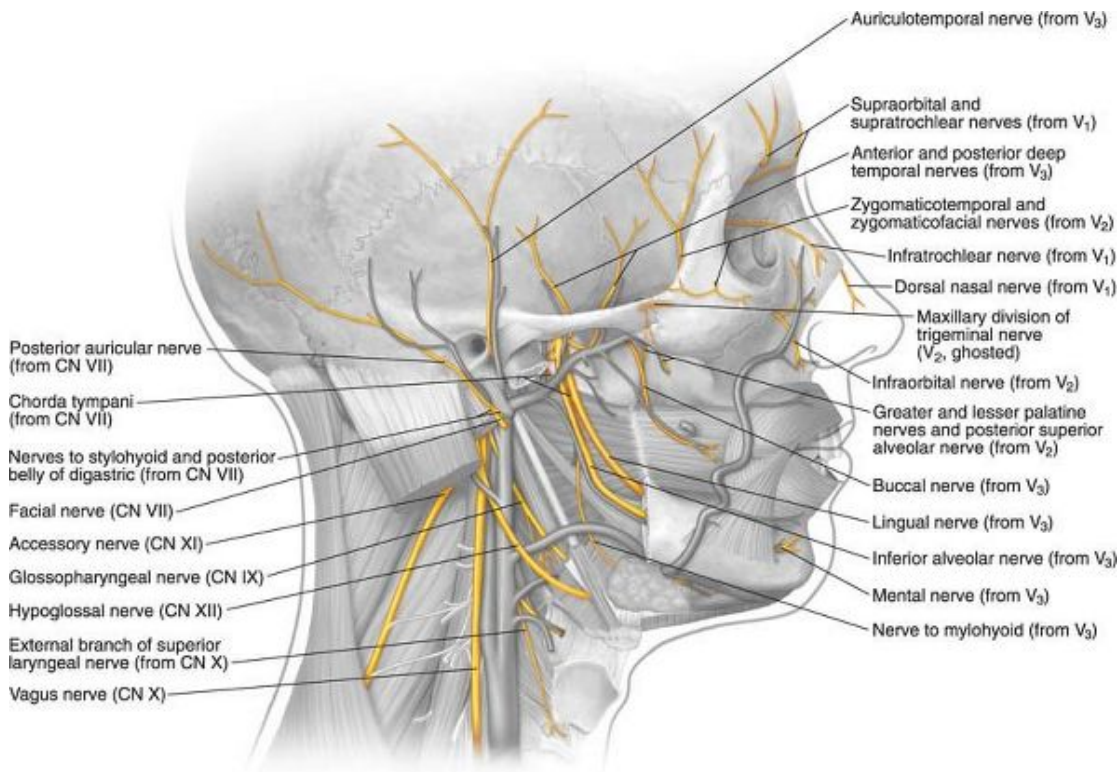


Plate 7-75 Cranial Nerve Summary I

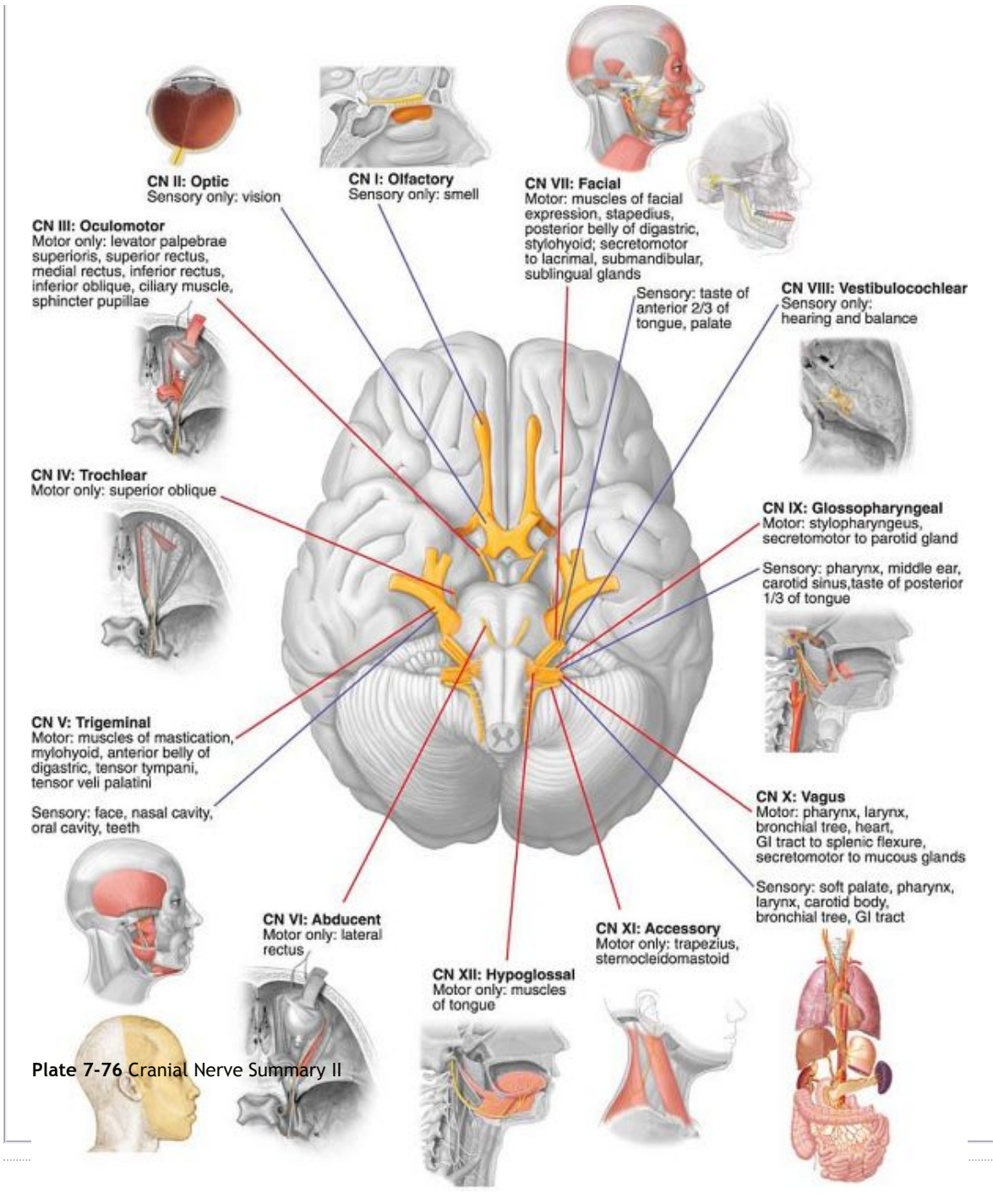
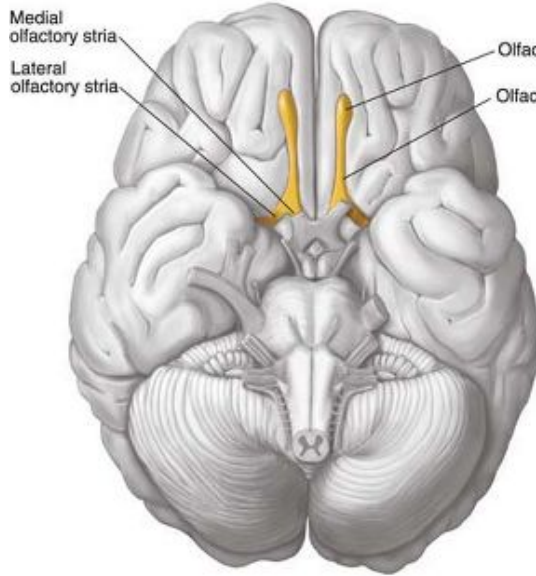
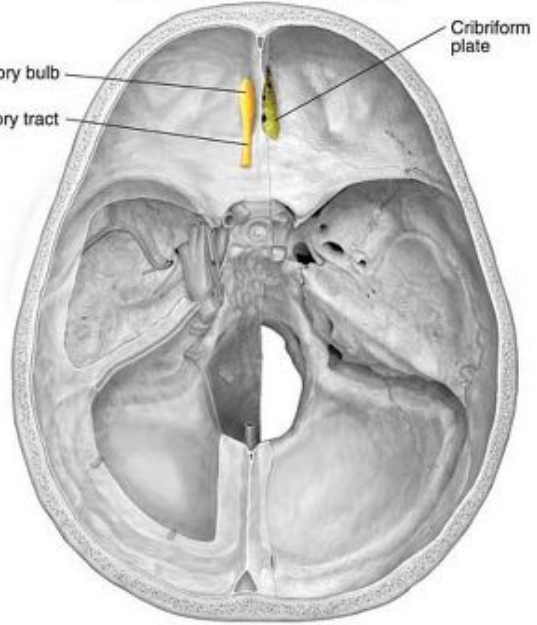


Plate 7-76 Cranial Nerve Summary II

A. Origin from brain



B. Exit from cranial cavity



C. Sensory innervation, sagittal section

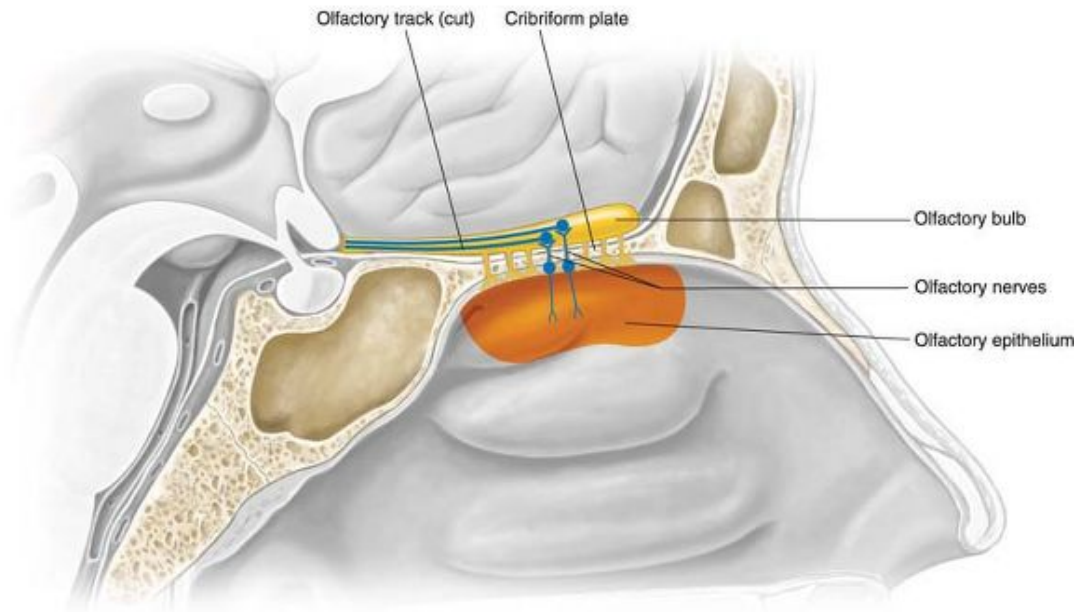
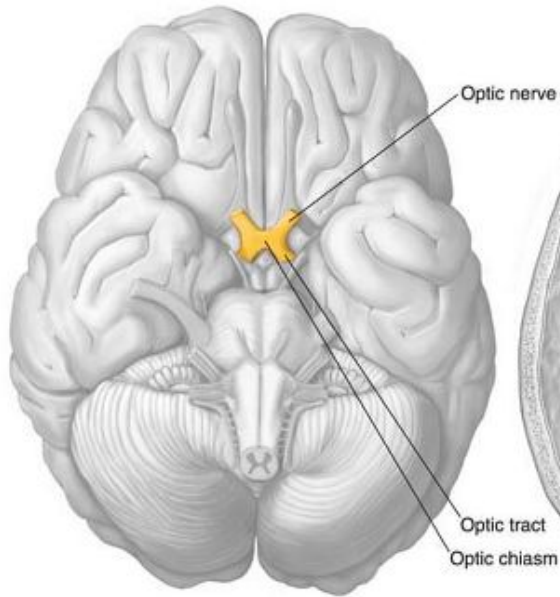
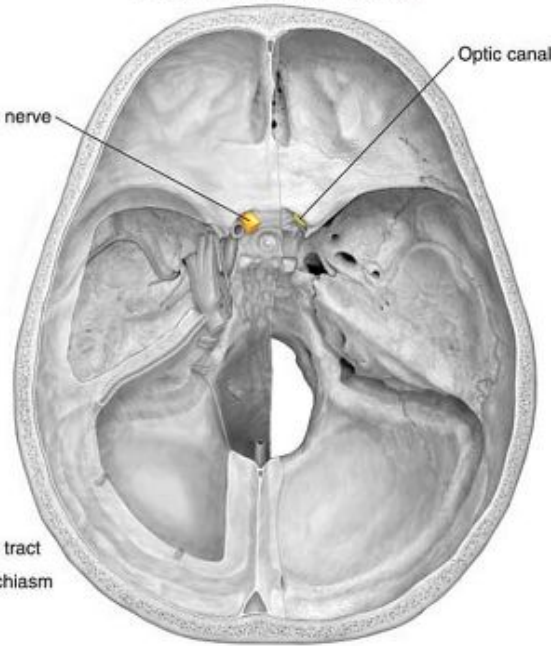


Plate 7-77 Olfactory Nerve, Cranial Nerve I

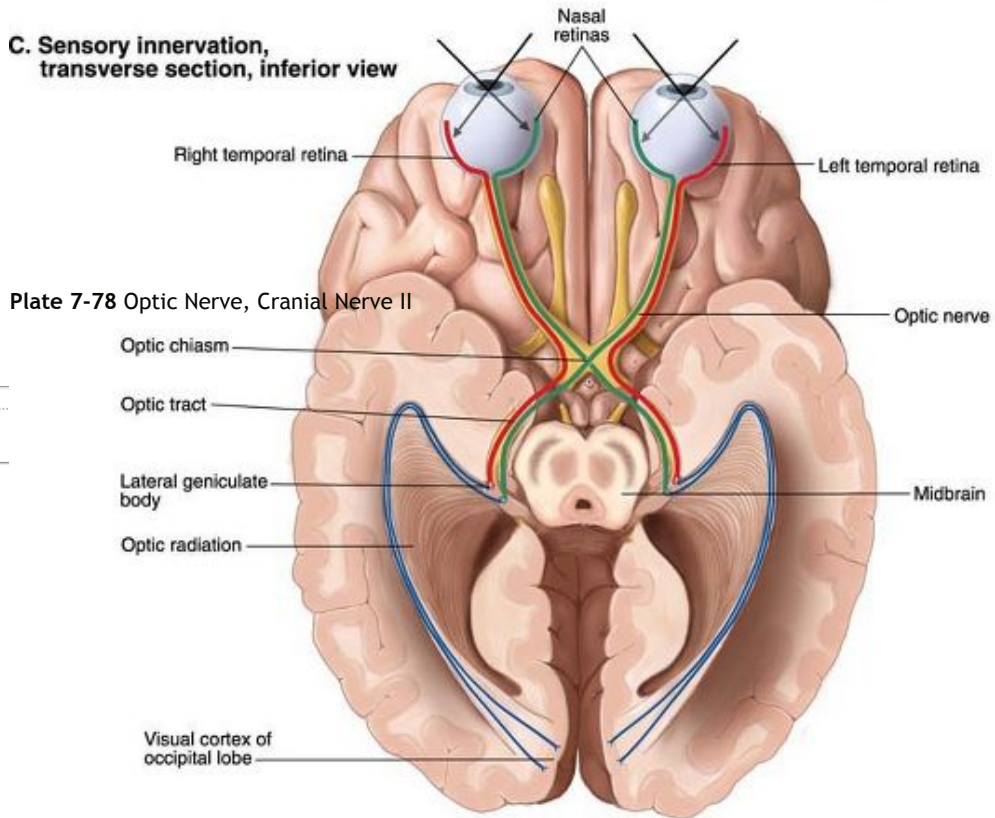
A. Origin from brain



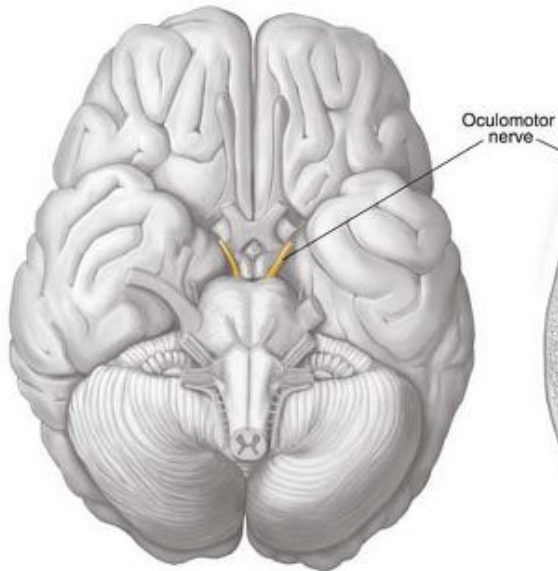
B. Exit from cranial cavity



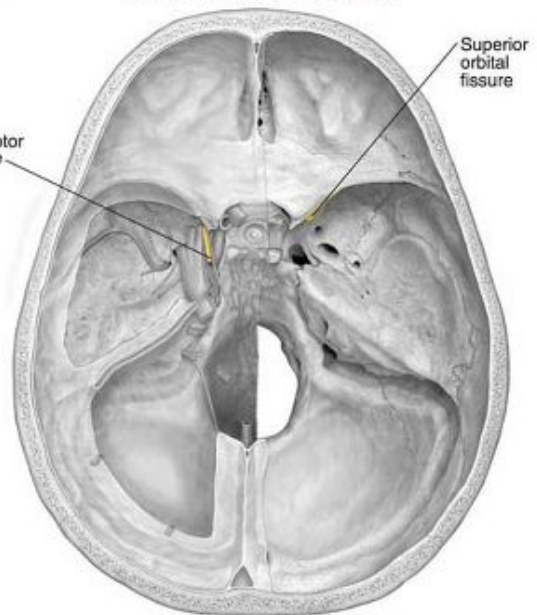
C. Sensory innervation, transverse section, inferior view



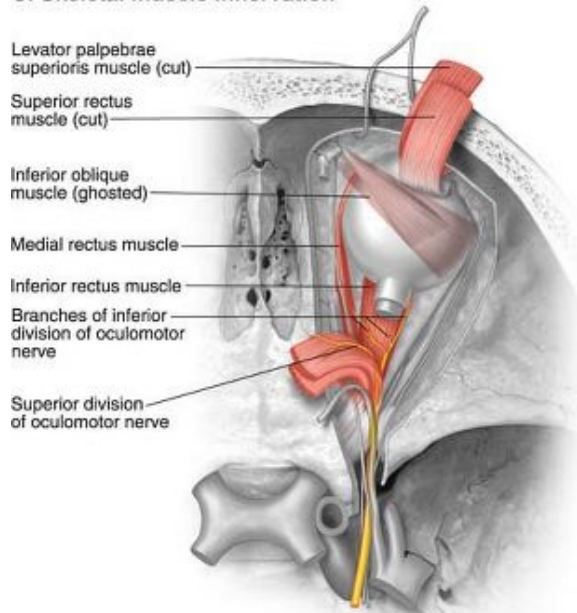
A. Origin from brain



B. Exit from cranial cavity



C. Skeletal muscle innervation



D. Parasympathetic innervation

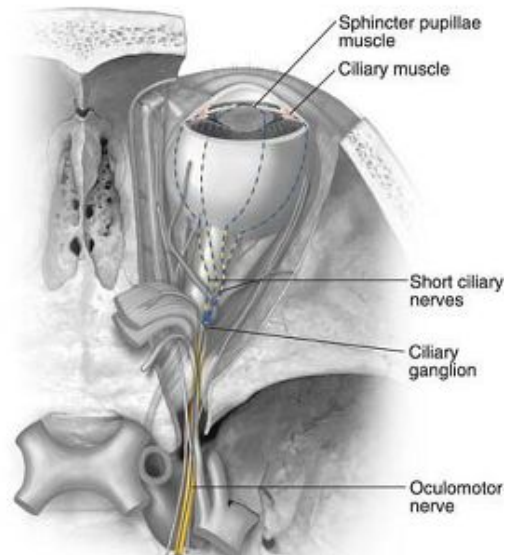
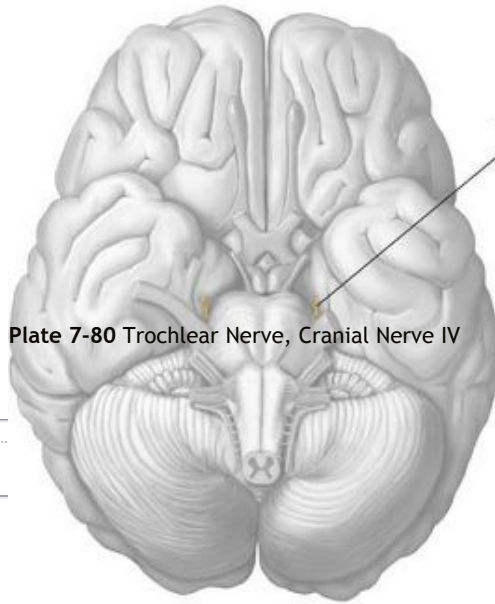


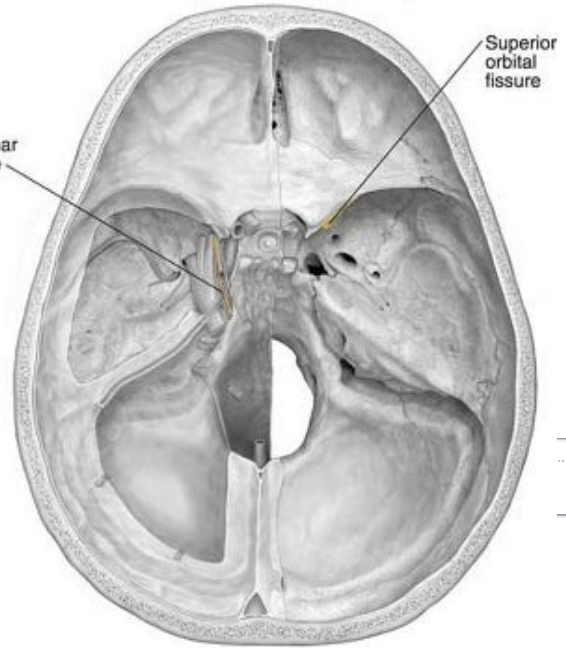
Plate 7-79 Oculomotor Nerve, Cranial Nerve III

P.375

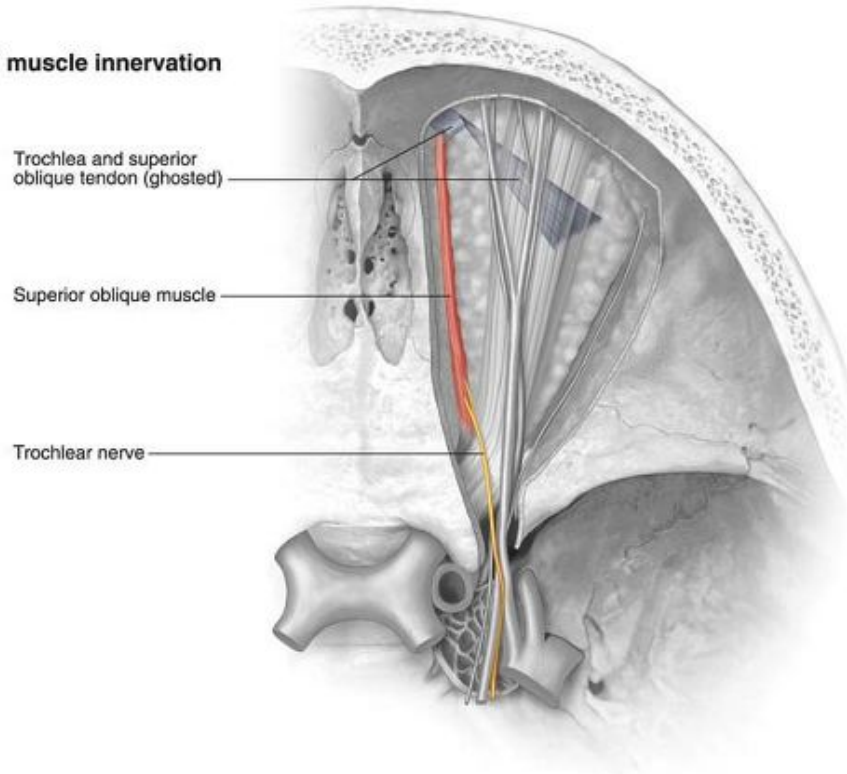
A. Origin from brain



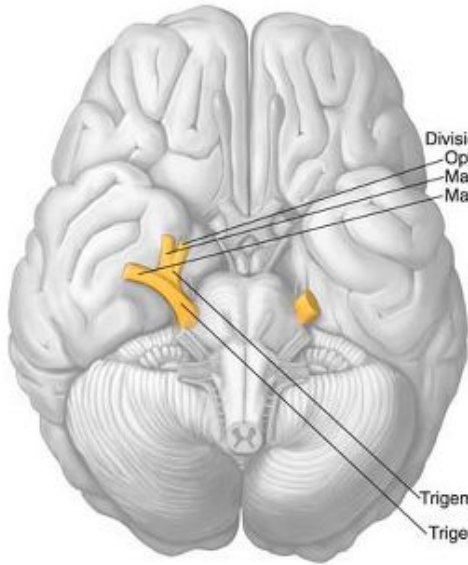
B. Exit from cranial cavity



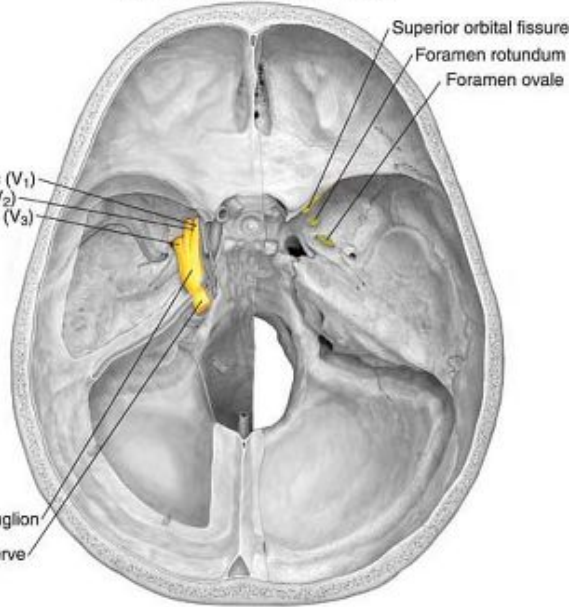
C. Skeletal muscle innervation



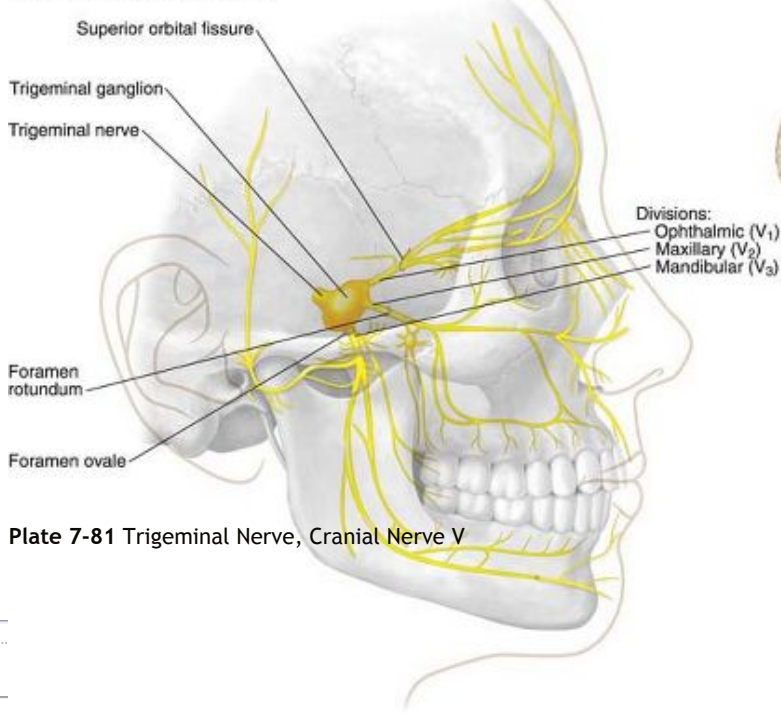
A. Origin from brain



B. Exit from cranial cavity



C. Overview of divisions



D. Cutaneous distribution

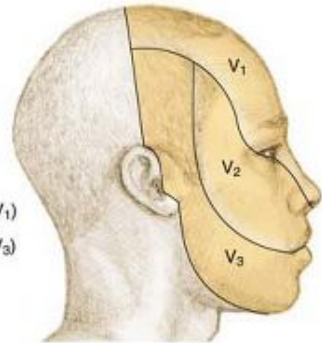
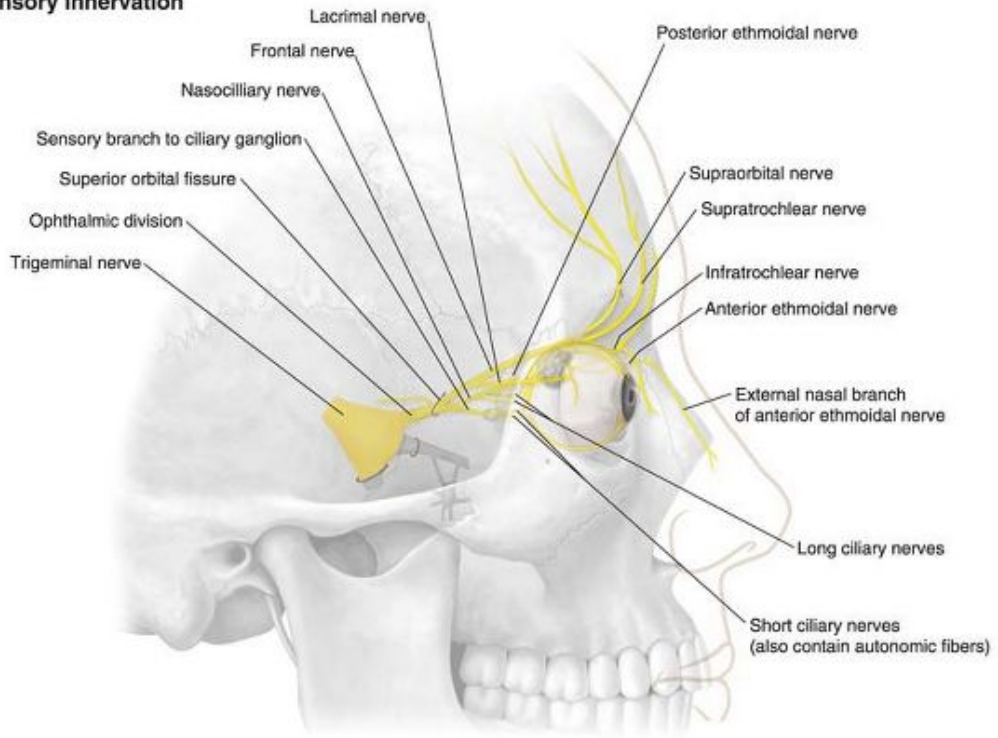
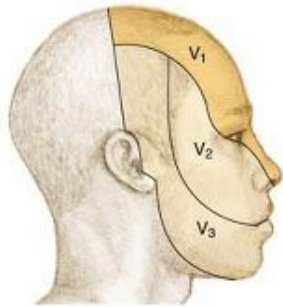


Plate 7-81 Trigeminal Nerve, Cranial Nerve V

A. Sensory innervation



B. Cutaneous distribution



C. Branches that carry parasympathetic innervation

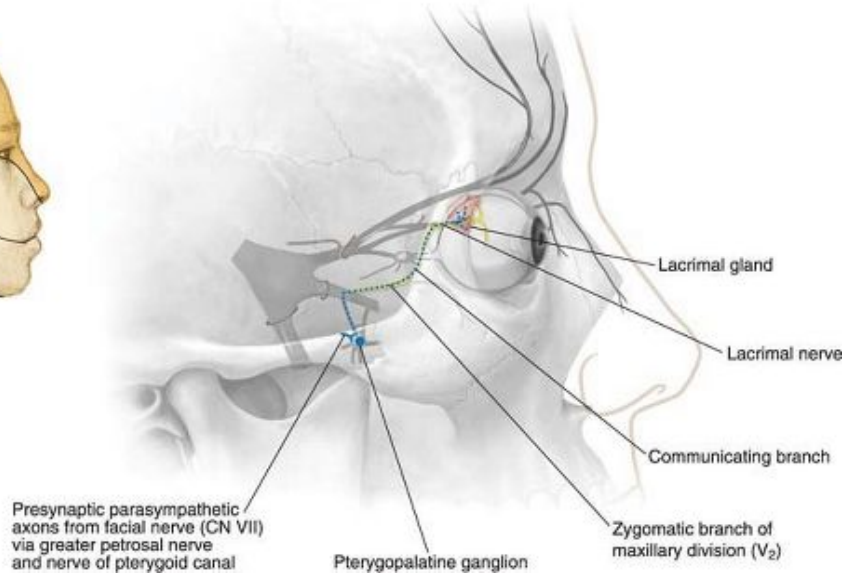
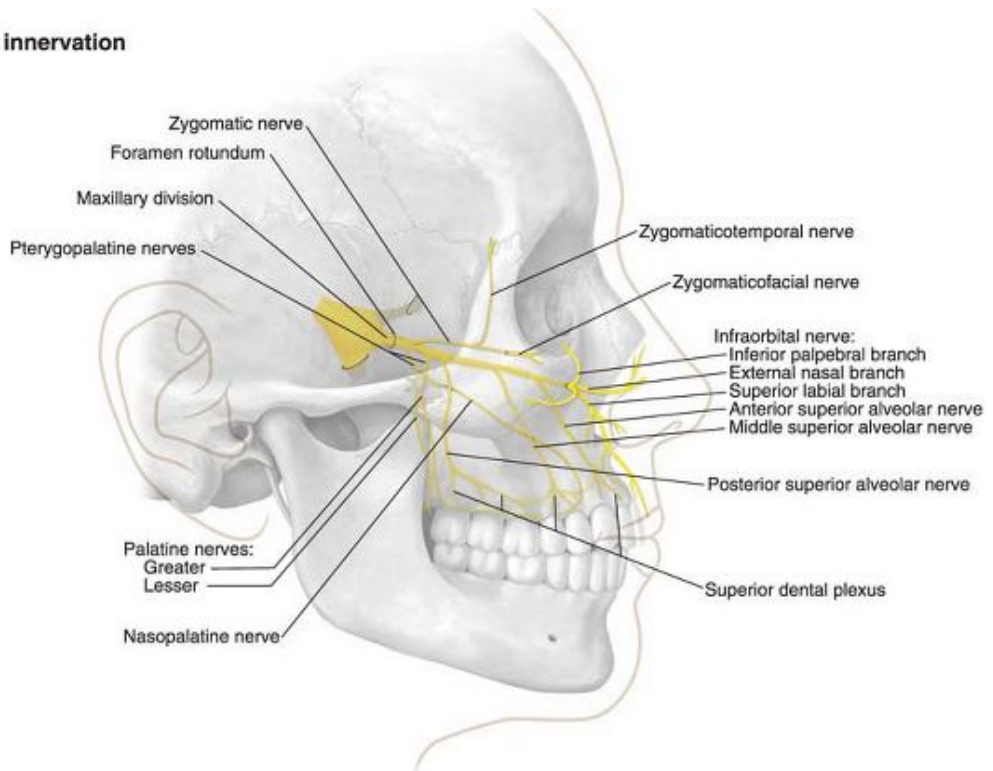


Plate 7-82 Ophthalmic Division of Trigeminal Nerve (V_1)

A. Sensory innervation



B. Cutaneous distribution

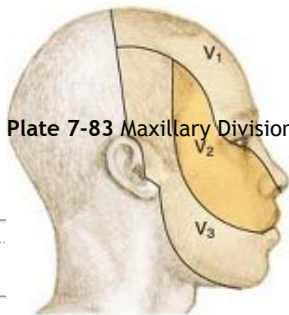
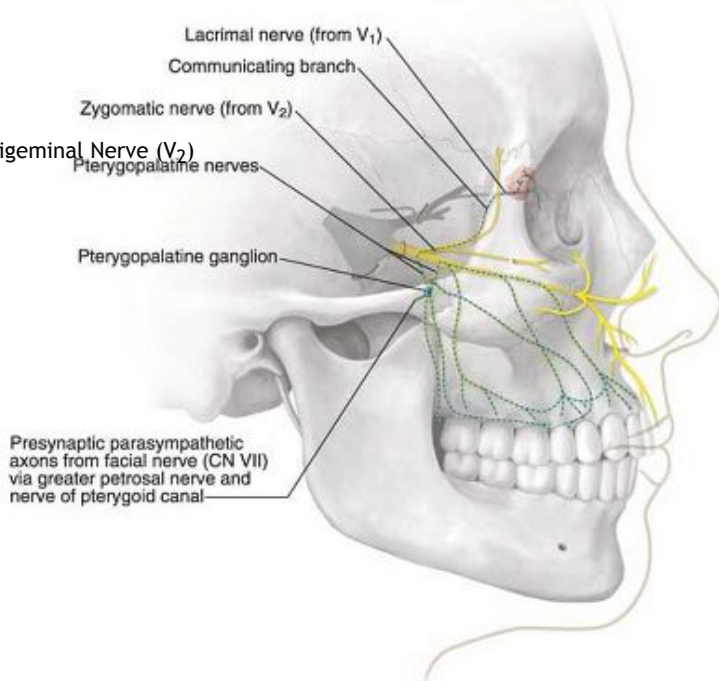
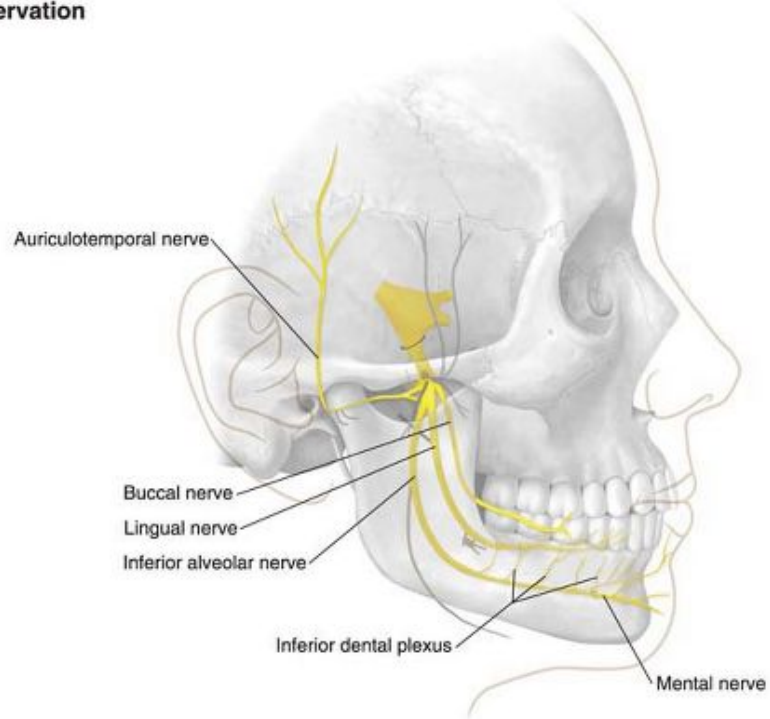


Plate 7-83 Maxillary Division of Trigeminal Nerve (V₂)

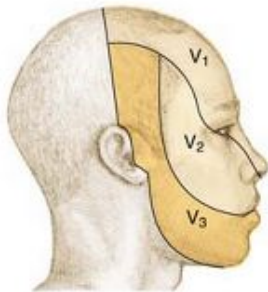
C. Branches that carry parasympathetic innervation



A. Sensory innervation

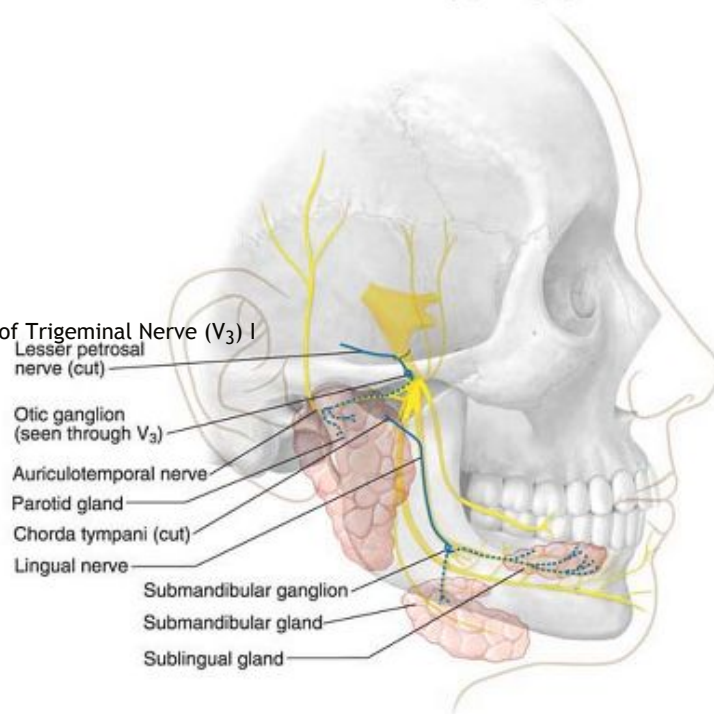


B. Cutaneous distribution

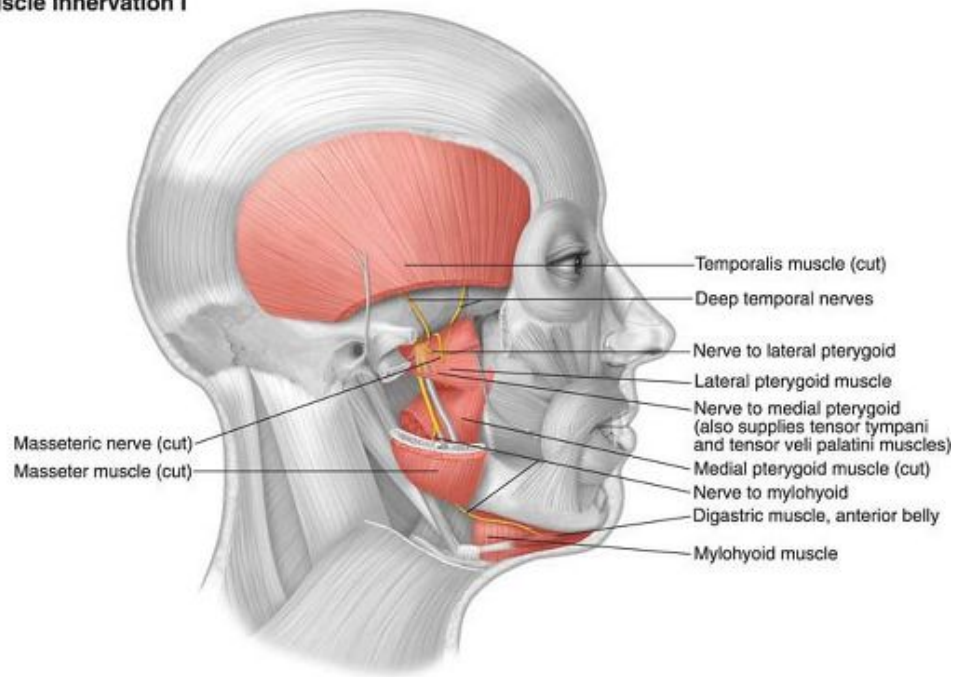


C. Branches that carry parasympathetic innervation

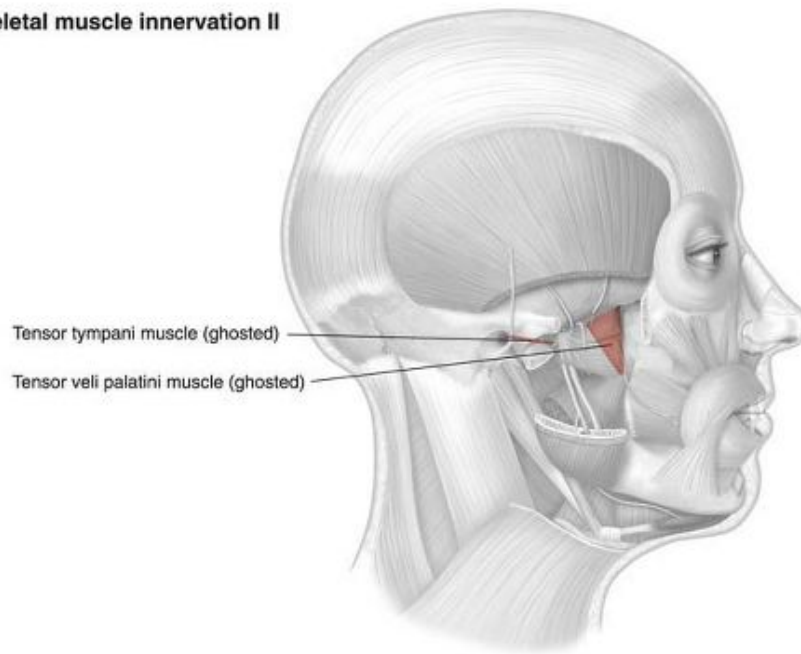
Plate 7-84 Mandibular Division of Trigeminal Nerve (V₃) I



A. Skeletal muscle innervation I

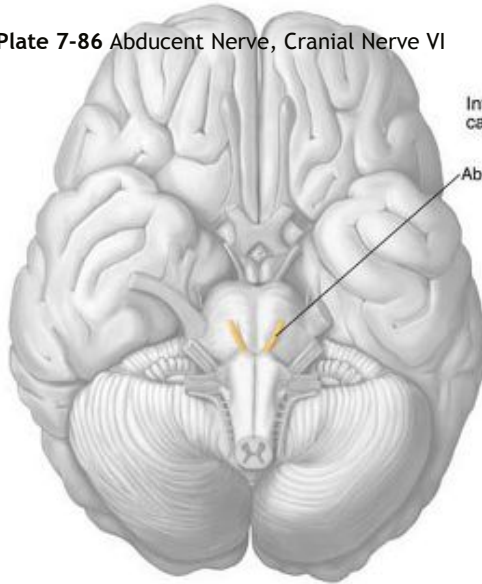


B. Skeletal muscle innervation II

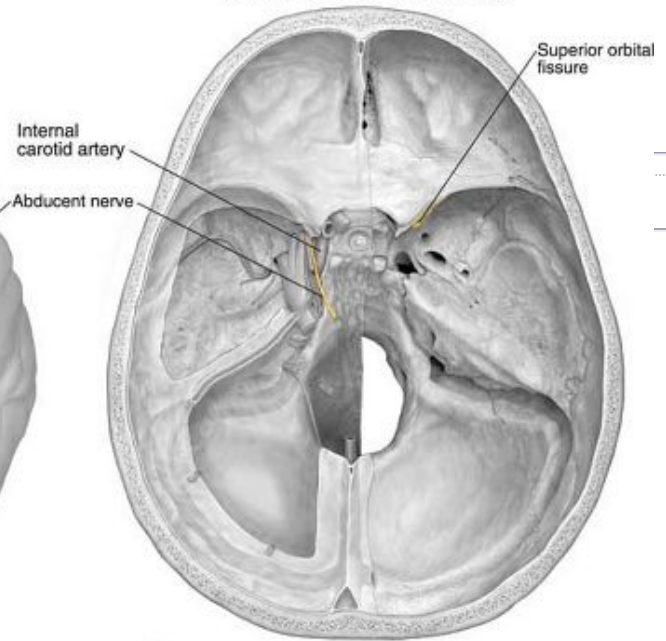


A. Origin from brain

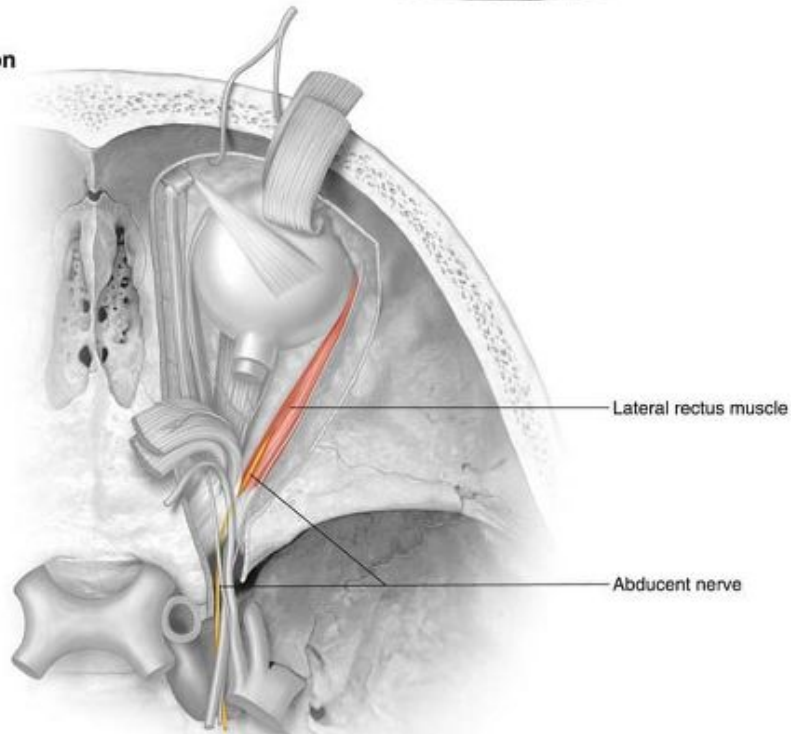
Plate 7-86 Abducent Nerve, Cranial Nerve VI



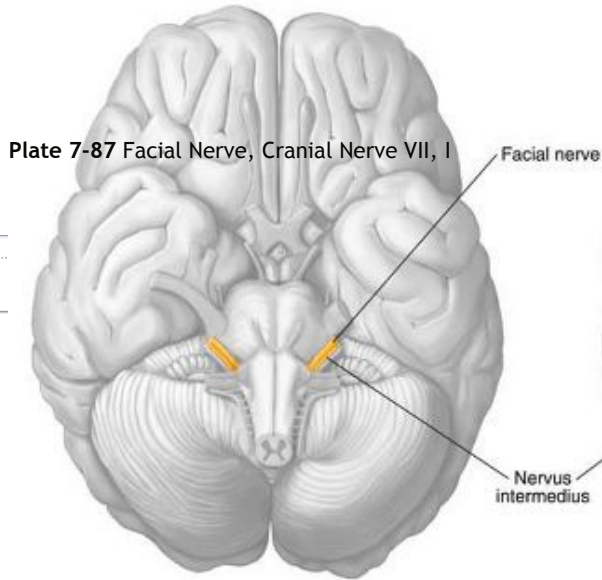
B. Exit from cranial cavity



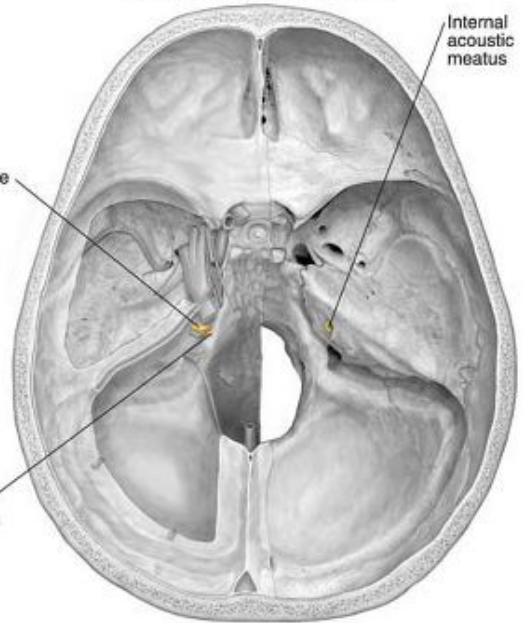
C. Skeletal muscle innervation



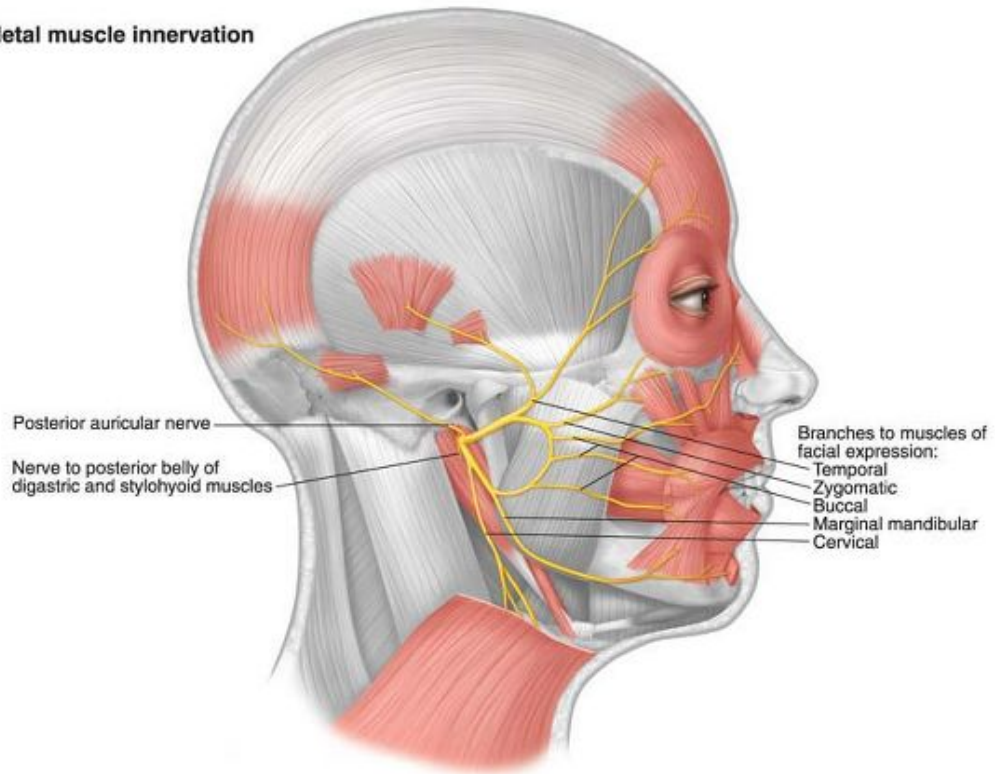
A. Origin from brain



B. Exit from cranial cavity

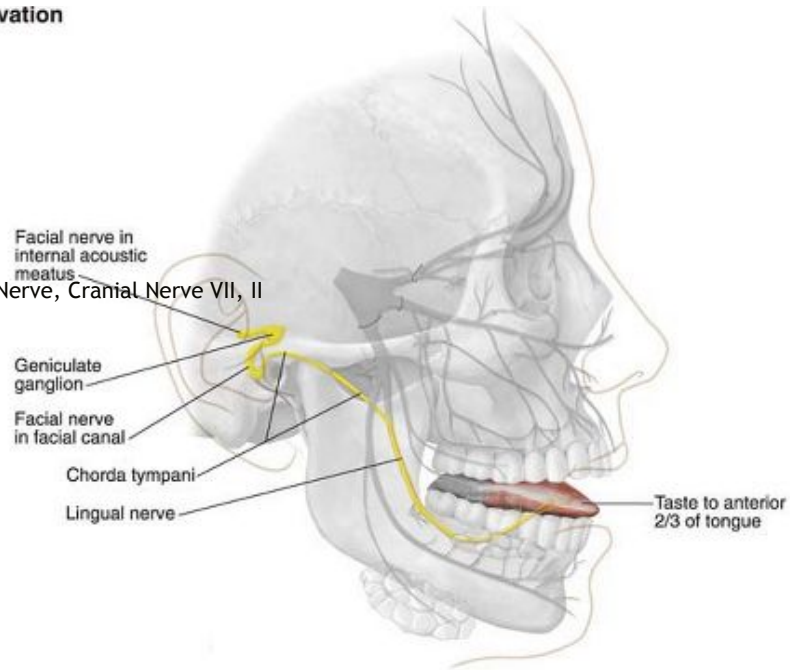


C. Skeletal muscle innervation

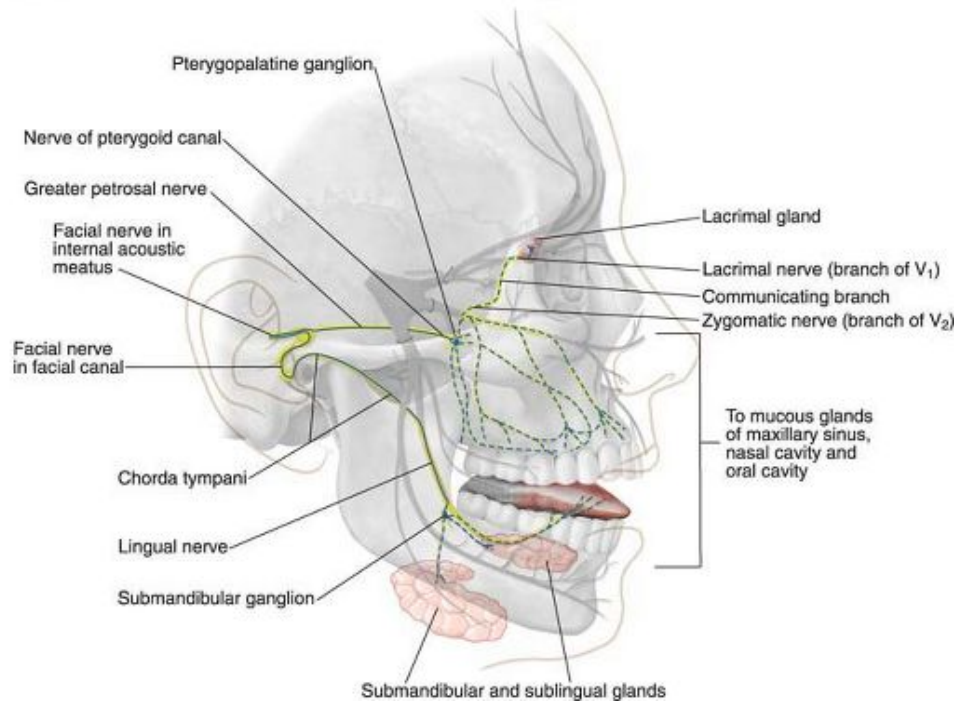


A. Sensory innervation

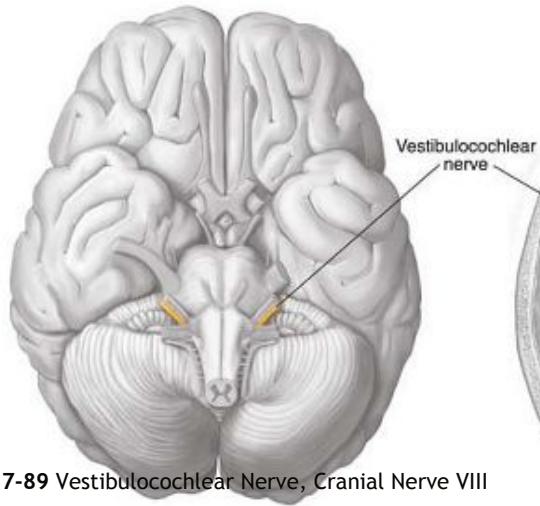
Plate 7-88 Facial Nerve, Cranial Nerve VII, II



B. Parasympathetic innervation



A. Origin from brain



B. Exit from cranial cavity

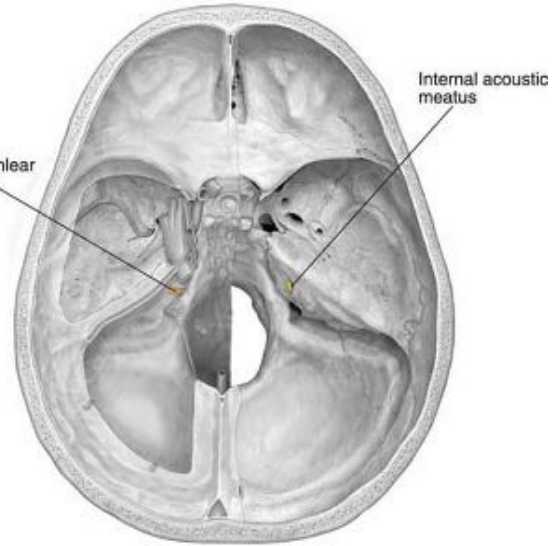
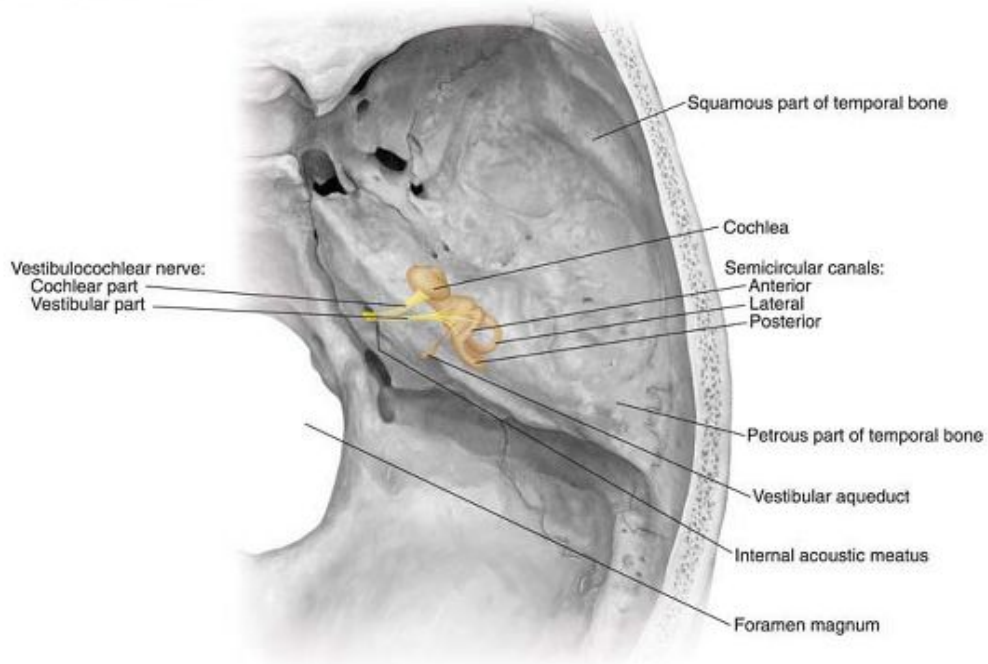
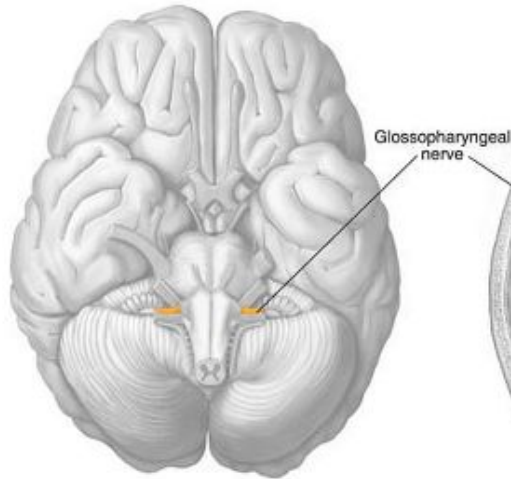


Plate 7-89 Vestibulocochlear Nerve, Cranial Nerve VIII

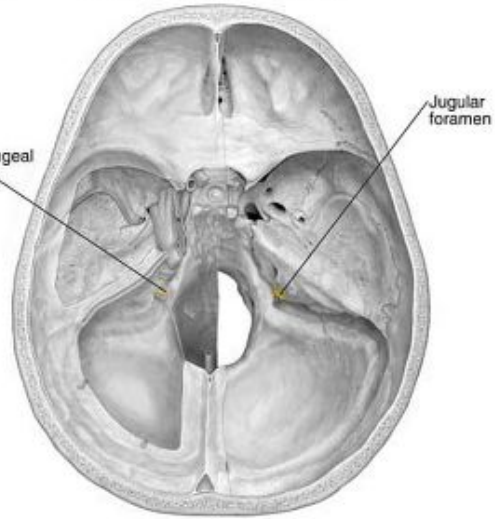
C. Sensory innervation



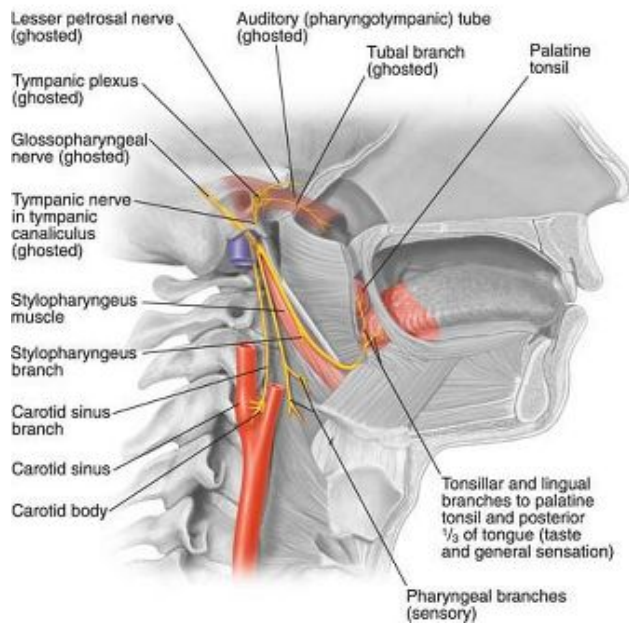
A. Origin from brain



B. Exit from cranial cavity



C. Sensory and skeletal muscle innervation



D. Parasympathetic innervation

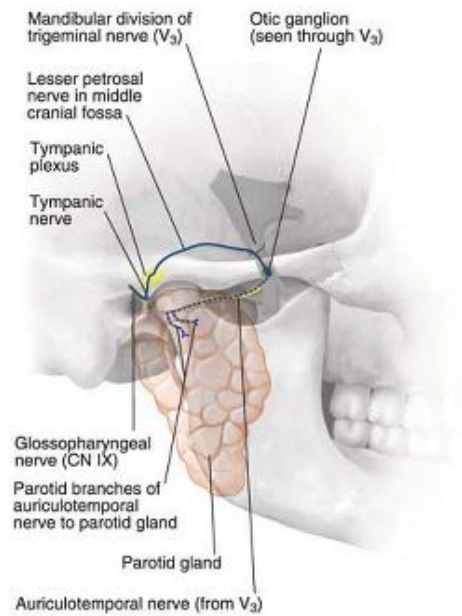


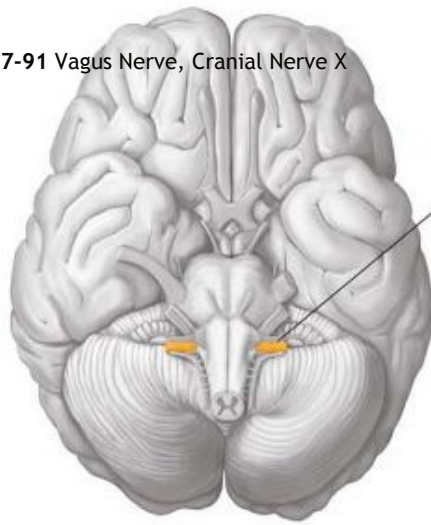
Plate 7-90 Glossopharyngeal Nerve, Cranial Nerve IX

P.386

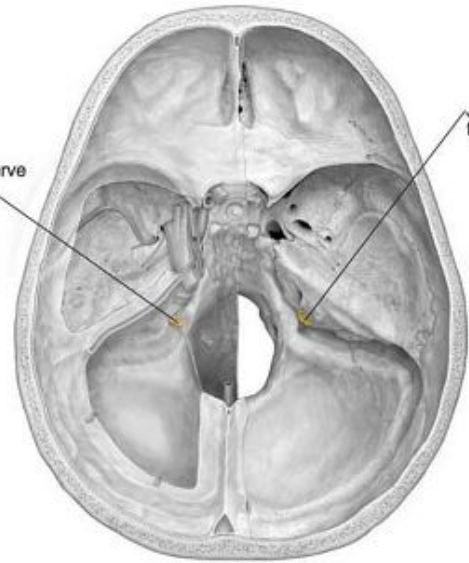


A. Origin from brain

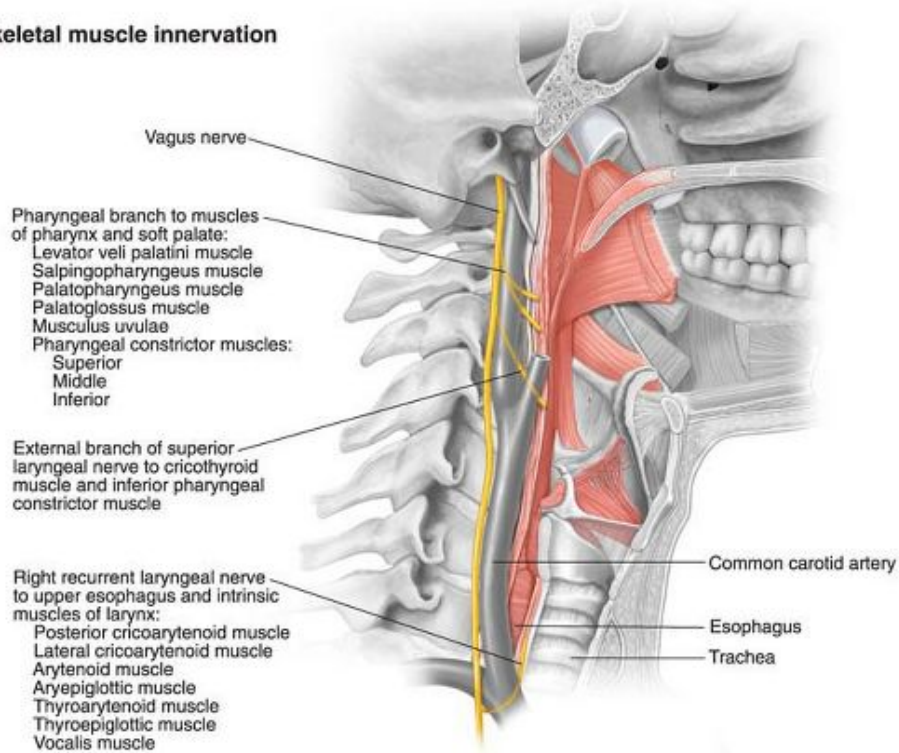
Plate 7-91 Vagus Nerve, Cranial Nerve X

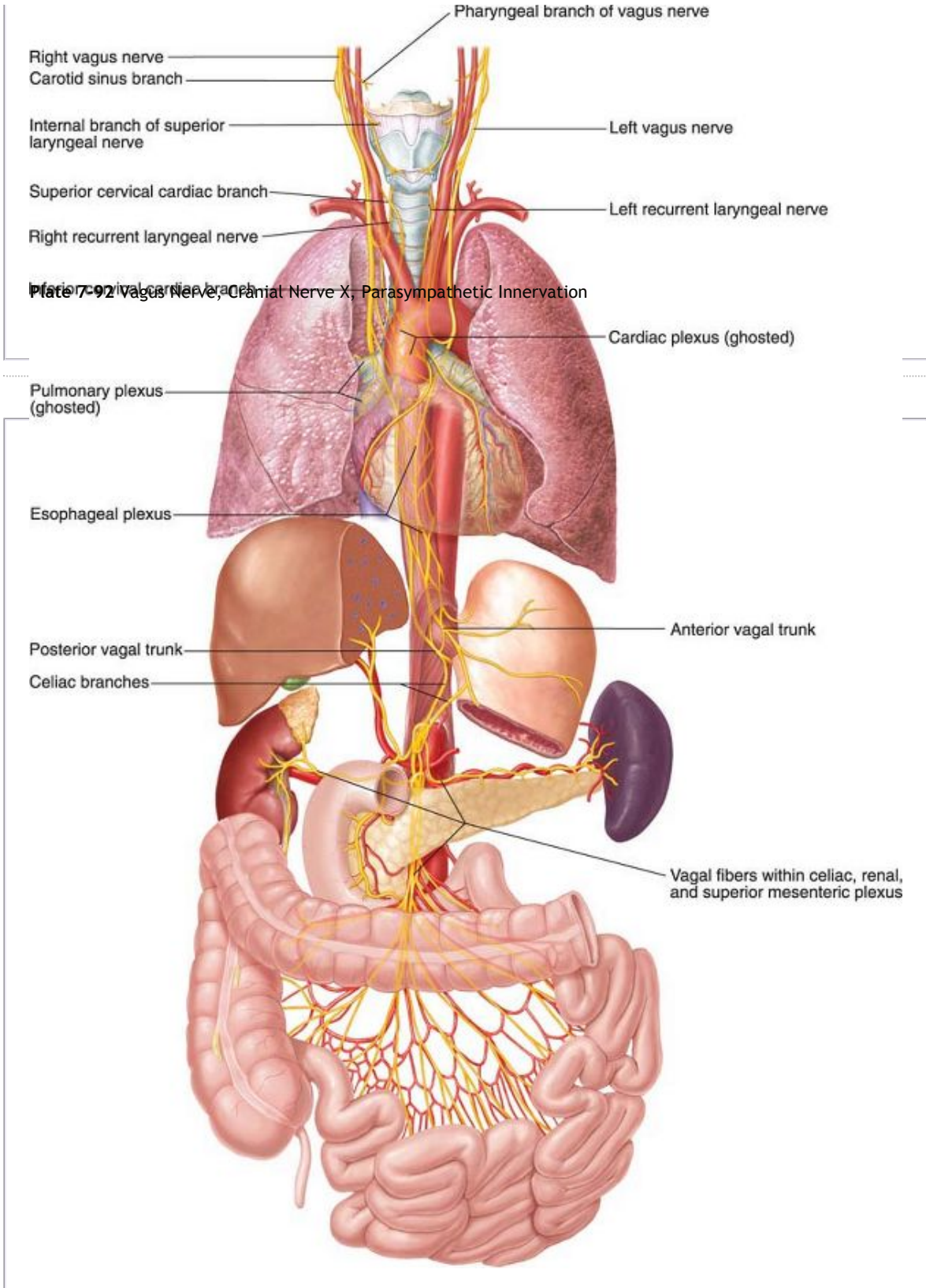


B. Exit from cranial cavity

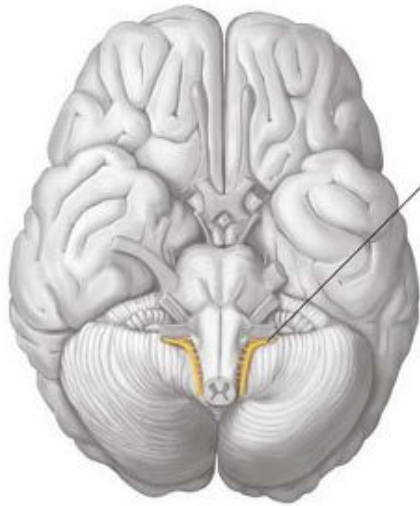


C. Skeletal muscle innervation

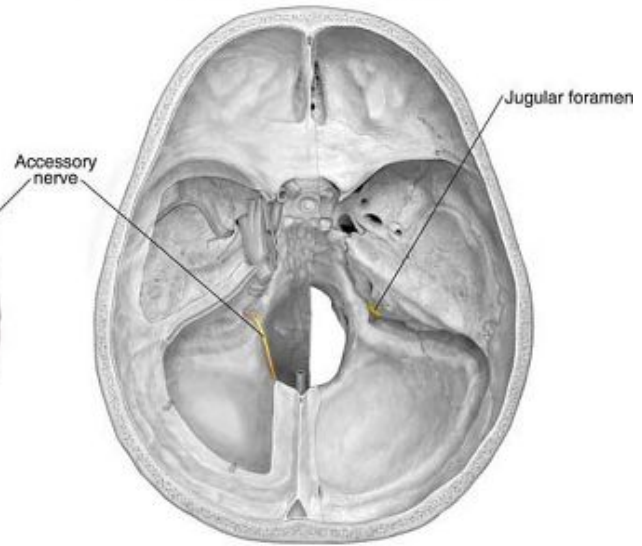




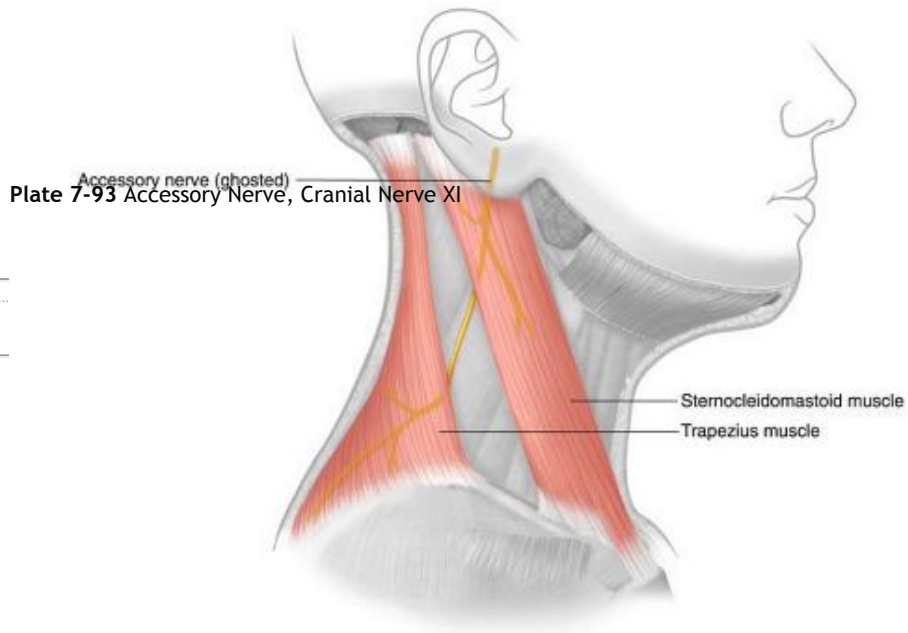
A. Origin from spinal cord



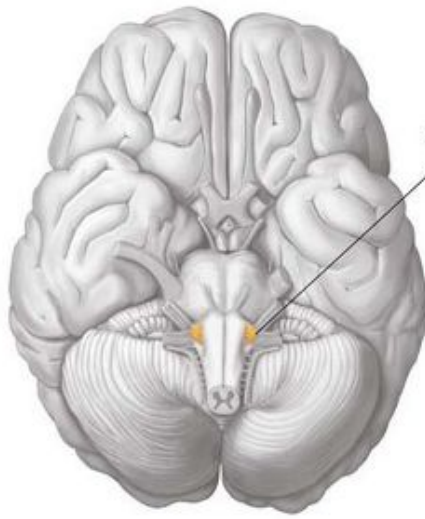
B. Exit from cranial cavity



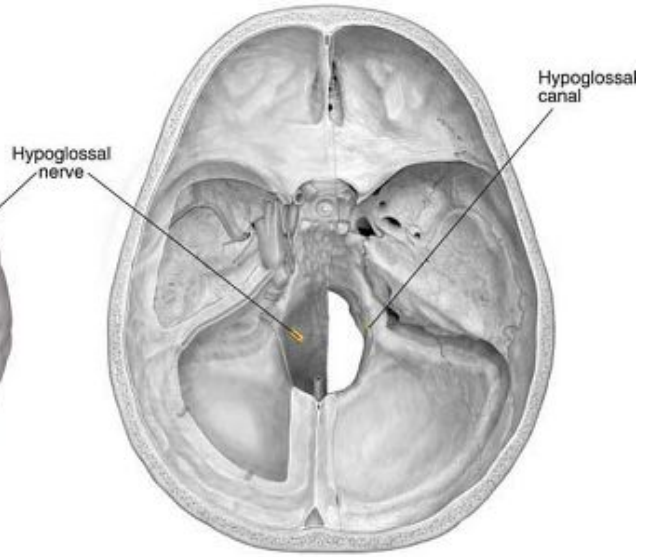
C. Skeletal muscle innervation



A. Origin from brain



B. Exit from cranial cavity



C. Skeletal muscle innervation

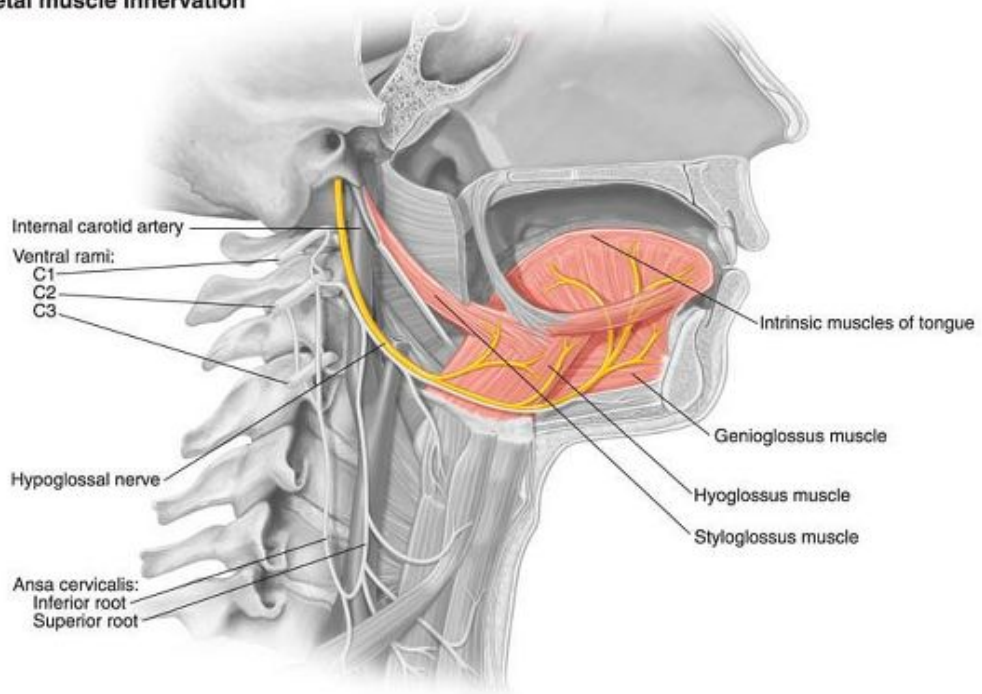


Plate 7-94 Hypoglossal Nerve, Cranial Nerve XII

Plate 7-95 Summary of Head and Neck Sympathetic Innervation

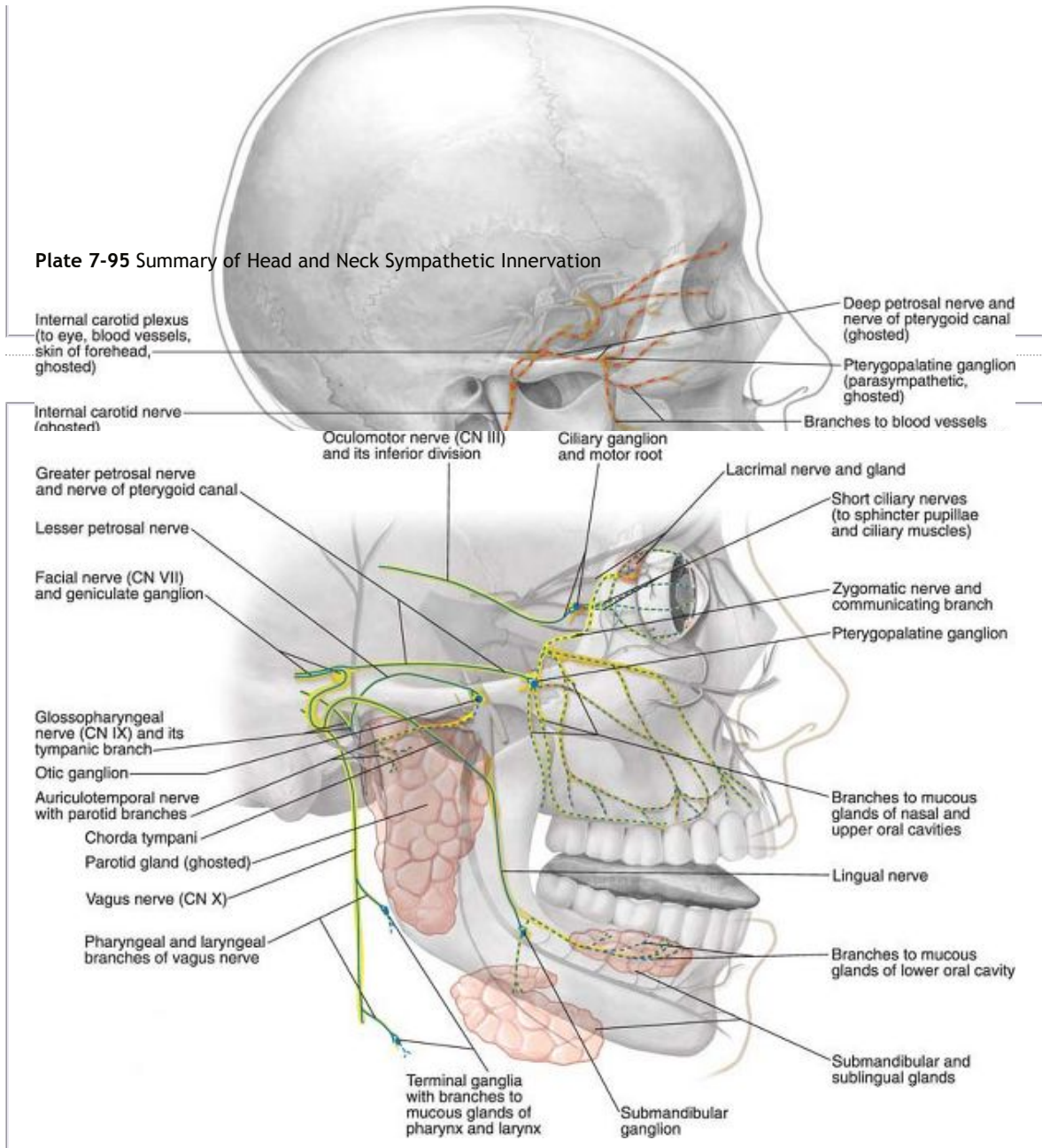


Plate 7-96 Summary of Head and Neck Parasympathetic Innervation

Authors: Tank, Patrick W.; Gest, Thomas R.

Title: *Lippincott Williams & Wilkins Atlas of Anatomy, 1st Edition*

Copyright ©2009 Lippincott Williams & Wilkins

> Table of Contents > Chapter 8 - The Autonomic Nervous System

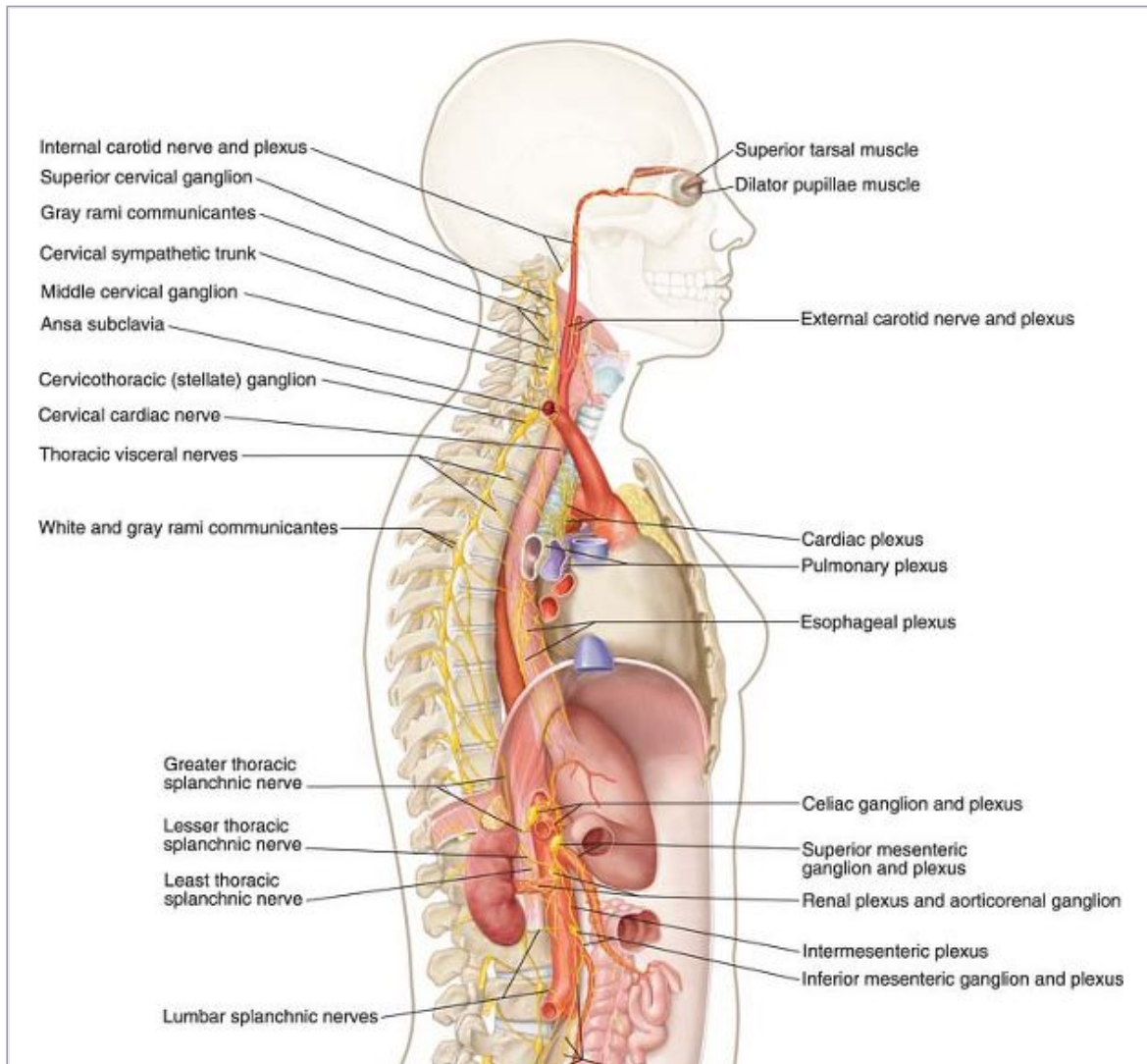
Chapter 8

The Autonomic Nervous System

P.393

P.394

P.395



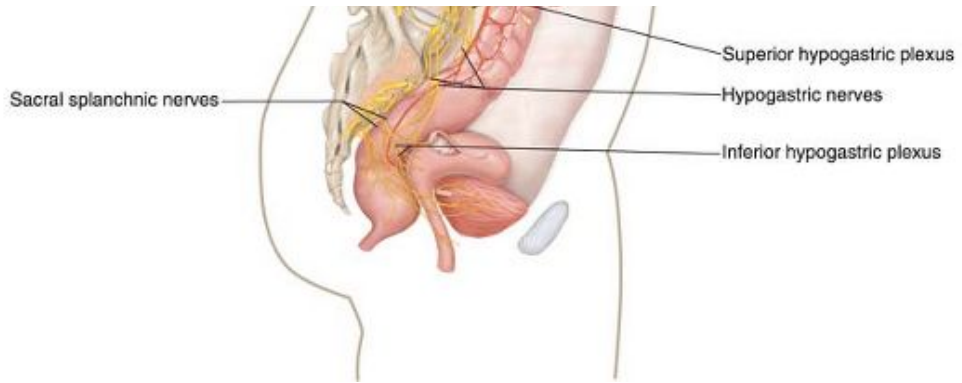
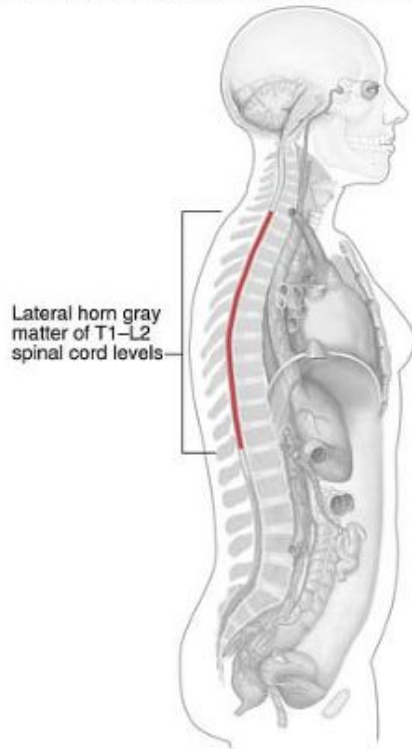
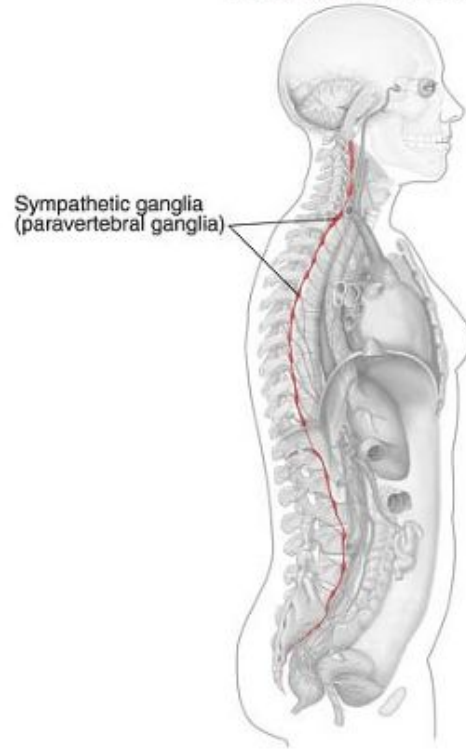


Plate 8-01 Overview of the Sympathetic Nervous System

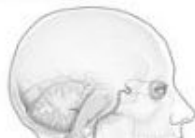A. Location of presynaptic cell bodies



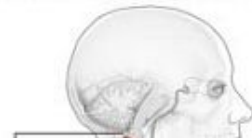B. Sympathetic trunk



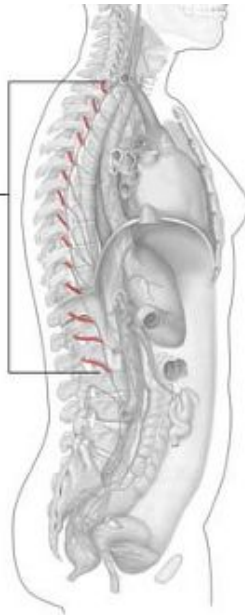C. White rami communicantes



D. Gray rami communicantes



From spinal nerves T1–L2 to sympathetic trunk

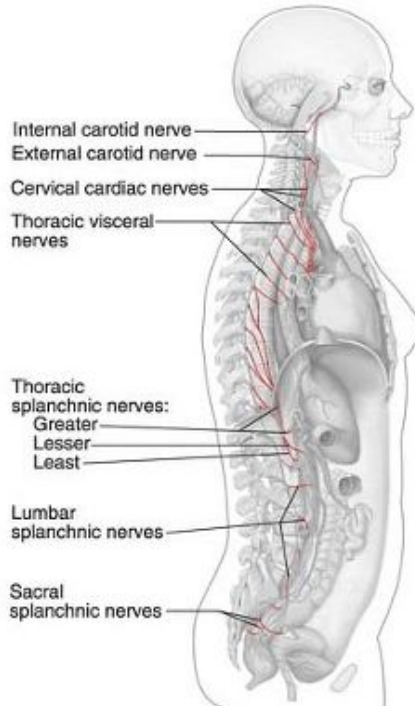


From sympathetic trunk to all spinal nerves

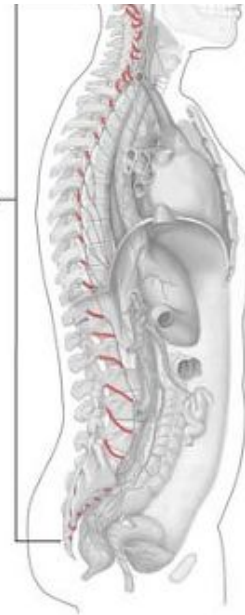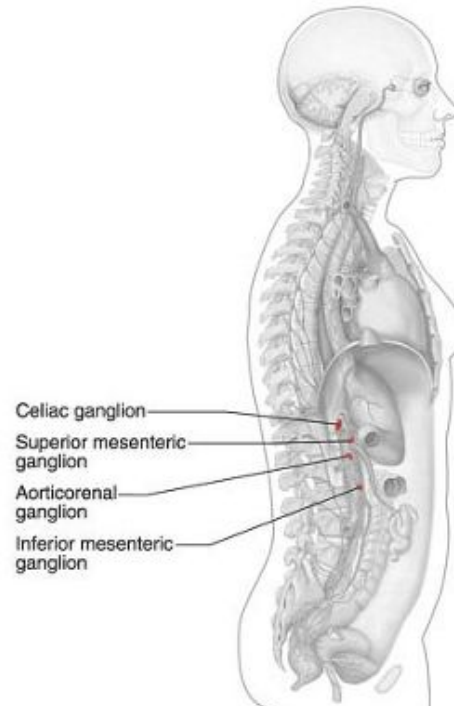


Plate 8-02 Components of the Sympathetic Nervous System I

A. Nerves that carry sympathetic fibers



B. Preaortic ganglia



C. Plexuses that carry postsynaptic sympathetic fibers

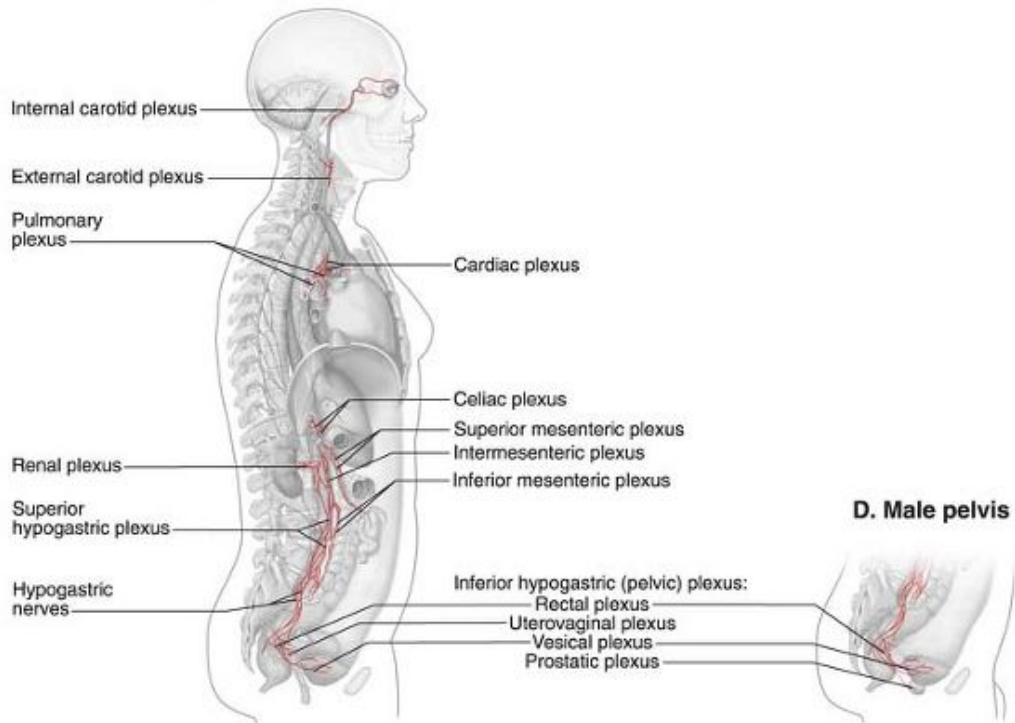
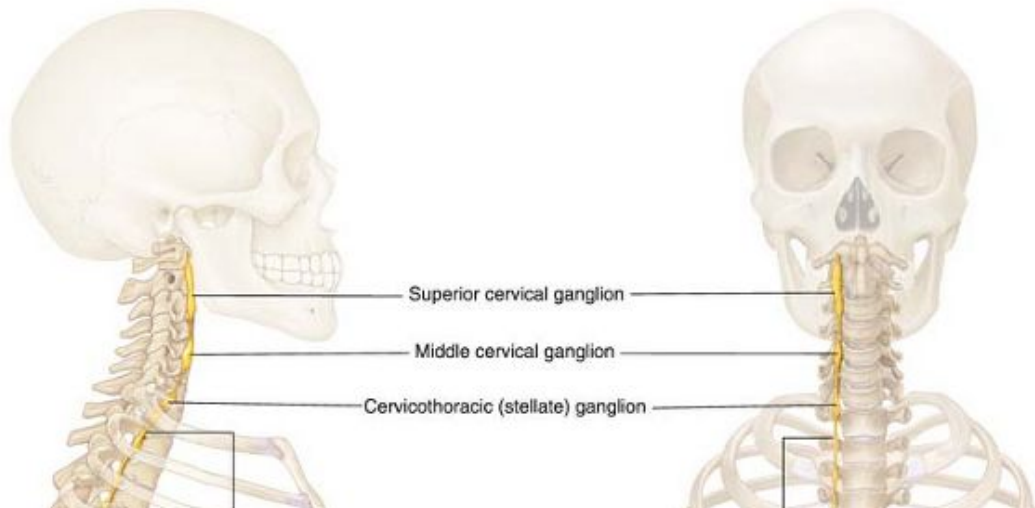


Plate 8-03 Components of the Sympathetic Nervous System II

A. Lateral view

B. Anterior view



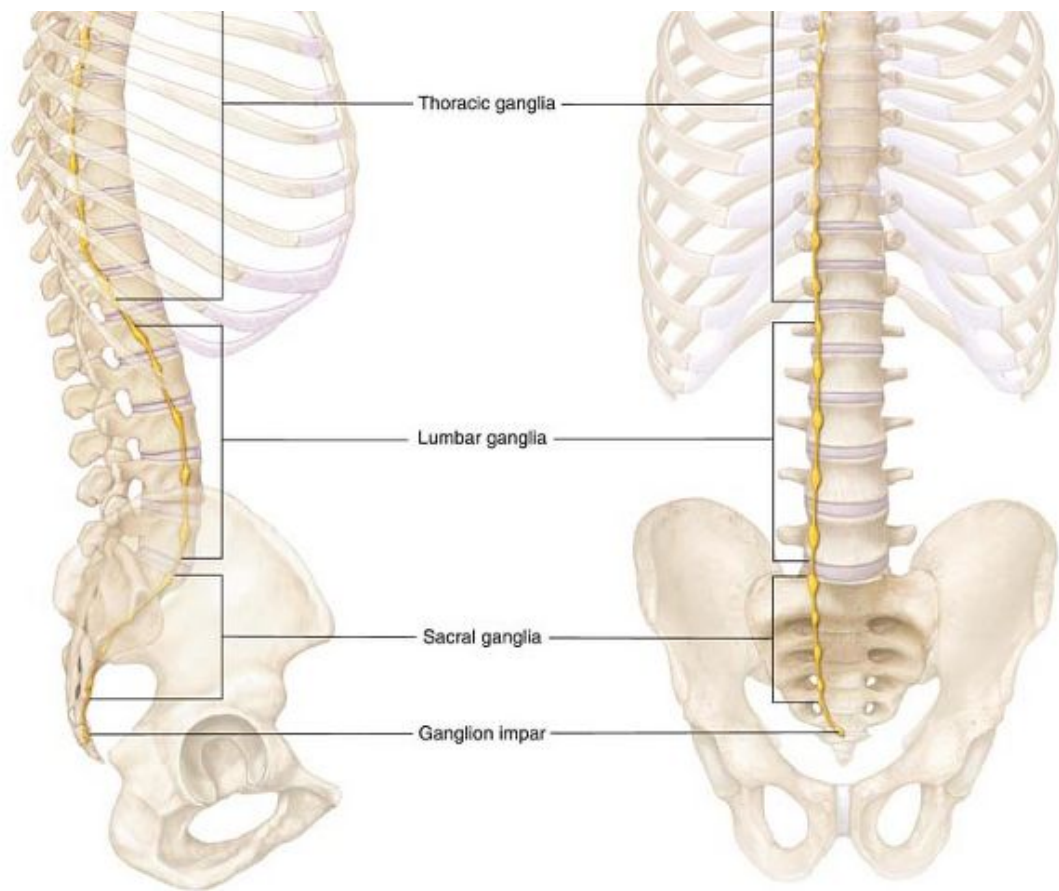
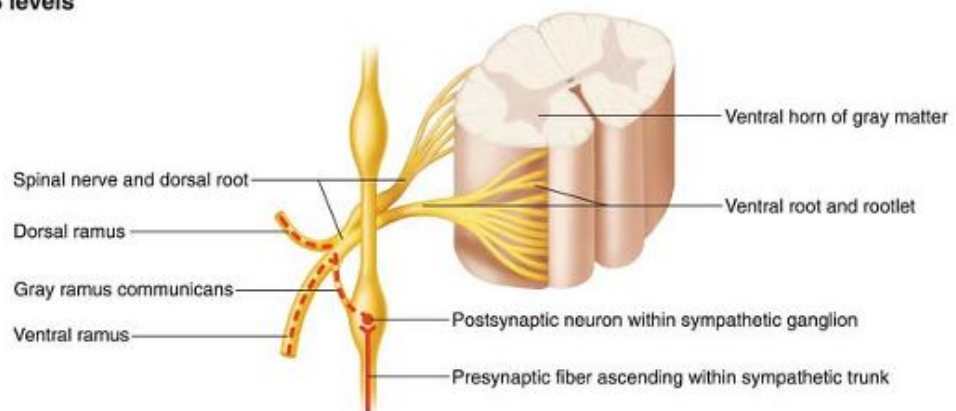
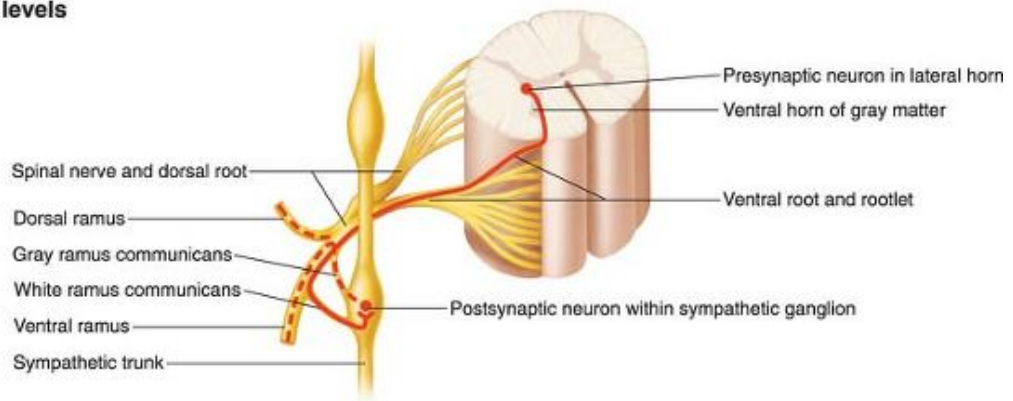


Plate 8-04 Position of Sympathetic Trunks

A. C1–C8 levels



B. T1–L2 levels



C. L3–Co levels

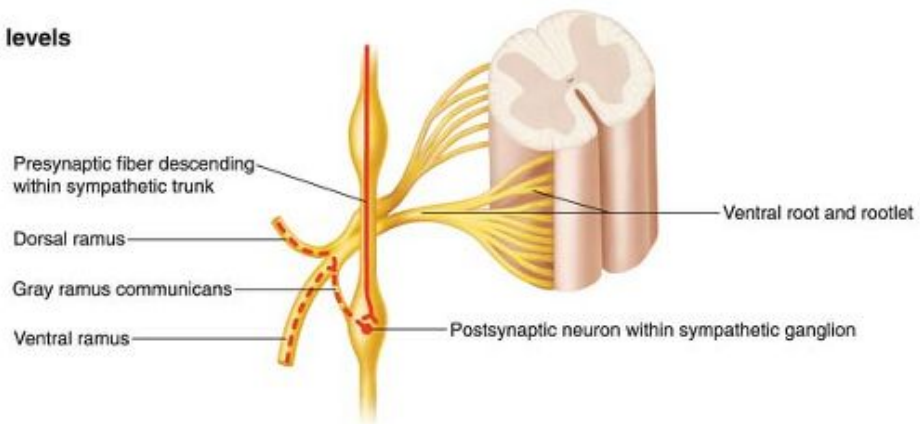
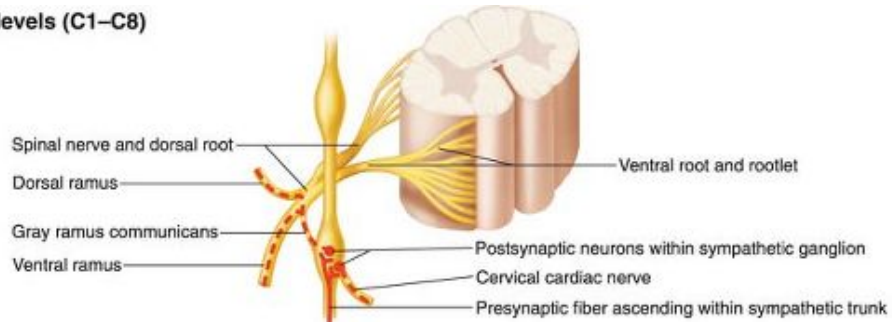
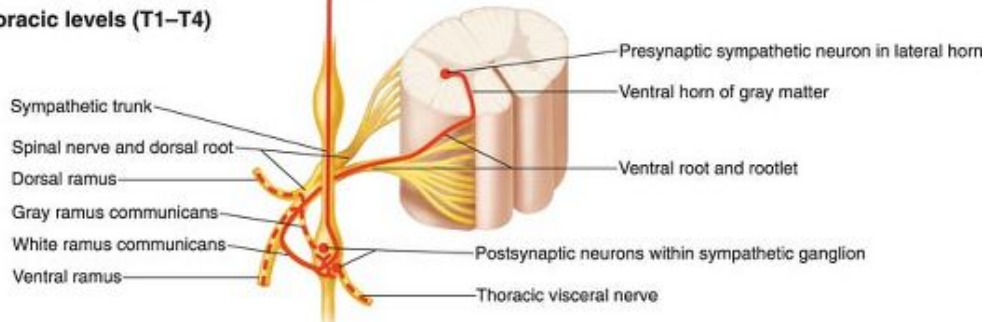


Plate 8-05 Pathways of Sympathetic Neurons, Oblique View I

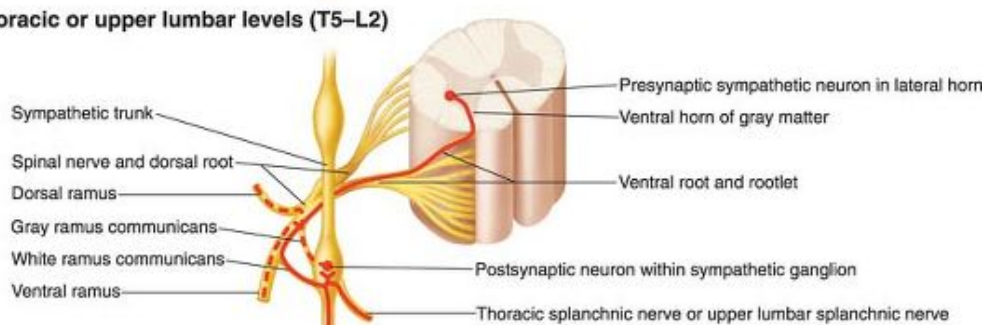
A. Cervical levels (C1–C8)



B. Upper thoracic levels (T1–T4)



C. Lower thoracic or upper lumbar levels (T5–L2)



D. Lower lumbar or sacral levels (L3–Co)

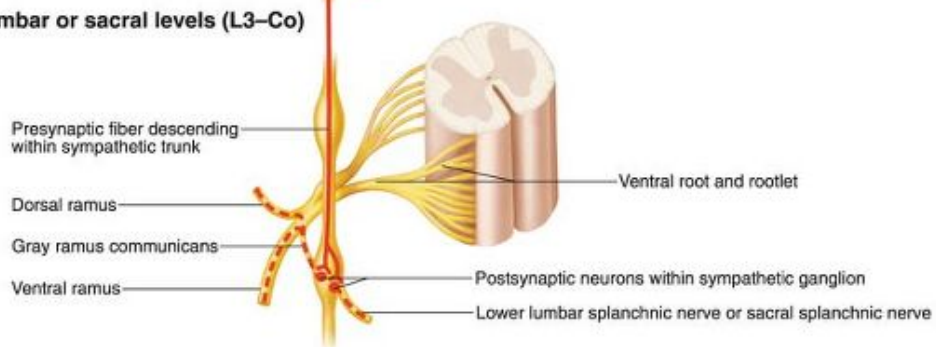
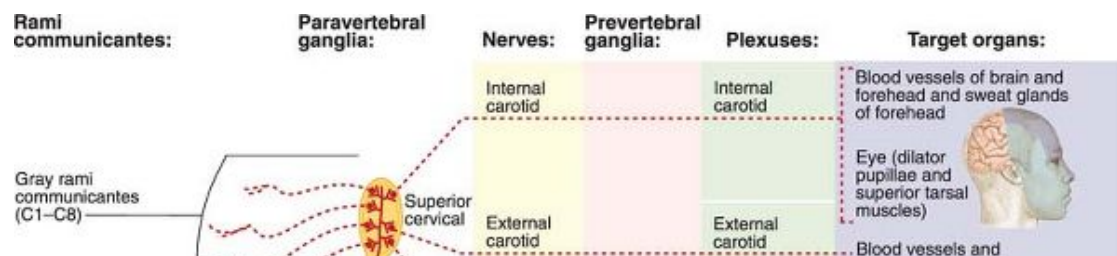


Plate 8-06 Pathways of Sympathetic Neurons. Oblique View II



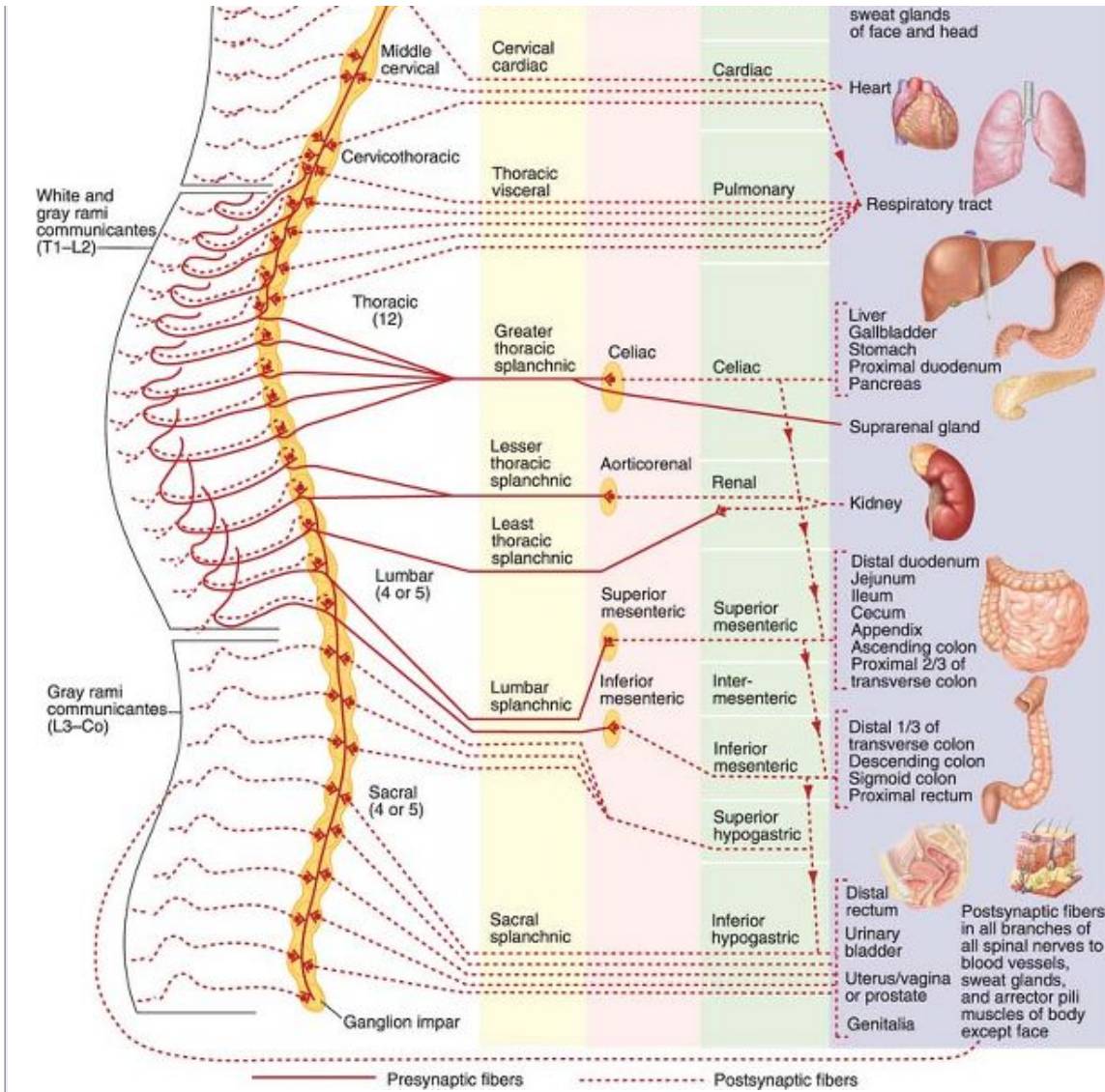
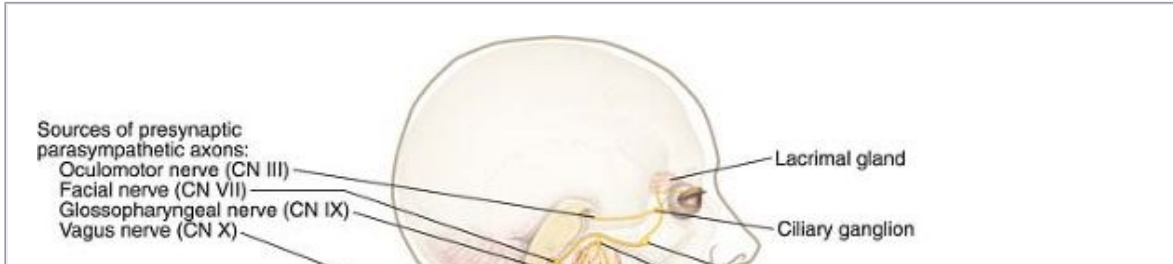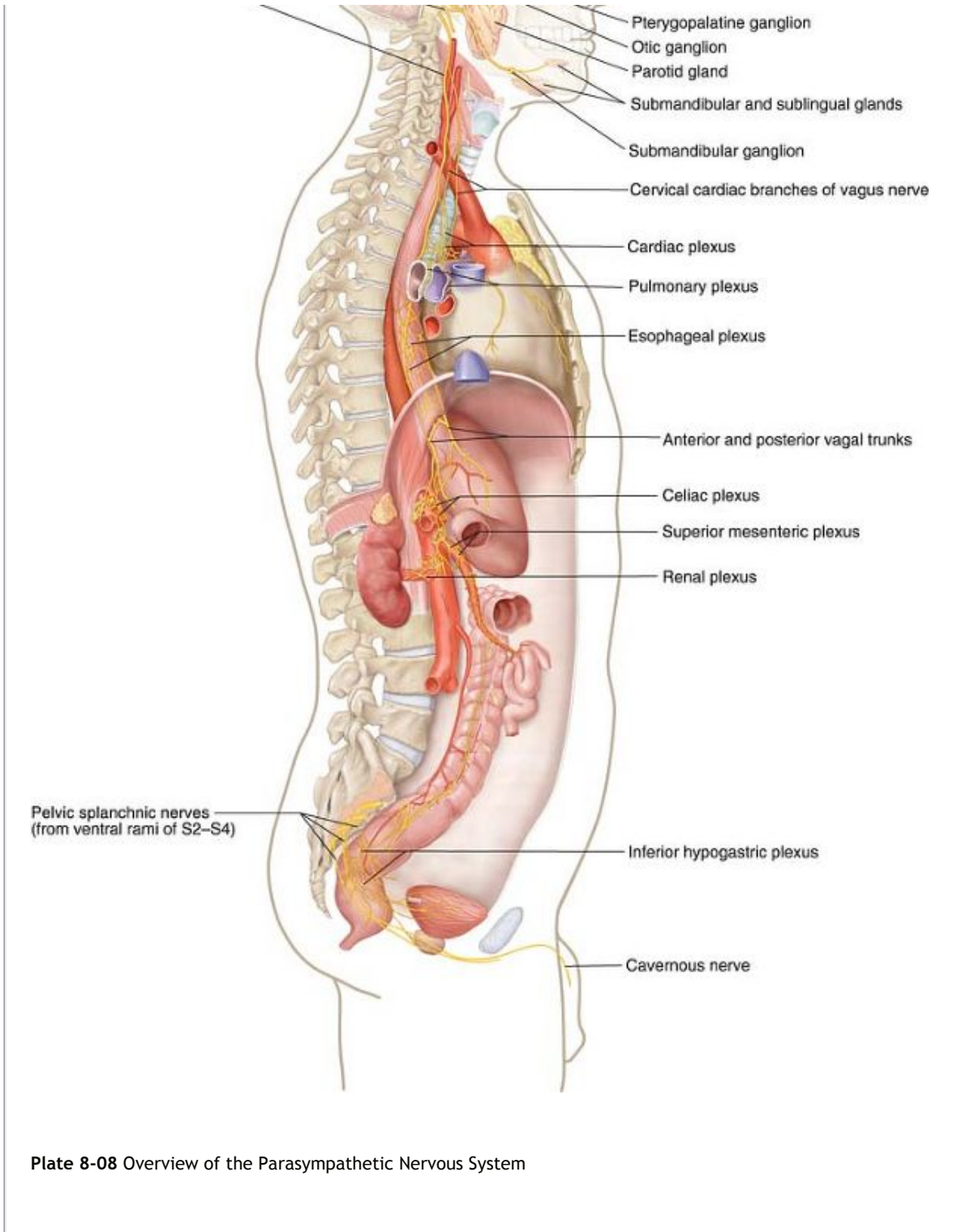
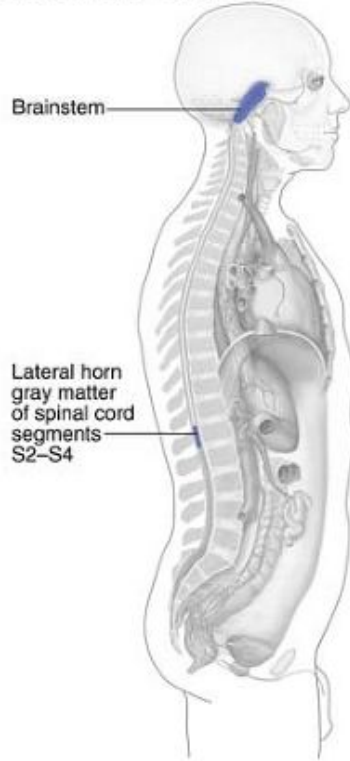


Plate 8-07 Pathways of the Sympathetic Nervous System

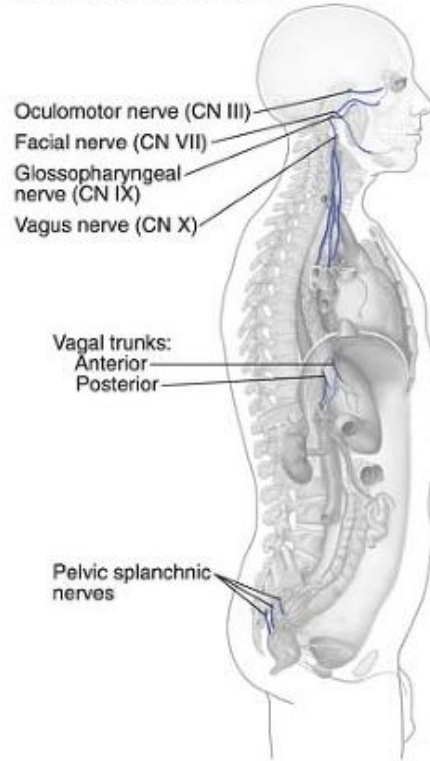




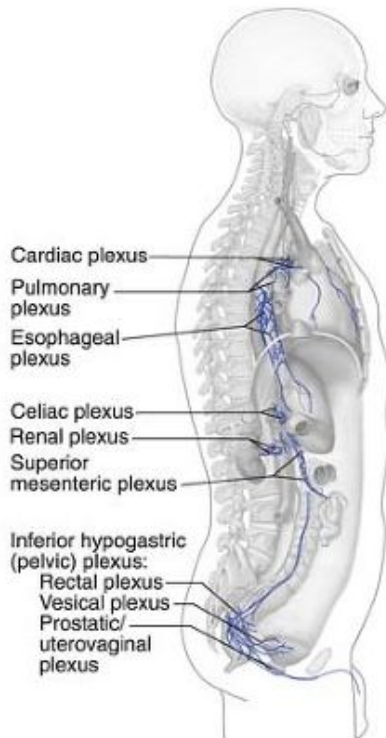
A. Location of presynaptic parasympathetic cell bodies



B. Nerves that carry presynaptic parasympathetic fibers



C. Plexuses that carry presynaptic parasympathetic fibers



D. Location of postsynaptic parasympathetic cell bodies

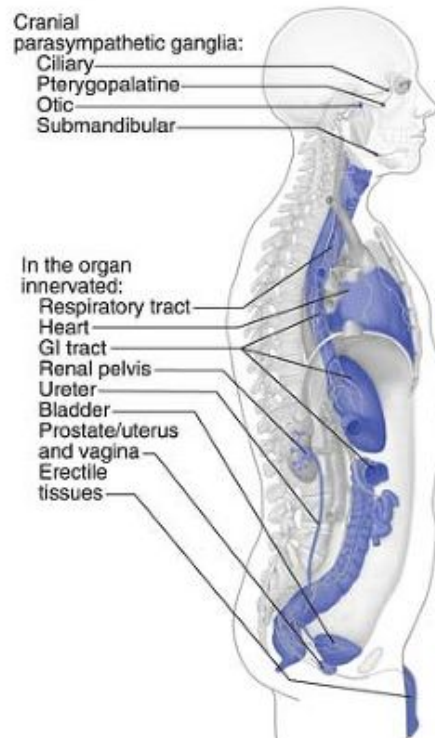
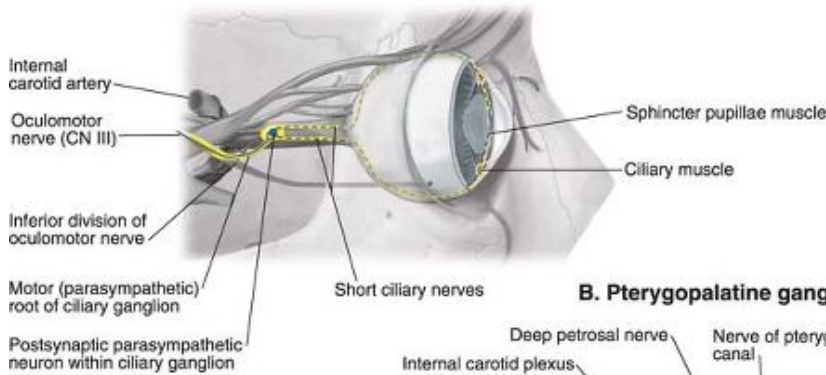
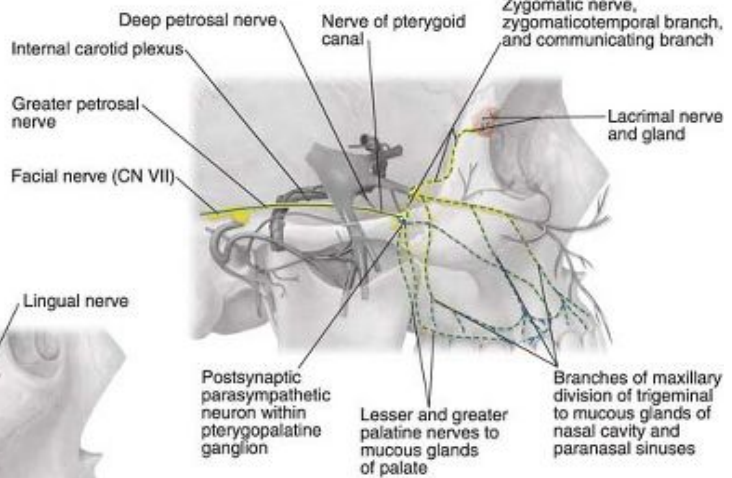


Plate 8-09 Components of the Parasympathetic Nervous System

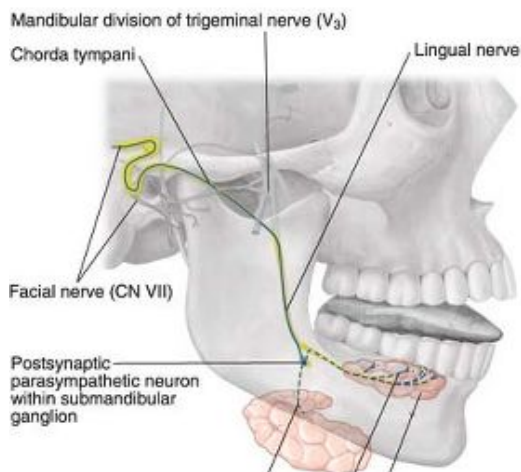
A. Ciliary ganglion



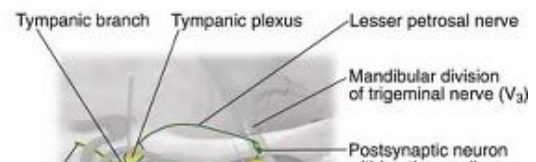
B. Pterygopalatine ganglion



C. Submandibular ganglion



D. Otic ganglion



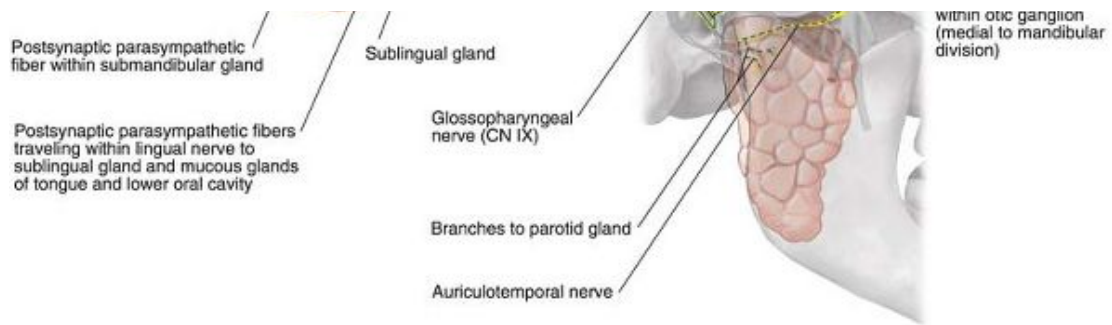
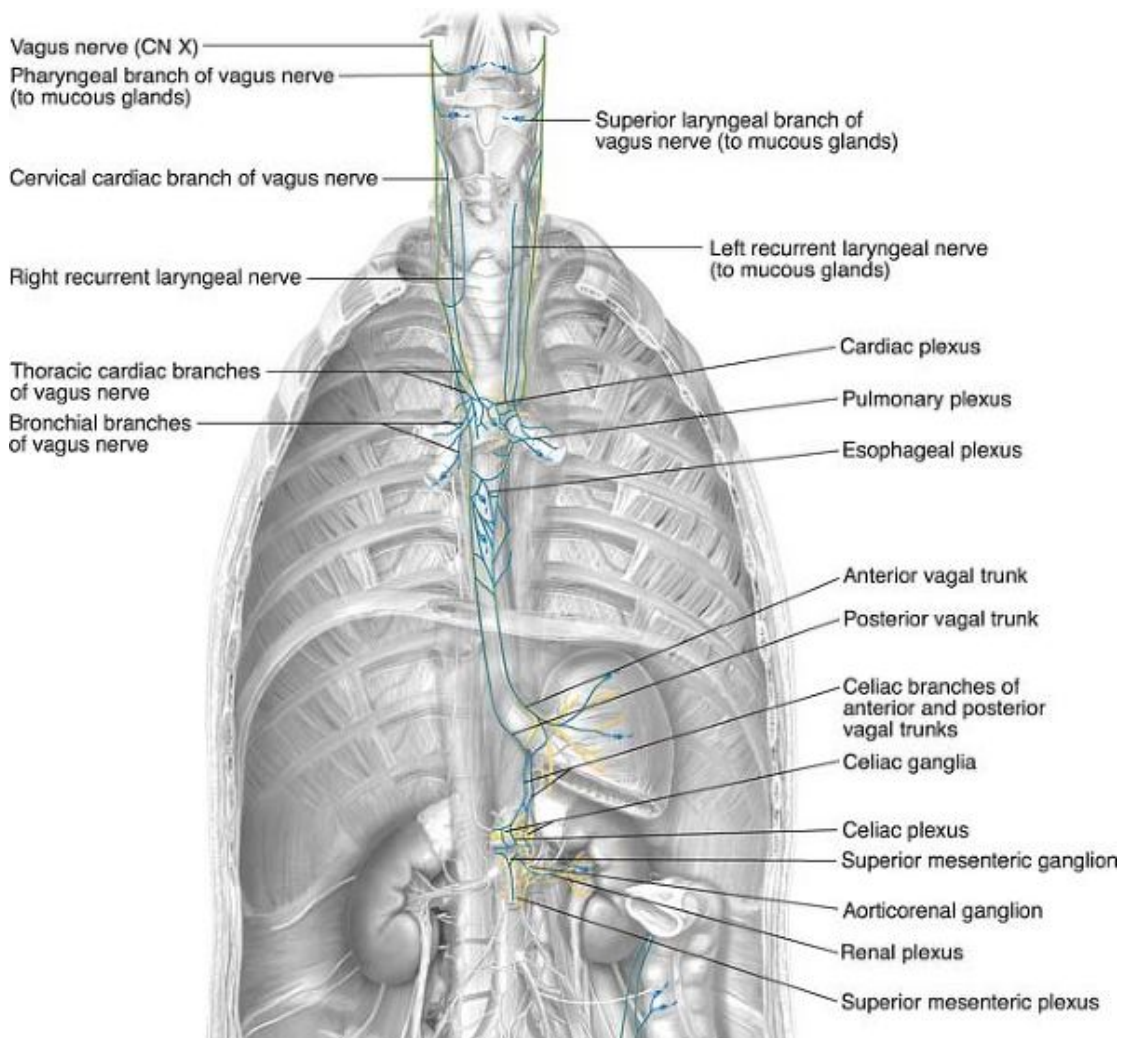


Plate 8-10 Parasympathetic Ganglia of the Head



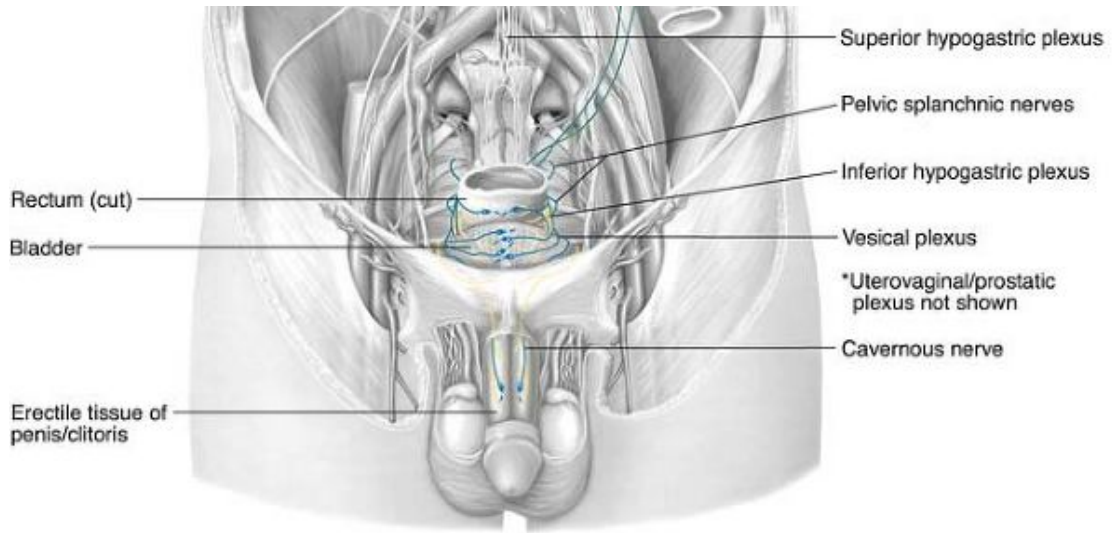


Plate 8-11 Parasympathetic Pathways Below the Head

Sources of presynaptic parasympathetic fibers:



Nerves:

Oculomotor

Ganglia:

Ciliary

Plexuses:

Ciliary

Target organs:

Ciliary muscles

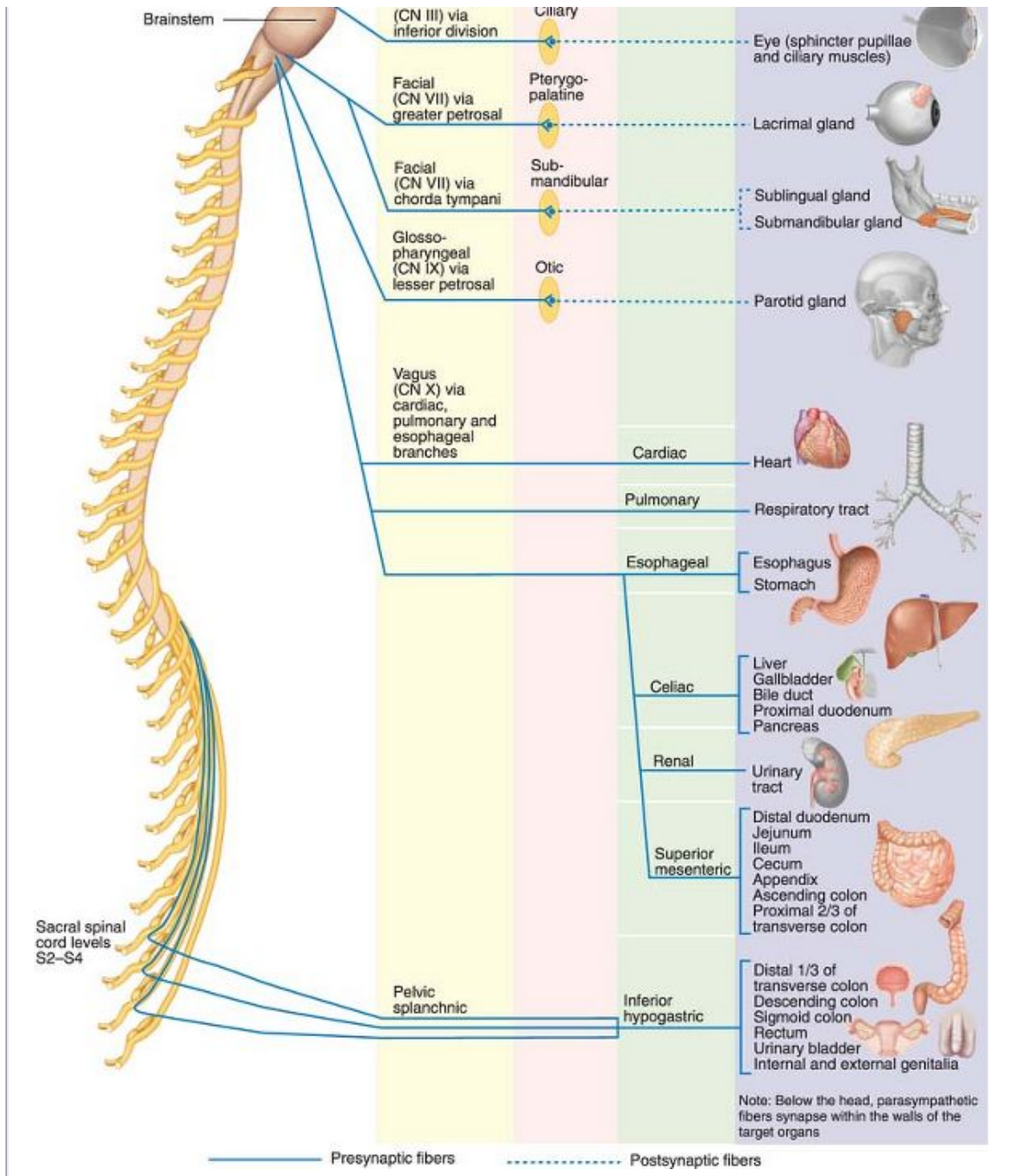
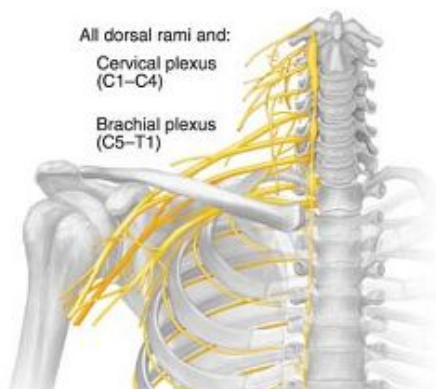
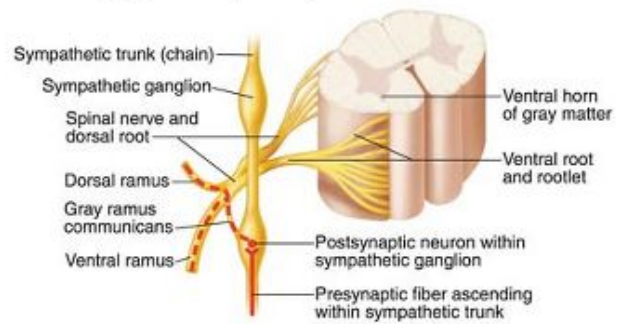


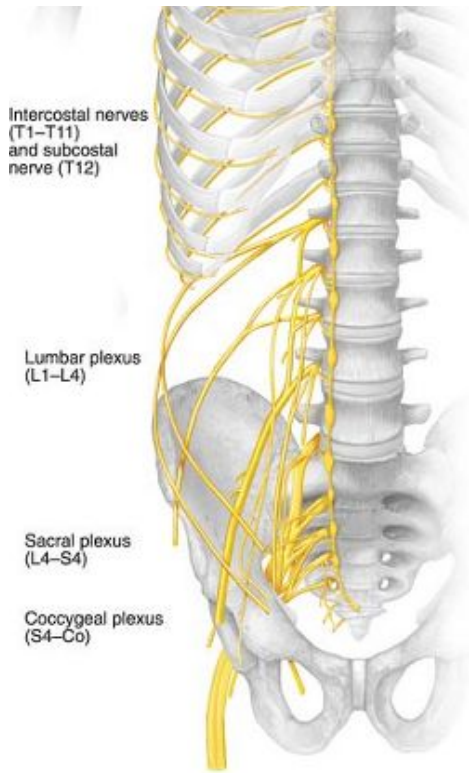
Plate 8-12 Pathways of the Parasympathetic Nervous System

A. Nerves carrying sympathetic fibers to the limbs and body wall

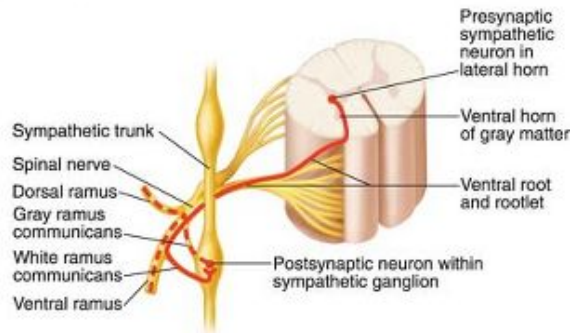


B. Sympathetic pathways at C1-C8 levels





C. Sympathetic pathways at T1-L2 levels



D. Sympathetic pathways at L3-Co levels

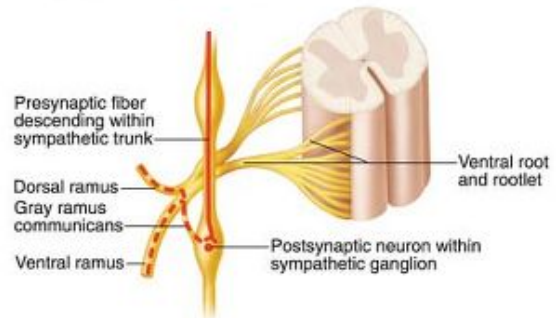
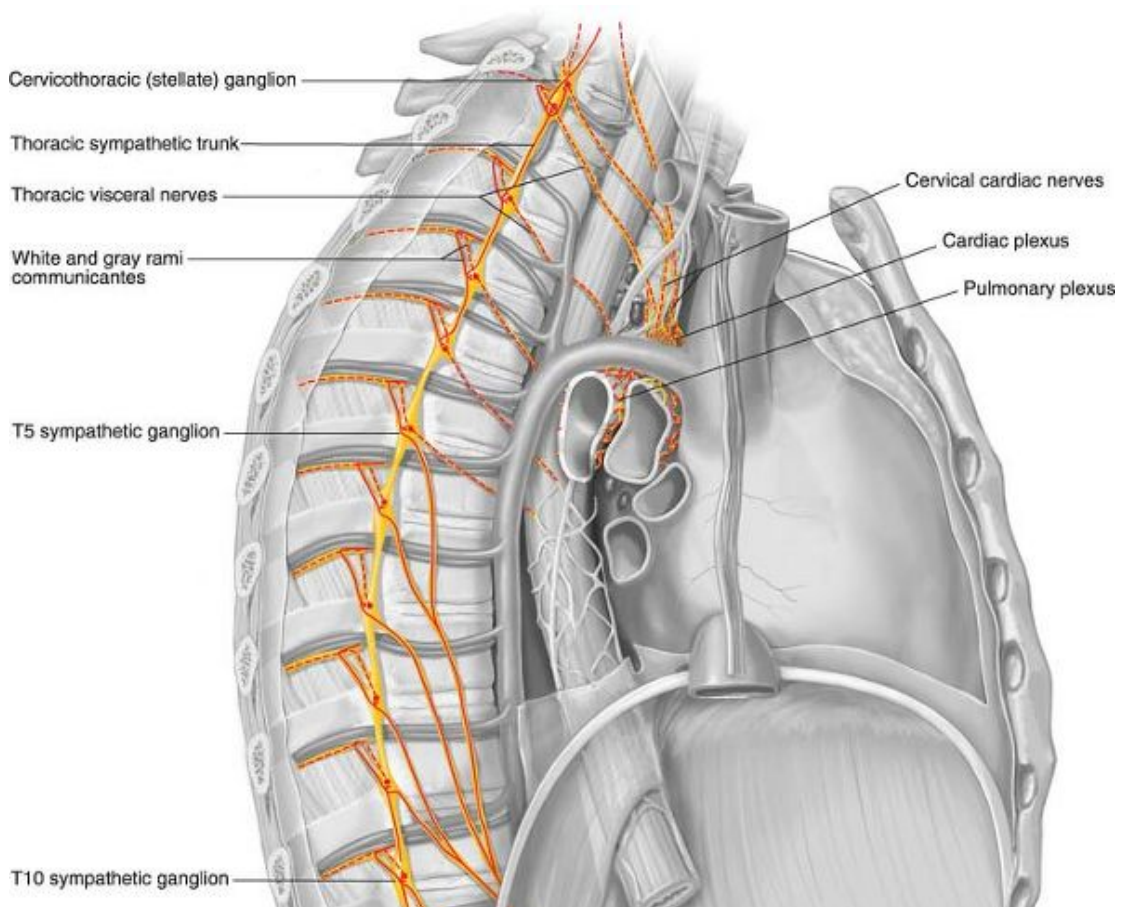


Plate 8-13 Autonomics of the Limbs and Body Wall



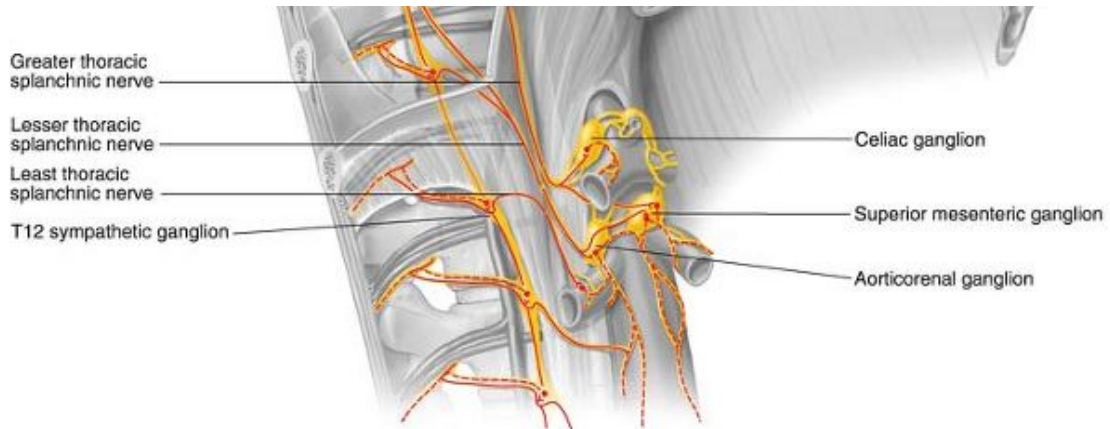


Plate 8-14 Autonomics of the Thorax, Sympathetic Pathways

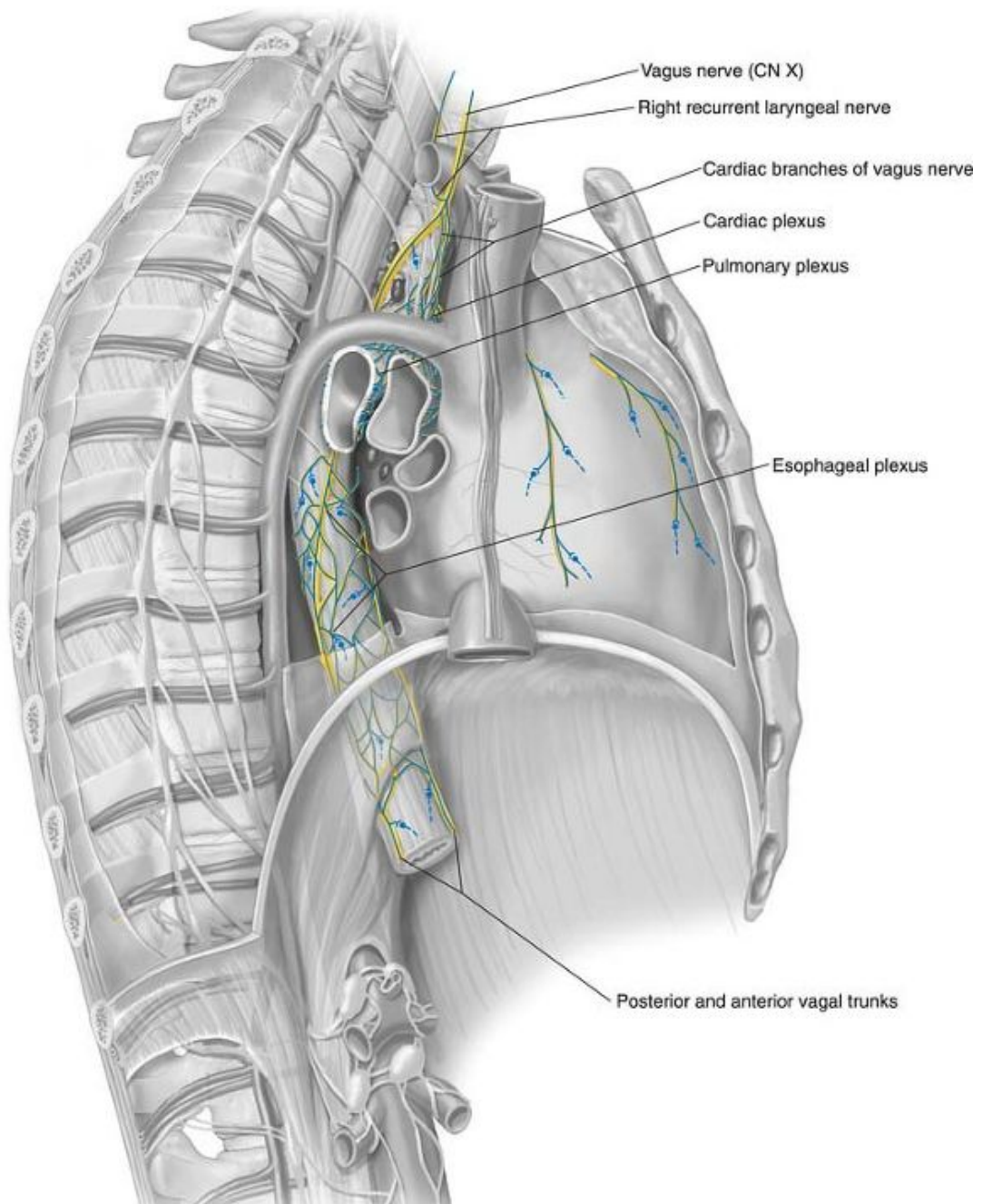
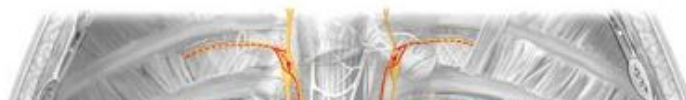



Plate 8-15 Autonomics of the Thorax, Parasympathetic Pathways

P.410



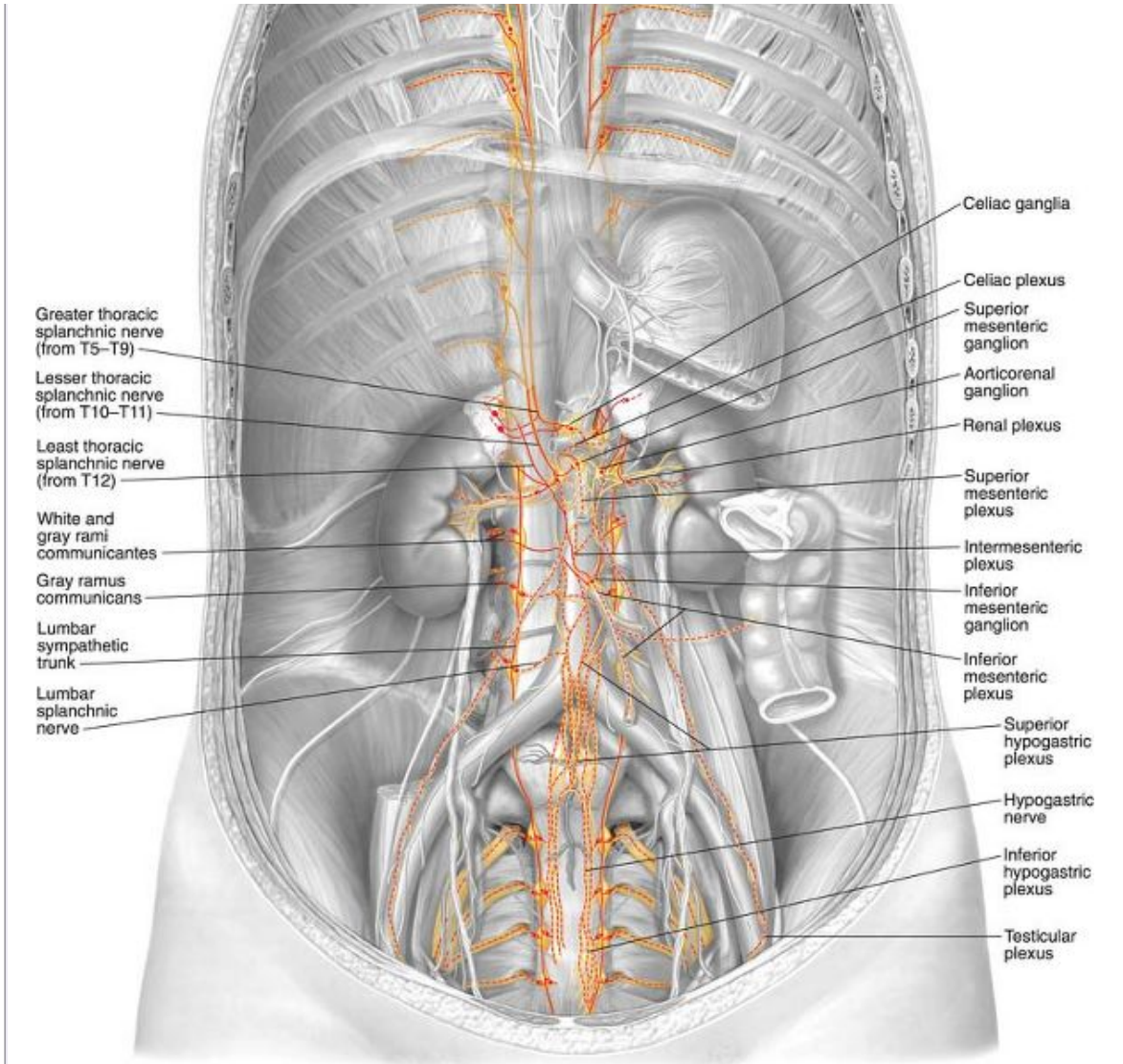


Plate 8-16 Autonomics of the Abdomen, Sympathetic Pathways

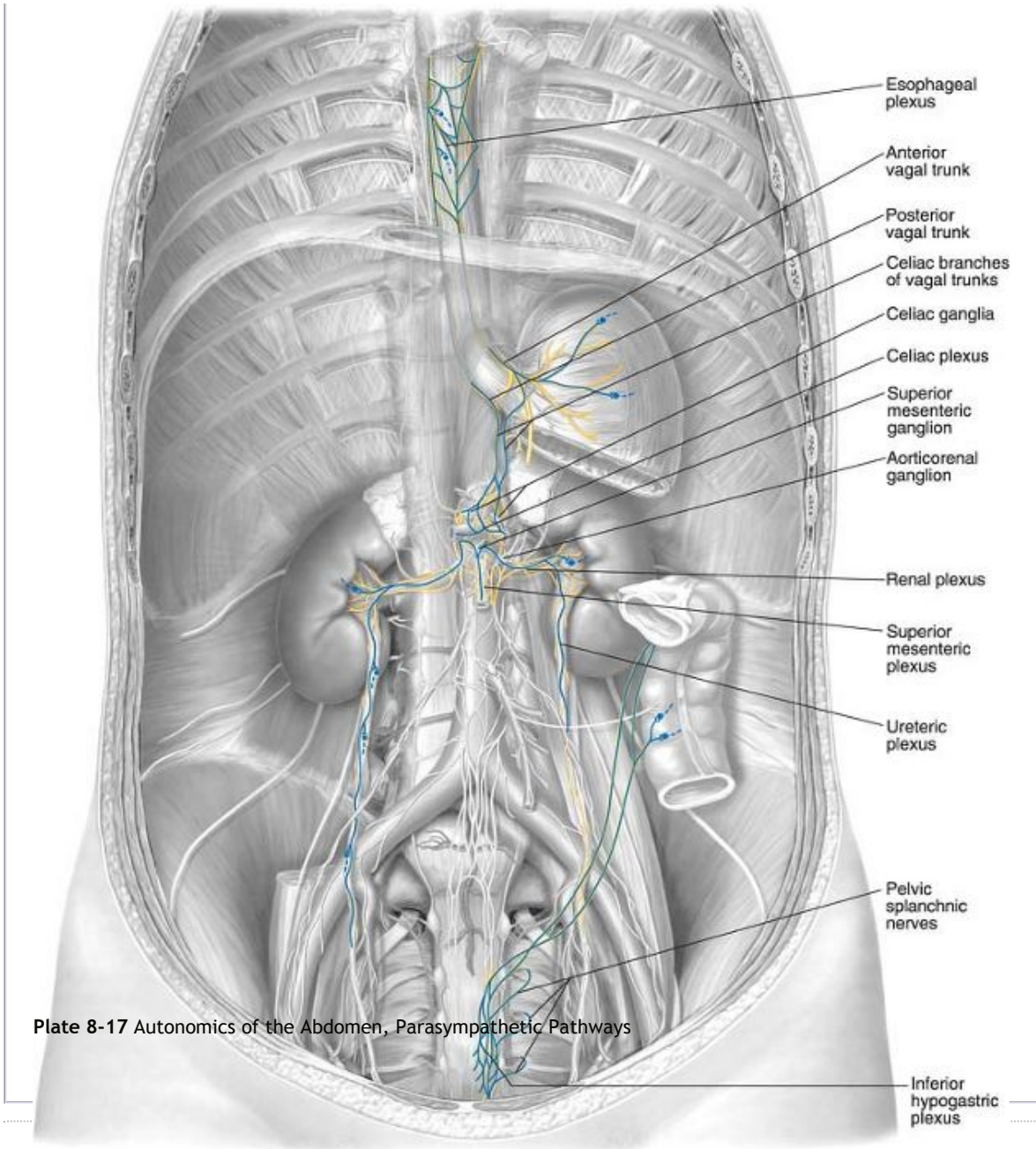


Plate 8-17 Autonomics of the Abdomen, Parasympathetic Pathways

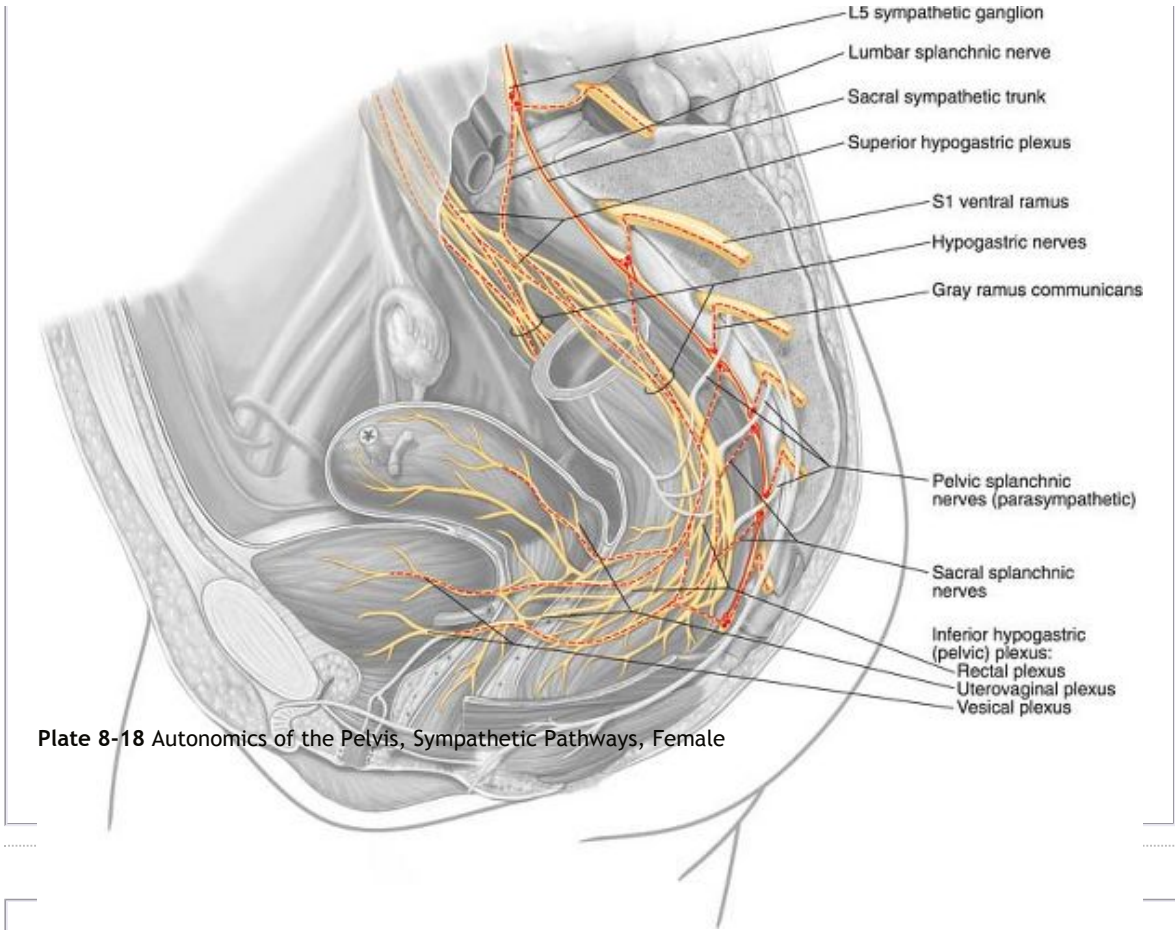


Plate 8-18 Autonomics of the Pelvis, Sympathetic Pathways, Female

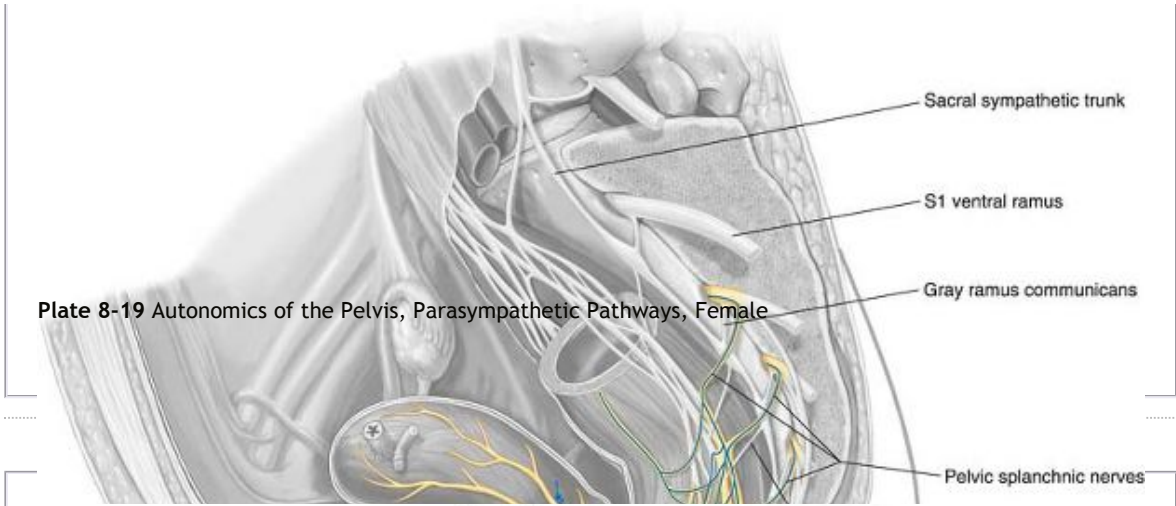


Plate 8-19 Autonomics of the Pelvis, Parasympathetic Pathways, Female

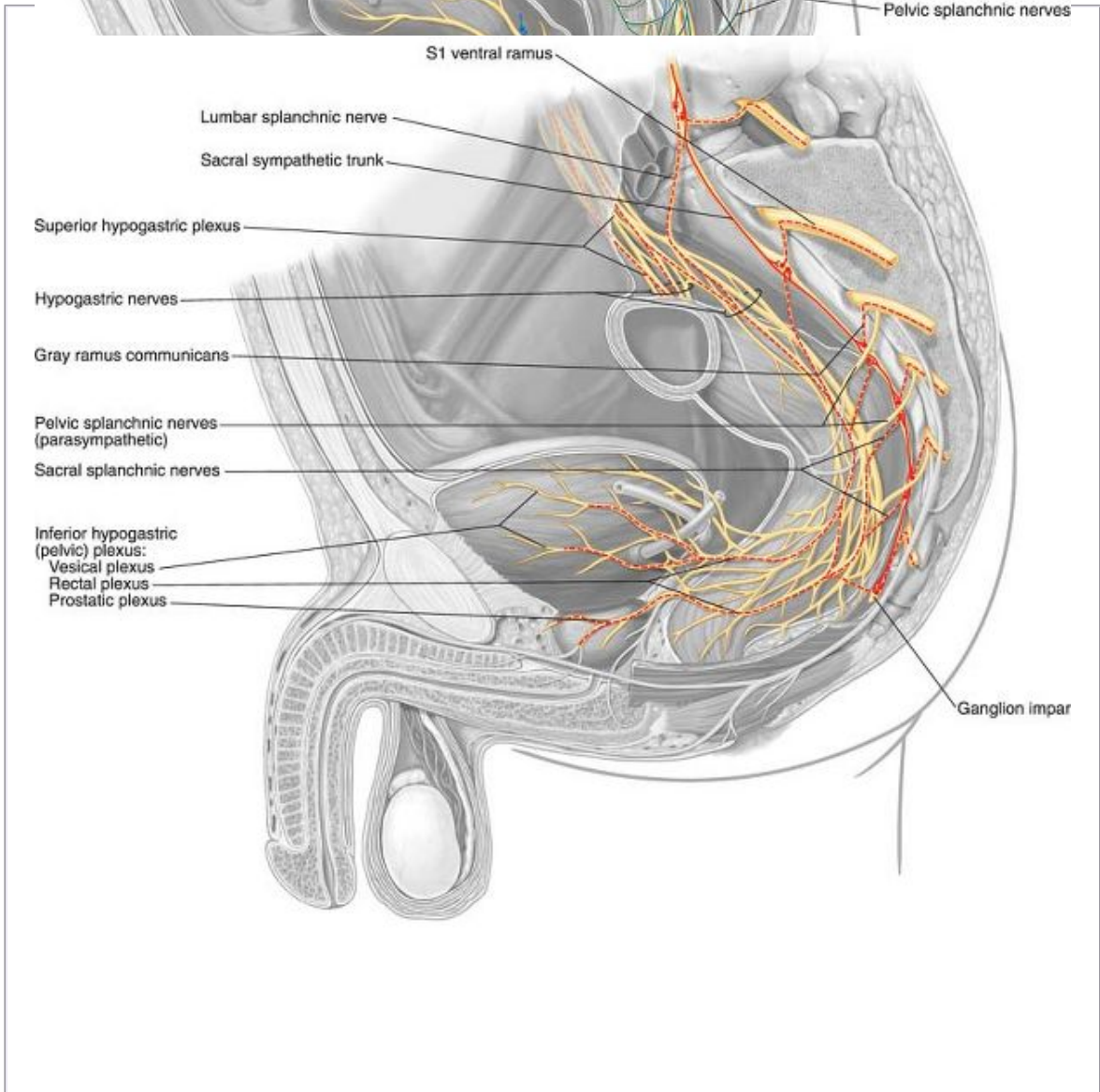


Plate 8-20 Autonomics of the Pelvis, Sympathetic Pathways, Male

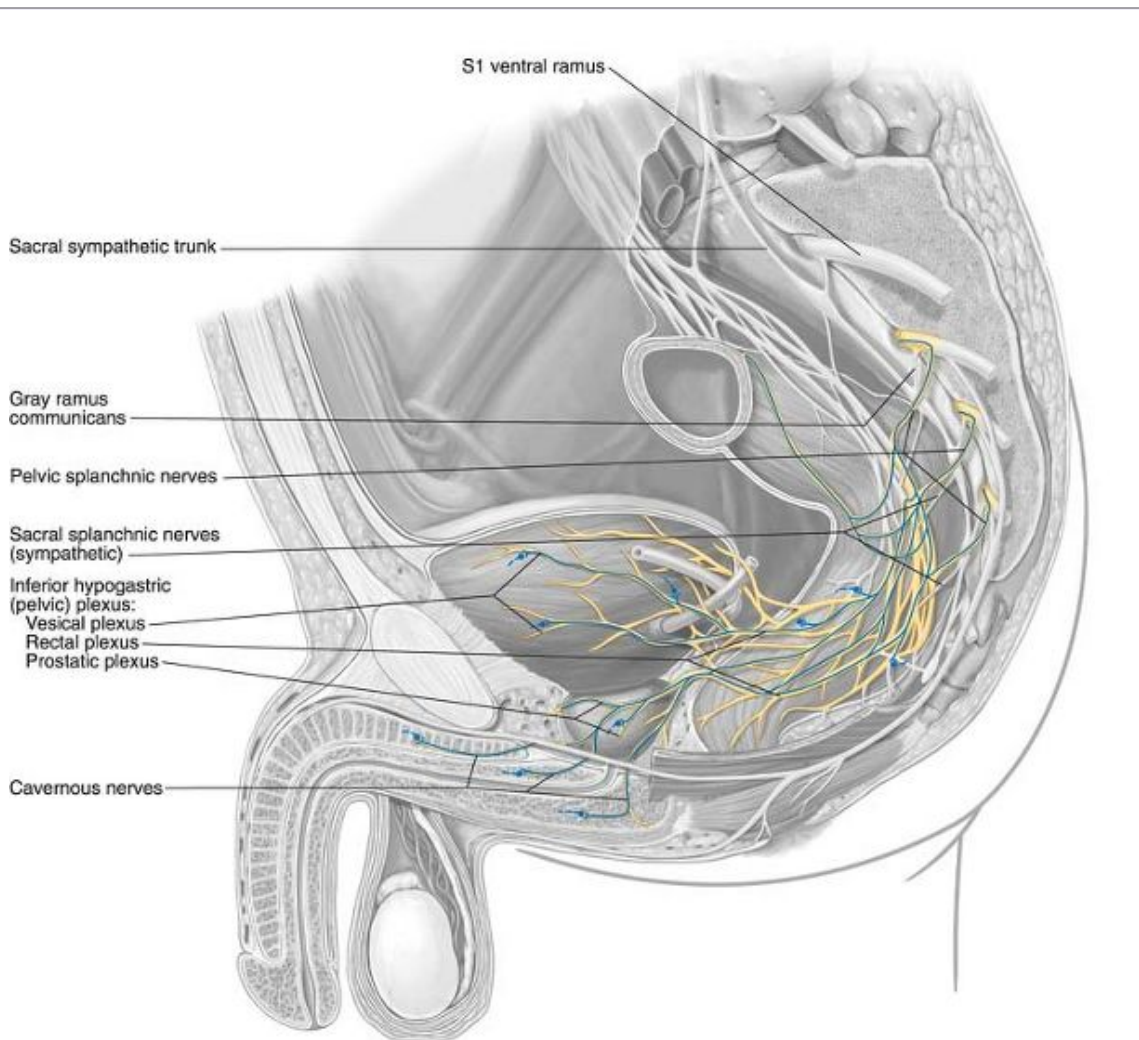


Plate 8-21 Autonomics of the Pelvis, Parasympathetic Pathways, Male

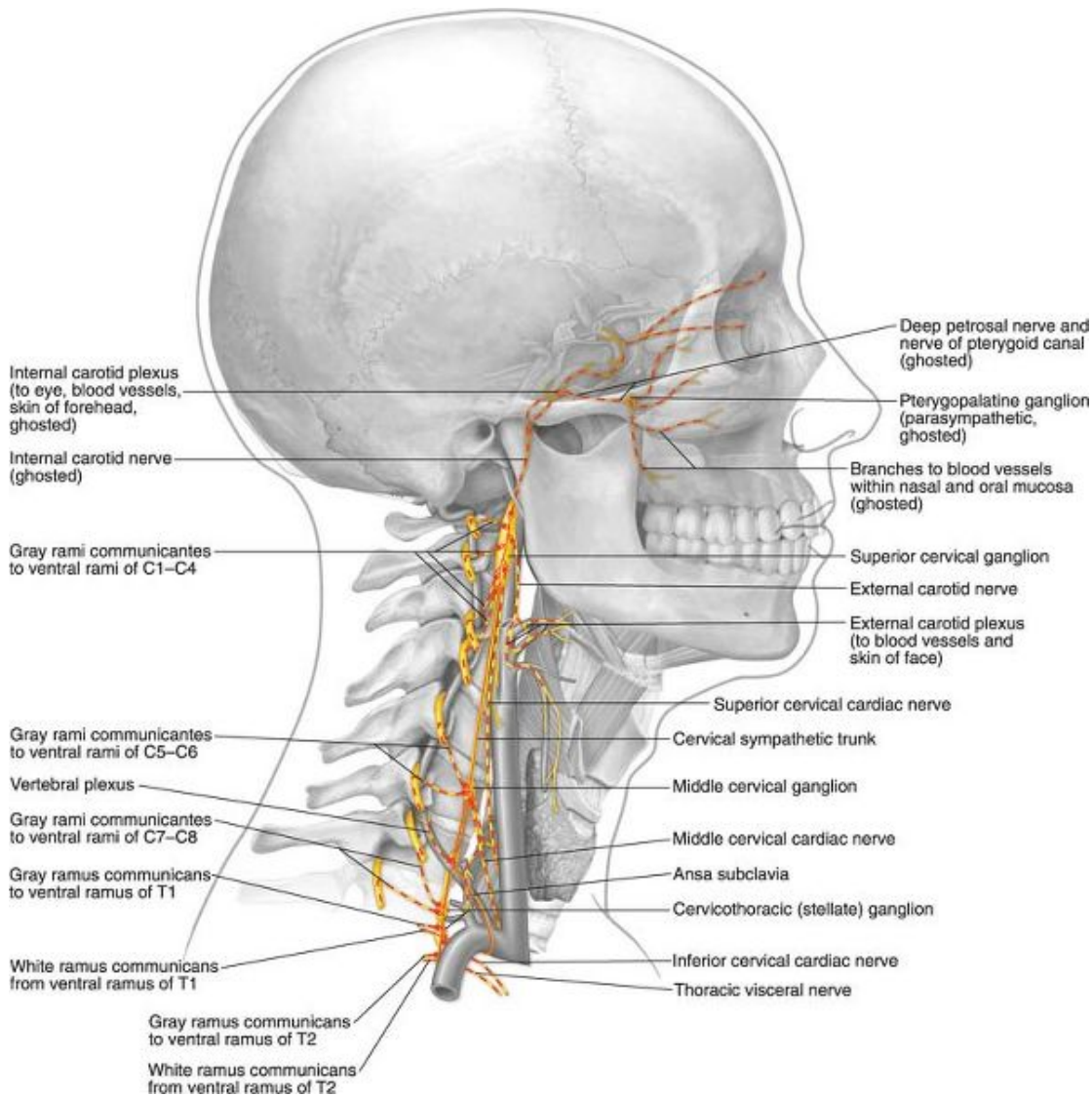


Plate 8-22 Autonomics of the Head and Neck, Sympathetic Pathways

